

Combined 1p/19q Loss in Oligodendroglial Tumors: Predictive or Prognostic Biomarker?

Michael Weller,¹ Hilmar Berger,² Christian Hartmann,³ Johannes Schramm,⁴ Manfred Westphal,⁶ Matthias Simon,⁴ Roland Goldbrunner,⁷ Dietmar Krex,⁸ Joachim P. Steinbach,¹ Christoph B. Ostertag,⁹ Markus Loeffler,² Torsten Pietsch,⁵ and Andreas von Deimling³ for The German Glioma Network

Abstract **Purpose:** The combined loss of genetic material on chromosomes 1p and 19q is strongly associated with favorable outcome in patients with WHO grade 3 anaplastic oligodendroglial tumors. The prognostic value of 1p/19q loss in WHO grade 2 oligodendroglial tumors is less well defined. Importantly, the possible effect of combined 1p/19q loss has not been studied in patients who were not treated with radiotherapy or chemotherapy. **Experimental Design:** Seventy-six patients with oligodendroglioma ($n = 33$), oligoastrocytoma ($n = 30$), anaplastic oligodendroglioma ($n = 6$), or anaplastic oligoastrocytoma ($n = 7$) were identified who had not received radiotherapy or chemotherapy after their first operation until the end of follow-up or until the first progression and had tissue for 1p/19q status available. 1p/19q status was assessed by multiplex ligation – dependent probe amplification. **Results:** After a median follow-up of 3.8 years, progressive disease was documented in 34 patients. The estimated median progression-free survival was 4.6 years. Fifty-eight of the 76 patients had a combined loss of 1p and 19q. The absence or presence of combined 1p/19q loss was not prognostic for progression-free survival using multivariate adjustment for histology, extent of resection, and gender. **Conclusions:** Combined 1p/19q loss is not a sensitive prognostic biomarker in patients with oligodendroglial tumors who do not receive radiotherapy or chemotherapy. The gene products lost as a consequence of this codeletion may include mediators of resistance to genotoxic therapies. Alternatively, 1p/19q loss might be an early oncogenic lesion promoting the formation of glial neoplasms, which retain high sensitivity to genotoxic stress.

Loss of genetic material on chromosomal arms 1p and 19q in the tumor tissue has been linked to a subset of patients with oligodendroglial tumors with a more favorable outcome (1). The prognostic role of 1p/19q loss is better defined for anaplastic WHO grade 3 tumors than for grade 2 tumors. The striking coexistence of these losses has recently been linked to a centromeric or pericentromeric translocation event between

chromosomes 1 and 19 preceding the loss of genetic material (2). Whereas it was initially shown that 1p/19q loss predicted response to chemotherapy with procarbazine, 1-(2-chloroethyl)-3-cyclohexyl-L-nitrosourea (lomustine), and vincristine (PCV regimen), it soon became clear that 1p/19q loss also predicted prolonged survival in patients receiving radiotherapy only (3). More recently, two large randomized trials, Radiation Therapy Oncology Group 94-02 and European Organization for Research and Treatment of Cancer 26951, compared radiotherapy alone with radiotherapy combined with PCV chemotherapy in patients with anaplastic oligodendroglial tumors. Both studies showed a moderate prolongation of progression-free survival (PFS) but failed to show a beneficial effect of combination treatment on overall survival. The loss of 1p/19q was a strong predictor of longer PFS [hazard ratio (HR), 0.44] and overall survival (HR, 0.31; refs. 4, 5). This effect was similar in both treatment arms of both trials. Accordingly, these results do not answer the question on whether 1p/19q loss is a molecular marker defining two subgroups of oligodendroglial tumors with identical morphology but different outcome, or whether this molecular feature predicts prolonged PFS and overall survival in response to radiotherapy or chemotherapy. To answer this question, it is necessary to determine the 1p/19q status in the tumor tissue in patients with oligodendroglial tumors who did not receive any adjuvant treatment after their first tumor resection and were followed up until their first

Authors' Affiliations: ¹Department of General Neurology, University of Tübingen, Tübingen, Germany; ²Institute of Medicinal Informatics, Statistics and Epidemiology, University of Leipzig, Leipzig, Germany; ³Institute of Neuropathology, Charité, Universitätsmedizin Berlin, Berlin, Germany; ⁴Departments of Neurosurgery and ⁵Neuropathology, University of Bonn, Bonn, Germany; ⁶Department of Neurosurgery, University of Hamburg, Hamburg, Germany; ⁷Department of Neurosurgery, University of Munich, Munich, Germany; ⁸Department of Neurosurgery, University of Dresden, Dresden, Germany; and ⁹Department of Stereotactic Neurosurgery, University of Freiburg, Freiburg, Germany
Received 3/8/07; revised 7/19/07; accepted 9/12/07.

Grant support: The German Glioma Network is supported by the Deutsche Krebshilfe.

The costs of publication of this article were defrayed in part by the payment of page charges. This article must therefore be hereby marked *advertisement* in accordance with 18 U.S.C. Section 1734 solely to indicate this fact.

Requests for reprints: Michael Weller, Department of General Neurology, University of Tübingen Medical School, Hoppe-Seyler-Strasse 3, D-72076 Tübingen, Germany. Phone: 49-7071-29-82049; Fax: 49-7071-29-5260; E-mail: michael.weller@uni-tuebingen.de.

© 2007 American Association for Cancer Research.
doi:10.1158/1078-0432.CCR-07-0573

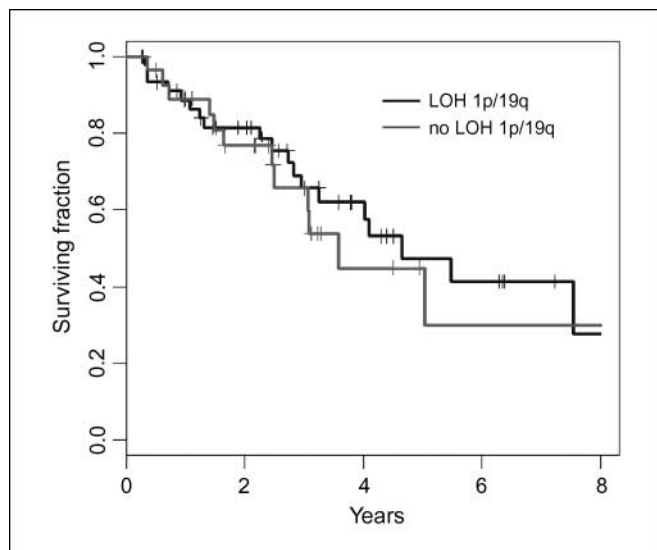


Fig. 1. PFS in all patients with combined LOH 1p/19q versus patients without this aberration ($P = 0.99$).

tumor progression. Such patients are more likely to be identified in the population of patients with grade 2 tumors than in those with grade 3 tumors whereas the prognostic effect of the 1p/19q status has been more convincingly shown in the latter. The six clinical centers of the German Glioma Network conducted a retrospective search for such patients to gain more information on the radiochemotherapy-independent prognostic value of the 1p/19q loss.

Materials and Methods

Patient selection. We identified 76 patients with oligodendroglioma ($n = 33$), oligoastrocytoma ($n = 30$), anaplastic oligodendro-

glioma ($n = 6$), or anaplastic oligoastrocytoma ($n = 7$) who (a) had not received radiotherapy or chemotherapy after their first operation until the first progression or the end of follow-up and (b) had tissue for 1p/19q status available. Progressive disease was defined by neuroradiologic criteria, which conformed to Macdonald criteria for contrast-enhancing lesions, or similar adapted criteria for nonenhancing lesions. There was no central neuroradiologic review. Tissues of 48 patients were available for central pathology review done by a neuropathologist (T.P.) according to the current WHO classification. The histologic diagnosis was changed from oligodendroglioma to oligoastrocytoma in 1 case, from oligodendroglioma to anaplastic oligoastrocytoma in 1 case, from oligodendroglioma to anaplastic oligodendroglioma in 3 cases, and from anaplastic oligodendroglioma to anaplastic oligoastrocytoma in 1 case. Thus, the 48 diagnoses in the centrally reviewed group of patients were 14 oligodendroglioma, 22 oligoastrocytoma, 6 anaplastic oligodendroglioma, and 6 anaplastic oligoastrocytoma. Before the extraction of DNA from tumor tissues by standard methods, all tumor samples were examined by an experienced neuropathologist (A.v.D.) to exclude contaminating nontumorous portions.

Multiplex ligation-dependent probe amplification. Multiplex ligation-dependent probe amplification (MLPA; ref. 6) was used for the determination of allelic losses in the tumor samples because no constitutional DNA was available for these archival tissues. The analysis was done using the SALSA MLPA KIT P088 lots 0305 and 0705 (MRC Holland). The kit contains 16 probes covering 1p, 8 probes covering 19q, and 19 control probes of other chromosomal locations. MLPA was done according to the manufacturer's protocol. PCR products were separated and quantified on an ABI 3730XL DNA analyzer (Applied Biosystems) and Genemapper 3.7 software using the AFLP algorithm (Applied Biosystems). In each run, at least four reference samples were included. DNA quality was evaluated by analyzing the DQ probes provided by the kit. The allelic status for each sample was determined as follows: peak areas of 19 control probes, which are included in P088, were calculated; an average peak area for the 19 control genes was determined; then, peak areas from each individual probe on 1p and 19q were divided by the value for the average peak area of control probes. We determined this average ratio on seven nontumorous DNAs for each probe on 1p and 19q and repeated this experiment four times.

Table 1. 1p/19q status by histology, gender, and extent of resection

	All	LOH 1p/19q	No LOH 1p/19q	P
Age (y), median (min.-max.)	39.7 (17.4-66.9)	40.5 (19.7-66.9)	38.0 (17.4-60.0)	0.45
Gender, n (%)				
Male	46 (61)	25 (52)	21 (75)	0.056
Female	30 (39)	23 (48)	7 (25)	
Histologic diagnosis, n (%)				
OA	30 (39)	15 (31)	15 (54)	0.07
AOA	7 (9)	6 (12)	1 (4)	
O	33 (43)	21 (44)	12 (43)	
AO	6 (8)	6 (12)	0 (0)	
Review diagnosis only, n (%)				
OA	22 (29)	13 (27)	9 (32)	0.23*
AOA	6 (8)	5 (10)	1 (4)	
O	14 (18)	11 (23)	3 (11)	
AO	6 (8)	6 (12)	0 (0)	
Not available	28 (37)	13 (27)	15 (54)	
Extent of resection, n (%)				
Biopsy only	1 (1)	0 (0)	1 (4)	0.01*
Partial (<50%)	6 (8)	3 (6)	3 (11)	
Subtotal (50-99%)	25 (33)	21 (44)	4 (14)	
Total	36 (47)	18 (38)	18 (64)	
Not available	8 (11)	6 (12)	2 (7)	

Abbreviations: O, oligodendroglioma, AO, anaplastic oligodendroglioma, OA, oligoastrocytoma, AOA, anaplastic oligoastrocytoma. *P values were calculated based on evaluable cases.

Table 2. Median PFS by 1p/19q status

1p/19q loss	Patients (n)	Events (n)	Median PFS (y)	95% CI (y)	P
All patients					
Yes	48	21	4.64	3.25-8.69	0.99
No	28	13	3.58	2.49-8	
Patients with central pathology review					
Yes	35	15	5.49	3.25-8.69	
No	13	4	3.58	3.05-8	
Patients without central pathology review					
Yes	13	6	4.64	2.25-8	
No	15	9	2.46	1.40-8	
Patients with grade 2 tumors only					
Yes	36	15	4.64	2.95-8	
No	27	13	3.58	2.49-8	

SD of this ratio for each probe was determined for the data of the multiple rounds of analyses on these seven control tissues. A ratio deviating >2 SD from that established for each of the probes in control tissues was scored as altered gene dosage. Because SDs for all data from controls were within narrow limits, data from tumors with a ratio <0.7 fulfilled these criteria for reduced gene dosage and ratios >1.3 indicated elevated gene dosage. Chromosomal regions from tumors were scored as underrepresented or overrepresented if two or more probes on 1p or 19q adjacent to each other exhibited a ratio <0.7 or >1.3 .

Loss of heterozygosity analysis. Corresponding constitutional DNA was available in 14 cases. These paired DNA samples served as a verification set for the MLPA analysis. DNA from blood and tumor was amplified with the microsatellite markers D1S1608, D1S548, D1S1592, D1S1161, and D1S1184 for 1p and with the markers D19S433, D19S431, D19S718, D19S559, and D19S601 for 19q to determine loss of heterozygosity (LOH). PCR products were separated on 8% denaturing acrylamide gels and visualized by silver staining (7).

Statistical analysis. Statistical analysis was done using the statistical software R (8). The Mann-Whitney *U* test, χ^2 test, and Fisher exact test were used to test for association of clinical variables and 1p/19q loss. The log-rank test was used to test for survival differences among groups. PFS was calculated from the day of first surgery until tumor progression, death, or end of follow-up. The effect of combined 1p/19q loss on PFS adjusted for gender, extent of resection, and age was analyzed using the Cox proportional hazards model. Combined loss of 1p/19q was defined as either partial or complete deletion of chromosome arms 1p and 19q.

Results

The median follow-up of the 76 patients was 3.8 years. Progression was documented in 34 patients. The estimated median PFS was 4.6 years [95% confidence interval (95% CI), 3.1-7.5; Fig. 1]. All cases had initial surgery except 2 (2.6%) cases that had a resection within 2 and 7 months after a stereotactic biopsy. One patient had only a biopsy; 6 (7.8%), 25 (32.9%), and 37 (48.7%) had partial ($<50\%$), subtotal (50-99%), or total resections, respectively; and 8 (10.5%) had a resection of unknown extent. Molecular analysis revealed a loss of 1p/19q in 48 (63%) of the patients; 4 (5.2%), 2 (2.6%), and 22 (28.9%) had isolated loss of 19q, loss of 1p, or intact chromosomes 1p and 19q. In 13 of 14 DNA sets, the MLPA and LOH results were identical, showing combined DNA losses on 1p/19q in 4 cases, loss on 19q but wild-type 1p in 1 case, and wild-type status of both 1p/19q in 8 cases. In 1 case, MLPA showed reduced gene dosage in only one and the most telomeric marker on 19q. This case was not

scored as carrying loss because our scoring criteria for loss require two adjacent markers with reduced gene dosage. Microsatellite analysis of this sample detected also reduced gene dosage in the telomeric marker D19S601 and was scored as loss. All statistical analyses were done on the MLPA data set.

The clinical characteristics of the patients with and without combined loss of 1p/19q are shown in Table 1. Patients with loss of 1p/19q had significantly fewer total resections on initial surgery than patients without. Further, the patients without loss of 1p/19q tended to be male (75% versus 52%; $P = 0.056$) and showed a higher frequency of oligoastrocytoma (54% versus 31%) than the other group.

The essential results of univariate analysis of PFS are summarized in Table 2. By univariate survival analysis, we find that the absence or presence of a combined 1p/19q loss is not associated with a different PFS. In multivariate models, including stratifications by histology, local or central review, age, or gender (data not shown), the HR for PFS for cases harboring combined loss of 1p/19q versus no loss 1p/19q in all cases was 0.99 (95% CI, 0.486-2.04; $P = 0.99$). When gender, extent of resection, and histology were used to adjust for imbalances of these factors in the genetically defined groups, the HR for loss of 1p/19q was 0.91 (95% CI, 0.39-2.14, $P = 0.83$). None of the other factors reached significance (Table 3) but extent of resection showed a trend for lower risk

Table 3. Multivariate analysis of PFS ($n = 68$ patients with data for all factors available)

Factor	Relative risk of progression (95% CI)	P
LOH 1p/19q		
No LOH	1.00	0.83
LOH	0.91 (0.39-2.14)	
Resection		
No total resection	1.00	0.36
Total resection	0.67 (0.29-1.58)	
Age (y)		
≤ 40	1.00	0.64
> 40	0.83 (0.38-1.80)	
Gender		
Female	1.00	0.69
Male	1.20 (0.50-2.88)	

Table 4. Multivariate analysis of PFS ($n = 57$ patients with grade 2 tumors and data for all factors available)

Factor	Relative risk of progression (95% CI)	P
LOH 1p/19q		
No LOH	1.00	
LOH	0.80 (0.33-1.95)	0.62
Resection		
No total resection	1.00	
Total resection	0.50 (0.20-1.26)	0.14
Age (y)		
≤ 40	1.00	
> 40	0.78 (0.33-1.82)	0.56
Gender		
Female	1.00	
Male	1.39 (0.51-3.83)	0.52

when total resection was done (HR, 0.67; 95% CI, 0.29-1.58). Similar results were observed when the analysis was restricted to WHO grade 2 tumors (Table 4).

Discussion

The somewhat unexpected results of two large randomized trials on the role of adjuvant chemotherapy, in addition to radiotherapy in anaplastic oligodendroglial tumors (4, 5), have reinforced the controversy over the use of 1p/19q loss as a prognostic or predictive marker. Both Radiation Therapy Oncology Group 94-02 and European Organization for Research and Treatment of Cancer 26951 had indicated that 1p/19q loss characterizes a less malignant variant of disease independent of whether radiotherapy or combined radiochemotherapy was administered. The observation until first progression of surgically treated patients followed without adjuvant radiotherapy or chemotherapy is the only way to determine whether the 1p/19q status predicts outcome in the absence of adjuvant treatment and is thus a prognostic marker independent of radiotherapy and chemotherapy. For anaplastic tumors, such a series cannot be retrieved retrospectively because it has been a standard of care for many years to treat patients with anaplastic tumors (WHO grade 3) either by radiotherapy or chemotherapy, or both, after surgery, but never by mere observation. In contrast, patients with WHO grade 2 tumors were often managed with a policy of wait-and-see after their first surgical intervention. Accordingly, WHO grade 2 tumors greatly outnumber WHO grade 3 tumors in the present series. The expected median PFS in a cohort of glioma patients as studied here is in the range of 3 to 5 years. The estimated PFS of 4.6 years in our population is thus not unexpected, given the selection bias that patients who were selected for a wait-and-see strategy commonly exhibit favorable prognostic factors. We

acknowledge that our study has several weaknesses. The sample size is relatively small. The design is largely retrospective. There are inhomogeneities of the two patient groups in that patients with a 1p/19q deletion were less likely to have a gross total resection. There were few patients with grade 3 lesions for which the prognostic value of 1p/19q status in the setting of radiotherapy or chemotherapy is much better defined. Nevertheless, as the essential conclusion from our study, summarized in Tables 2–4, we propose that the loss of 1p/19q per se, in the absence of genotoxic treatment, does not confer a major PFS advantage.

Kanner et al. (9) reported a significantly longer survival for oligodendrogloma patients with loss of 1p who received no adjuvant therapy after initial surgery compared with patients with intact chromosome 1p. However, PFS was not analyzed and the influence of 1p loss on survival was not adjusted for salvage therapy administered at the time of progression. A favorable prognostic effect for 1p/19q loss has also been claimed for a series of 66 patients with grade 2 gliomas who had never been treated with chemotherapy. However, 19% of these patients had radiotherapy at diagnosis. Because the patients with tumors lacking 1p/19q loss were more likely to be irradiated, the authors concluded that the effect of radiotherapy could not have produced an artifactual gain in survival in patients with tumors with 1p/19q loss. Importantly, 75% of the patients in that series had a pure astrocytic histology (10). Our series has the advantage that the decision to adopt a wait-and-see strategy was solely based on clinical considerations in a nonbiased way regarding molecular genetic findings in the tumor.

The MLPA technique has the advantage that no paired samples of constitutional and tumor DNA are necessary for the detection of DNA losses. However, the application of this novel method should be tightly controlled. We therefore validated the MLPA results with microsatellite analysis on a set of 14 patients of this study with both tumor and constitutional DNA available. All sets but one yielded identical results. In one tumor, both the terminal marker in the MLPA set and the terminal microsatellite marker exhibited reduced gene dosage. However, due to our definition of scoring loss by MLPA requiring two adjacent markers with alteration, this case was not scored as carrying a loss on 19q whereas it scored for LOH in the microsatellite analysis. Thus, data from MLPA and microsatellite analysis matched perfectly and both methods showed similar sensitivity and specificity.

We conclude that combined 1p/19q loss is not a strong prognostic biomarker in patients with oligodendroglial tumors who do not receive radiotherapy or chemotherapy. Thus, the gene products lost as a consequence of this codeletion may be mediators of resistance to genotoxic therapies. Alternatively, 1p/19q loss could be an early oncogenic lesion in glial tumorigenesis, which results in the formation of a characteristic subgroup of tumors sharing the retention of tumor suppressor and apoptosis proficiency pathways in response to genotoxic stress.

References

- Cairncross JG, Ueki K, Zlatescu MC, et al. Specific genetic predictors of chemotherapeutic response and survival in patients with anaplastic oligodendrogliomas. *J Natl Cancer Inst* 1998;90:1473–9.
- Jenkins RB, Blair H, Ballman KV, et al. A t(1;19) (q10;p10) mediates the combined deletions of 1p and 19q and predicts a better prognosis of patients with oligodendroglioma. *Cancer Res* 2006;66:9852–61.
- Bauman GS, Ino Y, Ueki K, et al. Allelic loss of chromosome 1p and radiotherapy plus chemotherapy in patients with oligodendrogliomas. *Int J Radiat Oncol Biol Phys* 2000;48:825–30.
- Intergroup Radiation Therapy Oncology Group Trial 9402; Cairncross G, Berkey B, Shaw E, et al. Phase III trial of chemotherapy plus radiotherapy compared with

- radiotherapy alone for pure and mixed anaplastic oligodendroglioma: Intergroup Radiation Therapy Oncology Group Trial 9402. *J Clin Oncol* 2006;24:2707–14.
5. van den Bent MJ, Carpentier AF, Brandes AA, et al. Adjuvant procarbazine, lomustine, and vincristine improves progression-free survival but not overall survival in newly diagnosed anaplastic oligodendrogliomas and oligoastrocytomas: a randomized European Organisation for Research and Treatment of Cancer phase III trial. *J Clin Oncol* 2006;24:2715–22.
6. Jeuken J, Cornelissen S, Boots-Sprenger S, et al. Multiplex ligation-dependent probe amplification: a diagnostic tool for simultaneous identification of different genetic markers in glial tumors. *J Mol Diagn* 2006;8:433–43.
7. Hartmann C, Müller W, Lass U, et al. Molecular genetic analysis of oligodendroglial tumors. *J Neuropathol Exp Neurol* 2005;64:10–4.
8. R Development Core Team. R: a language and environment for statistical computing. Vienna (Austria): R Foundation for Statistical Computing; 2005.
9. Kanner AA, Staugaitis SM, Castilla EA, et al. The impact of genotype on outcome in oligodendroglioma: validation of the loss of chromosome arm 1p as an important factor in clinical decision making. *J Neurosurg* 2006;104:542–50.
10. Mariani L, Deiana G, Vassella E, et al. Loss of heterozygosity 1p36 and 19q13 is a prognostic factor for overall survival in patients with diffuse WHO grade 2 gliomas treated without chemotherapy. *J Clin Oncol* 2006;24:4758–63.