

IMMEDIATELY LOADED BLADE IMPLANT RETRIEVED FROM A MAN AFTER A 20-YEAR LOADING PERIOD: A HISTOLOGIC AND HISTOMORPHOMETRIC CASE REPORT

Danilo Di Stefano, MD, DDS
Giovanna Iezzi, DDS, PhD
Antonio Scarano, DDS, MD
Vittoria Perrotti, DDS, PhD
Adriano Piattelli, MD, DDS

KEY WORDS

Blade implant
Bone-implant interface
Immediately loaded implant
Retrieved implant

Danilo Di Stefano, MD, DDS, is in private practice in Milano, Italy.

Giovanna Iezzi, DDS, PhD, is a research fellow, Antonio Scarano, DDS, MD, is a researcher, and Vittoria Perrotti, DDS, PhD, is a student in the Dental School, University of Chieti-Pescara, Chieti, Italy.

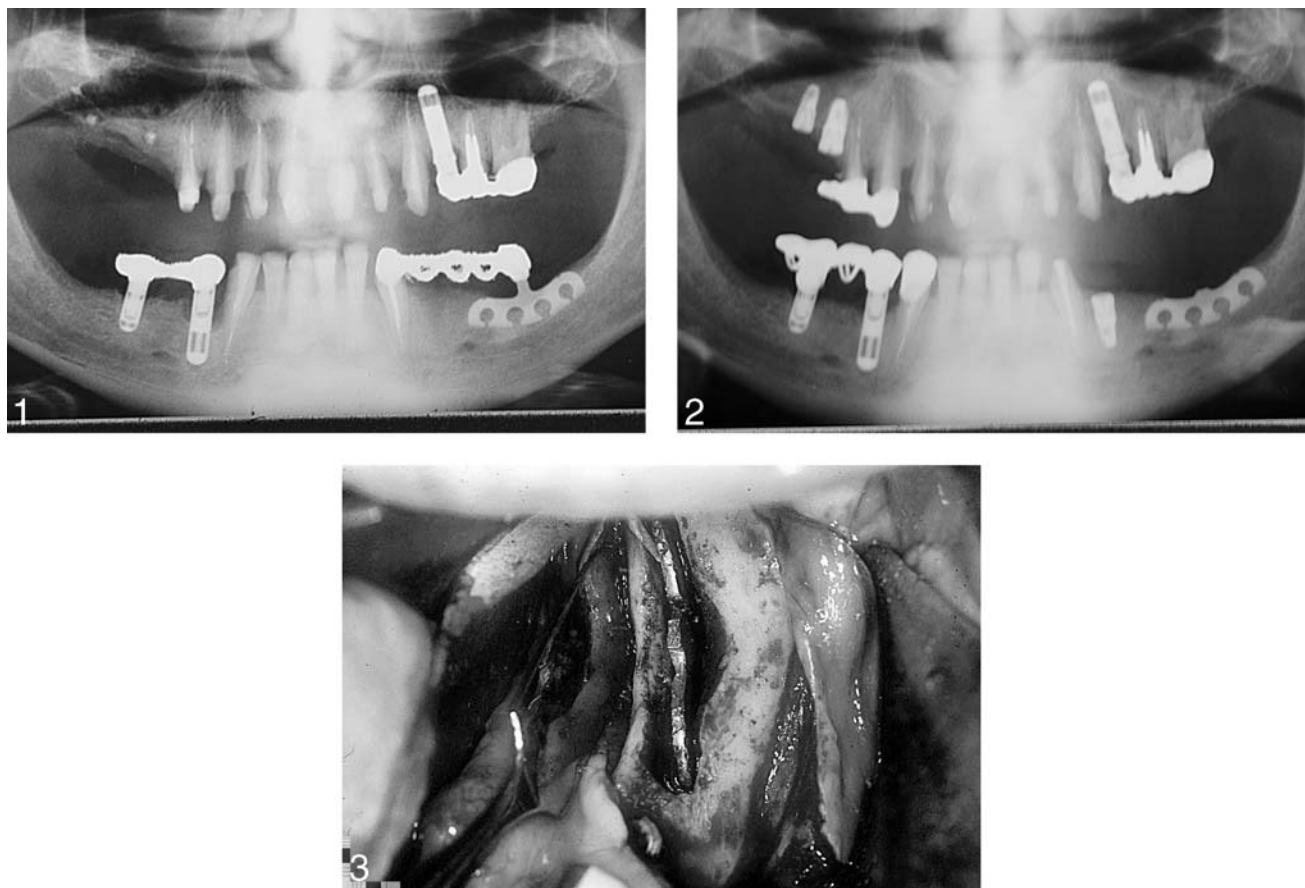
Adriano Piattelli, MD, DDS, is a professor of Oral Pathology and Medicine in the Dental School, University of Chieti-Pescara. Address correspondence to Prof Adriano Piattelli, Via F. Schiucchi 63, 66100 Chieti, Italy (e-mail: apiattelli@unich.it).

Immediate loading of root-form dental implants has shown promising results and offers treatment cost and convenience advantages to patients. Although blade implants have been immediately loaded for over 2 decades, the ability of this implant design to achieve osseointegration has been debated. The aim of the present study was to histologically evaluate the peri-implant tissues of an immediately loaded blade implant retrieved for abutment fracture after a 20-year loading period. Histologic samples were prepared and examined by light microscope. Compact, cortical, mature bone with well-formed osteons was present at the interface of the implant. Bone-to-implant contact was $51\% \pm 6\%$. The histologic data showed that osseointegration was obtained in an immediately loaded blade implant inserted into the mandible, and that mineralized tissues were maintained at the interface over a long period (20 years).

INTRODUCTION

Dental implants have been traditionally manufactured in 3 basic designs: cylinders, screws, and blades. Of these, blade implants generally feature a transgingival design for 1-stage surgical procedures.¹ One-stage implants immediately loaded after surgical insertion are often found to be surrounded by collagen-rich connective tissue without any bone contact²; however, bone has been

shown to be present around stable root-form implants.^{1,3} The high success rate of osseointegration with root-form dental implants is generally attributed to the absence of premature stresses on the tissue-implant interface during the early healing period, when the implant is completely submerged and unloaded; it is also believed that a premature loading of an implant leads to interfacial formation of fibrous tissue instead of bone.⁴⁻⁷ Although the presence of mineralized tissues at the interface



FIGURES 1–3. FIGURE 1. Panoramic radiography of the blade connected with a bridge 20 years ago. FIGURE 2. Panoramic radiography after abutment fracture. No peri-implant radiolucencies or crestal bone resorption were present. FIGURE 3. Clinical aspect of bone tissue around the blade implant.

with blade implants has been reported,^{4,8–13} the view that blade implants cannot osseointegrate still persists. Histologic evidence of osseointegration in clinically successfully osseointegrated implants can be found only rarely in the literature.^{14–26}

The aim of the present study was to histologically evaluate the peri-implant tissues of an immediately loaded blade implant that was removed for abutment fracture after a loading period of 20 years.

CASE REPORT

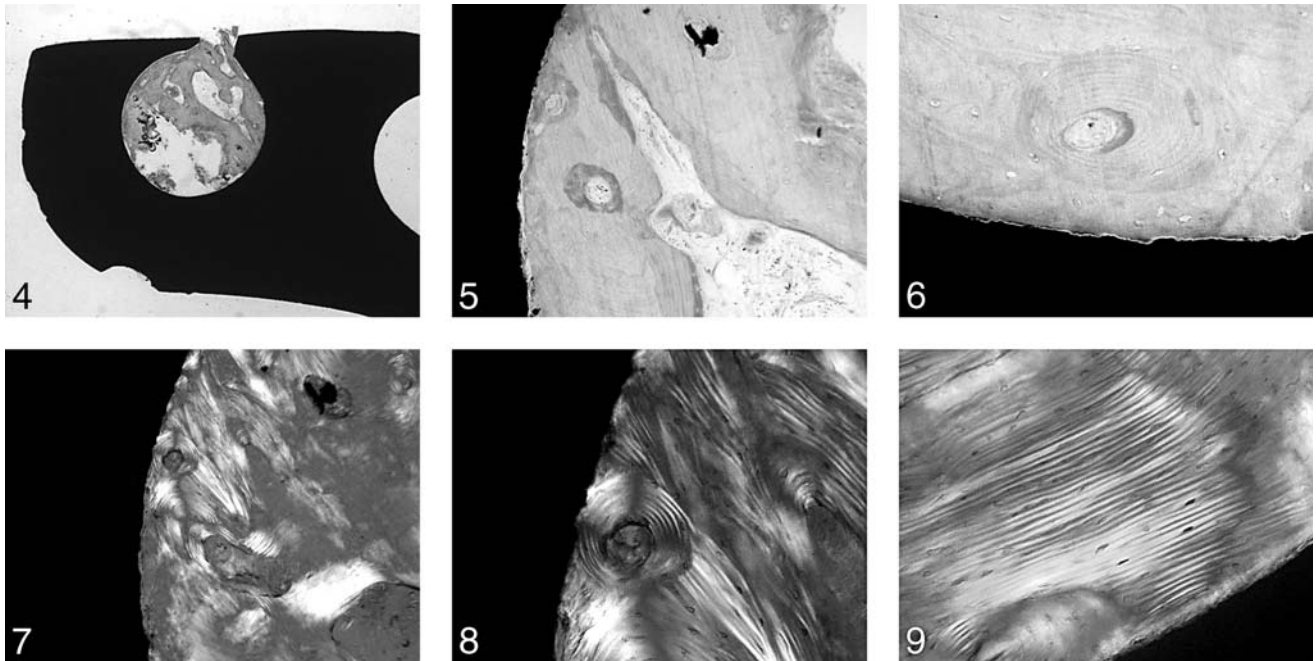
A 58-year-old male nonsmoking patient presented with a blade implant that sustained an abutment fracture 20 years after placement (Figures 1 through 3). This

implant had been immediately loaded and had been in use with no clinical problems before the fracture. The implant was stable, showing no peri-implant radiolucencies or crestal bone resorption. The peri-implant soft tissues appeared to be healthy, and no pain was present upon percussion. The blade was retrieved with a bur. Upon removal, mineralized tissue appeared to be attached to the implant surface. Subsequently, 2 root-form implants were inserted and a new bridge was installed.

METHODS

The processing of specimens was as follows. The implant and the surrounding tissues were stored

immediately in 10% buffered formalin and processed to obtain thin ground sections with the Precise 1 Automated System (Assing, Rome, Italy).²⁷ The specimen was dehydrated in an ascending series of alcohol rinses and embedded in a glycolmethacrylate resin (Technovit 7200 VLC, Kulzer, Wehrheim, Germany). After polymerization the specimen was sectioned longitudinally along the major axis of the implant with a high-precision diamond disc at about 150 μm and ground down to about 30 μm . Three slides were obtained. The slides were stained with basic fuchsin and toluidine blue. A double staining with von Kossa and acid fuchsin was performed to evaluate the degree of bone



FIGURES 4–9. FIGURE 4. No gaps or dense fibrous connective tissue were found at the bone-metal interface (toluidine blue and basic fuchsin, original magnification $\times 12$). FIGURE 5. No apical epithelial migration was found (toluidine blue and basic fuchsin, original magnification $\times 50$). FIGURE 6. Compact, mature bone with well-delineated osteons was present at the implant interface (toluidine blue and basic fuchsin, original magnification $\times 200$). FIGURE 7. Aspect of the peri-implant bone in polarized light. Most of the lamellar bone was arranged concentrically around a Haversian canal (polarized light, original magnification $\times 50$). FIGURE 8. Higher magnification of peri-implant bone in polarized light. Most Haversian systems ran perpendicular to the major axis of the blade (polarized light, original magnification $\times 100$). FIGURE 9. Distribution of the bone lamellae around the blade implant (polarized light, original magnification $\times 200$).

mineralization, and 1 slide, after polishing, was immersed in silver nitrate for 30 minutes and exposed to sunlight. The slides were then washed under tap water, dried, and immersed in basic fuchsin for 5 minutes. They were then washed and mounted.

The histomorphometry of bone-to-implant contact percentage was carried out with a light microscope (Laborlux S, Leitz, Wetzlar, Germany) connected to a high-resolution video camera (3CCD, JVC KY-F55B) and interfaced to a monitor and PC (Intel Pentium III 1200 MMX, Santa Clara, Calif). This optical system was associated with a digitizing pad (Matrix Vision GmbH, Oppenweiler, Germany) and a histomometry software package with image-capturing capabilities (Image-Pro Plus 4.5, Media Cybernetics Inc, Silver Springs, Md;

Immagini & Computer Snc, Milano, Italy).

Compact, mature bone with well-formed osteons was present at the implant interface (Figure 4). Each osteon was constituted by a Haversian system and 10 to 20 bone lamellae (Figures 5 and 6). Many of these osteons were in contact with the implant surface. Most Haversian systems ran perpendicular to the major axis of the blade (Figures 7 and 8). Near the implant, the bone lamellae tended to run parallel to the implant surface (Figure 9). In some fields, bone modeling units were present, and it was possible to observe osteoblasts, osteoclasts, osteoid matrix, and newly formed bone. These bone modeling units constituted about 3% to 4% of all the peri-implant bone area. The newly formed bone was easily differentiated from the

preexisting bone because of its higher staining affinity. A cement line was present at the interface between preexisting and newly formed bone. Bone-to-implant contact was $51\% \pm 6\%$. Bone constituted about $55\% \pm 5\%$ of all the evaluated peri-implant area; the rest was constituted by marrow spaces (about $40\% \pm 5\%$). Osteocyte lacunae were in close contact with the metal surface. No gaps or fibrous tissue were present at the interface. Some of the marrow spaces abutted on the implant surface. In a few fields, some capillaries were located very near the implant surface. No inflammatory infiltrate or epithelial downgrowth was present.

DISCUSSION

Immediately loaded dental implants have shown good clinical

results²⁸⁻³² and offer advantages such as cost of treatment, convenience to patients, and avoidance of functional and psychological problems. Histologic examination provides the best evidence of the type of tissue at the interface with dental implants. This study affirms other reports in the dental literature^{9,33} that blade implants can present a direct bone contact even if they are loaded immediately after insertion; however, they have been reported very often to be surrounded by collagen-rich connective tissue without any bone contact.³⁴⁻³⁹ The most important factor is primary stability of the implant during the healing phase. The precise fit of the implant in the bone socket, which is related to the implant design, is relevant. Implant failure can result from insufficient primary stability or by an inadequately stabilized early loading of the implant.²

Primary stability of root-form implants can be achieved biomechanically by creating an osteotomy that has a diameter less than the diameter of the implant.² If the implant is mobile, healing will lead to an encapsulation by a soft tissue layer^{40,41} and the bone cell differentiation process will be disturbed.⁴² A high amount of phagocytic or macrophage activity can also be created, which will prevent normal bone remodeling and stimulate the formation of granulation tissue.⁴¹ Moreover, the formation of connective tissue around the implants can be caused by an early loading of an adequately stabilized implant in a way similar to a bone fracture where an incomplete immobilization of the fracture fragments produces a pseudoarthrosis.²

Another important factor for the long-term success rate of the dental implants is the way to decrease the impact of deleterious

micromotion at the interface.⁴³ The threshold of critical micromotion appears to be between 50 and 150 μm .⁴³ An effective way to reduce micromovements could be splinting of the implant, in addition to using an implant with a retentive shape (ie, screw shaped). In a rigidly fixed implant system, no significant distortional strains will be produced at the interface, and in such a way no fibrous tissue formation will be stimulated.⁴⁴ Immediately loaded implants that are adequately stabilized have a clinical long-term predictability equivalent to 2-stage implants.⁴⁵ Immediate loading markedly shortens the total rehabilitation time, and patient satisfaction increases because there is no need to wear a conventional denture during the healing period.⁴⁶⁻⁴⁸

The present histologic results show that osseointegration can be obtained in an immediately loaded blade implant and that this osseointegration could be successfully maintained over a long period (20 years). In addition, the peri-implant bone formation did not appear to be disturbed by the stresses and strains at the interface, and mineralized tissues were maintained at the bone-implant interface. Proussaefs and Lozada⁴⁹ reported that blade implants retrieved after 13 and 21 years of function exhibited mature bone in tight contact with the implant and that it was present around most of the implant surface. In the present case, implant splinting may have helped decrease the amount of micromotion during the healing phase and contribute to the long-term success. This was probably obtained by the intimacy of initial fit and the percentage of implant surface in direct contact with bone. These histologic results could be explained by the fact

that functional loading appears to stimulate bone apposition.⁵⁰⁻⁵³ More reports on long-term results of immediately loaded implants will certainly help our understanding of the corresponding bone response.^{54,55}

ACKNOWLEDGMENTS

This work was partially supported by the National Research Council (Rome, Italy); by the Ministry of Education, University, and Research (Rome, Italy); and by the Research Association for Dentistry and Dermatology (Chieti, Italy).

REFERENCES

1. Donath K. Tissue reactions around loaded and unloaded titanium implants. *J Hard Tissue Biol.* 1993;2:37-47.
2. Donath K, Kirsch A. Welche Bedeutung hat die primäre Stabilisation von Implantaten für die Osseäre Integration während der Einheilphase. *Dtsch Z Zahnärztl Implantol.* 1986;2:11-17.
3. Donath K, Laass M, Gunzl HJ. The histopathology of different foreign-body reactions to oral soft tissue and bone tissue. *Virchows Arch A Pathol Anat Histopathol.* 1992;420:131-137.
4. Lum LB, Beirne OR, Curtis DA. Histological evaluation of HA-coated versus uncoated titanium blade implants in delayed and immediately loaded applications. *Int J Oral Maxillofac Implants.* 1991;6:456-462.
5. Brånemark PI, Hansson BO, Adell R, et al. Osseointegrated implants in the treatment of the edentulous jaw. Experience from a 10-year period. *Scand Reconstr Surg.* 1977;11(suppl 16):1-132.
6. Adell R, Lekholm U, Rockler B, Brånemark P-I. A 15-year study of osseointegrated implants in the treatment of the edentulous jaw. *Int J Oral Surg.* 1981;10:387-416.
7. Sagara M, Akagawa Y, Nikai H, Tsuru H. The effects of early occlusal loading on one-stage titanium alloy implants in beagle dogs: a pilot study. *J Prosthet Dent.* 1993;69:281-288.
8. Stefflik DE, Corpe RS, Lake FT, et al. Composite morphology of the bone and associated support-tissue interfaces to osseointegrated dental implants: TEM

- and HVEM analyses. *Int J Oral Maxillofac Implants.* 1997;12:443–453.
9. Linkow LI, Donath K, Lemons JE. Retrieval analyses of a blade implant after 231 months of clinical function. *Implant Dent.* 1992;1:37–43.
 10. Takeshita F, Ayukawa Y, Iyama S, Suetsugu T, Kido MA. A histologic evaluation of retrieved hydroxyapatite-coated blade-form implants using scanning electron, light, and confocal laser scanning microscopies. *J Periodontol.* 1996;67:1034–1040.
 11. Steflik DE, Noel C, McBrayer C, et al. Histologic observations of bone remodeling adjacent to endosteal dental implants. *J Oral Implantol.* 1995;21:96–106.
 12. Steflik DE, Sisk AL, Parr GR, et al. Correlative transmission electron microscopic and scanning electron microscopic observations of the tissue supporting endosteal blade implants. *J Oral Implantol.* 1992;18:110–120.
 13. Fritz ME, Lemons JE, Jeffcoat M, Braswell LD, Reddy M. Evaluation of consecutively placed unloaded root-form and plate-form implants in adult macaca mulatta monkeys. *J Periodontol.* 1994;65:788–796.
 14. Degidi M, Petrone G, Iezzi G, Piattelli A. Histologic evaluation of a human immediately loaded titanium implant with a porous anodized surface. *Clin Implant Dent Relat Res.* 2002;4:110–114.
 15. Rocci A, Martignoni M, Miranda Burgos P, Gottlow J, Sennerby L. Histology of retrieved immediately and early loaded oxidized implants: light microscopic observations after 5 to 9 months of loading in the posterior mandible. *Clin Implant Dent Relat Res.* 2003;5(suppl 1):88–98.
 16. Degidi M, Scarano A, Petrone G, Piattelli A. Histological analysis of clinically retrieved immediately loaded implants: a report of 11 cases. *Clin Implant Dent Relat Res.* 2003;5:89–94.
 17. Degidi M, Scarano A, Iezzi G, Piattelli A. Peri-implant bone in immediately loaded titanium implants: an histologic and histomorphometric evaluation in man. A report of 2 cases. *Clin Implant Dent Relat Res.* 2003;5:170–175.
 18. Trisi P, Lazzara R, Rebaudi A, Rao W, Testori T, Porter SS. Bone-implant contact on machined and dual acid-etched surfaces after 2 months of healing in the human maxilla. *J Periodontol.* 2003;74:945–956.
 19. Lazzara RJ, Testori T, Trisi P, Porter SS, Weinstein RL. A human histologic analysis of osseotite and machined surfaces using implants with 2 opposing surfaces. *Int J Periodontics Restorative Dent.* 1999;19:117–129.
 20. Degidi M, Petrone G, Iezzi G, Piattelli A. Bone contact around acid-etched implants: a histological and histomorphometrical evaluation of two human-retrieved implants. *J Oral Implantol.* 2003;29:13–18.
 21. Rohrer MD, Bulard RA, Patterson MK. Maxillary and mandibular titanium implants 1 year after surgery: histologic examination in a cadaver. *Int J Oral Maxillofac Implants.* 1995;10:466–473.
 22. Gores RJ, Hayes CK, Unni KK. Post mortem examination of six maxillary Core-Vent implants: report of a case. *J Oral Maxillofac Surg.* 1989;47:302–306.
 23. Cappuccilli M, Conte M, Praiss ST. Placement and postmortem retrieval of a 28-year-old implant: a clinical and histologic report. *J Am Dent Assoc.* 2004;135:324–329.
 24. Takeshita F, Ayukawa Y, Suetsugu T, et al. Histologic investigation of hollow implants retrieved for psychological reasons. *Oral Surg Oral Med Oral Pathol Oral Radiol Endod.* 1996;82:379–385.
 25. Proussaefs P, Lozada J, Ojano M. Histologic evaluation of threaded HA-coated root-form implants after 3.5 to 11 years of function: a report of three cases. *Int J Periodontics Restorative Dent.* 2001;21:21–29.
 26. Proussaefs PT, Tatakis DN, Lozada J, Caplanis N, Rohrer MD. Histologic evaluation of hydroxyapatite-coated root-form implants retrieved after 7 years in function: a case report. *Int J Oral Maxillofac Implants.* 2000;15:438–443.
 27. Piattelli A, Scarano A, Quaranta M. High-precision, cost-effective system for producing thin sections of oral tissues containing dental implants. *Biomaterials.* 1997;18:577–579.
 28. Horiuchi K, Uchida H, Yamamoto K, Sugimura M. Immediate loading of Branemark system implants following placement in edentulous patients: a clinical report. *Int J Oral Maxillofac Implants.* 2000;15:824–830.
 29. Jaffin RA, Kumar A, Berman CL. Immediate loading of implants in partially and fully edentulous jaws: a series of 27 case reports. *J Periodontol.* 2000;71:833–838.
 30. Ganeles SJ, Rosenberg MM, Holt RL, Reichman LH. Immediate loading of implants with fixed restorations in the completely edentulous mandible: report of 27 patients from a private practice. *Int J Oral Maxillofac Implants.* 2001;16:418–426.
 31. Degidi M, Piattelli A. Immediate functional and nonfunctional loading of dental implants: a 2 to 60 months follow-up study of 646 titanium implants. *J Periodontol.* 2003;74:225–241.
 32. Proussaefs P, Lozada J. Immediate loading of hydroxyapatite-coated implants in the maxillary premolar area: three-year results of a pilot study. *J Prosthet Dent.* 2004;91:228–233.
 33. Trisi P, Emanuelli M, Quaranta M, Piattelli A. A light microscopy, scanning electron microscopy and laser scanning microscopy analysis of retrieved blade implants after 7 to 20 years of clinical function. *J Periodontol.* 1993;64:374–378.
 34. Muratori G. The importance of fibrous retention in implantology. *J Oral Implantol.* 1987;13:297–315.
 35. Freigel A, Makek M. The significance of fibro-osseous tissue in blade implantology. *J Oral Implantol.* 1987;13:368–386.
 36. Linkow LI, Rinaldi AW. The significance of “fibro-osseous integration” and “osseointegration” in endosseous dental implants. *Int J Oral Implantol.* 1987;4:41–46.
 37. Weiss CM. A comparative analysis of fibro-osteal and osteal integration and other variables that affect long term bone maintenance around dental implants. *J Oral Implantol.* 1987;13:467–486.
 38. Weiss CM. Short- and long-term bone maintenance surrounding fibro-osteal and osteal integrated dental implants. *J Oral Implantol.* 1990;16:12–19.
 39. Dahl SA. Osseointegration vs. fibro-osseous integration. Biomechanical considerations. *J Oral Implantol.* 1987;13:521–526.
 40. Listgarten MA, Lang NP, Schroeder HE, Schroeder A. Periodontal tissues and their counterparts around endosseous implants. *Clin Oral Implants Res.* 1991;2:1–19.
 41. Heimke G. The aspects and modes of fixation of bone replacements. In: Heimke G, ed. *Osseointegrated Implants.* Boca Raton, Fla: CRC Press; 1990:36–45.
 42. Gotfredsen K, Rostrup E, Hjørtting-Hansen E, Stoltze K, Budtz-Jørgensen E. Histological and histomorphological evaluation of tissue reactions adjacent to endosteal implants in monkeys. *Clin Oral Implants Res.* 1991;2:30–37.
 43. Brunski JB, Moccia AF, Pollock SR, Korostoff E, Trachtenberg DI. The influence of functional use of endosseous dental implants on the tissue implant interface: I. Histological aspects. *J Dent Res.* 1979;58:1953–1969.
 44. Akagawa Y, Hashimoto M, Kondo N, Satomi K, Tsuru H. Initial

bone-implant interfaces of submergible and supramergible endosseous single-crystal sapphire implants. *J Prosthet Dent.* 1986;55:96-101.

45. Cannizzaro G, Leone M. Restoration of partially edentulous patients using dental implants with a microstructured surface: a prospective comparison of delayed and immediate full occlusal loading. *Int J Oral Maxillofac Implants.* 2003;18:512-522.

46. Szmukler-Moncler S, Piattelli A, Favero GA, Dubruille JH. Considerations preliminary to the application of early and immediate loading protocols in dental implantology. *Clin Oral Implants Res.* 2000;11:12-25.

47. Gapski R, Wang HL, Mascarenhas P, Lang NP. Critical review of

immediate implant loading. *Clin Oral Implants Res.* 2003;14:515-527.

48. Romanos GE. Present status of immediate loading of oral implants. *J Oral Implantol.* 2004;30:189-197.

49. Proussaefs P, Lozada J. Evaluation of two Vitallium blade-form implants retrieved after 13 and 21 years of function: a clinical report. *J Prosthet Dent.* 2002;87:412-415.

50. Frost HM. Wolff's law and bone's structural adaptations to mechanical usage: an overview for clinicians. *Angle Orthod.* 1994;64:175-188.

51. Frost HM. Bone "mass" and the "mechanostat": a proposal. *Anat Rec.* 1987;219:1-9.

52. Forwood MR, Turner CH. Skeletal adaptations to mechanical usage:

results from tibial loading studies in rats. *Bone.* 1995;17:197s-205s.

53. Cowin SC. Wolff's law of trabecular architecture at remodeling equilibrium. *J Biomech Eng.* 1986;108:83-88.

54. Piattelli A, Scarano A, Paolantonio M. Immediately loaded screw implant removed for fracture after a 15-year loading period: histological and histochemical analysis. *J Oral Implantol.* 1997;23:75-79.

55. Ledermann PD, Schenk RK, Buser D. Long-lasting osseointegration of immediately loaded bar-connected TPS screws after 12 years of function: a histologic case report of a 95-year-old patient. *Int J Periodontics Restorative Dent.* 1998;18:558-563.