

# Case Study: A 30-Year-Old Man With Metformin-Treated Newly Diagnosed Diabetes and Abdominal Pain

Ranjna Garg, MRCP, MD

## PRESENTATION

M.P. is a 30-year-old man who was diagnosed with type 2 diabetes 2 weeks before admission to the hospital. He has a strong family history of type 2 diabetes. He smokes heavily (> 20 cigarettes/day) and admits to some alcohol consumption. His primary care physician had started him on metformin, 500 mg three times daily. There were no complications of diabetes at the time of presentation. Two days before his admission, he developed generalized abdominal discomfort, watery diarrhea, and bilious vomiting. He denied any history suggestive of food poisoning or recent surgery. He was afebrile on admission. His blood pressure was 170/101 mmHg, pulse was 100 bpm, and temperature was 98.9°F. There were no signs suggestive of peritonitis, and his abdomen was soft without guarding. He had deep-seated tenderness in the epigastric region. Initial investigations showed a white blood count of  $25.9 \times 10^9$ , hemoglobin of 15.8 g/dl, and C-reactive protein (CRP) of 200 mg. Renal functions were normal, and liver function tests were normal except for an increased lactic acid dehydrogenase (LDH) level of 848 IU/l.

His metformin was stopped because his gastrointestinal symptoms were attributed to metformin. After stopping metformin, he was able to eat normally and tolerate a regular diet. He received subcutaneous insulin therapy to control his glucose levels. He continued to have some abdominal discomfort, however, and on questioning reported right shoulder pain. Shoulder examination showed no signs of inflammation. There was no restriction of

movement at the right shoulder. A chest X-ray appeared to demonstrate free air beneath the diaphragm.

## QUESTIONS

1. Why is this patient having abdominal discomfort?
2. What investigation would confirm the diagnosis?
3. How should this condition be managed?

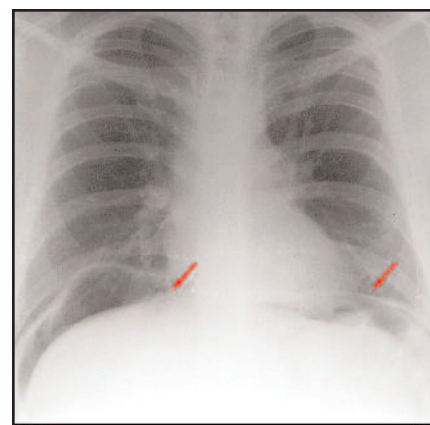
## COMMENTARY

M.P. has pneumoperitoneum (PP). PP is the presence of air within the peritoneal cavity. Most commonly, it is caused by perforated viscus (perforated gastric ulcer, bowel perforation, tumour, or trauma). PP from perforation is associated with peritonitis in most cases.<sup>1</sup> In this setting, signs and symptoms of peritonitis are present, and patients require prompt surgical intervention. On rare occasion, PP may occur without gastrointestinal perforation. Trauma, recent surgery, barotraumas, mechanical ventilation, diagnostic procedures (e.g., endoscopy and colonoscopy) are other causes of spontaneous PP without peritonitis. The cause is often identifiable from the patient's history, but in this case it was not.

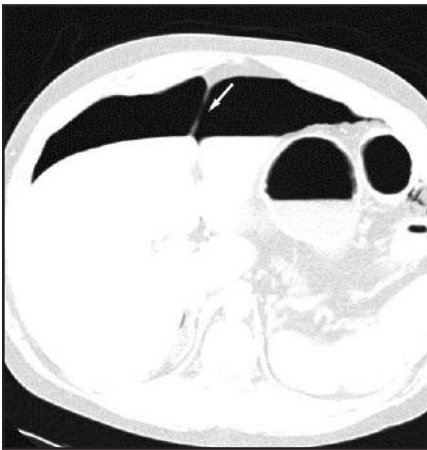
Nonsurgical PP is PP that is not associated with signs of peritonitis. Patients with nonsurgical PP present with vague abdominal symptoms but do not have signs suggestive of acute abdomen. Nonsurgical PP can occur in a number of situations (e.g., silent self-sealing perforation as in patients with diabetes, patients receiving steroids, elderly patients, or critically ill patients). Deliberate air introduction into the peritoneum could

also account for nonsurgical PP, as in the case of peritoneal dialysis, injury to the female genital tract (e.g., from skiing accidents), postendoscopy leakage, or ruptured pneumatosis intestinal cysts.<sup>2</sup>

The pain in the right shoulder noted in this case was likely referred pain. Initial abdominal discomfort and diarrhea was attributed to metformin-induced gastrointestinal side effects. When the symptoms persisted even after metformin was discontinued, search for another cause of abdominal pain revealed the correct diagnosis. This case illustrates the need to continue searching for other causes of gastrointestinal distress when symptoms do not resolve after stopping metformin. M.P.'s ultrasound scan of the abdomen showed the presence of fatty liver consistent with heavy alcohol abuse. It is also noteworthy that metformin is contraindicated in alcohol abuse and in patients at risk for dehydration. This patient, therefore, had multiple reasons to discontinue metformin. The chest X-ray showed the



**Figure 1.** Chest X-ray showing air under diaphragm (arrows).



**Figure 2.** Abdominal CT scan showing presence of air within the peritoneal cavity. Arrow points to the falciparum ligament made prominent by the presence of air on both sides.

presence of air under the diaphragm (Figure 1). An abdominal computed tomography (CT) scan showed the presence of free air within the peritoneal cavity (Figure 2). There was no evidence of viscous perforation on further barium studies.

PP unaccompanied by peritonitis is usually asymptomatic. It can be diagnosed by erect chest X-ray showing the presence of air under the diaphragm. Abdominal CT scanning is the gold standard for confirming the diagnosis of PP. The CT scan is a sensitive tool and demarcates air within the peritoneal

space. Once the diagnosis is confirmed, further investigations should be directed to uncover the cause and source of the air leak. Barium studies may show the perforation unless it is too small or has sealed spontaneously.

M.P. was managed conservatively. He was monitored closely. He tolerated normal meals. His diarrhea stopped. His CRP remained elevated for 2 weeks and then normalized at the time of discharge. Other markers of inflammation also improved in the same time period. Abdominal discomfort improved in 2 weeks. His blood glucose stabilized with insulin therapy. He remained fully mobile and independent and was discharged to home. He has not had any recurrences.

Nonsurgical PP has been described in the literature. Isolated cases from different pathophysiological origins have been reported.<sup>3-5</sup> Nonsurgical PP masquerading as metformin-induced gastrointestinal upset has not been reported previously. In addition to recognizing and diagnosing PP, it is important to be aware of rare nonsurgical causes of PP. Unnecessary surgery can be avoided in such cases.

### Clinical Pearls

- PP does not always require surgical intervention. In hemodynamically stable, minimally symptomatic

patients, unusual causes of PP should be considered to avoid unnecessary surgery.

- Patients with diabetes may have self-limiting small perforations that seal spontaneously. Absence of clinical signs of peritonism and the medical history of the patient can point to the nonsurgical nature of the condition.
- Metformin can cause gastrointestinal upset, but other causes of such symptoms should be diligently searched for if patients remain symptomatic after stopping metformin.

### REFERENCES

- <sup>1</sup>McGlone FB, Vivion CG Jr, Meir L: Spontaneous pneumoperitoneum. *Gastroenterol* 51:393-398, 1966
- <sup>2</sup>Luks FI, Chung MA, Brandt ML, Hertecant J, Roy CC, Blanchard H, Bensoussan AL: Pneumatosis and pneumoperitoneum in chronic idiopathic intestinal pseudoobstruction. *J Pediatr Surg* 26:1384-1386, 1991
- <sup>3</sup>Salky BA, Kaynon A, Bauer JJ, Gelernt IM, Krel I: Ruptured hepatic abscess: a rare cause of spontaneous pneumoperitoneum. *Am J Gastroenterol* 77:880-881, 1982
- <sup>4</sup>Watson DI, Isaacs J, Williams RS: Emphysematous cholecystitis can cause pneumoperitoneum. *Aust N Z J Surg* 64:130-131, 1994
- <sup>5</sup>Ongena K, Simoens C, Opdebeek B, Willems G: Acute pneumoperitoneum without peritonitis: a case report. *Acta Chir Belg* 97:36-38, 1997

*Ranjna Garg, MRCP, MD, is specialist registrar at University Hospital in Birmingham, U.K.*