

# FIXED CERAMOMETALLIC PROSTHESES OVER ANTERIOR AND TRANSZYGOMATIC IMPLANTS BY USING THE SINUS SLOT TECHNIQUE—REPORT OF A CASE

Miguel Peñarrocha-Diago, DDS,  
PhD

A. Boronat, DDS

R. Cervera, DDS

B. Garcia, DDS

## KEY WORDS

Transzygomatic implants  
Sinus slot technique

*Miguel Peñarrocha-Diago, DDS, PhD, is an assistant professor of Oral Surgery and director of the Master of Oral Surgery and Implantology and A. Boronat, DDS, and B. Garcia, DDS, are residents in the Master of Oral Surgery and Implantology program, Valencia University Medical and Dental School, Valencia, Spain.*

*R. Cervera, DDS, is in the private practice of medicine and dentistry in Valencia, Spain.*

*Address correspondence to Dr Peñarrocha-Diago at Unidad Médico-Quirúrgica, Clínica Odontológica (Facultad de Odontología), Gascó Oliag 1, 46021—Valencia, Spain (e-mail: penarrocc@uv.es).*

Atrophy of the upper jaw poses problems for fixed rehabilitation of implants. Of the different management possibilities that have been developed, transzygomatic implant placement is a good option and affords a high success rate. These implants are positioned in zygomatic bone by using 2 possible techniques. We present a 48-year-old woman with severe posterior maxillary atrophy in which the canine and frontozygomatic prominence were used to place 6 anterior and 2 transzygomatic implants by using the sinus slot technique for fixed bridge rehabilitation. The advantages of the sinus slot technique over the sinus window technique are discussed.

## INTRODUCTION

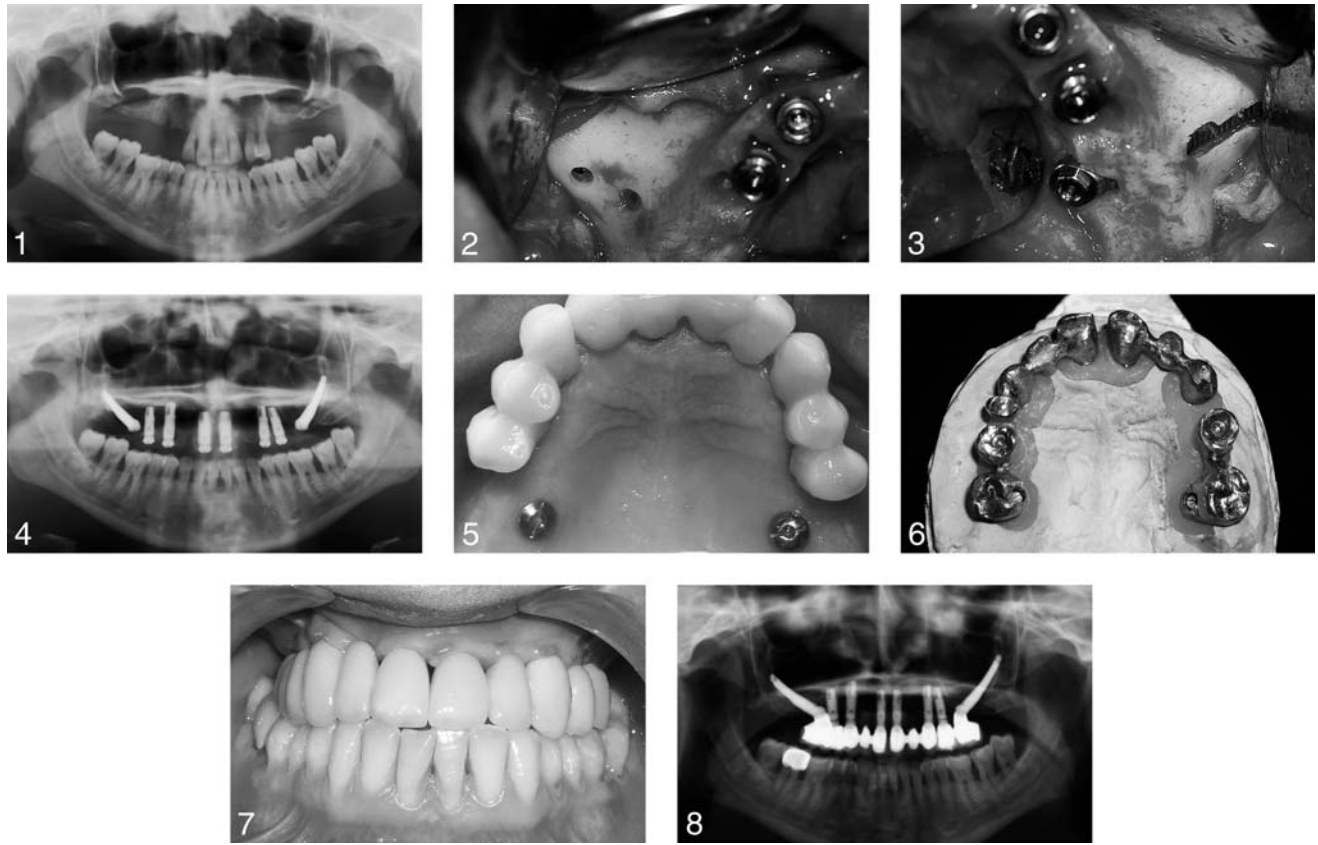
**A** lack of sufficient bone height and poor bone quality requires the definition of new surgical techniques for dental implant placement. Transzygomatic implants offer an alternative to bone grafting before implant placement for fixed rehabilitation of severely atrophic maxillae.<sup>1,2</sup> Transzygomatic implants are inserted after displacement along the lateral sinus wall to ensure anchoring within the zygomatic bone. By utilizing the sinus slot technique, the implants are positioned more vertically with respect to the occlusal plane,

with emergence above the alveolar crest at the level of the first molar.

We present a case of severe posterior maxillary atrophy in which 6 anterior and 2 transzygomatic implants were placed by using the sinus slot technique for fixed bridge rehabilitation.

## CLINICAL CASE

A 48-year-old woman without antecedents of interest consulted for periodontal problems. She showed grade III mobility of 4 maxillary incisors, maxillary left canine, and maxillary left first premolar. Orthopantomography revealed bone atrophy (Figure 1).



FIGURES 1–8. FIGURE 1. Orthopantomography before implant surgery. FIGURE 2. Intraoperative view of transzygomatic implant placement, with osteotomies as orientating marks at the base of the zygomatic process. FIGURE 3. Intraoperative view with the transzygomatic implant in place, showing the sinus slot. FIGURE 4. Panoramic X-ray view after implant placement. FIGURE 5. Occlusal view of the cemented provisional prosthesis. FIGURE 6. Metal testing. The cemented anterior bridges are seen, along with the screwed transzygomatic fixations. FIGURE 7. Frontal image showing the definitive restoration. FIGURE 8. Orthopantomography after placement of the definitive prosthesis.

The treatment plan contemplated removal of the remaining upper teeth and the placement of 6 anterior and 2 transzygomatic implants because of the presence of severe posterior maxillary atrophy.

Surgery was performed under intravenous sedation and local anesthesia (2% articaine with 1:100 000 adrenalin). A supra-crestal incision was made from one tuberosity to the other with 1-cm distal releasing incisions and the raising of a full-thickness flap followed by removal of the anterior teeth.

Six solid threaded Defcon TSA implants with Avantblast surface (Impladent, Senmenat, Barcelona,

Spain) were placed. Four were positioned immediately in maxillary right lateral and central incisors, maxillary left canine, and maxillary left first premolar, whereas 2 were placed in mature bone in maxillary right canine and maxillary left second premolar. The bone defects were filled with autologous bone obtained from drilling of the surgical bed. All implants were conventionally machine positioned under abundant irrigation with sterile saline solution.

Two Branemark transzygomatic implants (Nobel Biocare, Göteborg, Sweden) measuring 40 mm in length were positioned according to the sinus slot tech-

nique. A rounded drill was used to position 2 orientating marks, 1 at the base of the zygomatic process (orienting drill angle) and another at 5 mm above the alveolar crest (at first molar level) (Figure 2). A fissure drill was used to prepare the groove corresponding to the lateral wall of the maxillary sinus to the base of the zygomatic bone, followed by drilling at crest level of the first molar (Figure 3). A zygomatic drill was used to prepare the implant bed, perforating the zygomatic-maxillary junction in the direction of the angle formed by the malar maxillary process and the zygomatic arch. Machine fixation was performed, followed by

the use of a hexagonal driver. Suturing was then performed with 3-0 silk, leaving the implants submerged (Figure 4).

Amoxicillin was provided (500 mg every 8 hours for 7 days) along with ibuprofen (600 mg every 8 hours for 4 days).

The sutures were removed 1 week later. Second-step surgery was performed after 1½ months, and impressions were obtained for placement of a provisional fixed prosthesis over the 6 anterior implants. The provisional prosthesis was cemented 2 weeks later (Figure 5). Implant integration was favorable with no symptoms, and the fixations remained stable. Impressions were obtained for the definitive ceramometallic prosthesis 6 months after surgery, whereby the transzygomatic implants formed a screwed bridge with an anterior implant and the other implants formed 2 cemented bridges (Figure 6).

The findings at the recall visit 12 months after placement of the prosthesis proved favorable. Patient satisfaction during treatment was great, and the esthetic outcome was very positive (Figure 7). The extraoral panoramic X-ray study showed good implant integration and adaptation of the prosthesis (Figure 8).

## DISCUSSION

A number of options have been developed for rehabilitating atrophic jaws, including the sinus lift technique, the placement of bone grafts, or the positioning of transzygomatic implants.<sup>1,3</sup> Although the choice of technique depends on the specific case involved, bone grafting increases the waiting time during treatment.<sup>4,5</sup>

According to Keller et al,<sup>6</sup> percentage of survival in 118 inlay-type grafts was 87%. In turn,

Lekholm et al<sup>7</sup> reported a 25% failure rate with implants placed over onlay-type grafts, whereas Widmark et al<sup>8</sup> reported an 82% success rate in the first year (vs 74% after 3–5 years of control) for implants with simultaneous bone grafting. The success rates afforded by transzygomatic implants are greater. Parel et al<sup>9</sup> conducted a retrospective study of 65 zygomatic implants placed in 27 patients and recorded 100% survival after an average follow-up of 6 years. Bedrossian et al<sup>2</sup> reported the same percentage in 44 implants, whereas Branemark obtained a 97% success rate in 164 implants 10 years after placement. Hirsch et al<sup>10</sup> recorded good results (97.9% success) in 124 implants and after 1 year of follow-up, and reported fewer complications and an impressive degree of patient satisfaction.

In the present clinical case, the transzygomatic implants were placed by using the sinus slot technique described by Stella and Waner.<sup>3</sup> In this procedure, the implant is placed through the sinus along a narrow groove following the contour of the malar bone and anchoring the implant in the zygomatic process. This technique offers a series of advantages over the sinus window approach developed by Branemark in that the flap is more conservative, the sinus window is much smaller, there is less trauma, and the postoperative course is improved. In turn, fixation is more vertical with respect to the occlusal plane, and implant emergence is over the alveolar crest at first molar level. This makes it possible to position a definitive fixed prosthesis with 4 ceramometallic bridges (2 screwed to the transzygomatic implants and 2 cemented onto the anterior implants). The out-

come offers improved esthetic results and function (with less palatal positioning than the sinus window approach) with no need for hybrid rehabilitation.

## REFERENCES

1. Aparicio-Magallón C, Malevez CH. El implante trans-zigomático. *RCOE*. 1999;4:171–184.
2. Bedrossian E, Stumpel L III, Beckely M, Indersano T. The zygomatic implant: preliminary data on treatment of severely resorbed maxillae. A clinical report. *Int J Oral Maxillofac Implants*. 2002; 17:861–865.
3. Stella J, Warner M. Sinus slot technique for simplification and improved orientation of zygomatic dental implants: a technical note. *Int J Oral Maxillofac Implants*. 2000;15:889–893.
4. Ferrara E, Stella J. Restoration of the edentulous maxilla: the case for the zygomatic implants. *J Oral Maxillofac Surg*. 2004;62:1418–1422.
5. Nakai H, Okazaki Y, Ueda M. Clinical application of zygomatic implants for rehabilitation of the severely resorbed maxilla: a clinical report. *Int J Oral Maxillofac Implants*. 2003;18:566–570.
6. Keller EE, Tolman DE, Eckert SE. Maxillary antral-nasal inlay autogenous bone graft reconstruction of compromised maxilla: a 12-year retrospective study. *Int J Oral Maxillofac Implants*. 1999; 14:707–721.
7. Lekholm U, Wannfors K, Isaksson S, Adielsson B. Oral implants in combination with bone grafts. A 3-year retrospective multicenter study using the Bränemark implant system. *Int J Oral Maxillofac Surg*. 1999;28:181–187.
8. Widmark G, Andersson B, Carlsson GE, Lindvall AM, Ivanoff CJ. Rehabilitation of patients with severely resorbed maxillae by means of implants with or without bone grafts: a 3- to 5-year follow-up clinical report. *Int J Oral Maxillofac Implants*. 2001;16:73–79.
9. Parel SM, Bränemark PI, Ohnell LO, Svensson B. Remote implant anchorage for the rehabilitation of maxillary defects. *J Prosthet Dent*. 2001;86:377–381.
10. Hirsch JM, Ohnell LO, Henry PJ, et al. A clinical evaluation of the zygoma fixture: one year of follow-up at 16 clinics. *J Oral Maxillofac Surg*. 2004; 62:22–29.