

MINIMALLY INVASIVE ANTRAL MEMBRANE BALLOON ELEVATION FOLLOWED BY MAXILLARY BONE AUGMENTATION AND IMPLANT FIXATION

Efraim Kfir, DMD
Vered Kfir, DMD
Eitan Mijiritsky, DMD
Ronen Rafaeloff, DMD
Edo Kaluski, MD

KEY WORDS

Antral membrane
Posterior maxillary segment
Bone augmentation
Dental implants

Efraim Kfir, DMD, is from the Dental Clinic at Hanesilim Street 40 in Petah-Tikvah, Israel.

Vered Kfir, DMD, is from the Dental Clinic at Kupat Holim Clalit (Remez) in Rehovot, Israel.

Eitan Mijiritsky, DMD, is from the Oral Implant Center at The Hebrew University-Hadassah School of Dental Medicine in Jerusalem, Israel.

Ronen Rafaeloff, DMD, is from the Dental Clinic at Shprintzak Street 3 in Tel Aviv, Israel.

Edo Kaluski, MD, is from the Department Cardiology at Assaf Harofeh Medical Center in Zrifin and Sackler School of Medicine at the University of Tel Aviv in Israel. Address correspondence to Dr Kaluski, director of the Coronary Care Unit, Assaf Harofeh Cardiology Institute, Zrifin, DN Beer Yacov, 70300, Israel.

The posterior maxillary segment frequently suffers from insufficient bone mass to support dental implants. Current bone augmentation methods, including the lateral maxillary approach (ie, hinge osteotomy) and sinus elevation by osteotome, have many shortcomings. The objective of our study was to assess the safety and efficacy of minimally invasive antral membrane balloon elevation (MIAMBE) followed by bone augmentation and implant fixation (executed during the same procedure). Alveolar crest exposure and implant osteotomy were followed by sequential balloon inflations yielding >10 mm MIAMBE. A mix of autologous fibrin and bone particles with bone speckles was injected beneath the antral membrane. Implants were fixated into the osteotomies, and primary closure was performed during the same sitting. A total of 24 patients were enrolled. Successful conclusion of this procedure was accomplished in 91.6% of the initial 12 patients and 100% in the second dozen cases without significant complications. Patient discomfort was minimal. Long-term follow up revealed satisfactory bone formation, resulting in adequate implant stability. We conclude that the protocol of MIAMBE results in an excellent success rate, low complication rate, minimal discomfort, and long-term safety and durability. Because it requires only basic equipment and a short learning curve, this clinical approach should be widely employed.

INTRODUCTION

Candidates for dental implants of the posterior maxillary segment frequently suffer from insufficient bone mass¹ to support the implants. To perform

bone augmentation in the inferior aspect of the maxillary sinus, dentists and orofacial surgeons traditionally use 2 approaches: the lateral maxillary window approach (ie, hinge osteotomy) and a limited sinus elevation by osteotome.² The latter approach

TABLE 1
Limitations of lateral maxillary approach (hinge osteotomy)

- 1) Relative contraindications
 - a) Anatomic: sinus convolutions, septum, or narrow sinus
 - b) Previous sinus surgery (Caldwell Luke)
- 2) Complications
 - a) Sinus membrane perforation (10%–35%)
 - b) Obstruction of antronasal foramen
 - c) Bleeding
 - d) Infection
 - e) Infraorbital nerve laceration
- 3) Periprocedural discomfort
 - a) Swelling, discoloration, disability, and pain
 - b) Hematomas and nosebleed
- 4) Timing: delayed (7–8 month) implants fixation
- 5) Skills
 - a) Requires surgical expertise
 - b) Demanding learning curve
 - c) Time consuming and resource consuming

yields an average bone height of $3 \pm 0.8 \text{ mm}^3$; hence, it cannot be applied if the initial bone height is $<5 \text{ mm}$. Moreover, this procedure can be complicated by membrane perforation and tear.⁴ These adversities can be minimized with expert technique and dedicated instrumentation.⁵ Although the lateral maxillary window offers an average implant survival of 91.8% (ranging from 61.7%–100%),⁶ this method suffers from many shortcomings (Table 1). We describe an original, minimally invasive technique for antral

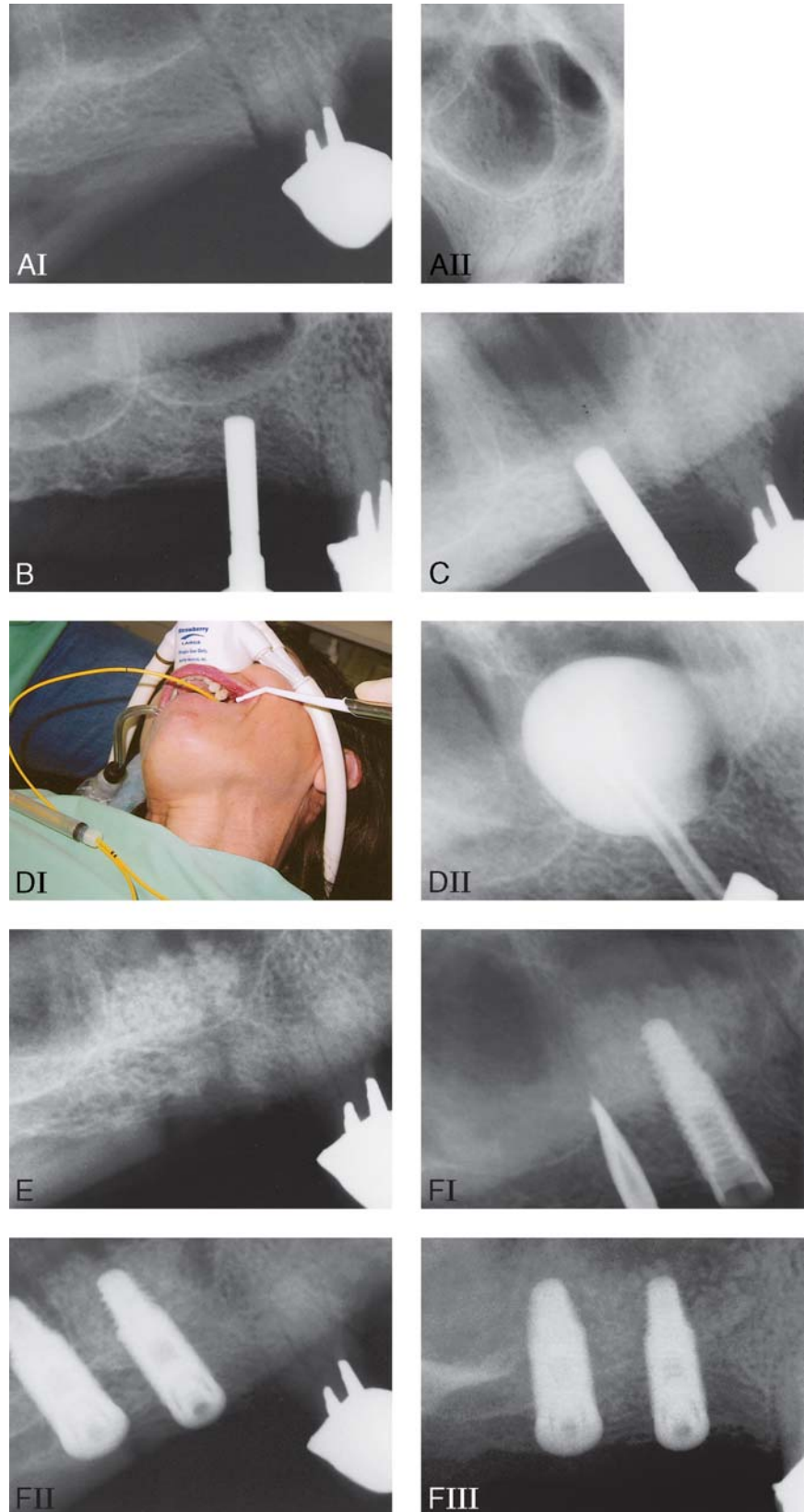


FIGURE 1. Case 1. (AI) Bone thickness under sinus membrane and septum. (AII) Maxillary sinus. (B) Pilot drill. (C) Expanding osteotomy (2.8 mm) and breaking the sinus floor. (DI) Balloon setup. (DII) Antral membrane elevation by balloon. (E) Following bone transplantation. (FI) Implant fixation and septal drilling. (FII) Second implant fixation. (FIII) Postprocedural follow up (3 weeks).

TABLE 2
Results of 24 patients using MIAMBE*

	Patients Nos. 1-12	Patients Nos. 13-24
Procedural success (%)	91.6	100
Major complications (%)	0	0
Initial bone height (mm, mean ± SD)	3.7 ± 2.1	3.5 ± 2.3
Six months' bone-height increment (range)	10-17	10-18
Number of implants (mean ± SD)	2.08 ± 0.51	1.91 ± 0.51
Implant diameter, range (mm)	3.75-5	3.75-5
Implant length, range (mm)	13-17.1	13-17.1
Minor complications	1 rupture balloon and membrane	1 minor nosebleed
Rejected implants at 6 months	1	0
Implant exposure and rehabilitation at 6-8 months (%)	100	100
Follow up (mo; mean ± SD)	23 ± 6	12 ± 4

*MIAMBE indicates minimally invasive antral membrane balloon elevation; SD, standard deviation.

membrane balloon elevation executed via the osteotomy site. Bone grafting is also performed via the osteotomy site, and implant fixation is done at the same sitting.

MATERIALS AND METHODS

All enrolled patients had edentulous posterior maxillary segment, required implants, and were willing to sign an informed consent. Designated equipment and materials were as follows:

- 7F "Right Heart Catheter" (Swan-Ganz catheter, Edwards Lifesciences, Irvine, Calif)
- Dedicated bone transplant injector
- Inflation syringe (BASIX 25, Merit Medical, Galway, Ireland) filled with diluted contrast material (Ultravist 370, Schering; Schering Randjespark, Germany)
- Dedicated 8F screw-in sleeve with balloon locker
- Autologous Fibrin (obtained by centrifugation of 40 mL of patients' blood divided into 4 test tubes and spun for 10 minutes at 2700 RPM by Fibe-tec centrifuge)

- Bi Ostetic synthetic bone graft (Berkeley Advanced Biomaterials Inc, San Leandro, Calif)
- Autologous bone particles collected by drilling

Study protocol

Each patient received an explanation regarding the procedure and signed a consent form. Preprocedural computerized tomography

(CT) was optional, and panoramic views were performed to assess mucosa thickness and pathology, bone height and thickness, sinus structure, and major blood vessels. Periapical X rays were performed before the procedure (Figure 1AI through 1AII). Preprocedural Augmentin 375/125 mg twice daily was initiated 24 hours prior to the procedure. Nitric oxide was administered if the patient consented. Local anesthesia (infiltration of posterior superior alveolar nerve and greater palatine nerve) was executed by Ubistesin Forte (Articain 4% [3M ESPE DENTAL, Seefeld, Germany]). A horizontal, full-thickness flap with palatal bias (to preserve keratinized tissue) was performed, followed by a minimal (2-3 mm) vertical mesial incision to expose the alveolar crest. Implant osteotomy employing a pilot drill of 2 mm reached 1 mm to 2 mm short of the sinus floor (Figure 1B). The osteotomy was enlarged by osteotome of 2.8 mm to 3.15 mm (Figure 1C), and the sinus floor was gently broken.

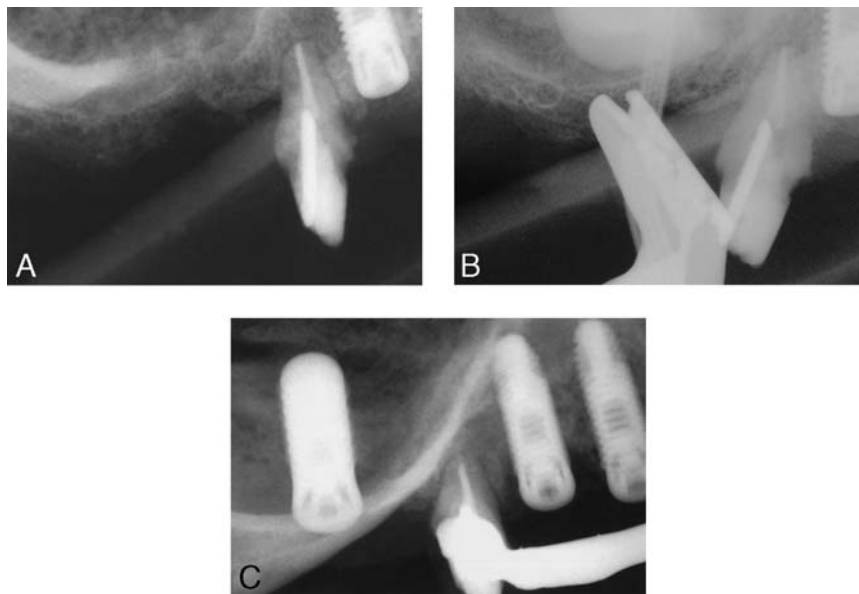


FIGURE 2. Case 2. (A) Before augmentation. (B) Antral membrane balloon elevation. (C) Postaugmentation (6 months).

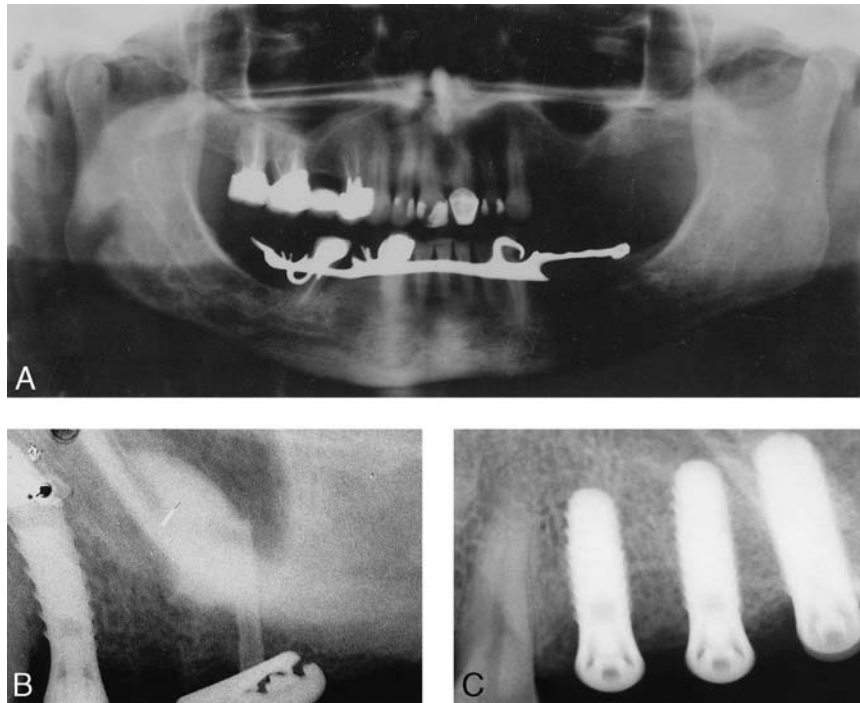


FIGURE 3. Case 3. (A) Preprocedural panoramic X ray. (B) Antral membrane balloon elevation. (C) Follow up (6 months).

After examining the integrity of the sinus membrane (by Valsalva maneuver and direct visualization), Fisiograft gel (GHIMAS, Casalecchio di Reno, Italy) was injected to enhance lubrication.

An 8F sleeve (2.6-mm internal diameter) was screwed in up to 0.5 mm superior to the sinus floor. A dedicated inflatable balloon (7F external diameter, inflated volume ≤ 2.5 mL) was advanced 1 mm to 2 mm beyond the tip of the metal sleeve and anchored by a locking mechanism at the proximal part of the sleeve (Figure 1DI). The balloon was slowly inflated with the dedicated inflator syringe using diluted contrast media (50% Ultravist 370 diluted with normal saline), with inflating pressure not exceeding 2 atmospheres. The balloon inflation and sinus-floor elevation were evaluated by sequential periapical X rays (Figure 1DII). Once the desired elevation (usu-

ally >10 mm) was obtained, the balloon was deflated and removed with the sleeve. A second test of membrane integrity was done as previously mentioned. A mix of autologous fibrin (obtained from each patient's centrifuged blood) and bone particles (collected by suction) and Bio-stetic bone speckles was injected under the elevated antral membrane (Figure 1E). After bone transplantation, implants of 3.75- to 5-mm diameter were screwed in via osteotomies (Figure 1FI through 1FIII) and primary closure was performed. Patients were discharged with a single, 600-mg dose of Ibuprofen for treatment of pain and Augmentin 850/125 mg BID for 7 days. Suture removal was executed within 7 days. At 6 months' postprocedure, follow up CT (optional), panoramic, and periapical X rays were performed, and prosthetic reha-

bilitation was executed 3 weeks after implant exposure.

Study end points

This registry's feasibility and efficacy primary end point was successful conclusion of the procedure. Primary safety end point was major complications (including severe bleeding, infection, nerve injury, and prolonged [>7 days] disability). We also monitored procedure time, long-term implant failure, and bone height and quality at 6 months.

RESULTS

Between January 2002 and June 2004, we enrolled 24 patients with a mean age of 42 ± 9 years (Table 2). Half of the patients were female. Baseline bone height was 3.7 ± 1.4 mm in the first 12 patients and 3.5 ± 1.3 mm in the second 12 patients. All 24 consecutive patients who were referred to us for posterior maxillary bone augmentation preferred the minimally invasive antral membrane balloon elevation (MI-AMBE) over the conventional procedure of hinge osteotomy. Procedural success was 91.6% for the first 12 patients and 100% for the second 12 patients. One procedure was aborted due to balloon and membrane rupture, but was successfully performed 3 weeks later. Recorded minor events included one patient who had a mild, self-limiting, periprocedural nosebleed. Procedure time in the first 12 patients was close to 2 hours. In the second 12 patients, the average procedure time dropped to <1 hour. Patients were extremely pleased and needed very little medical attention and analgesic medication, and no patient required

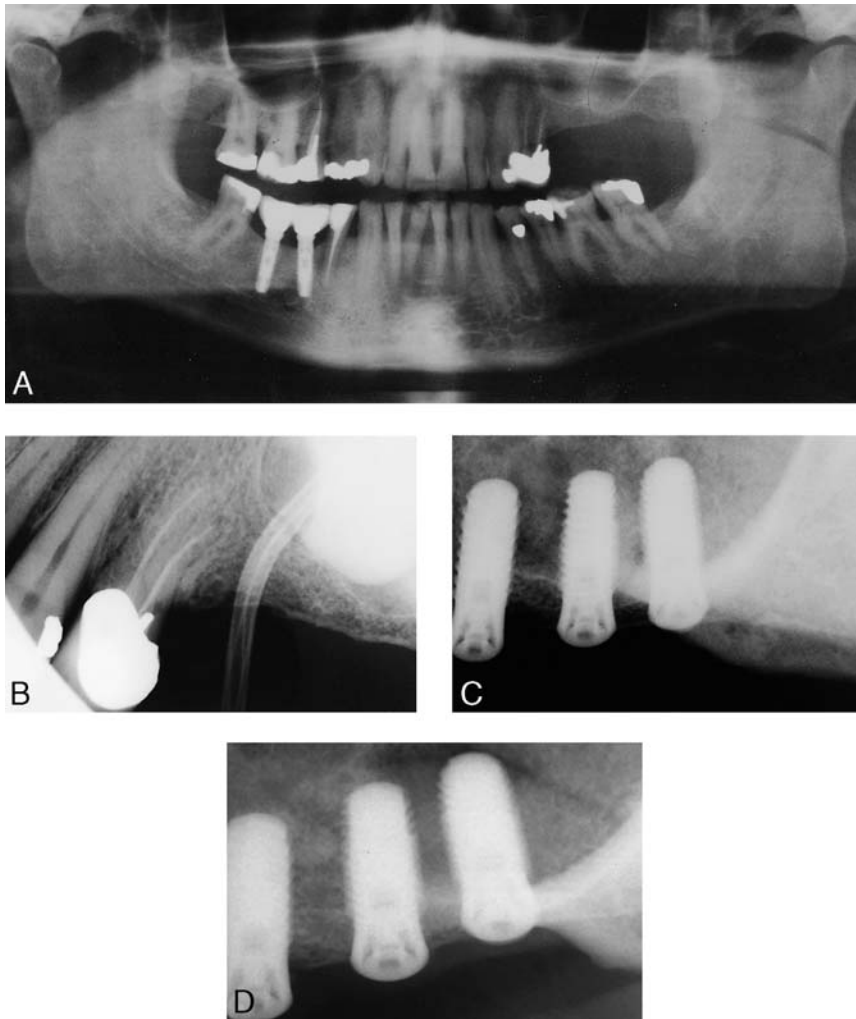


FIGURE 4. Case 4. (A) Preprocedural panoramic view. (B) Minimally invasive antral membrane balloon elevation. (C) Implant fixation. (D) Follow up (6 months).

medication for swelling alleviation. There was only one implant failure (2 weeks after the procedure), with a follow up >6 months. All patients were happy with the procedure and would recommend it. Physicians who performed or witnessed the procedure and its results think that it should be the method of choice for posterior maxillary bone augmentation. We submitted 7 demonstrative cases. The first case emphasizes the technical aspects of the procedure step by step, while Cases 2 through 7

(Figures 2 through 7) demonstrate the MIAMBE and long-term follow up.

DISCUSSION

This study reports a minimally invasive, single-sitting procedure of maxillary bone augmentation. The authors believe that all procedure goals, including procedural success approaching 100% after a short learning curve in a non-selective cohort, were met. There were no major complications, and the procedure yielded satisfactory bone augmentation results

and good implant durability as observed by our long-term follow up. For physicians, this procedure is highly successful, has a short learning curve, and is not time or resource consuming. For patients, this procedure eliminates the complications, discomfort, disfiguring, and disability associated with traditional hinge osteotomy and shortens the time to implant exposure and functionality by more than 6 months.

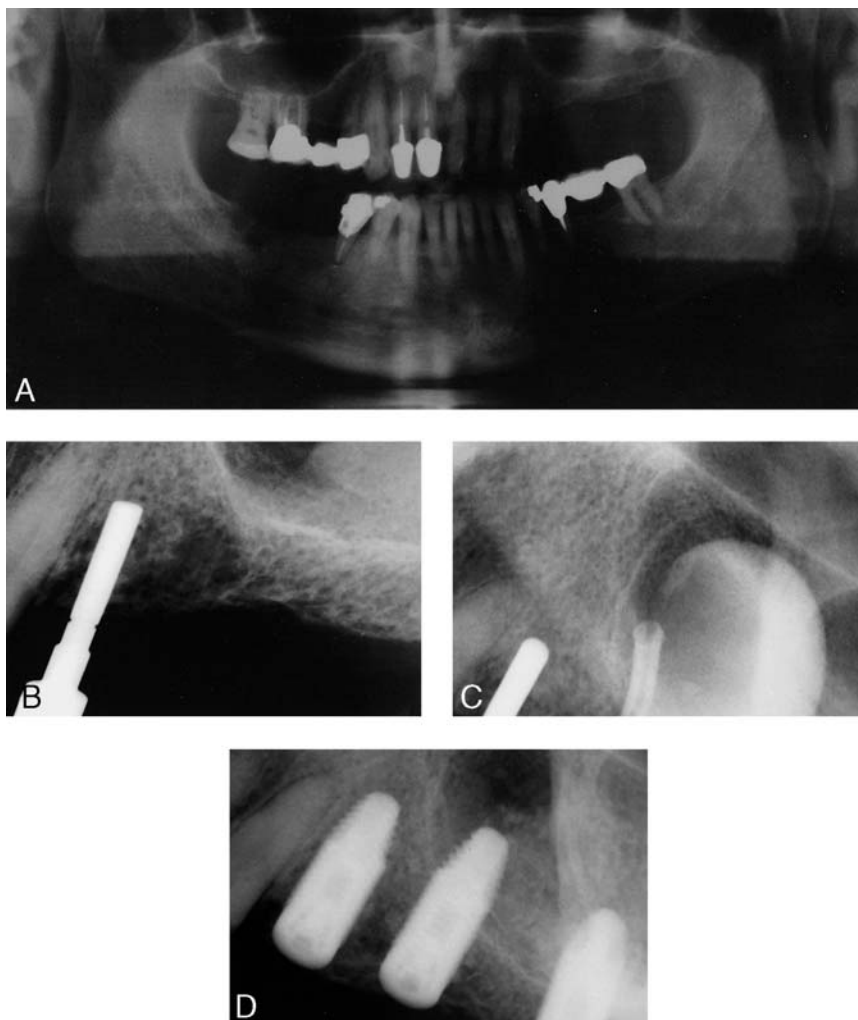
Soltan and Smiler⁷ recently described antral membrane balloon elevation employed via a lateral bone fenestration, but their approach is not minimally invasive. The authors state (but do not substantiate it by any data) that this modification of hinge osteotomy is "highly successful, and predictable, and is likely to reduce pain, bleeding, infection, and other morbid symptoms often associated with sinus lift procedures."

We believe that by teaching MIAMBE and using more elaborate and dedicated equipment, we will increase dentists' and patients' interest in implants of the problematic segment of the posterior maxillary bone, thus rendering lateral (hinge) osteotomy obsolete.

Issues that remain unresolved include the optimal ways to induce bone formation and the best ways to assess bone augmentation in vivo. Lundgren and colleagues⁸ reported that sinus membrane elevation, per se, in an unknown mechanism is a powerful stimulator for bone formation and regeneration. Positive bone formation was reported with a mixture of 80% bovine hydroxyapatite, 20% autogenous bone, and fibrin glue (when assessed by light microscopy and morphometry measurements of biopsy specimens

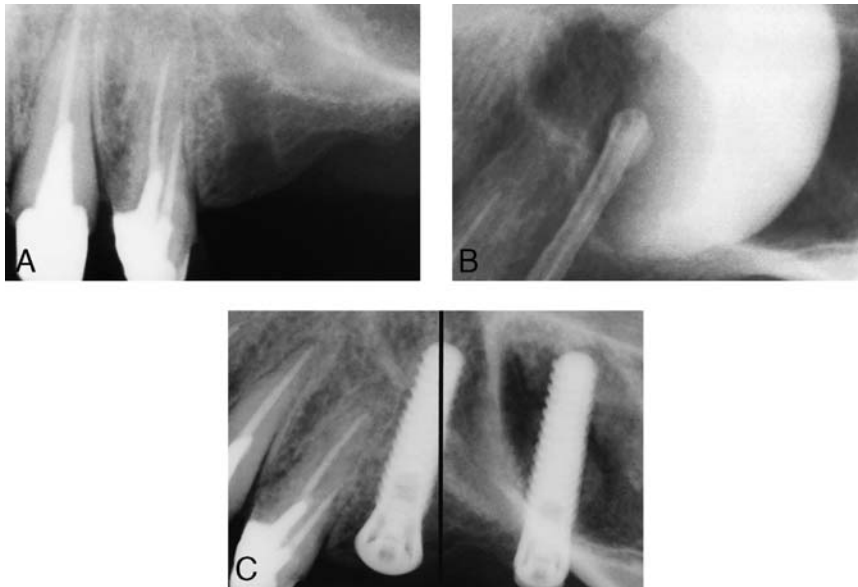

FIGURE 5. Case 5. (A) Preprocedural X ray. (B) Minimally invasive antral membrane balloon elevation. (C) Implant fixation after bone transplantation.



obtained 6 and 36 months after maxillary sinus floor augmentation).⁹ Others reported similar histologic results (bone formation) in biopsy specimens obtained from maxillary augmentation using autologous bone with either hydroxyapatite or demineralized, freeze-dried bone allograft (DFDBA).¹⁰ Another report demonstrated favorable clinical and histologic findings 12 months postimplant exposure following augmentation, which employed platelet-rich, plasma-mixed DFDBA.¹¹ Although initially sparking some enthusiasm,¹² it is not clear whether the histologic benefit reported¹³ with autologous bone, alone or in combination with other particulate grafting materials, offers any clinically meaningful advantage in bone formation and implant durability.⁶ Based on our clinical follow up, the authors are convinced that, along with primary stabilization obtained by large-diameter implants (3.75 mm–5 mm), sufficient bone augmentation can be enhanced by micro-invasive introduction of bone-enhancing elements beneath the antral membrane. We plan to substantiate this impression with 6 months and 3 years of CT bone-densitometry data.

CONCLUSIONS

This is the first publication of MIAMBE, an original method to

←

FIGURE 6. Case 6. (A) Preprocedural panoramic view. (B) Before minimally invasive antral membrane balloon elevation (MIAMBE) periapical X ray. (C) MIAMBE. (D) Implant fixation after bone transplantation.

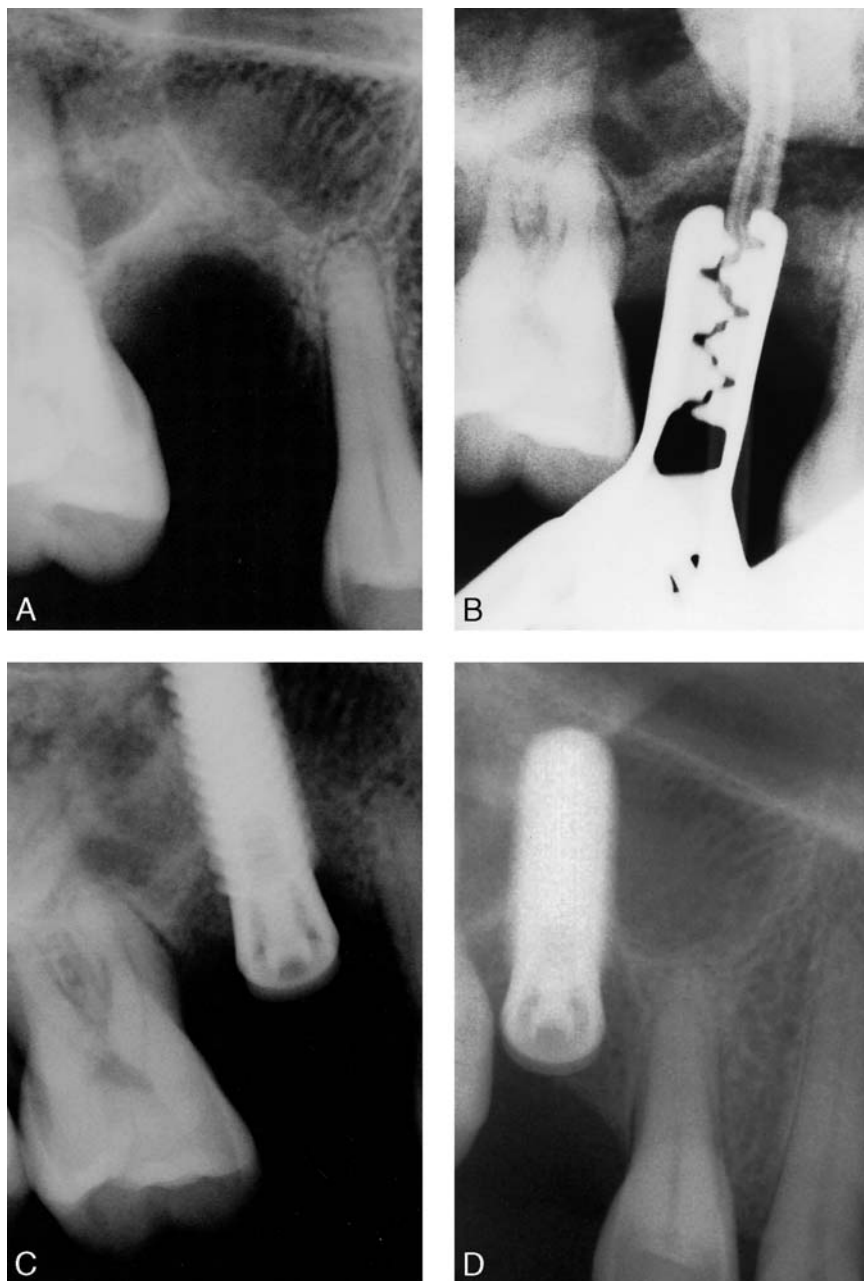


FIGURE 7. Case 7. (A) Preprocedural periapical X ray. (B) Minimally invasive antral membrane balloon elevation. (C) Implant fixation after bone transplantation. (D) Follow up (6 months).

execute dental implantation in an edentulous posterior maxillary segment with insufficient bone height or quality. The method requires a very abbreviated learning curve, carries excellent procedural success and low complication rates, and yields very

satisfactory long-term results. The procedure is truly minimally invasive and is associated with very little discomfort. The authors are convinced that, along with improving dedicated equipment for the procedure, MIAMBE should

be taught for the benefit of our patients.

NOTE

The authors of this manuscript have no financial association that might pose a conflict of interest in connection with the submitted manuscript or the products and equipment employed in this manuscript.

REFERENCES

1. Garg AK. Augmentation grafting of the maxillary sinus for placement of dental implants: anatomy, physiology, and procedures. *Implant Dent.* 1999;8:36-46.
2. Summers RB. Sinus floor elevation with osteotomes. *J Esthet Dent.* 1998;10:164-171.
3. Nkenke E, Schlegel A, Schultze-Mosgau S, Neukam FW, Wiltfang J. The endoscopically controlled osteotome sinus floor elevation: a preliminary prospective study. *Int J Oral Maxillofac Implants.* 2002;17:557-566.
4. Berengo M, Sivoletta S, Majzoub Z, Cordioli G. Endoscopic evaluation of the bone-added osteotome sinus floor elevation procedure. *Int J Oral Maxillofac Surg.* 2004;33:189-194.
5. Toffler M. Staged sinus augmentation using a crestal core elevation procedure and modified osteotomes to minimize membrane perforation. *Pract Proced Aesthet Dent.* 2002;14:767-774.
6. Wallace SS, Froum SJ. Effect of maxillary sinus augmentation on the survival of endosseous dental implants: a systematic review. *Ann Periodontol.* 2003;8:328-343.
7. Soltan M, Smiler D. Antral membrane balloon elevation. *J Oral Implantol.* 2005;31:85-90.
8. Lundgren S, Andersson S, Gualini F, Sennerby L. Bone reformation with sinus membrane elevation: a new surgical technique for maxillary sinus floor augmentation. *Clin Implant Dent Relat Res.* 2004;6:165-173.
9. Hallman M, Lundgren S, Sennerby L. Histologic analysis of clinical biopsies taken 6 months and 3 years after maxillary sinus floor augmentation with 80% bovine hydroxyapatite and 20% autoge-

nous bone mixed with fibrin glue. *Clin Implant Dent Relat Res*. 2001;3:87–96.

10. Boeck-Neto RJ, Gabrielli M, Lia R, Marcantonio E, Shibli JA, Marcantonio E Jr. Histomorphometrical analysis of bone formed after maxillary sinus floor augmentation by grafting with a combination of autogenous bone and demineralized freeze-dried bone allograft or hydroxyapatite. *J Periodontol*. 2002;73:266–270.

11. Kassolis JD, Rosen PS, Reynolds MA. Alveolar ridge and sinus augmentation utilizing platelet-rich plasma in combination with freeze-dried bone allograft: case series. *J Periodontol*. 2000;71:1654–1656.

12. Raghoebar GM, Brouwer TJ, Reintsema H, Van Oort RP. Augmentation of the maxillary sinus floor with autogenous bone for the placement of endosseous implants: a preliminary re-

port. *J Oral Maxillofac Surg*. 1993;51:1198–1203.

13. Lorenzetti M, Mozzati M, Campanino PP, Valente G. Bone augmentation of the inferior floor of the maxillary sinus with autogenous bone or composite bone grafts: a histologic-histomorphometric preliminary report. *Int J Oral Maxillofac Implants*. 1998;13:69–76.