

PRESERVATION OF THE GINGIVAL ARCHITECTURE WITH THE SCALLOPED IMPLANT DESIGN: A CLINICAL REPORT

Amir H. Khatami, DDS
Mohammed Al-Ajmi, DDS, MS
Alejandro Kleinman, DDS

KEY WORDS

Scallop-design implant
Crestal bone profile
Gingival architecture
Immediate provisional
restoration
Flapless surgery

Amir H. Khatami, DDS, is an assistant professor at the College of Dentistry, The Ohio State University. Correspondence should be addressed to Dr Khatami at College of Dentistry, The Ohio State University, 305 West 12th Avenue, #191, PO Box 182357, Columbus, OH 43218-2357 (e-mail: akhatami@msn.com).

Mohammed Al-Ajmi, DDS, MS, is with the Saudi Aramco Dental Department, Dhahran, Saudi Arabia.

Alejandro Kleinman, DDS, is an associate professor of Advanced Education in Implant Dentistry, Loma Linda University, Loma Linda, Calif.

Replacing the missing maxillary anterior teeth with dental implants and maintaining the soft tissue structure and alveolar profile is an esthetic challenge for the restorative dentist. This clinical report describes the immediate provisional placement and prosthetic rehabilitation of 2 missing maxillary central incisors with scalloped dental implants.

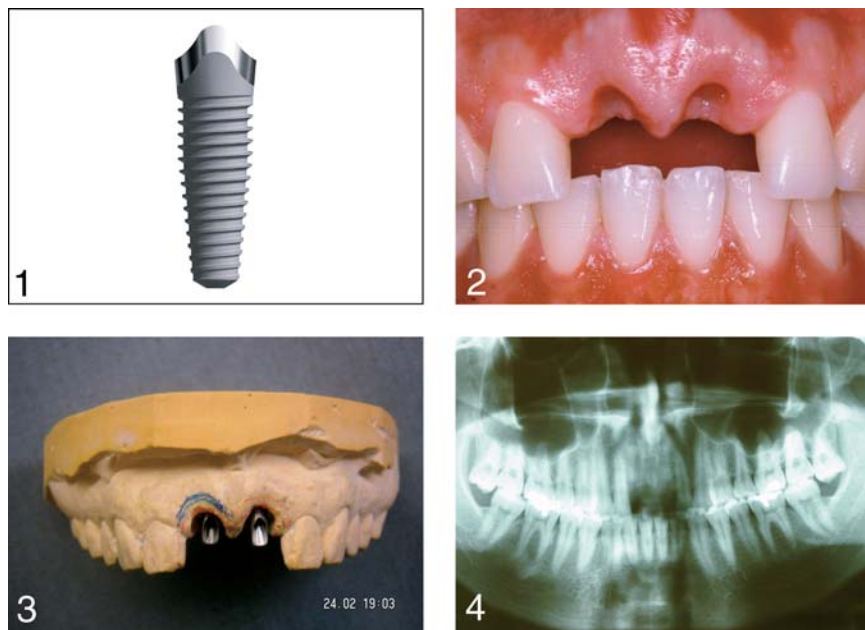
INTRODUCTION

The original Brånemark dental implant design had a titanium machined surface and flat top and was mainly designed for edentulous patients. Over the past few years, major changes have been made to the thread design, implant surfaces, and implant size. With the introduction of rough implant surfaces, the idea of having more stable implants encouraged more clinicians to utilize dental implants to replace the missing anterior teeth in partially edentulous patients and immediately restore them with provisional restorations.

The bone morphology in a partially edentulous individual is significantly different from a completely edentulous individual. The osseous crest rises interproximally and is lower on the buccal and lingual surfaces. The gingiva around the tooth follows this un-

derlying bony crest very closely. Becker et al¹ have classified the alveolar bone anatomic profiles into flat, scalloped, and pronounced scallop. The degree of scallop varies among the 3 types, but after extraction this profile changes, crestal bone resorbs, and soft tissue follows this contour.

In replacing missing anterior teeth, maintaining the gingival contour and interproximal papilla becomes extremely critical to achieve good esthetics. Various augmentation techniques have been advocated as corrective procedures, but these techniques are time consuming and not always predictable. Therefore, the fundamental concept of site development for anterior single-implant esthetics in the event of a failing tooth is to preserve the existing gingival and osseous tissue.²⁻⁴ It has also been suggested that a biologic width exists around unloaded and loaded nonsubmerged rough surface titanium implants, and this could be a physiologic and stable dimension.⁵



Figures 1–4. FIGURE 1. Scalloped dental implant. FIGURE 2. Preoperative photograph of 2 missing maxillary central incisors. FIGURE 3. Diagnostic cast with implant replicas and abutments. FIGURE 4. Preoperative panoramic radiograph.

Bone remodeling to establish this dimension may be dependent on the location of implant-abutment interface and the status of implant surface (rough vs smooth).⁶ Traditionally, the access for implant placement has been by a flap surgery and burying the implants for 4 to 6 months. The primary purpose of burying the implants was to minimize the micromotion and eliminate the bacterial contamination. More recently a minimally invasive flapless approach was suggested.⁷ Some of the advantages with this approach are shorter surgical time, minimal bleeding, less inflammation, minimal changes in crestal bone levels, and less postoperative discomfort for the patient.^{7–9}

In a 10-year retrospective study using the flapless approach, Campelo and Camara⁷ reported implant survival rates from 74.1% for the first postoperative year to 100% for the 10th postoperative year. In a retrospec-

tive 3-year analysis of implants placed by flapless surgery, Rocci et al⁸ showed a 91% survival rate with an average of 1.0 mm bone resorption during the first postoperative year, 0.4 mm for the second postoperative year, and 0.1 mm for the third postoperative year. A more recent prospective multicenter study⁹ of 79 implants placed by flapless surgery in 57 patients reported a 98.7% cumulative success rate at 2 years. The average time for placing the implants was 28 minutes, and crestal bone loss was 0.07 mm.

There was no implant design to consider the alveolar profile in replacing the missing anterior teeth until the NobelPerfect (Nobel Biocare, Yorba Linda, Calif) was specifically developed to replace missing anterior teeth with scalloped ridge (Figure 1). The purpose of the scalloped design and rough implant surface is to keep or create interdental bony peaks that support the soft tissue,

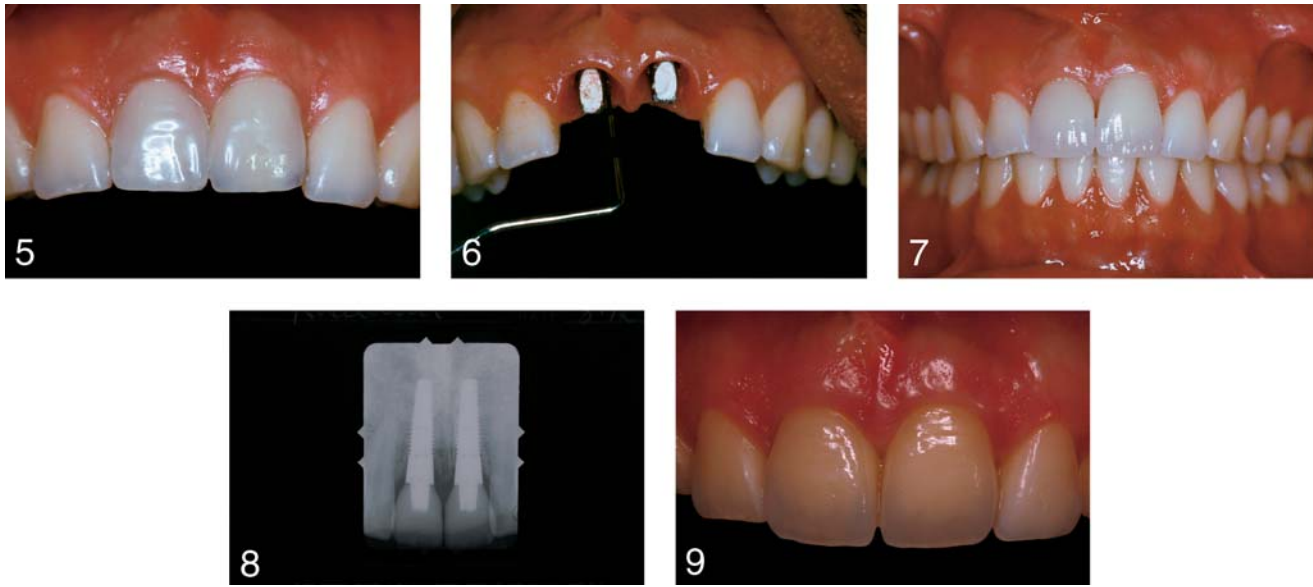
thereby maintaining or creating interimplant papillae.¹⁰

This clinical report describes the immediate provisional placement and prosthetic rehabilitation of 2 missing maxillary central incisors with scalloped dental implants by the flapless approach to preserve the alveolar profile and gingival architecture.

CLINICAL REPORT

A 22-year-old man with no significant medical history was referred to the Department of Prosthodontics in Loma Linda University, School of Dentistry, for replacement of 2 missing maxillary central incisors. The teeth had been avulsed in a biking accident 2 weeks before the appointment (Figure 2). An intra-oral evaluation revealed a sound remaining dentition. The gingival contour and interproximal papillae were intact, and there were no significant changes after teeth avulsion. Also, the patient was wearing an interim maxillary removable dental prosthesis to replace the missing teeth. Bone sounding was performed to evaluate the 3-dimensional alveolar bone structure and to rule out any buccal plate perforation. An impression was made of the maxillary arch with an irreversible hydrocolloid (Jeltrate, Dentsply Intl, York, Pa).

A diagnostic waxing was made on the maxillary cast and a polyethylene vacuum-formed index was made as a guide to orient the implant replicas (Nobel Biocare) (Figure 3). They were fixed with the GC pattern resin (GC America Inc, Alsip, Ill). A putty jig (Lab Putty, Coltene, Cuyahoga Falls, Ohio) was made as a surgical guide for proper scalloped implant orientation.



Figures 5–9. FIGURE 5. Photographs of immediately placed provisionals. FIGURE 6. Abutments after torque tightening the screws and sealing access holes. FIGURE 7. Cemented Procera restorations. FIGURE 8. Postoperative periapical radiograph. FIGURE 9. One-year postoperative follow-up.

The proper shade was chosen, acrylic denture teeth (Portrait IPN, Dentsply Intl) were hollowed out, and acrylic resin provisional copings (Nobel Biocare) were modified. Implant diameter and length were determined by mesiodistal and buccolingual width of the avulsion site and by measuring the amount of bone height between the alveolar ridge and the anatomical landmarks on the preoperative radiograph (Figure 4). Before surgery, the patient rinsed for 1 minute with chlorhexidine digluconate solution 0.12% (Peridex, Zila Professional Pharmaceutical, Phoenix, Ariz).

Surgery was performed under local anesthesia with appropriate asepsis and sterility. The surgical template was used and osteotomy was performed in a flapless manner to preserve the soft tissue architecture. Once the osteotomy was completed according to the NobelPerfect surgical guidelines, the osteotomy sites were checked for fenestrations with a periodontal probe (CP 15 UNC, Hu-Friedy,

Chicago, Ill). A fenestration in the deepest part of the osteotomy site of the right maxillary central incisor was detected. The horizontal incision was made in the depth of the labial sulcus by a mucoperiosteal flap and the fenestration site was exposed. The fenestration was possibly caused by unfavorable jawbone anatomy at the apical portion of the maxillary right central incisor.¹¹ Because of the small fenestration size (1 × 2 mm), the decision was made to place the implants and evaluate implant stability and thread exposure.

NobelPerfect 4.3- × 13-mm implants were placed in the area of teeth #8 and #9, and a good initial stability was achieved. One to 2 threads were exposed on the apical aspect of the labial surface of the implant replacing tooth #8. However, because of a good initial stability of the implant and minimal thread exposure, the decision was made to proceed with the guided bone regeneration.^{12–17} Bio-Oss (OsteoHealth Co, Shirley, NY) (cancellous particles,

size = 0.25–1.00 mm) was packed around the area and was covered with Bio-Mend (Zimmer Dental, Carlsbad, Calif). The area was sutured with 5-0 sutures (Vicryl, Ethicon Inc, Somerville, NJ). Manual hand tightening of abutments and modification of the prefabricated acrylic denture teeth were performed. A vacuum-formed polyethylene index was used to orient the denture teeth, and they were indexed with light-cured flowable composite (Permaflo, Ultradent, South Jordan, Utah).

The provisional restorations were removed; the emergence profile was modified; and the occlusion was adjusted to clear all contacts in maximum intercuspation, lateral excursions, and protrusive. The provisional crowns were polished and cemented with temporary cement (TempBond Kerr, Orange, Calif) (Figure 5). The patient was placed on Peridex (Zila Professional Pharmaceutical) mouth rinse and amoxicillin 500 mg every 8 hours for 1 week.

Four months after implant placement, an impression was made with implant-level impression copings. Crowns were then made with the prefabricated ceramic copings and the Procera porcelain system (Nobel Biocare). The crowns were tried in, and necessary adjustments were made. Abutments were tightened to 35 Ncm (Figure 6). Subsequently, the definitive crowns were cemented with IM-Prov (Nobel Biocare) (Figure 7). A periapical radiograph was made to confirm that excess cement had been removed (Figure 8). The patient was pleased with the results at both 3-month and 1-year follow-up appointments (Figure 9). There were no discernable clinical and radiographic changes in the soft tissue architecture and crestal bone profile. The patient was then placed on a 6-month recall schedule.

CONCLUSION

After traumatic avulsion of the 2 maxillary central incisors, a 22-year-old man was treated with the NobelPerfect dental implant system. Implants were placed in the avulsion socket and provisional restorations were made and cemented immediately. All ceramic Procera crowns were cemented and followed for 1 year. At follow-up, there were no discernable clinical and radiographic changes in the soft tissue architecture and crestal bone profile. The outcome of this clinical

report may support the manufacturer's claim that the scalloped implant design helps preserve the remaining crestal bone profile and support the overlying gingival tissue.

REFERENCES

1. Becker W, Ochsenbein C, Tibbetts L, et al. Alveolar bone anatomic profiles as measured from dry skulls. Clinical ramifications. *J Clin Periodontol.* 1997;24:727-731.
2. Kan JYK, Rungcharassaeng K, Kiotaka U, et al. Dimensions of peri-implant mucosa: an evaluation of maxillary anterior single implants in humans. *J Periodontol.* 2003;74:557-562.
3. Kan JY, Rungcharassaeng K. Site development for anterior single implant esthetics: the edentulous site. *Compend Contin Educ Dent.* 2001;22:221-226.
4. Lazzara RJ. Immediate implant placement into extraction sites: surgical and restorative advantages. *Int J Periodontics Restorative Dent.* 1989;9:332-343.
5. Cochran DL, Hermann JS, Schenk RK, et al. Biologic width around titanium implants. A histometric analysis of the implant-to-gingival junction around unloaded and loaded nonsubmerged implants in the canine mandible. *J Periodontol.* 1997;68:186-198.
6. Hermann JS, Buser D, Schenk RK, et al. Crestal bone changes around titanium implants. A histometric evaluation of unloaded nonsubmerged and submerged implants in the canine mandible. *J Periodontol.* 2000;71:1412-1424.
7. Campelo LD, Camara JR. Flapless implant surgery: a 10-year clinical retrospective analysis. *Int J Oral Maxillofac Implants.* 2002;17:271-276.
8. Rocci A, Martignoni M, Gottlow J. Immediate loading of Branemark System TiUnite and machined-surface implants in the posterior mandible: a randomized open-ended clinical trial. *Clin Implant Dent Relat Res.* 2003;5(suppl 1):57-63.
9. Becker W, Goldstein M, Becker BE, et al. Minimally invasive flapless implant surgery: a prospective multicenter study. *Clin Implant Dent Relat Res.* 2005(7 suppl 1);S21-S27.
10. Wohrle PS. NobelPerfect esthetic scalloped implant: rationale for a new design. *Clin Implant Dent Relat Res.* 2003(5 suppl 1);64-73.
11. Becker W, Dahlin C, Lekholm U, et al. Five-year evaluation of implants placed at extraction and with dehiscences and fenestration defects augmented with ePTFE membranes: results from a prospective multicenter study. *Clin Implant Dent Relat Res.* 1999;1:27-32.
12. Artzi Z, Givol N, Rohrer MD, et al. Qualitative and quantitative expression of bovine bone mineral in experimental bone defects. Part 1: description of a dog model and histological observations. *J Periodontol.* 2003;74:1143-1152.
13. Artzi Z, Givol N, Rohrer MD, et al. Qualitative and quantitative expression of bovine bone mineral in experimental bone defects. Part 2: morphometric analysis. *J Periodontol.* 2003;74:1153-1160.
14. Widmark G, Ivanoff CJ. Augmentation of exposed implant threads with autogenous bone chips: prospective clinical study. *Clin Implant Dent Relat Res.* 2000;2:178-183.
15. Lekholm U, Sennerby L, Roos J, et al. Soft tissue and marginal bone conditions at osseointegrated implants that have exposed threads: a 5-year retrospective study. *Int J Oral Maxillofac Implants.* 1996;11:599-604.
16. Dahlin C, Andersson L, Linde A. Bone augmentation at fenestrated implants by an osteopromotive membrane technique. A controlled clinical study. *Clin Oral Implants Res.* 1991;2:159-165.
17. Dahlin C, Lekholm U, Becker W, et al. Treatment of fenestration and dehiscence bone defects around oral implants using the guided tissue regeneration technique: a prospective multicenter study. *Int J Oral Maxillofac Implants.* 1995;10:312-318.