

Effects of Oleoresin Capsicum Pepper Spray on Human Corneal Morphology and Sensitivity

Minna Vesaluoma,¹ Linda Müller,² Juana Gallar,³ Alessandro Lambiase,⁴ Jukka Moilanen,¹ Tapani Hack,⁵ Carlos Belmonte,³ and Timo Tervo¹

PURPOSE. To examine the potential harmful effects on corneal structure, innervation, and sensitivity of a spray containing the neurotoxin capsaicin (oleoresin capsicum, OC).

METHODS. Ten police officers who volunteered for the study were exposed to OC. Clinical signs were assessed. Corneal sensitivity was measured using a Cochet-Bonnet or a noncontact esthesiometer that provides separate measurements of mechanical, chemical, and thermal sensitivity. Tear fluid nerve growth factor (NGF) was measured. Corneal cell layers and subbasal nerves were examined by in vivo confocal microscopy. The subjects were examined before application and 30 minutes, 1 day, 1 week, and 1 month after OC exposure.

RESULTS. OC spray produced occasional areas of focal epithelial cell damage that healed within 1 day. Each eye showed conjunctival hyperemia and in two subjects, mild chemosis. All except one eye had unchanged best corrected visual acuity (BCVA). A transient decrease (day 1) of mechanical sensitivity was observed with the Cochet-Bonnet esthesiometer. With the gas esthesiometer, mechanical sensitivity remained below normal values for 7 days. Chemical sensitivity to CO₂ was high for as much as 1 day and decreased below normal 1 week later, whereas sensitivity to cold was unaffected. Two subjects had measurable tear NGF that increased after exposure. Basal epithelial cell morphology suggested temporary corneal epithelial swelling, whereas keratocytes, endothelial cells, and subbasal nerves remained unchanged.

CONCLUSIONS. Although OC causes immediate changes in mechanical and chemical sensitivity that may persist for a week, a single exposure to OC appears harmless to corneal tissues. The changes are possibly associated with damage of corneal nerve terminals of mainly unmyelinated polymodal nociceptor fibers. (*Invest Ophthalmol Vis Sci.* 2000;41:2138-2147)

The cornea receives sensory innervation from primary sensory neurons located in the trigeminal ganglion¹⁻⁵ and to a much lesser extent from autonomic sympathetic and parasympathetic nerves that innervate the limbus and the peripheral cornea.⁶⁻⁹ Corneal nerve fibers exhibit immunoreactivity for a great variety of neuropeptides, including substance P and calcitonin gene-related peptide (CGRP),¹⁰⁻¹⁹ as well as classic neurotransmitters, presumably associated with autonomic nerve fibers.^{9,20-22} Functionally, corneal nerve fibers have been classified as mechanosensory units, activated only by mechanical stimulation, polymodal units, responding also to chemical substance and to heat, and

cold-sensitive units, that are excited by low temperatures (see Reference 23 for review).

Capsaicin (8-methyl-vanillyl-6-nonenamide), the pungent component of chili peppers, has been shown to induce intense pain in humans and pseudoaffective pain reactions in animals when applied to the skin and the front of the eye, as well as neurogenic inflammation due to the release of neuropeptides contained in nerve terminals.²⁴⁻²⁶ Capsaicin's effects are associated with acute stimulation of primary sensory nerve endings,²⁷⁻²⁸ which is accompanied by a depletion of their neuropeptide content.²⁹⁻³⁰ This process is followed by nerve inactivation and suppression of neurogenic inflammation in response to injury.^{29,31,32} Capsaicin also has long-lasting effects on sensory nerves and their target tissues. Neonatal injection of capsaicin into small rodents induces a selective sensory denervation followed by a slow and incomplete regeneration of the sensory fibers that is not fully compensated by increased sprouting of intact nerve fibers and persists in adult animals.³³⁻³⁷ Corneal and/or skin ulcers and scars are concomitantly formed and may persist for months,^{29,34,35,37,38} resembling the clinical picture of neuroparalytic-neurotrophic keratitis secondary to trigeminal denervation.³⁹ Capsaicin treatment in adult animals causes less prominent but still detectable alterations of sensory innervation. In vitro and in vivo studies show that nerve growth factor (NGF) reverses the decrease of transmitter content and restores the peripheral function of primary afferent neurons impaired by capsaicin treatment.^{40,41} In humans, the effects of capsaicin on sensory innervation are

From the ¹Department of Ophthalmology, University of Helsinki, Finland; ²The Netherlands Ophthalmic Research Institute, Amsterdam; ³Instituto de Neurociencias, Universidad Miguel Hernandez-CSIC, San Juan de Alicante, Spain; the ⁴Department of Ophthalmology, University of Rome "Tor Vergata," Italy; ⁵Helsinki City Police Department, Finland.

Supported by the Finnish Medical Council, Finnish Eye and Tissue Bank Foundation, Finnish Eye Foundation, The Friends of the Blind, Instrumentarium Scientific Foundation, Ella and Georg Ehrnrooth Foundation, Mary och Georg C. Ehrnrooth Foundation.

Submitted for publication December 28, 1999; accepted February 15, 2000.

Commercial relationships policy: P (JG, CB); N (MV, LM, AL, JM, TH, TT).

Corresponding author: Minna Vesaluoma, Department of Ophthalmology, University of Helsinki, PO Box 220, FIN-00029 HUS, Finland. minna.vesaluoma@hus.fi

poorly known. Capsaicin injected subcutaneously produces acute pain and hyperalgesia.⁴² Topically applied capsaicin ointment (0.075%) used for pain relief results in a reduced sensitivity to cutaneous stimuli and decreased numbers of epidermal nerve fibers. Reinnervation of the skin and recovery of sensitivity have been observed after discontinuation of treatment.²⁶

In the present work, we studied in human eyes the effects of topical capsaicin on corneal innervation and corneal sensitivity using *in vivo* confocal microscopy^{43,44} and noncontact esthesiometry.⁴⁵ We also measured tear fluid NGF concentrations in subjects exposed to capsaicin.⁴⁶

METHODS

OC Exposure

Testing the safety of oleoresin capsicum (OC) spray on police officers was proposed by the Police Department of The Ministry of Internal Affairs, Finland, with the purpose of developing less-than-lethal or nonlethal weapons for use when arresting individuals who resist capture. At a distance of 1.5 to 2.5 m, a mixture containing 5.5% OC, isobutane (30.5%) as a propellant, and isopropyl alcohol (64%) as a carrier (pepper spray, Capstum; Zarc, Bethesda, MD) was sprayed in the face of 10 police officers who volunteered to serve in the study. The exposure lasted for 0.5 to 1.5 seconds during which the police officers were told to hold their eyes open. No special instructions were given in regard to breathing, but most officers held their breath when their faces were exposed. After the OC exposure, routine first aid was given, in which the face was washed with cold water and soap for 5 to 15 minutes. This first aid reduced the intensity of the pain. A medical doctor was available during the exposure and first aid periods.

Subjects and Tests

The Police Department of the Ministry of Internal Affairs and the Ethical Review Committee of Helsinki University Eye Hospital approved the research plan, which followed the tenets of the Declaration of Helsinki. Each subject gave informed consent.

The study was performed in two stages. For the first, five police officers were used (men, 27–34 years of age). All had been exposed several times to OC or to diortho-chlorobenzylidenemalononitrile (CS): three officers 3 times, one 5 times, and one 15 times. For the test, subjects were treated with the OC spray and after first aid, were queried about symptoms and examined by slit lamp biomicroscopy, corneal photography, corneal sensitivity testing with a Cochet–Bonnet esthesiometer, determination of tear fluid NGF levels, and *in vivo* confocal microscopy. The group was re-examined 1 day, 1 week, and 1 month after OC exposure. Visual acuity was also measured at these times. In this group of subjects, prominent changes in corneal sensitivity were noticed. Therefore, in a second group of five police officers (four men and one woman, 24–50 years of age), the eyes were evaluated before and after OC exposure by the same clinical explorations made in the previous group. Corneal sensitivity was, however, more extensively explored using a noncontact gas esthesiometer. Subjects were examined within the first hour, 1 day, and 1 week after OC exposure. Three subjects of this group had never been exposed before to OC or CS. One had undergone bilateral photorefractive kera-

tomy 2 years earlier. The remaining two officers had experienced two and three previous OC exposures, respectively.

Symptom Query and Scoring of Ocular Lesions

The severity of the symptoms including nasal congestion, dyspnea, facial hyperemia, and ocular and facial stinging pain were evaluated. Heart rate was measured with a pulse meter (Polar Electro, Oulunsalo, Finland) before and 1 and 10 minutes after exposure. Ocular lesions were scored according to Draize's scale.⁴⁷

Testing of Corneal Sensitivity

Contact Sensitivity. In the first group of subjects, the sensitivity of the central cornea and of four corneal quadrants was explored in both eyes, by using a Cochet–Bonnet esthesiometer provided with a number 8 filament.⁴⁸ Each area was touched three times, beginning at a filament length of 60 mm and reducing it sequentially in 5-mm steps. A minimum of two positive answers were required for the response to be considered positive. The longest filament that evoked the positive response was considered as the threshold for mechanical sensitivity.

Noncontact Gas Esthesiometry. Corneal sensitivity of the second group of police officers was tested unilaterally with a gas esthesiometer that performed selective mechanical, chemical, and thermal stimulation of the cornea.⁴⁵ Gas jets of 3 seconds' duration were applied to the corneal surface at 2-minute intervals. Mechanical stimulation consisted of a series of pulses of warmed air at flow rates varying from 0 to 300 ml/min. Chemical stimulation was performed with series of six pulses of a warmed mixture of air and CO₂ at different concentrations (0–80%). For selective thermal stimulation 10 pulses of air, warmed or cooled in the tip of the probe (from –10° to +80°C, corresponding to changes in corneal surface temperature between –5°C and +3°C around the control value of 34.5°C) were used. At least one blank stimulus (a pulse with no gas flow) was applied between pulses of each series. To prevent mechanical stimulation during selective chemical and thermal stimulation, flows below mechanical threshold value previously measured for each subject were used. To avoid changes in basal corneal temperature during selective mechanical and chemical stimulation, the gas stream was heated up to 50°C at the tip of the probe.⁴⁵

Subjects were seated comfortably in front of a slit lamp, with the head supported by the head holder. With the slit lamp table controls, the tip of the gas esthesiometer was adjusted at a distance of 5 mm perpendicular to the center of the cornea. The subject was asked to blink immediately before the stimulus. A click produced by the opening of the valve in the probe identified the onset of the stimulus. Selective mechanical, chemical, and thermal stimulation was performed in the left eye in each session. The protocol was completed after the third session, performed 1 week after OC exposure.

Immediately after each stimulation pulse, the subject had to judge and mark the magnitude of the various parameters of the sensation in a continuous horizontal scale of 10 cm (the visual analog scale [VAS]). In the VAS, 0 was assigned to no sensation and 10 to the maximal sensation ever experienced. Six different components of the sensation were studied: 1) intensity 2) degree of irritation, 3) magnitude of burning pain, 4) magnitude of stinging pain, 5) cooling component of the

sensation, and 6) warming component of the sensation (Acosta MC, Belmonte C, Gallar J, unpublished observations).

Tear Fluid Collection

Unilateral tear fluid samples were collected with a scaled 5- or 25- μ l fire-polished microcapillary tube, as previously described.⁴⁹ The tear fluid flow in the collection capillary (in microliters per minute) was calculated by dividing the volume of the tear fluid sample by the collection time. The release (in picograms per minute) was calculated by multiplying the concentration in the sample by the tear fluid flow in the collection capillary.⁵⁰ As capsaicin exposure induced a marked hypersecretion of tears, the use of the parameter "release" (flow-corrected concentration) enabled the comparison of pre- and postexposure concentrations. The tear samples were directly transferred to tubes (Eppendorf, Fremont, CA) and stored at -70°C .

Tear NGF Determination

The tear NGF concentrations were measured by a two-site, immunoenzymatic assay that recognizes human and murine NGF and is capable of detecting as low as 5 pg/ml.⁴⁶ Briefly, polystyrene 96-well microtube immunoplates (NUNC, Naperville, IL) were coated with affinity-purified polyclonal goat anti-NGF antibody. Parallel wells were coated with preimmune goat IgG for evaluation of the nonspecific signal. After overnight incubation at room temperature and 2-hour incubation with the coating buffer (0.05 M carbonate buffer [pH 9.5] in 2% bovine serum albumin), plates were washed with 50 mM Tris-HCl (pH 7.4), 200 mM NaCl, 0.5% gelatin, and 0.1% Triton X-100). After extensive washing, the diluted tear and NGF standard solutions were distributed into the wells and left at room temperature overnight. The plates were washed and incubated with 4 mU/well anti- β -NGF-galactosidase (Boehringer Mannheim, Mannheim, Germany) for 2 hours at 37°C and, after another washing, 100 μ l of substrate solution (4 mg chlorophenol red/ml substrate buffer; Boehringer Mannheim) was added to each well. After an incubation of 2 hours at 37°C , optical density was measured at 575 nm using an enzyme-linked immunosorbent assay reader (Dynatech Laboratories, Billingshurst, UK), and the values of standards and samples were corrected by subtracting the background value produced by nonspecific binding. Data were expressed in picograms per milliliter, and all assays were performed in duplicate.

In Vivo Confocal Microscopy

A tandem scanning confocal microscope (TSCM, Model 165A; Tandem Scanning, Reston, VA) was used to examine all layers of the central cornea. The left eye of each subject was explored. First a drop of topical anesthetic (benoxinate hydrochloride; Oftan Obucain; Santen, Tampere, Finland) was applied on the cornea, and a drop of 2.5% hydroxymethylcellulose gel (Goniosol; IOLAB Pharmaceuticals, Claremont, CA) was placed on the tip of the objective lens. The setup and operation of the confocal microscope has been described previously.^{43,44} Briefly, a $\times 24$, 0.6 numeric aperture variable working-distance objective lens was used. The field of view with this lens is $450 \times 360 \mu\text{m}$, and the z -axis resolution is 9 μm . Images were detected using a low-light-level camera (VE1000; Dage, Michigan City, IN) and recorded on SVHS tape. Video images of interest were digitized using a computer-based

imaging system with custom software (University of Texas Southwestern Medical Center, Dallas), and printed (Stylus Color 800 printer; Seiko Epson, Nagano, Japan).

Statistical Analyses

Data are expressed as means \pm SEM or SD. Differences between groups or subjects were examined with parametric (Student's t -test, one-way analysis of variance [ANOVA]) or nonparametric statistical tests (repeated measures, ANOVA on ranks, Friedman's test), as necessary. Pearson correlation was used to determine the stimulus-response relationship. Statistical significance was set at $P < 0.05$.

RESULTS

Symptoms

After OC exposure, all subjects had mild to moderate facial hyperemia. Additionally, they reported mild to moderate ocular and/or facial stinging sensations with a mean duration of 24 minutes (range, 4–50 minutes). Five police officers had mild nasal congestion during the first 30 minutes, but none of them had dyspnea. The mean heart rate increased significantly from a basal value of 79.7 ± 13.3 beats/min (mean \pm SD) to 116.0 ± 19.1 beats/min (at 1 minute) and subsequently decreased in 10 minutes to 73.0 ± 17.9 beats/min (one-way ANOVA, $P < 0.001$).

Scoring of Ocular Lesions by Slit Lamp Biomicroscopy

Draize's scale for scoring of ocular lesions includes signs in cornea, iris, and conjunctiva.⁴⁷ Six corneas of four police officers showed focal corneal epithelial cell damage at 20 minutes as shown in Figure 1, but none of the corneas showed opacities as described in Draize's scale.⁴⁷ The following day, the epithelial surface of all subjects was normal again. All eyes showed conjunctival hyperemia (score 1) at 20 minutes. The mean duration of conjunctival injection was 9.8 hours (range, 2–24 hours). Mild chemosis (score 1) was observed in two subjects after the exposure, but it was undetectable on the following day.

Visual Acuity

Best corrected visual acuity (BCVA) was not tested immediately after OC exposure, because the subjects could not keep their eyes open. Except for those in one subject, all eyes had unchanged BCVA ($\geq 20/20$) throughout the study. One police officer lost one line at both 1 day and 1 week after OC.

Sensitivity Testing

Table 1 illustrates that 20 minutes after OC exposure mechanical sensitivity explored with the Cochet-Bonnet esthesiometer in the first group of subjects was markedly decreased in all quadrants of the cornea. One subject had complete bilateral corneal anesthesia, while reduced mechanical sensitivity was observed in six eyes of the remaining four police officers. Within 1 day, normal levels were recovered, remaining normal to Cochet-Bonnet exploration up to 1 month. The sensitivity of right and left eyes at different time points are shown separately.

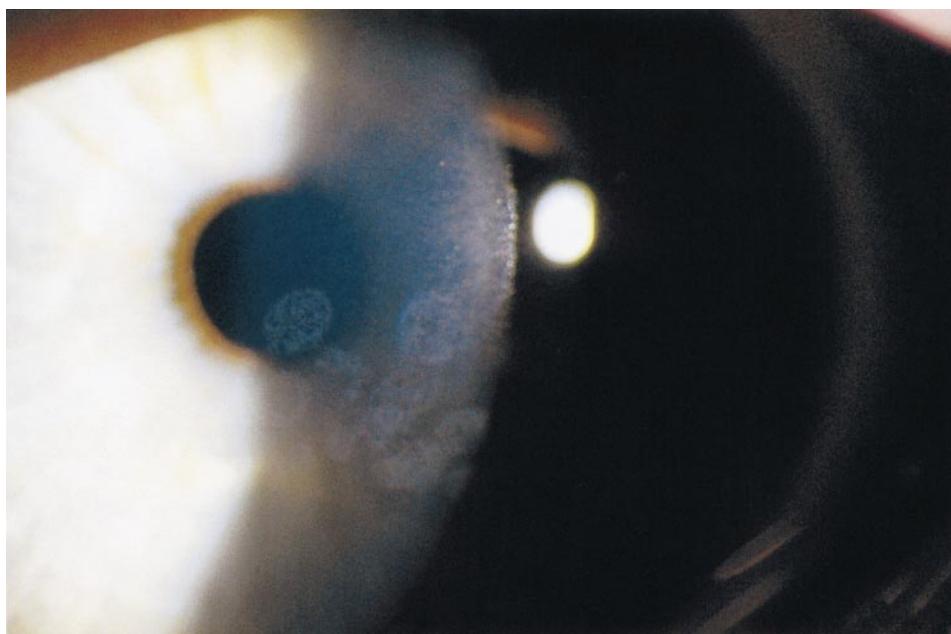


FIGURE 1. A cornea after OC exposure showing focal epithelial cell damage visible in slit lamp examination.

Gas Esthesiometry

Sensation Threshold. Table 2 presents the sensation threshold for mechanical, chemical, and thermal stimulation of the cornea before and at 30 minutes, 1 day, and 1 week after capsaicin treatment. Thirty minutes after OC, mechanical sensitivity was present in all studied subjects, but the average mechanical threshold was significantly higher than control (Table 2), and the frequency distribution curve of mechanical threshold values was shifted to the right 30 minutes, 1 day, and 1 week after OC (Fig. 2A).

Threshold for CO₂ stimulation was not significantly modified 30 minutes after OC (Table 2). One day later, sensitivity to CO₂ pulses was present in only three of five subjects. In these three subjects, the CO₂ threshold was significantly higher (Table 2, Fig. 2B) in comparison with control values. The remaining two subjects did not respond to CO₂. One of them was again tested 1 week after exposure to capsaicin and showed a recovered sensitivity to CO₂.

Thirty minutes after exposure to OC, sensitivity to heat

had disappeared in two subjects, but threshold for hot stimulation of the remaining three was normal (Table 2, Fig. 2C). Similar results were obtained 1 day and 1 week after capsaicin (Table 2, Fig. 2C). Cold sensitivity and cold threshold were unaffected by OC (Table 2, Fig. 2D).

Stimulus-Response Curves. *Mechanical Stimulation.* Figure 3A illustrates the stimulus-response curve of subjective intensity of mechanical stimulation in control conditions and 30 minutes after OC. In both cases, subjective intensity was significantly correlated with the magnitude of the stimulus (correlation coefficients: 0.950 and 0.966; $P = 0.00,008$ and 0.002 for control and 30 minutes after OC exposure, respectively). However, the values of intensity of the sensation reported for increasing stimulus forces were lower 30 minutes after OC (Fig. 3A). Thus, the power of the function describing the stimulus-response relation (Steven's power function) was slightly smaller for OC-treated eyes (exponent: 1.20 versus 1.54 in control; Fig. 3A, inset). One day and 1 week after capsaicin, the intensity curve for mechanical stimulation still deviated to the right in comparison with control conditions (Figs. 4A, 5A).

TABLE 1. Corneal Mechanical Sensitivity (Mechanical Threshold) after OC Exposure

	Central	Upper Nasal	Lower Nasal	Upper Temporal	Lower Temporal
20 Minutes					
OD ($n = 4$)	35.0 ± 26.5	40.0 ± 27.1	30.0 ± 21.6	37.5 ± 28.7	32.5 ± 25.0
OS ($n = 5$)	42.0 ± 24.9	40.0 ± 23.5	38.0 ± 22.8	42.0 ± 24.9	38.0 ± 24.9
1 Day					
OD ($n = 4$)	60.0 ± 0	60.0 ± 0	58.8 ± 2.5	56.3 ± 7.5	55.0 ± 4.1
OS ($n = 5$)	60.0 ± 0	58.0 ± 2.7	53.0 ± 13.0	59.0 ± 2.2	52.2 ± 12.6
1 Week					
OD ($n = 5$)	55.0 ± 4.1	53.8 ± 12.5	60.0 ± 0	55.0 ± 5.8	56.3 ± 4.8
OS ($n = 5$)	60.0 ± 0	46.3 ± 18.0	57.5 ± 5.0	52.5 ± 15.0	56.3 ± 4.8
1 Month					
OD ($n = 4$)	60.0 ± 0	57.5 ± 5.0	55.0 ± 10.0	58.8 ± 2.5	56.3 ± 7.5
OS ($n = 4$)	60.0 ± 0	60.0 ± 0	60.0 ± 0	58.8 ± 2.5	58.8 ± 2.5

Data are Cochet-Bonnet esthesiometer filament lengths (mean ± SD). The differences in sensitivity of each area at various time points did not reach statistical significance (Friedman's test). Right (OD) and left (OS) eyes considered separately. Pre-exposure sensitivity values are not available.

TABLE 2. Sensation Thresholds for Mechanical, Chemical, Heat, and Cold Stimulation Determined at Different Times after OC Application

Threshold	Control (n = 5)	Time after OC		
		30 Minutes	24 Hours	1 Week
Mechanical (ml/min)	121 ± 11	210 ± 38 (5)*	204 ± 45 (5)†	183 ± 48 (4)†
Chemical (% CO ₂)	22 ± 3	24 ± 4 (5)	33 ± 6 (3/5)‡	35 ± 9 (4)
Heat (°C)	65 ± 3	73 ± 6 (3/5)§	65 ± 5 (2/5)§	70 ± 10 (2/4)§
Cold (°C)	17 ± 5	16 ± 3 (5)	13 ± 3 (5)	9 ± 7 (4)‡

Data are mean ± SEM; number of examined subjects in parentheses.

* $P < 0.001$, † $P < 0.01$, ‡ $P < 0.05$, Student's *t*-test, differences from control.

§ Number of responding subjects/number of examined subjects.

Chemical Stimulation. In control conditions, values given to the intensity of the sensation increased with the concentration of CO₂ in the applied stimulus (Fig. 3B, squares). A significant correlation was found between subjective intensity and magnitude of the stimulus (correlation coefficient: 0.983, $P = 0.00,001$). Thirty minutes after OC exposure, subjects reported higher VAS values for all values of CO₂ concentration (Fig. 3B, circles). This was reflected in the steeper slope of the line obtained when the data were fitted to a straight line (Fig. 3B, inset). Twenty-four hours after exposure, there was no response in two individuals, whereas the intensity-response curve to chemical stimulation of the remaining three remained shifted to the left for the highest CO₂ concentration values (Fig. 4B) and was back to control values 1 week after exposure (Fig. 5B).

Hot Air. Thirty minutes after OC exposure, no response to hot stimulation was obtained in two subjects. VAS values re-

ported by the remaining three subjects were similar to control values (Fig. 3C). Twenty-four hours after OC exposure, responsiveness to hot air was present in two of five subjects, with the average VAS values lower than in control subjects (Fig. 4C). One week after exposure, values of the response to hot air was slightly lower than in control (Fig. 5C).

Cold Air. Intensity-response curves obtained with cold stimulation of the cornea were not modified by OC exposure (Figs. 3D, 4D, 5D).

Tear Fluid NGF

NGF was at measurable levels in the tear samples of 2 of 10 police officers (Figs. 6A, 6B). Of note, these eyes had not had earlier contacts with tear gases, nor had they undergone any corneal surgery.

In Vivo Confocal Microscopy

In the first examination at 30 to 60 minutes after OC exposure, surface epithelial changes were observed in two eyes. These

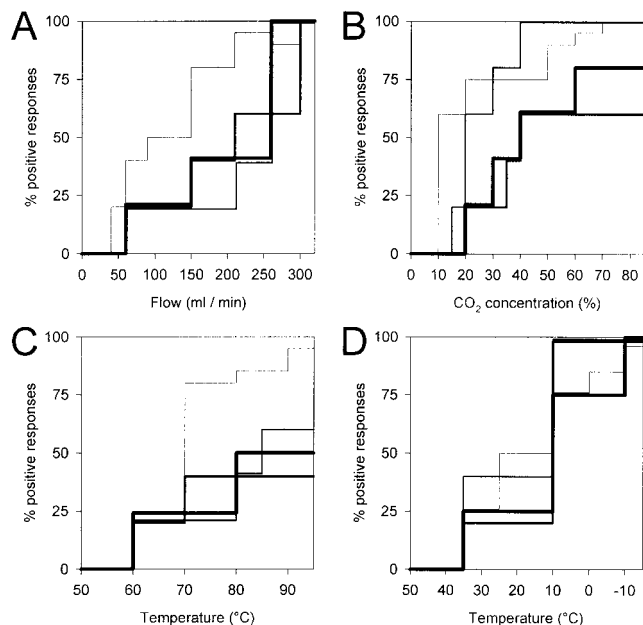


FIGURE 2. Cumulative distribution of thresholds for mechanical (A), chemical (B), hot (C), and cold (D) selective stimulation of the cornea of human volunteers before and at different times after OC application. Data represent the incidence of positive responses of subjects to increasing intensities of stimulation as a percentage of the total number of stimuli. Lines of increasing thickness represent control, 30 minutes after OC, 1 day after OC, and 1 week after OC.

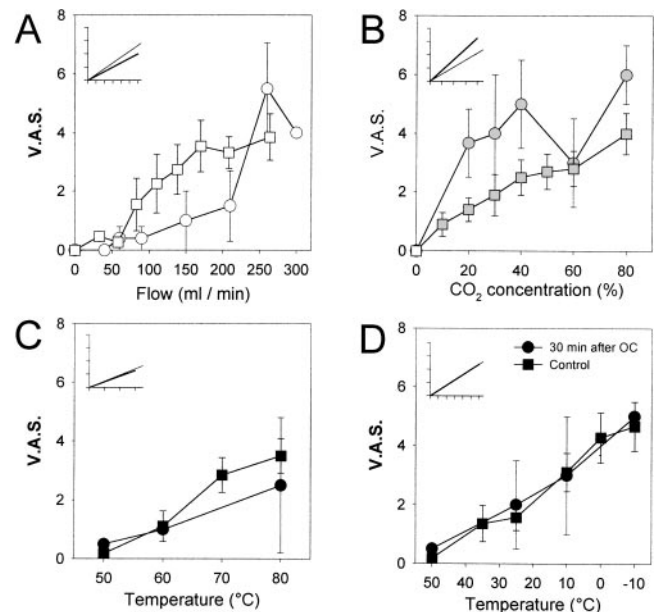


FIGURE 3. Intensity-response curves for selective to mechanical (A), chemical (B), and thermal (C) stimulation of the cornea 30 minutes after OC exposure. Intensity was measured with a VAS from 0 to 10 by control (squares) and capsaicin-treated (circles) subjects. Data are mean ± SEM, $n = 5$. Inset: linear regression analysis of the data represented in each figure; thin line, control; thick line, OC exposure.

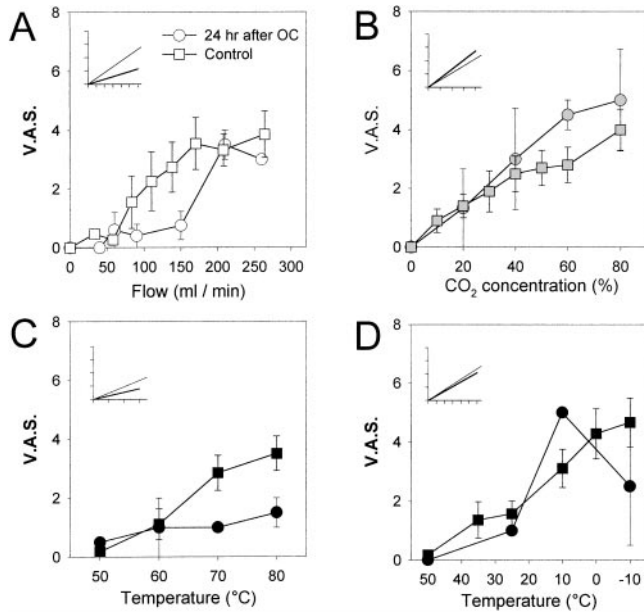


FIGURE 4. Intensity-response curves 1 day after OC treatment. Stimuli, intensity measurement, data expression, and linear regression are as in Figure 3 (*n* = 5).

appeared as cells detaching from the corneal surface either individually or as a larger cluster of highly reflective epithelial cells (Fig. 7A). The epithelial surface regained its normal appearance by the next day (Fig. 7B). Although basal epithelial cells were clearly visible during all examinations, cell borders were more pronounced 30 minutes and 1 day after OC (Figs. 7C, 7D). No morphologic changes were evident in subbasal nerves, but they were also, in some cases, better visualized 30 minutes and 1 day after treatment (Figs. 8A, 8B, 8C). The cornea of a police officer previously exposed to OC 15 times,

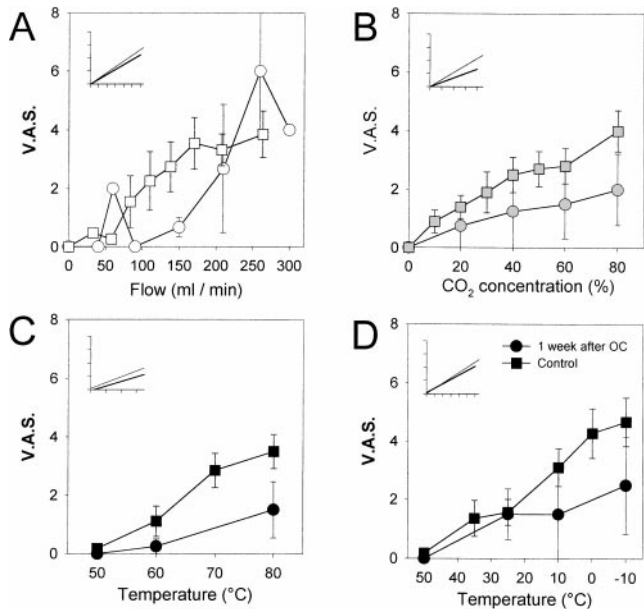


FIGURE 5. Intensity-response curves 1 week after OC treatment. Stimuli, intensity measurement, data expression, and linear regression are as in Figure 3 (*n* = 4).

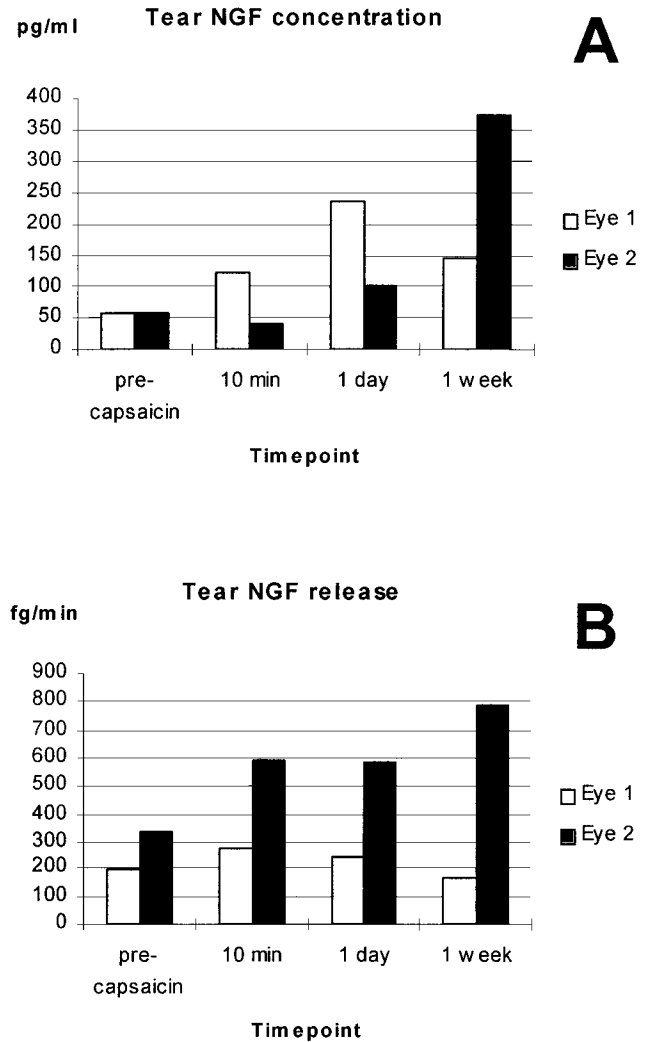


FIGURE 6. Tear NGF concentrations (in picograms per milliliter) (A) and releases (in femtograms per minute) (B) of two subjects. Neither of these eyes had had previous contact with tear gases.

showed a strange spirallike subbasal plexus with interspersing, most probably, Langerhans' cells (Fig. 8D). The remaining subjects had normal parallel, running, bifurcated, and fused nerves (Fig. 8A). Most of the nerves contained one or several beaded nerve fiber bundles (Fig. 8A). The interindividual variation in visualizing subbasal nerves was high, but the images at all time points of each individual remained similar.

The morphology of the most anterior keratocytes remained unaltered throughout the study (Fig. 9A, 9B, 9C). As for the basal epithelial cells, keratocyte nuclei were also occasionally better visualized at 30 minutes. No signs of keratocyte death or activation were observed.^{44,51} The morphologic appearance of the mid and posterior keratocytes as well as the transparency was also normal throughout the study (data not shown). The endothelial cells, easily visualized in all corneas, maintained a regular hexagonal pattern after OC application (Fig. 9D).

DISCUSSION

The rationale of adding capsaicin to a self-protecting spray is that this substance induces an intensive but relatively short-

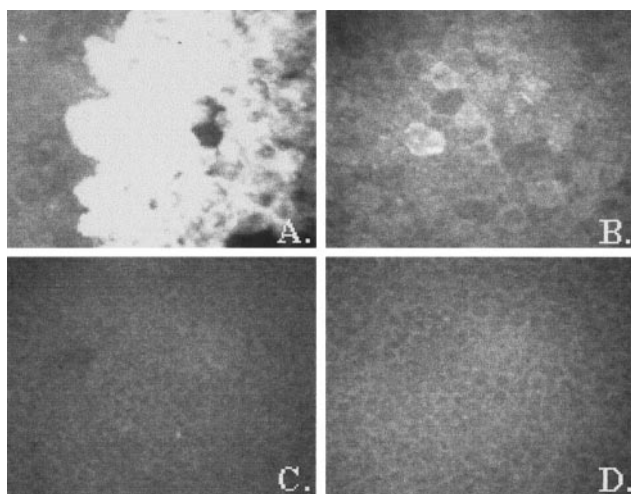


FIGURE 7. Corneal epithelial cells after OC exposure. A large cluster of highly reflective surface epithelial cell is observed in one cornea immediately after exposure (A). The epithelium appeared close to normal on the following day (B). Basal epithelial cells were clearly perceived before exposure (C), but at 30 minutes the cell borders were more pronounced, possibly because of epithelial swelling (D). Image size, $265 \times 220 \mu\text{m}$.

lasting pain²⁴ leading to blepharospasm and hypersecretion of tears. Capsaicin sprayed onto the face immobilizes the individual and prevents attack or resistance against arrest by law enforcement personnel. Early-generation tear gases such as chloroacetophenone (CN) and CS frequently induced detachment of the whole corneal epithelium necessitating medical assistance for days or weeks. Pepper spray, containing OC as the active substance, is widely used in private self-protection and by the police.

This study shows that the structural and functional effects of OC spray on conjunctiva and cornea are mild and temporary. This interpretation applies only to the preparation used in the present work; other solvents, such as 92% trichloroethyl-

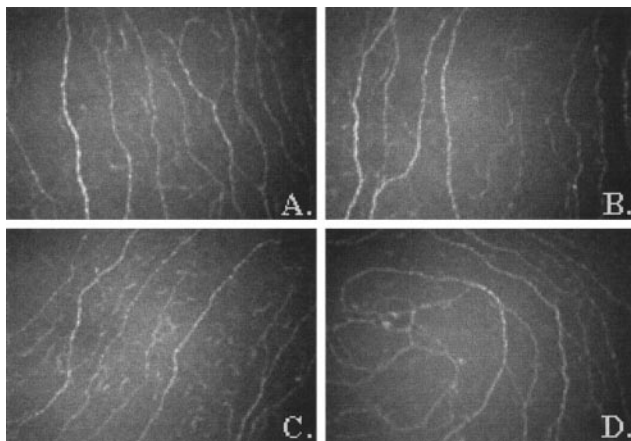


FIGURE 8. Subbasal nerves after OC exposure. No morphologic changes could be detected by confocal microscopy (A) before exposure, (B) at 30 minutes, and (C) at 1 day. However, a cornea with 15 previous exposures to OC or other tear gases showed an abnormal spirallike subbasal plexus, not previously described in humans (D). Image size, $380 \times 275 \mu\text{m}$.

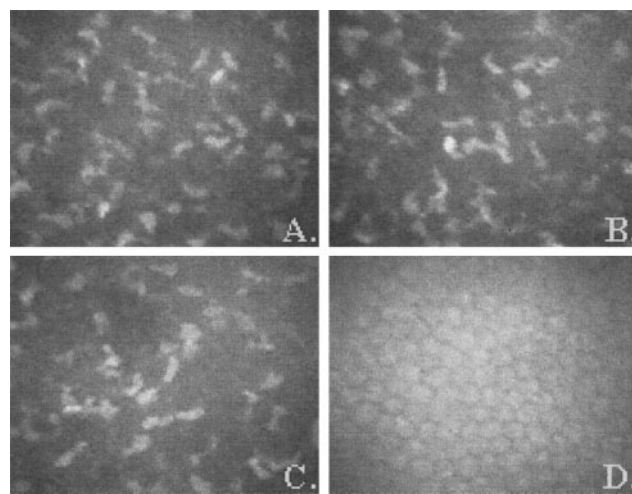


FIGURE 9. The morphology of the first anterior keratocytes after OC exposure remained the same, and no signs of activation could be detected (A) before exposure, (B) at 30 minutes, and (C) at 1 day. Only the keratocyte nuclei can be perceived. Endothelial cells showed a regular hexagonal pattern throughout the follow-up (D, at 1 month). Image size, $265 \times 220 \mu\text{m}$.

ene, may induce severe corneal damage (Tervo et al., unpublished observations, 1999). Several studies on the ocular effects of capsaicin in animals have been published.^{27,28,34,38} However, only recently the effects of OC sprays on the human eye were briefly reported.⁵² These researchers described transient and moderate conjunctival and corneal changes with occasional punctate epithelial erosions. In the present study, mild and short-lasting corneal and conjunctival signs were also observed. It is possible that epithelial damage was caused by the alcohol solvent rather than by capsaicin, because similar grayish white epithelial changes can occasionally be seen after contact with isopropyl alcohol-cleaned, but wet, tonometer tips. Visual acuity was unaffected in all but one eye, in agreement with the data of Zollman et al.⁵²

The acute effects of capsaicin on the sensory activity of corneal nerve afferents in animals are well documented.^{27,28,53} In the cat eye, capsaicin at high concentrations (1%, 33 mM) produced a transient excitation of polymodal nociceptive fibers followed by inactivation of most fibers to all subsequent stimuli; cold sensory fibers were weakly activated, but many remained active after capsaicin, whereas pure mechanosensory fibers were largely unaffected by this substance. The excitatory effects of capsaicin are due to activation of a vanilloid receptor (VR1) present in polymodal nociceptive neurons^{54,55} that acts as a nonselective cationic channel, thus depolarizing sensory nerve terminals. This strong excitatory effect on polymodal nociceptive fibers explains the intense pain experienced immediately after capsaicin application to the eye. Toxic effects of capsaicin are the consequence of a massive calcium entrance that leads to cell damage and functional inactivation, making nerve endings insensitive to further stimuli.⁵⁶

Determinations of mechanical threshold with the Cochet-Bonnet esthesiometer after capsaicin treatment showed an acute reduction of corneal mechanical sensitivity followed by a progressive recuperation of control values.⁵² Nevertheless, the Cochet-Bonnet esthesiometer does not permit evaluation in detail of the degree of short- and long-term functional distur-

bances caused by capsaicin in the various populations of sensory fibers that sustain corneal sensitivity. Graded measurement of the responsiveness to mechanical, chemical, and thermal stimulation of the cornea with the gas esthesiometer indicate that the effect of capsaicin on the different populations of corneal nerve fibers was heterogeneous and evolved with time.

With the gas esthesiometer, the reduction of mechanical sensitivity observed with Cochet-Bonnet stimulation was confirmed. Responses to low and moderate mechanical stimulation were depressed to a varying degree among individuals 30 minutes after OC and remained below control values 1 week after OC treatment. Acute blockade of a fraction of polymodal nociceptors, preferentially those with unmyelinated axons that are highly sensitive to capsaicin,⁵³ seemed to be responsible for the immediate reduction of sensitivity to mechanical stimulation. Residual mechanical sensitivity in the first hour after OC application is attributable to activation of pure mechanosensory fibers that have a higher threshold and would be much less affected by capsaicin²⁷ and to those polymodal units presumably A-delta that remained functional. The gradual return of mechanosensitivity during the ensuing hours and days may be ascribed to the recovery of those corneal polymodal fibers that were initially inactivated by capsaicin. The response to chemical stimulation with CO₂, which is also mediated by polymodal fibers was enhanced immediately after OC application. Twenty-four hours later, it remained high in three subjects but was absent in two, reappearing in a depressed state in all subjects 7 days after treatment. These results confirm that a variable fraction of the polymodal fibers was acutely inactivated and that this process reached a maximum 24 hours after OC exposure. They further indicate that the fibers that remain functional became sensitized⁵⁷ thus producing a hyperalgesic response. This phenomenon was more prominent with CO₂ than with heat stimulation, although both stimuli activate polymodal nociceptive fibers, probably reflecting the fact that heat responses are mediated by VR1 (capsaicin) receptors while additional, capsaicin-insensitive ion channels participate in the responses to acid.⁵⁸ The absence of changes in cold sensitivity during the 24 hours after OC exposure indicates that cold-sensory fibers were not immediately affected by capsaicin. Nevertheless, as occurred with the other modalities of sensation, cold sensitivity was depressed 1 week later, implying that a part of both polymodal and cold fibers were disturbed in the long term by the treatment.

NGF is the prototypical member of the neurotrophin family of growth factors.⁵⁹ It plays a critical role in the development of primary sensory neurons during embryonic life,^{60,61} including those that innervate the cornea.⁶² In adult animals, NGF receptors (TrkA) remain in the subpopulation of small nociceptive sensory ganglion neurons.⁶³ During chemically induced inflammation with carrageenan⁶⁴ or turpentine,⁶⁵ increased tissue levels of NGF have been measured. Tissue NGF seems to increase the sensibility of peripheral terminals to noxious stimuli.⁶⁶ In the present experiments two of the five police officers showed detectable levels of NGF in tears, and levels increased after OC treatment. Elevated values could still be measured 1 week later. In spite of the limited number of data, these results suggest that in the cornea,⁶⁷ as in other tissues, NGF is released during noxious stimulation contributing to sensitization and hyperalgesia of inflamed ocular tissues. Moreover, elevated NGF levels may contribute to nerve sprout-

ing and enhanced neuropeptide synthesis observed in the skin after injury and in the cornea after capsaicin treatment.^{36,37} This in turn would facilitate healing of the injured target tissues.^{38,68,69}

In vivo confocal microscopy is a noninvasive method for examining tissue responses in different corneal sublayers of the human cornea.^{43,44} Toxicity of various substances has been evaluated in an animal model,⁵¹ but to our knowledge, this is the first in vivo confocal microscopy study on potential toxic effects of a substance on the human cornea. The results show that OC spray causes surface epithelial damage of short duration in some subjects. That the cell borders of the basal epithelial cells were easily visualized at 30 minutes and 1 day after OC, without signs of cell damage, suggests epithelial swelling.

No changes could be ascertained in the morphology of subbasal nerves after a single pepper spray exposure. Electron microscopic observations^{70,71} have revealed that corneal subbasal nerves that are seen by in vivo confocal microscopy correspond to nerve bundles, because visualization of individual nerve fibers is beyond the level of resolution of confocal microscopy. In most cases the nerves were more apparent after OC exposure, probably because of swelling of the epithelial cells through which the nerves are pressed into the same focal plane. The images of the nerve fiber bundles did not vary during the study, and no signs of sprouting were apparent. It is possible that the insult to the nerves is not great enough to induce sprouting. Alternatively, sprouting may be beyond the level of resolution or is limited to the peripheral cornea, as described for experimental animals,³⁷ which was out of the range of observation in the present experiment in which explorations were limited to the central cornea. A surprising finding was the spirallike nerve fiber bundle arrangement of the subbasal plexus in the eyes of a police officer repeatedly exposed to OC or CS. A similar organization has been observed in the nerves of the cornea of an alkaline phosphatase transgenic mice (Belmonte and Raviola, unpublished observations, 1999), but its significance is obscure.

Because of the mild and transient signs of tissue injury, it can be concluded that single exposure of human eyes to OC is relatively harmless to the cornea and conjunctiva. However, one should be cautious in repeated OC exposures, because long-lasting changes in corneal sensitivity could occur. These changes are possibly associated with damage of nerve terminals of mainly unmyelinated polymodal nociceptive fibers.

Acknowledgments

The authors thank Luigi Aloe, Institute of Neurobiology of National Research Council of Rome, for help with tear NGF measurements.

References

1. Zander E, Weddel G. Observation on the innervation of the cornea. *J Anat.* 1951;85:68-99.
2. Ruskell GL. Ocular fibres of the maxillary nerve in monkeys. *J Anat.* 1974;118:195-203.
3. Tervo T. Histochemical demonstration of cholinesterase activity in the cornea of the rat and the effect of various denervations on corneal nerves. *Histochemistry.* 1976;47:133-143.
4. Ten Tusscher MPM, Klooster J, Vrensen GFJM. The innervation of the rabbit's anterior eye segment: A retrograde tracing study. *Exp Eye Res.* 1988;46:717-750.

5. De Felipe C, Gonzalez GG, Gallar J, Belmonte C. Quantification and immunocytochemical characteristics of trigeminal ganglion neurons projecting to the cornea: effects of corneal wounding. *Eur J Pain*. 1999;3:31-39.
6. Ehinger B. Distribution of adrenergic structures to orbital structures. *Acta Physiol Scand*. 1964;62:291-292.
7. Tervo T, Palkama A. Sympathetic nerves to the rat cornea. *Acta Ophthalmol*. 1976;54:75-84.
8. Tervo T, Palkama A. Adrenergic innervation of the rat corneal epithelium. *Invest Ophthalmol*. 1976;15:147-150.
9. Toivanen M, Tervo T, Partanen M, Vannas A, Hervonen A. Histochemical demonstration of adrenergic nerves in the stroma of human cornea. *Invest Ophthalmol Vis Sci*. 1987;28:398-400.
10. Miller AS, Costa M, Furness JB, Chubb IW. Substance P immunoreactive sensory nerves supply the rat iris and cornea. *Neurosci Lett*. 1981;23:243-249.
11. Tervo K, Tervo T, Eränkö L, Eränkö O, Cuello AC. Immunoreactivity for substance P in the Gasserian ganglion, ophthalmic nerve and anterior segment of the rabbit eye. *Histochem J*. 1981;13:435-443.
12. Tervo K, Tervo T, Eränkö L, Vannas A, Cuello AC, Eränkö O. Substance P-immunoreactive nerves in the human cornea and iris. *Invest Ophthalmol Vis Sci*. 1982;23:671-674.
13. Sasaoka A, Ishimoto I, Kuwayama Y, et al. Overall distribution of substance P nerves in the rat cornea and their three dimensional profiles. *Invest Ophthalmol Vis Sci*. 1984;25:351-356.
14. Stone RA, Kuwayama Y, Laties AM, Schmidt ML. Guinea-pig ocular nerves contain peptide of the cholecystokinin/gastrin family. *Exp Eye Res*. 1984;39:387-391.
15. Stone RA, Kuwayama Y, Terenghi G, Polak J. Calcitonin gene-related peptide: Occurrence in corneal sensory nerves. *Exp Eye Res*. 1986;43:279-283.
16. Stone RA, Laties AM, Emson P. Neuropeptide Y and the ocular innervation of rat, guinea pig, cat and monkey. *Neurosci*. 1986;17:1207-1216.
17. Stone RA, Tervo T, Tervo K, Tarkkanen A. Vasoactive intestinal polypeptide-like immunoreactive nerves to the human eye. *Acta Ophthalmol*. 1986;64:12-18.
18. Terenghi G, Polak JM, Ghatei MA, et al. Distribution and origin of calcitonin gene-related polypeptide (CGRP) immunoreactivity in the sensory innervation of the mammalian eye. *J Comp Neurol*. 1984;233:506-516.
19. Jones MA, Marfurt CF. Peptidergic innervation of the rat cornea. *Exp Eye Res*. 1998;66:421-435.
20. Tervo T, Joo F, Huikuri K, Toth I, Palkama A. Fine structure of sensory nerves in the rat cornea: an experimental nerve degeneration study. *Pain*. 1979;6:57-70.
21. Katz DM, Markey KA, Goldstein M, Black IB. Expression of catecholaminergic characteristics by primary sensory neurons in the normal adult rat in vivo. *Proc Natl Acad Sci USA*. 1983;80:3526-3530.
22. Ueda S, del Cerro M, LoCascio JA, Aquavella JV. Peptidergic and catecholaminergic fibers in the human corneal epithelium. *Acta Ophthalmol*. 1989;67:80-89.
23. Belmonte C, Garcia-Hirschfeld J, Gallar J. Neurobiology of ocular pain. *Prog Retinal Eye Res*. 1997;16:117-156.
24. Dupuy B, Thompson H, Beuerman RW. Capsaicin: a psychophysical tool to explore corneal sensitivity. [ARVO Abstract.] *Invest Ophthalmol Vis Sci*. 1988;29(4):S454. Abstract nr 27.
25. Gonzalez GG, Garcia de la Rubia P, Gallar J, Belmonte C. Reduction of capsaicin-induced ocular pain and neurogenic inflammation by calcium antagonists. *Invest Ophthalmol Vis Sci*. 1993;34:3329-3335.
26. Nolan M, Simone DA, Wendelschafer-Crabb G, Johnson T, Hazen E, Kennedy WR. Topical capsaicin in humans: parallel loss of epidermal nerve fibers and pain sensation. *Pain*. 1999;81:135-145.
27. Belmonte C, Gallar J, Pozo MA, Rebollo I. Excitation by irritant chemical substances of sensory afferent units in the cat's cornea. *J Physiol*. 1991;437:709-725.
28. Chen X, Belmonte C, Rang HP. Capsaicin and carbon dioxide act by distinct mechanisms on sensory nerve terminals in the cat cornea. *Pain*. 1997;70:23-29.
29. Gamse R, Holzer P, Lembeck F. Decrease of substance P in primary afferent neurones and impairment of neurogenic plasma extravasation by capsaicin. *Br J Pharmacol*. 1980;68:207-213.
30. Maggi CA, Santicioli P, Geppeti P, et al. Involvement of a peripheral site of action in the early phase of neuropeptide depletion following capsaicin desensitization. *Brain Res*. 1987;436:402-406.
31. Jancsó N, Jancsó-Gabor A, Szolcsanú J. Direct evidence for neurogenic inflammation and its prevention by denervation and by pretreatment with capsaicin. *Br J Pharmacol*. 1967;31:138-151.
32. Jessel TM, Iversen LL, Cuello AC. Capsaicin induced depletion of substance P from primary sensory neurones. *Brain Res*. 1977;152:183-188.
33. Tervo K. Effect of prolonged and neonatal capsaicin treatments of the substance P immunoreactive nerves in the rabbit eye and spinal cord. *Acta Ophthalmol*. 1982;59:737-746.
34. Fujita S, Shimizu T, Izumi K, Fukuda T, Sameshima M, Ohba N. Capsaicin-induced neuroparalytic keratitis-like corneal changes in the mouse. *Exp Eye Res*. 1984;38:165-175.
35. Shimizu T, Izumi K, Fujita S, et al. Capsaicin-induced corneal lesions in mice and the effects of chemical sympathectomy. *J Pharmacol Exp Ther*. 1987;243:690-695.
36. Ogilvy CS, Silverberg KR, Borges LF. Sprouting of corneal sensory fibers in rats treated at birth with capsaicin. *Invest Ophthalmol Vis Sci*. 1991;32:112-121.
37. Marfurt CF, Ellis LC, Jones MA. Sensory and sympathetic nerve sprouting in the rat cornea following neonatal administration of capsaicin. *Somatosensory Motor Res*. 1993;10:377-398.
38. Gallar J, Pozo MP, Rebollo I, Belmonte C. Effects of capsaicin on corneal wound healing. *Invest Ophthalmol Vis Sci*. 1990;31:1968-1974.
39. Pannabecker CL. Keratitis neuroparalytica. *Arch Ophthalmol*. 1944;32:456-463.
40. Schicho R, Skofitsch G, Donnerer J. Regenerative effect of human recombinant NGF on capsaicin-lesioned sensory neurons in the adult rat. *Brain Res*. 1999;815:60-69.
41. Donnerer J, Amann R, Schuligoi R, Skofitsch G. Complete recovery by nerve growth factor of neuropeptide content and function in capsaicin-impaired sensory neurons. *Brain Res*. 1996;741:103-108.
42. Schmelz M, Schmidt R, Ringkamp M, Foster C, Handwerker HO, Torebjork EH. Limitation of sensitization to injured parts of receptive field in human skin C-nociceptors. *Exp Brain Res*. 1996;109:141-147.
43. Cavanagh HD, Petroll WM, Alizadeh H, He Y-G, McCulley JP, Jester JV. Clinical and diagnostic use of in vivo confocal microscopy in patients with corneal diseases. *Ophthalmology*. 1993;100:1444-1454.
44. Møller-Pedersen T, Vogel M, Li HF, Petroll WM, Cavanagh HD, Jester JV. Quantification of stromal thinning, epithelial thickness, and corneal haze after photorefractive keratectomy using in vivo confocal microscopy. *Ophthalmology*. 1997;104:360-368.
45. Belmonte C, Acosta MC, Schmelz M, Gallar J. Measurement of corneal sensitivity to mechanical and chemical stimulation with a CO₂ esthesiometer. *Invest Ophthalmol Vis Sci*. 1999;40:513-519.
46. Lambiase A, Bonini S, Bonini S, et al. Increased plasma levels of nerve growth factor in vernal keratoconjunctivitis and relationship to conjunctival mast cells. *Invest Ophthalmol Vis Sci*. 1995;36:2127-2132.
47. Draize JH. *Appraisal of the Safety of Chemicals in Foods, Drugs, and Cosmetics*. Austin, Texas: Association of Food and Drug Officials of the United States; 1959.
48. Cochet P, Bonnet R. L'esthésie cornéenne. *Clin Ophthalmol*. 1960;4:3-27.
49. van Setten G-B, Viinikka L, Tervo T, Pesonen K, Tarkkanen A, Perheentupa J. Epidermal growth factor is a constant component of normal human tear fluid. *Graefes Arch Clin Exp Ophthalmol*. 1989;27:184-187.
50. Vesaluoma M, Tervo T. Tenascin and cytokines in tear fluid after photorefractive keratectomy. *J Refract Surg*. 1998;14:447-454.
51. Jester JV, Li H-F, Petroll WM, et al. Area and depth of surfactant-induced corneal injury correlates with cell depth. *Invest Ophthalmol Vis Sci*. 1998;39:922-936.

52. Zollman TM, Bragg R, Harrison DA. Clinical effects of oleoresin capsicum (pepper spray) on the human cornea and conjunctiva. [ARVO Abstract.] *Invest Ophthalmol Vis Sci.* 1999;40(4):S338. Abstract nr 1797.
53. Gallar J, Pozo MA, Tuckett RP, Belmonte C. Response of sensory units with unmyelinated fibres to mechanical, thermal and chemical stimulation of the cat's cornea. *J Physiol.* 1993;468:609-622.
54. Caterina MJ, Schumacher MA, Tominaga M, Rosen TA, Levine JD, Julius D. The capsaicin receptor: a heat-activated ion channel in the pain pathway. *Nature.* 1997;389:816-824.
55. Tominaga M, Caterina MJ, Malmberg AB, et al. The cloned capsaicin receptor integrates multiple pain-producing stimuli. *Neuron.* 1998;21:531-543.
56. Szallasi A, Blumberg PM. Vanilloid (capsaicin) receptors and mechanisms. *Pharmacol Rev.* 1999;51:159-211.
57. Guenther S, Reeh PW, Kress M. Rises in $[Ca^{2+}]$ mediate capsaicin- and proton-induced heat sensitization of rat primary nociceptive neurons. *Eur J Neurosci.* 1999;11:3143-3150.
58. Waldmann R, Champigny G, Bassilana F, Heurteaux C, Lazdunski M. A proton-gated cation channel involved in acid-sensing. *Nature.* 1997;386:173-177.
59. Snider WD. Functions of the neurotrophins during nervous system development: what the knockouts are teaching us. *Cell.* 1994;77:627-638.
60. Johnson EM, Gorin PD, Brandeis LD, Pearson J. Dorsal root ganglion neurons are destroyed by exposure in utero to maternal antibody to nerve growth factor. *Science.* 1980;219:916-918.
61. Smeyne RJ, Klein R, Schnapp A, et al. Severe sensory and sympathetic in mice carrying a disrupted Trk/NGF receptor gene. *Nature.* 1994;368:246-249.
62. De Castro F, Silos-Santiago I, Lopez de Armentia M, Barbacid C, Belmonte C. Corneal innervation and sensitivity to noxious stimuli in trkA knockout mice. *Eur J Neurosci.* 1998;10:146-152.
63. Davies AM. The role of neurotrophins in the developing nervous system. *J Neurobiol.* 1994;25:1334-1148.
64. Westkamp G, Otten U. An enzyme-linked immunoassay for nerve growth factor (NGF) a tool for studying regulatory mechanisms involved in NGF production in brain and peripheral tissues. *J Neurochem.* 1987;48:1779-1786.
65. Oddiah D, Annand P, McMahon SB, Rattray M. Rapid increase of NGF, BDNF and NT-3 mRNAs in inflamed bladder. *Neuroreport.* 1998;9:1455-1458.
66. Lewin GR, Ritter AM, Mendell LM. Nerve growth factor-induced hyperalgesia in the neonatal and adult rat. *J Neurosci.* 1993;13:2136-2148.
67. Lambiase A, Manni L, Bonini S, Rama P, Micera A, Aloe L. Nerve growth factor promotes corneal healing: structural, biochemical and molecular analysis on rat and human cornea. *Invest Ophthalmol Vis Sci.* In press.
68. Garcia-Hirschfeld J, Lopez-Briones LG, Belmonte C. Neurotrophic influences on corneal epithelial cells. *Exp Eye Res.* 1994;59:597-605.
69. Lambiase A, Rama P, Bonini S, Caprioglio G, Aloe L. Topical treatment with nerve growth factor for corneal neurotrophic ulcers. *N Engl J Med.* 1998;338:1174-1180.
70. Müller LJ, Pels E, Vrensen GFJM. Ultrastructural organization of human corneal nerves. *Invest Ophthalmol Vis Sci.* 1996;37:476-488.
71. Müller LJ, Vrensen GFJM, Pels E, Nunes Cardozo B, Willekens B. Architecture of human corneal nerves. *Invest Ophthalmol Vis Sci.* 1997;38:985-994.