

Optical Response to LASIK Surgery for Myopia from Total and Corneal Aberration Measurements

Susana Marcos,¹ Sergio Barbero,¹ Lourdes Llorente,¹ and Jesús Merayo-Llodes²

PURPOSE. To evaluate the optical aberrations induced by LASIK refractive surgery for myopia on the anterior surface of the cornea and the entire optical system of the eye.

METHODS. Total and corneal aberrations were measured in a group of 14 eyes (preoperative myopia ranging from -2.5 to -13 D) before and after LASIK surgery. Total aberrations were measured using a laser ray-tracing technique. Corneal aberrations were obtained from corneal elevation maps measured using a corneal system and custom software. Corneal and total wave aberrations were described as Zernike polynomial expansions. Root-mean-square (RMS) wavefront error was used as a global optical quality metric.

RESULTS. Total and corneal aberrations (third-order and higher) showed a statistically significant increase after LASIK myopia surgery, by a factor of 1.92 (total) and 3.72 (corneal), on average. This increase was more pronounced in patients with the highest preoperative myopia. There is a good correlation ($r = 0.97$, $P < 0.0001$) between the aberrations induced in the entire optical system and those induced in the anterior corneal surface. However, the anterior corneal spherical aberration increased more than the total spherical aberration, suggesting also a change in the spherical aberration of the posterior corneal surface. Pupil centration and internal optical aberrations, which are not accounted for in corneal topography, play an important role in evaluating individual surgical outcomes.

CONCLUSIONS. Because LASIK surgery induces changes in the anterior corneal surface, most changes in the total aberration pattern can be attributed to changes in the anterior corneal aberrations. However, because of individual interactions of the aberrations in the ocular components, a combination of corneal and total aberration measurements is critical to understanding individual outcomes, and by extension, to designing custom ablation algorithms. This comparison also reveals changes in the internal aberrations, consistent with the posterior corneal changes reported using scanning slit corneal topography. (*Invest Ophthalmol Vis Sci.* 2001;42:3349-3356)

From the ¹Instituto de Optica "Daza de Valdés," Consejo Superior de Investigaciones Científicas (CSIC), Madrid, Spain; and the ²Instituto de Oftalmobiología Aplicada, Universidad de Valladolid, Spain.

Supported by Grants TIC98-0925-C02-01 from the Ministerio de Educación y Cultura, Spain, and CAM08.7/0010.1/2000 from the Consejería de Educación de la Comunidad Autónoma de Madrid, Spain. Carl Zeiss, S.A., Spain, lent a Mastervue Atlas Corneal Topography unit and partially funded a CSIC fellowship (SB). LL was funded by a fellowship from Comunidad Autónoma de Madrid, Spain.

Submitted for publication May 23, 2001; revised July 13, 2001; accepted August 2, 2001.

Commercial relationships policy: N.

The publication costs of this article were defrayed in part by page charge payment. This article thus therefore be marked "advertisement" in accordance with 18 U.S.C. §1734 solely to indicate this fact.

Corresponding author: Susana Marcos, Instituto de Optica, CSIC, Serrano 121, Madrid 28006, Spain. susana@io.cfmac.csic.es

Laser in situ keratomileusis (LASIK)^{1,2} has become a popular surgical alternative for the correction of myopia, and a rapidly increasing number of LASIK procedures are performed daily worldwide. In this technique, a hinged flap is created and folded back, and the exposed stroma is photoablated using an excimer laser. In LASIK for myopia, stromal tissue is removed so that the curvature of the central cornea is flattened to compensate for the excessive refractive power or longer axial length of the myopic eye. Most of the published studies evaluate the clinical outcomes of LASIK in terms of visual performance (visual acuity or contrast sensitivity).^{3,4} Some reports evaluate the microstructural changes induced in the stroma and Bowman layer by means of in vivo confocal microscopy.⁵ However, there are still many open questions regarding the wound-healing process⁶ and the biologic response of the cornea to ablation.^{7,8}

Recently, the implementation of techniques to precisely measure the optical wave aberration pattern⁹⁻¹⁶ before and after refractive surgery has generated significant excitement among specialists in refractive surgery. First, the measurement of optical defects (aberrations) after refractive surgery has revealed that, although conventional refractive errors (i.e., myopia or astigmatism) are reduced or canceled, higher order aberrations (uncorrectable by conventional means) are generally induced.¹⁷⁻²⁰ Second, along with other technical developments (e.g., scanning small-spot lasers, eye trackers), the precise measurement of ocular wave aberrations has opened the potential for improved refractive surgery that is customized for each patient and intended to cancel both low- and high-order aberrations in the eye.²¹⁻²⁴ Two approaches are currently being pursued, both to evaluate and to guide ablation procedures: wavefront aberrations (aberrations of the entire optical system)^{18,21} and corneal topography²⁵⁻²⁷ (alternatively, aberrations of the anterior corneal surface). Analysis of the total aberrations of the eye provides the most direct and complete measurement of retinal image quality and therefore can be directly related to visual performance. Previous studies show high correlations between corneal aberrations (wavefront variance) and visual performance (area under contrast sensitivity function).²⁸

We have shown that most of the decrease in contrast sensitivity found after LASIK can be explained by a decrease in the modulation-transfer function computed directly from the wave aberration.²⁹ However, because in refractive surgery changes are induced only in the cornea, the question arises whether corneal topography would be sufficient to fully predict visual outcomes.⁷ In this article, we present corneal and total aberrations in the same eyes before and after LASIK for myopia. We show that the combination of these two pieces of information is important in understanding individual surgical outcomes (which becomes critical in customizing ablation algorithms). It also provides insights into the biomechanical response of the cornea (both the anterior and posterior surfaces) to laser refractive surgery.

METHODS

Patients

Fourteen eyes of eight patients (two men and six women; mean age, 28.9 ± 5.4 years) were measured before (28 ± 35 days) and after ($59 \pm$

23 days) LASIK surgery. The preoperative spherical refractive error ranged from -2.5 to -13 D (mean, -6.8 ± 2.9 D), and preoperative astigmatism was less than 2.5 D. Postoperative recovery was uneventful, and none of the patients was retreated. The procedures were reviewed and approved by institutional bioethics committees and met the tenets of the Declaration of Helsinki. All patients were fully informed and understood and signed an informed consent before enrollment in the study. Aberration measurements were conducted at Instituto de Optica, Consejo Superior de Investigaciones Cientificas (CSIC), Madrid, Spain. Generally, both types of measurements (total and corneal aberrations) were obtained bilaterally in one experimental session.

LASIK Surgery

Standard LASIK surgery was conducted using a narrow-beam, flying-spot excimer laser (Chiron Technolas 217-C equipped with the PlanoScan program; Bausch & Lomb Surgical, Madrid Spain). This laser has an emission wavelength of 193 nm, a fixed pulse repetition rate of 50 Hz, and a radiance exposure of 400 mJ. The procedure was assisted by an eye tracker. The flap diameter (performed with a Hansatome microkeratome; Bausch & Lomb España, SA, Madrid Spain) was 8.5 mm, and the intended depth was 180 μm . Photoablation was applied to a 6-mm optical zone, with a transition zone of 9 mm. The LASIK procedures were conducted at the Instituto de Oftalmobiología Aplicada, Universidad de Valladolid, Spain.

Total Aberrations Using LRT

Total wave aberrations were measured using laser ray tracing (LRT), developed at the Instituto de Optica in Madrid, Spain.¹² The principles^{30,31} and, in particular, its use as an evaluation tool in LASIK surgery for myopia, have been described in detail elsewhere.¹⁸ In this technique, a scanning system scans a narrow laser beam (543 nm) across the pupil. Simultaneously, a high-resolution charged-coupled device (CCD) camera captures the retinal spot images corresponding to each entry pupil location. Figure 1A shows a particular series of images after surgery in a LASIK-treated eye. The positions of the centroids of the set of retinal images form a spot diagram (Fig. 1B). The deviations of each centroid from the principal ray are proportional to the local slopes of the wave aberration. Each run consists of 37 rays, sampling a 6.5-mm pupil in 1-mm steps in a hexagonal pattern, and lasts 4 seconds. Each measurement is repeated five times.

Aberration measurements were obtained after pupil dilation with 1 drop tropicamide 1%. Subjects' heads were stabilized with a dental impression and a headrest, and the pupil was continuously monitored on a CCD camera to ensure proper alignment of the pupil center to the optical axis of the instrument. Spherical refractive errors were corrected with trial lenses when necessary. The raw data (derivatives of the wave aberration) were fitted to a seventh-order Zernike (Z) polynomial, and the wave aberration was obtained using a least-mean-squares procedure. We used the root-mean-square (RMS) wavefront to assess global optical quality and its change with LASIK. We analyzed either individual Zernike (Z) terms (i.e., Z_4^0 , spherical aberration) or the RMS for third-order terms and higher, i.e., excluding piston (Z_0^0), tilts (Z_1^1 and Z_1^{-1}), defocus (Z_2^0) and astigmatism (Z_2^2 and Z_2^{-2}), and for isolated Z terms. In these groups of patients, Zernike coefficient SD (averaged across terms) ranged from 0.026 to 0.170 μm (mean, 0.069 ± 0.037 μm [SD]).

Corneal Aberrations from Corneal Topography

Corneal height numerical data were obtained with a corneal topography system (Atlas Mastervue; Humphrey Instruments-Zeiss, San Leandro, CA). These data were processed using custom software (Matlab; Mathworks, Natick, MA) and exported to an optical design program (Zemax ver. 9; Focus Software, Tucson, AZ), which performed a ray-tracing simulation to compute corneal aberrations from corneal topography data.³²⁻³⁵ This technique has been validated in recent

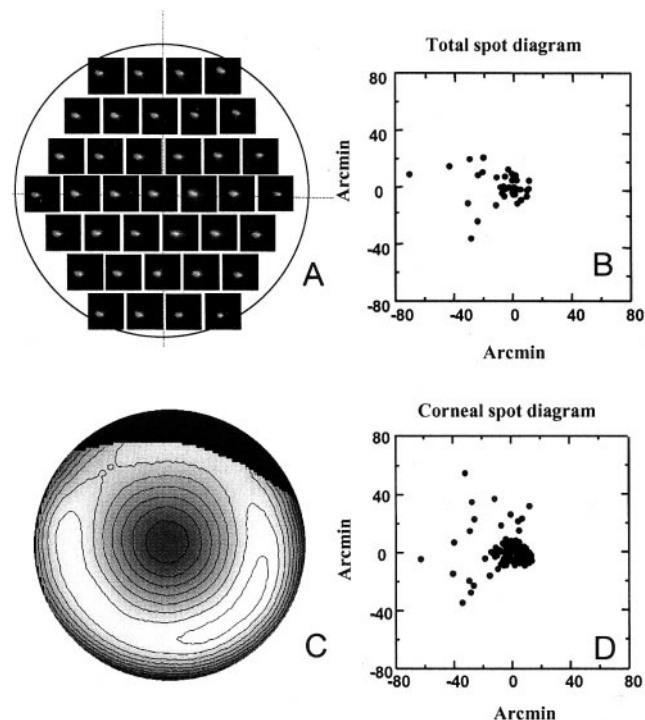


FIGURE 1. (A) Set of aerial images in post-LASIK eye 10, as a function of entry pupil as recorded in LRT. (B) Retinal angular position of all centroids (spot diagram) from the series of retinal images shown in (A). The deviations from the principal ray are proportional to the local derivatives of the wave aberration. (C) Corneal elevation map (10-mm pupil, centered at the corneal reflex) from corneal topography data (eye 10). Terms 1 to 6 in the Zernike expansion have been excluded to reveal high-order features. Contours plotted every 0.01 mm. (D) Simulated spot diagram from virtual ray tracing on a 6.5-mm diameter region of the corneal map shown in (C). This subregion is centered at the pupil center, not the corneal reflex.

studies of keratoconus and aphakia.³⁶ Both the corneal surface and the corneal aberration pattern (at the plane of best focus) were described by a Zernike polynomial expansion. We checked that a seventh-order polynomial expansion represented a good description of the surface: the RMS error of the fitting was 0.43 ± 0.11 before surgery and 0.53 ± 0.11 after surgery (average across the eyes of this study). This error is lower than the accuracy of the corneal topography devices, which can measure surfaces to an RMS error of 3.7 ± 0.7 μm .³⁷

Figure 1C shows a corneal elevation map (10-mm diameter, centered on the corneal reflex) for the same eye as in Figure 1A. To show the irregularities, we subtracted the first six terms of a Zernike polynomial fit to the height data from the raw height data.³⁴ Ray aberrations were obtained by virtual ray tracing, sampling 64×64 points of the corneal surface (in a rectangular grid). Figure 1D shows a spot diagram corresponding to a subset of 91 rays, through a 6.5-mm corneal region centered at -0.6 to $+0.6$ mm from the corneal reflex. The indices of refraction were taken as that of the air and the aqueous humor (1.3391). For this analysis, the corneal index of refraction was not considered. Wavelength was set to 543 nm (as in the LRT measurements). Unlike the LRT measurements (for which the reference was the pupil center), corneal topography typically uses the corneal reflex (location of the first Purkinje image when the subject fixates foveally) for alignment. Proper alignment of corneal and total aberration is necessary for direct comparison.

We developed custom software to locate the colinear pupil position.³⁶ Corneal aberrations were computed over a large pupil diameter (10 mm) and recomputed over a 6.51-mm pupil (matching the pupil size of total aberration measurements), moving the center over a

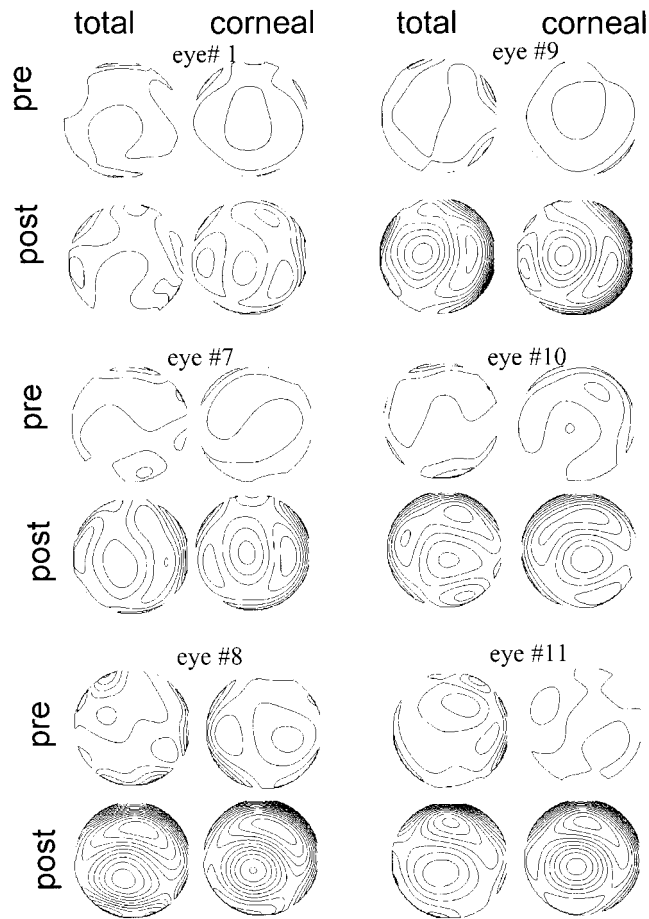


FIGURE 2. Total and corneal wave aberration contour plots (third-order and higher aberrations), before (pre) and after (post) LASIK in a subset of eyes. Contour lines have been plotted every 1 μm . Pupil size is 6.5 mm.

± 1 -mm grid, in 0.1-mm steps. A difference total-corneal map was computed for each pupil location. These maps were smooth and in all cases showed a clear, single minimum—typically, slightly decentered from the corneal reflex. Despite the underlying assumptions, independent observations³⁶ in control subjects showed that this procedure identifies well the pupil center (inaccessible otherwise from the corneal topography images). Apart from the decentration between the corneal reflex and pupil center, the keratometric axis is tilted with respect to the line of sight. This angle can be computed by measuring the distance between the corneal intersect of the keratometric axis and corneal sighting center (not available in our patients) and using the fixation point distance. Mandell³⁸ reported an average difference of 0.38 ± 0.10 mm between the corneal intersect of the keratometric axis and the corneal sighting center across 20 normal eyes. Assuming similar values in our group of eyes and for the 148.3-mm fixation point distance in our videokeratoscope, the neglected corneal tilt is approximately 0.15° . For a typical cornea (eye 10) we found that, considering this tilt, RMS changes by only 2.7% before surgery and 0.68% after surgery for third-order Z terms and by 0.46% before surgery and 0.15% after surgery for spherical aberration (Z_4^0).

In this particular experiment, we obtained only one corneal map per eye and per session. Experiments in one control eye (RMS = 0.59 μm , for third- and higher order terms) showed a Zernike coefficient SD of 0.016 (averaged across terms). Experimental centration errors (SDs) were 0.08 mm for the horizontal coordinate and 0.08 mm for the vertical coordinate.

RESULTS

Total and Corneal Wave Aberration Patterns

Figure 2 shows contour plots of wave aberration patterns for total and corneal aberrations before and after LASIK surgery, in six eyes. Piston, tilts, defocus, and astigmatism have been excluded in all cases, so that these patterns represent simulated best corrected optical quality. Pupil diameter is 6.51 mm, and contour lines are plotted every 1 μm . There was a clear deterioration (accounting for an increase in the number of contour lines) after surgery, both for total and corneal aberrations. Before surgery, total and corneal aberrations showed similarities in only some of the eyes, whereas after surgery, total and corneal aberrations showed very similar patterns, indicating the prevalence of corneal defects over the entire optics. LASIK induced a round central area (with various amounts of decentration, depending on the eye) of positive aberration, surrounded by an area of negative aberration.

Comparison of the Change in Total and Corneal Aberrations with LASIK

RMS wavefront error increased with LASIK, both for total and corneal aberrations. Figure 3 shows RMS before and after LASIK for third- and higher order aberrations—that is, best corrected for defocus and astigmatism. Figure 3A shows the change for total aberrations and Figure 3B the change for corneal aberrations. The eyes were sorted by increasing preoperative spherical refractive error. Before surgery, total aberrations tend to increase with myopia,^{39,40} although this tendency was not evident in corneal aberrations. Both total and corneal aberrations increased significantly after LASIK, except for eyes 5 and 6 for total aberrations, and eye 4 for corneal aberrations. Clearly, for both total and corneal aberrations the increase was much more pronounced in the most myopic eyes.

Total aberrations increased on average by a factor of 1.92 and corneal aberrations by a factor of 3.72. For the low pre-

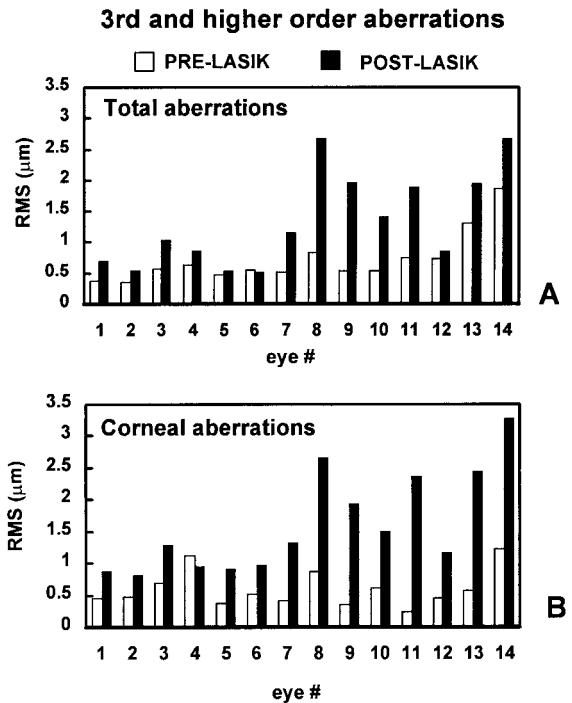


FIGURE 3. RMS wavefront error for third-order and higher aberrations, before and after LASIK for (A) total and (B) corneal aberrations. Eyes have been sorted by increasing preoperative spherical error.

operative myopia group (-2.5 to -6.5 D) the average increase was 1.53 (total) and 1.97 (corneal), whereas for the high preoperative myopia group (-6.8 to -13.1 D) the average increase was 2.29 (total) and 4.37 (corneal). In terms of RMS differences (before minus after surgery), total RMS difference changed from -0.05 to 0.80 μm , reaching statistical significance in 11 of the 14 eyes, and corneal RMS changed from -0.16 to 2.04 μm , statistically significant in 13 of the 14 eyes. Part of this increase is accounted for by an increase in the third-order aberrations (increasing by a factor of 1.98 for total and 2.73 for corneal) and by an increase of the fourth-order aberrations (increasing by a factor of 2.54 for total and 3.93 for corneal).

Figure 4 shows the change of the fourth-order spherical aberration coefficient (Z_4^0), both total (Fig. 4A) and corneal (Fig. 4B). Sign and normalization follow the convention suggested by the Optical Society of America Standardization Committee.⁴¹ The preoperative total spherical aberration coefficient was close to zero in most eyes (significantly positive in seven eyes and significantly negative in three eyes). Preoperative corneal spherical aberration was positive in all eyes, except for one that was not significantly different from zero. Total spherical aberration increased significantly with LASIK in all eyes and corneal spherical aberration in all but one eye. The most dramatic increase occurred in patients with the highest

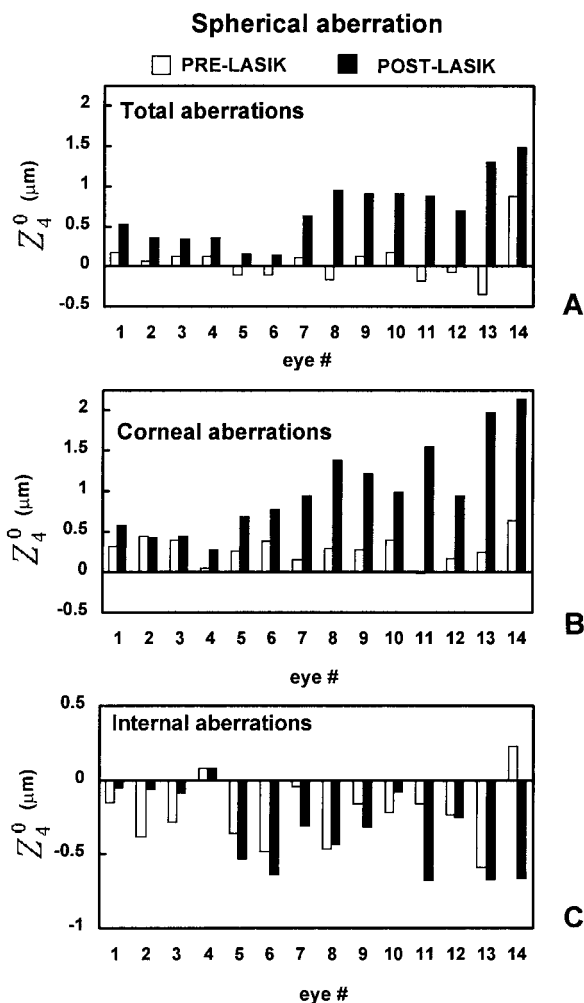


FIGURE 4. Fourth-order spherical aberration coefficient (Z_4^0 in the Zernike polynomial expansion), before and after LASIK for (A) total, (B) corneal, and (C) internal aberrations. Eyes have been sorted by increasing preoperative spherical error.

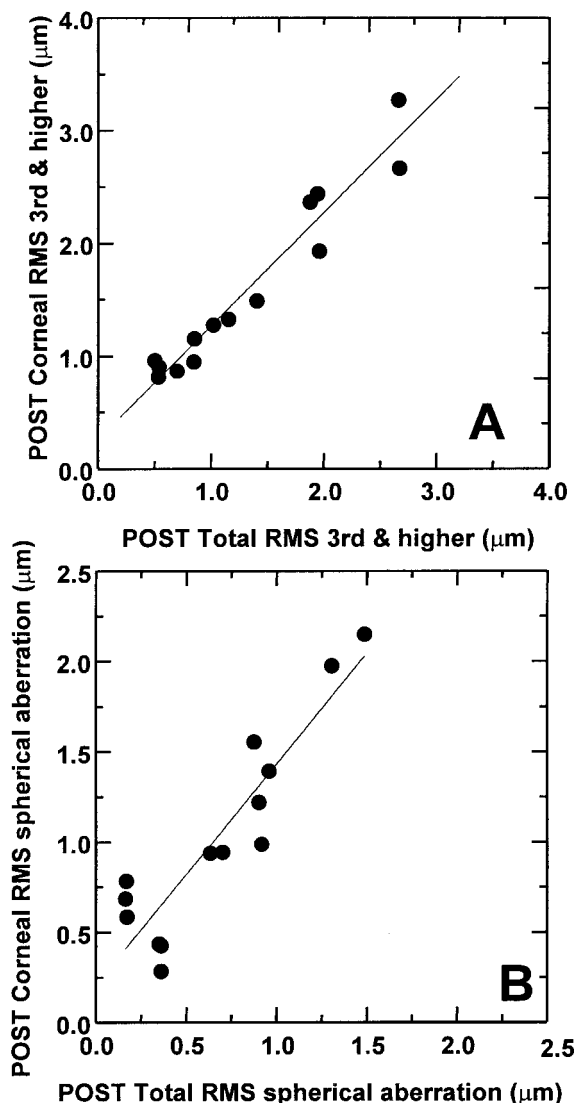


FIGURE 5. Total aberrations versus corneal aberrations induced by LASIK, in terms of RMS wavefront error. (A) Third-order and higher aberrations. (B) Spherical aberration. Lines are linear regressions of the data.

preoperative myopia, both for total¹⁸ and corneal aberrations.^{33,42} Total spherical aberration Z_4^0 coefficient for the preminus postoperative difference ranged from 0.22 to 1.64 μm (0.63 μm , on average), and for the cornea the differences ranged from -0.01 to 1.72 μm (0.74 μm on average). The increase of spherical aberration seems to be more pronounced for corneal than for total aberrations.

Figure 5 shows post-LASIK corneal versus total aberrations, Figure 5A for third-order and higher aberration RMS (i.e., data in black bars) and Figure 5B for RMS for spherical aberration (i.e., roughly the modulus of the data in black bars in Fig. 4, although not exactly, because it includes the contribution of Z_6^0 also). There was a very good correlation between corneal and total aberrations (third-order and higher) after LASIK ($r = 0.97$, $P < 0.0001$; slope = 1.01 ; Fig. 5A). The corneal spherical aberration after LASIK was also well correlated to the total spherical aberration after LASIK ($r = 0.91$, $P < 0.0001$; slope = 1.22 ; Fig. 5B). However, that the slope is significantly higher than 1 suggests that a larger spherical aberration is induced in the anterior corneal surface than in the entire eye. A higher slope in the post-LASIK corneal versus total aberration was

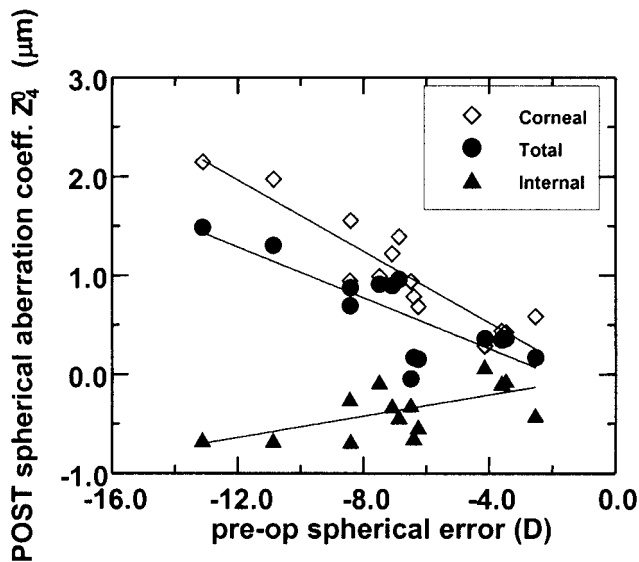


FIGURE 6. Total, corneal, and internal spherical aberration after LASIK as a function of preoperative spherical error. Lines are linear regressions of the data.

found for the RMS of the spherical aberration, the spherical aberration coefficient (Z_4^0), and the RMS of fourth-order Z terms, but not for third-order aberrations or all high-order aberrations (third-order and higher).

Change of Internal Aberrations with LASIK

The internal aberrations can be computed by subtracting corneal from total aberration coefficients. Figure 4C shows the internal aberrations before and after LASIK. We found that internal spherical aberration changed significantly in 10 eyes after LASIK. Except for the four less myopic eyes (eyes 1-4) and eye 10, the internal spherical aberration changed toward more toward the negative. Experiments performed in control subjects who had undergone a surgical procedure performed in two different experimental sessions (separated by at least 1 month, as in the surgical eyes) did not reveal statistically significant changes in the internal aberrations across sessions. This indicates that possible changes across sessions in the accommodative state or decentrations of corneal topography data (which otherwise are compensated by the recenteration algorithm) cannot account for the observed differences in the internal optics found between pre- and post-LASIK results. Therefore these changes must be attributable to surgery.

Figure 6 shows the spherical aberration coefficient Z_4^0 after LASIK as a function of preoperative spherical refractive error, for corneal, total, and internal aberrations. The internal aberration coefficients were computed as the total minus the corneal coefficients. There was a statistically significant increase of the absolute amount of postoperative spherical aberration for total ($r = 0.80, P = 0.0003$), corneal ($r = 0.92, P < 0.0001$), and internal ($r = 0.73, P = 0.0024$) aberrations with preoperative refractive error. However, the total spherical aberration increased less than the spherical aberration in the anterior corneal surface, because of the spherical aberration of negative sign induced on the posterior corneal surface. The same analysis for post-LASIK third-order aberrations shows no statistically significant difference between corneal and total aberrations. Therefore, third-order aberrations do not seem to be induced in the posterior corneal surface.

DISCUSSION

Both corneal and total aberrations increased after LASIK surgery for myopia. The higher the preoperative myopia, the higher the increase. In general, although the trends are similar when looking at third-order and higher aberrations, we found that the spherical aberration in the anterior corneal surface was greater than that in the entire eye. In the following sections, we will discuss several other factors that indicate that anterior corneal aberrations alone are not sufficient to explain surgical outcomes. We will also relate our findings to those in current biomechanical models of corneal response to surgery and previous observations. We will finally discuss the implications of these results in the evaluation of refractive surgery outcomes and aberration-free ablation procedures.

Role of Pupil Centration

Several studies have shown the impact of refractive surgery for myopia (radial keratotomy [RK] and photorefractive keratectomy [PRK]) on corneal aberrations.^{25,33,43} As in the present analysis, those studies computed the corneal aberration pattern by measuring corneal elevation maps using commercial corneal videokeratoscopes. In these devices, centration is typically achieved by aligning a set of concentric rings to the corneal reflex of the fixation light. Corneal aberrations are then typically referred to the corneal reflex rather than the pupil center. Our processing algorithms align the corneal aberration pattern with the total aberration pattern, which is referred to the pupil center. The position of the pupil is important for a correct estimation of retinal image quality⁴⁴ and should be taken into account when predicting visual performance from corneal aberration data. According to our computations, corneal aberration data (third-order and higher) changed by 10% when the pupil position was taken into account. Although, as expected, spherical aberration did not change significantly by recenteration (3% on average), third-order aberrations changed by 22%. Figure 7 shows the corneal aberration pattern for the same post-LASIK eye (eye 10), centered at the corneal reflex (Fig. 7, right; as directly processed from the corneal topographer raw data) and at the pupil center (left). First- and second-order Z terms (which also changed with decentration) are excluded in each map. Although direct corneal data show no coma, when the actual pupil position is taken into account, we observed that coma is predominant along with spherical aberration.

Role of Preoperative Internal Optics

Total aberrations result from the combination of corneal and internal aberrations and their inter-relationships. Before surgery, both components contributed comparable amounts of

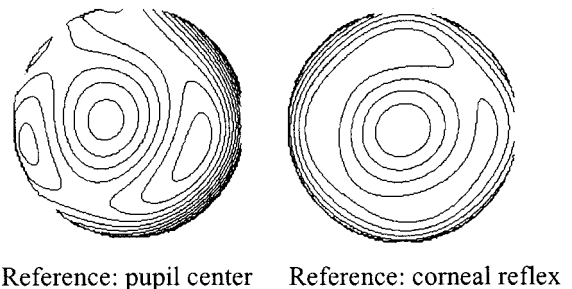


FIGURE 7. Corneal wave aberration contour maps for eye 10, after surgery, centered at the pupil center, after realignment (left) and centered at the corneal reflex (right), directly from corneal topography data without realignment. Contour line spacing: 1 micrometers. Pupil diameter: 6.5 mm. Piston, tilt, defocus, and astigmatism excluded to minimize the RMS wavefront error in each map.

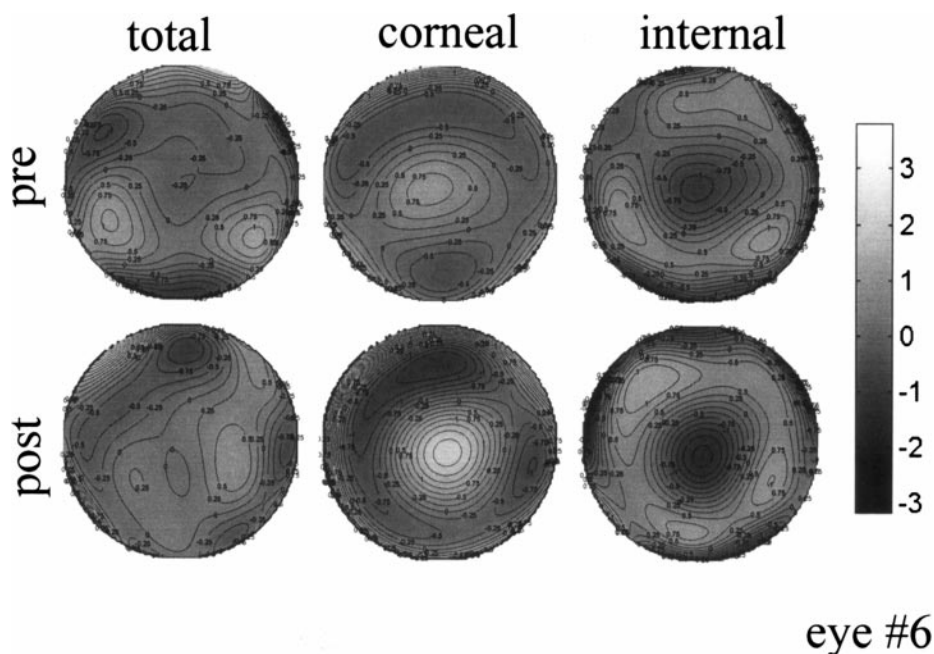


FIGURE 8. Total (*left*), corneal (*middle*), and internal (*right*) wave aberration maps (third-order and higher aberrations) before (*top*) and after (*bottom*) LASIK, for eye 6 (with a particularly good surgical outcome). Before surgery, the negative internal aberration dominates the total pattern. After LASIK, the positive spherical aberration induced on the anterior corneal surface partially cancels the preoperative negative spherical aberration of the internal optics. Contour line spacing: $0.25 \mu\text{m}$; pupil diameter: 6.5 mm.

aberrations—in some cases even balancing each other. Figure 2 shows that whereas before surgery the cornea dominated the total wave aberration pattern in some eyes (i.e., eye 1 or 7), in some others there was little similarity between total and corneal patterns, indicating an important contribution of the internal optics. Although the relative contribution of the internal optics is expected to be much lower after refractive surgery, interactions between corneal and internal optics may still play some role in determining the surgical outcomes. A recent study⁴⁵ indicates a high degree of balance between corneal and internal aberrations in normal young eyes. Before surgery, we found a term-by-term balance of at least 50% of the aberration in 28% of the 14 eyes of this study. For spherical aberration, this balance increased to 57% of the eyes. In 78% of the eyes, the spherical aberration of the anterior corneal surface and the internal optics had a different sign (Fig. 4, white bars).

Furthermore, it is not uncommon (35%) that the amount of negative internal spherical aberration (likely from the crystalline lens^{46,47}) exceeds the amount of positive spherical aberration of the anterior corneal surface. Figure 8 illustrates one of these cases (eye 6), with a corneal preoperative spherical aberration (Z_4^0) of $0.38 \mu\text{m}$ and internal preoperative aberration of $-0.48 \mu\text{m}$. The upper row shows the measured total and corneal and the computed internal aberration patterns. The negative internal aberration dominates the central area total aberration pattern. After LASIK (lower row), positive spherical aberration is induced on the anterior corneal surface, which cancels (actually overcompensates) the preoperative negative spherical aberration of the internal optics. For this reason, the post-LASIK total aberration pattern for this eye is much better than predicted from corneal aberrations alone. Unlike other subjects with similar preoperative myopia and similar corneal topography after LASIK, this subject did not show any loss of contrast sensitivity (actually improved at two spatial frequencies).²⁹

An individual comparison of pre- and postsurgical total and corneal aberration can be invoked to explain the surprisingly good surgical outcomes in this patient. In general, the possible balance between corneal and internal aberration gets disrupted with refractive surgery. In our study, compensation of more than 50% of the corneal spherical aberration by the preoperative internal aberrations decreased from eight eyes before sur-

gery to four eyes after surgery and only happened in eyes with the lowest preoperative spherical errors (eyes 2, 3, 5, and 6). However, at least in these eyes, these interactions are relevant in determining the total wave aberration pattern.

LASIK-Induced Posterior Corneal Aberrations and Biomechanical Response

Comparison of post-LASIK corneal and total aberrations revealed an increase in the amount of negative internal spherical aberration, which tended to slightly attenuate the impact of the positive spherical aberration induced in the anterior corneal surface (Fig. 6). The effect was larger as the preoperative spherical refractive error increased and did not depend on the preoperative internal aberrations. The correlation coefficient of post-LASIK internal spherical aberration to pre-LASIK spherical refractive error is 0.73 ($P = 0.0024$) and of the induced internal spherical aberration (before minus after surgery) to pre-LASIK spherical refractive error is 0.74 ($P = 0.0016$). LASIK surgery is not likely to induce changes in the crystalline lens; the changes therefore seem to occur in the posterior corneal surface. The effect is only present for spherical aberration, but not for other terms.

This finding is consistent with recent reports using scanning slit corneal topography. They show posterior corneal surface changes of curvature after PRK for myopia⁴⁸ and LASIK,^{49,50} which produce a forward shift of the posterior corneal surface. This suggests that after LASIK and PRK the thinner, ablated cornea may bulge forward slightly, steepening the posterior corneal curvature. This effect has been thought to account for the regression toward myopia that is sometimes found after treatment, particularly in the patients with highest preoperative myopia.⁴⁸ We used a simple corneal model with aspherical surfaces and found that the observed mean changes of internal spherical aberrations are consistent with the changes in power and asphericity of the posterior corneal surface that have been reported recently. Seitz et al.⁵¹ found that the posterior central corneal power changed significantly from -6.28 to -6.39 D after LASIK, and the asphericity power changed from 0.98 to 1.14, in a group of eyes with preoperative spherical refractive error similar to those in our study (range: -1.00 to -15.50 , mean, -5.07 ± 2.81 D). For these data, we found that the

induced spherical aberration of the posterior corneal surface is $-0.103 \mu\text{m}$ —very similar to the change in internal spherical aberration that we measured experimentally ($-0.110 \mu\text{m}$, on average).

In summary, using a combination of aberrometry and anterior corneal topography, we showed that this change in the posterior corneal shape also produced a decrease of spherical aberration in comparison with that predicted from anterior corneal aberrations alone. Our results confirm that this biomechanical corneal response is correlated with the amount of preoperative myopia (or, equivalently, with the depth of corneal ablation). From previous studies,⁴⁹ it is likely that it also depends on the preoperative corneal thickness and intraocular pressure.

Implications

Our results have important implications for the evaluation outcomes in standard LASIK surgery for myopia, as well as for the design of wavefront-guided ablation procedures (designed to individual canceling preoperative aberrations). First, the results show that the combination of corneal and total aberrations is necessary to understand individual surgical outcomes and their impact on visual performance. In general, both corneal and total aberrations increased with surgery, but the particular increment depended on the individual subject. This is particularly critical in any aberration-free procedure, which cannot rely on the mean population response, but must be adapted to the individual patient. Second, total wavefront aberration measurements complement corneal topography information to gain insight into the biomechanical corneal response. Although the ablation is applied on the anterior corneal surface, our analysis revealed changes in the shape of the posterior corneal surface, assessed by the modification of its spherical aberration.

Acknowledgments

The authors thank Esther Moreno-Barriuso for inestimable contributions in the early stages of the study, Raúl Martín for initial help with corneal topography data acquisition, Ron Scharf and Steve Kaatmann (Humphrey Instruments-Zeiss) for kind assistance, Alex Nugent and Jamie McLellan for critical revision of the manuscript, Cynthia Roberts for interesting discussions, and two anonymous reviewers and a member of the editorial board for helpful suggestions.

References

- Pallikaris I, Papatzanaki M, Stathi E, Frenschok O, Georgiadis A. Laser in situ keratomileusis. *Lasers Surg Med.* 1990;10:463–468.
- Farah S, Azar D, Gurdal C, Wong J. Laser in situ keratomileusis: literature review of a developing technique. *J Cataract Refract Surg.* 1998;24:989–1006.
- Nakamura K, Bissen-Miyajima H, Toda I, Hori Y, Tsubota K. Effect of laser in situ keratomileusis correction on contrast visual acuity. *J Cataract Refract Surg.* 2001;27:357–361.
- Mutyala S, McDonald M, Scheinblum K, Ostrick M, Brint S, Thompson H. Contrast sensitivity evaluation after laser in situ keratomileusis. *Ophthalmology.* 2000;107:1864–1867.
- Vesaluoma M, Perez-Santonja J, Petroll W, Linna T, Alio J, Tervo T. Corneal stromal changes induced by LASIK for myopia. *Invest Ophthalmol Vis Sci.* 2000;41:369–376.
- Jester J, Petroll W, Cavanagh H. Corneal stromal wound healing in refractive surgery: the role of myofibroblasts. *Prog Retinal Eye Res.* 1999;18:311–356.
- Roberts C. Future challenges to aberration-free ablative procedures. *J Refract Surg.* 2000;16:623–629.
- Roberts C. The cornea is not a piece of plastic. *J Refract Surg.* 2000;16:407–413.

- Charman WN. Wavefront aberrations of the eye: a review. *Optom Vis Sci.* 1991;68:574–583.
- He JC, Marcos S, Webb RH, Burns SA. Measurement of the wavefront aberration of the eye by a fast psychophysical procedure. *J Opt Soc Am A.* 1998;15:2449–2456.
- Liang J, Grimm B, Goetz S, Bille JF. Objective measurement of wave aberrations of the human eye with the use of a Hartmann-Shack wave-front sensor. *J Opt Soc Am A.* 1994;11:1949–1957.
- Navarro R, Losada MA. Aberrations and relative efficiency of light pencils in the living human eye. *Optom Vis Sci.* 1997;74:540–547.
- Liang J, Williams DR. Aberrations and retinal image quality of the normal human eye. *J Opt Soc Am A.* 1997;14:2873–2883.
- Mierdel P, Krinke HE, Wiegand W, Kaemmerer M, Seiler T. Measuring device for determining monochromatic aberration of the human eye. *Ophthalmologie.* 1997;94:441–445.
- Howland HC, Howland B. A subjective method for the measurement of the monochromatic aberrations of the eye. *J Opt Soc Am A.* 1977;67:1508–1518.
- Webb RH, Penney CM, Thompson KP. Measurement of ocular wavefront distortion with a spatially resolved refractometer. *Appl Opt.* 1992;31:3678–3686.
- Seiler T, Kaemmerer M, Mierdel P, Krinke H-E. Ocular optical aberrations after photorefractive keratectomy for myopia and myopic astigmatism. *Arch Ophthalmol.* 2000;118:17–21.
- Moreno-Barriuso E, Merayo-Lloves J, Marcos S, Navarro R, Llorente L, Barbero S. Ocular aberrations before and after myopic corneal refractive surgery: LASIK-induced changes measured with laser ray tracing. *Invest Ophthalmol Vis Sci.* 2001;42:1396–1403.
- Campbell MW, Haman H, Simonet P, Brunette I. Dependence of optical image quality on refractive error: eyes after excimer laser photorefractive keratectomy (PRK) versus controls. *Invest Ophthalmol Vis Sci.* 1999;40(4):S7. Abstract nr 34.
- Thibos LN, Fao P, Xin Hong M. Clinical applications of the Shack-Hartmann aberrometer. *Optom Vis Sci.* 1999;76:817–825.
- McRae S, Schwiegerling J, Snyder SW. Customized and low spherical aberration corneal ablation design. *J Refract Surg.* 1999;15:246–248.
- Mrochen M, Kaemmerer M, Seiler T. Wavefront-guided laser in situ keratomileusis: early results in three eyes. *J Refract Surg.* 2000;16:116–121.
- McDonald M. Summit-autonomous custom cornea: laser in situ keratomileusis outcomes. *J Refract Surg.* 2000;16:617–618.
- Schwiegerling J, Snyder R. Custom photorefractive keratectomy ablations for the correction of spherical and cylindrical refractive error and higher-order aberration. *J Opt Soc Am A.* 1998;15:2572–2579.
- Oshika T, Klyce SD, Applegate RA, Howland HC, El Danasoury MA. Comparison of corneal wavefront aberrations after photorefractive keratectomy and laser in situ keratomileusis. *Am J Ophthalmol.* 1999;127:1–7.
- Applegate RA, Howland HC, Sharp RP, Cottingham AJ, Yee RW. Corneal aberrations and visual performance after radial keratotomy. *J Refract Surg.* 1998;14:397–407.
- Dausch D, Schroder E, Dausch S. Topography-controlled excimer laser photorefractive keratectomy. *J Refract Surg.* 2000;16:13–22.
- Applegate R, Hilmante LG, Howland H, Tu E, Starck T, Zayac E. Corneal first surface optical aberrations and visual performance. *J Refract Surg.* 2000;16:507–514.
- Marcos S. Aberrations and visual performance following standard laser vision correction. *J Refract Surg.* 2001;17:596–601.
- Moreno-Barriuso E, Marcos S, Navarro R, Burns SA. Comparing laser ray tracing, spatially resolved refractometer and Hartmann-Shack sensor to measure the ocular wavefront aberration. *Optom Vis Sci.* 2001;78:152–156.
- Navarro R, Moreno-Barriuso E. Laser ray-tracing method for optical testing. *Opt Lett.* 1999;24:1–3.
- Applegate RA, Hilmantel G, Howland HC. Corneal aberrations increase with the magnitude of radial keratotomy refractive correction. *Optom Vis Sci.* 1996;73:585–589.
- Oliver KM, Hermenger P, Corbett MC, et al. Corneal optical aberrations induced by photorefractive keratectomy. *J Refract Surg.* 1997;13:246–254.

34. Schwiegerling J, Greivenkamp JE. Using corneal height maps and polynomial decomposition to determine corneal aberrations. *Optom Vis Sci.* 1997;74:906-916.
35. Oshika T, Klyce SD, Applegate RA, Howland HC. Changes in corneal wavefront aberrations with aging. *Invest Ophthalmol Vis Sci.* 1999;40:1351-1355.
36. Barbero S, Marcos S, Martin R, Llorente L, Moreno-Barriuso E, Merayo-Llodes JM. Validating the calculation of corneal aberrations from corneal topography: a test on keratoconus and aphakic eyes [ARVO Abstract]. *Invest Ophthalmol Vis Sci.* 2001;42(4):S894. Abstract nr 4799.
37. Schultze R. Accuracy of corneal elevation with four corneal topography systems. *J Refract Surg.* 1998;14:100-104.
38. Mandell R. Locating the corneal sighting center from videokeratography. *J Refract Surg.* 1995;11:253-258.
39. Collins MJ, Wildsoet CF, Atchinson DA. Monochromatic aberrations and myopia. *Vision Res.* 1995;35:1157-1163.
40. Marcos S, Moreno-Barriuso E, Llorente L, Navarro R, Barbero S. Do myopic eyes suffer from larger amount of aberrations? In: Thorn F, Troilo D, Gwiazda J, eds. *Myopia 2000: Proceedings of the 8th International Conference on Myopia.* Boston, MA: Conference on Myopia 2000, Inc. 2000:118-121.
41. Thibos LN, Applegate RA, Schwiegerling JT, Webb RH, Members VST. Standards for reporting the optical aberrations of eyes. *Trends Opt Photon.* 2000;35:110-130.
42. Schwiegerling J, Snyder RW. Corneal ablation patterns to correct for spherical aberration in photorefractive keratectomy. *J Cataract Refract Surg.* 2000;26:214-221.
43. Martinez C, Applegate RA, Klyce S, McDonald MB, Medina JP, Howland HC. Effects of pupillary dilation on corneal optical aberrations after photorefractive keratectomy. *Arch Ophthalmol.* 1998;116:1053-1062.
44. Artal P, Marcos S, Iglesias I, Green DG. Optical modulation transfer function and contrast sensitivity with decentered small pupils. *Vision Res.* 1996;6:3575-3586.
45. Artal P, Guirao A. Contributions of the cornea and the lens to the aberrations of the human eye. *Opt Lett.* 1998;23:1713-1715.
46. Sami G, Berny F. Contribution of the crystalline lens to the spherical aberration of the eye. *J Opt Soc Am A.* 1973;63:205-211.
47. Smith G, Cox M, Calver R, Garner L. The spherical aberration of the crystalline lens of the human eye. *Vision Res.* 2001;15:235-243.
48. Naroo S, Charman W. Changes in posterior corneal curvature after photorefractive keratectomy. *J Cataract Refract Surg.* 2000;26:872-878.
49. Baek T, Lee K, Kagaya F, Tomidokoro A, Amano S, Oshika T. Factors affecting the forward shift of posterior corneal surface after laser in situ keratomileusis. *Ophthalmology.* 2001;108:317-320.
50. Bruno CR, Roberts CJ, Castellano D, Mahmoud A, Birnbaum L. Posterior corneal surface changes after laser in situ keratomileusis. *Invest Ophthalmol Vis Sci.* 2001;42(4):S605 Abstract nr 3252.
51. Seitz B, Torres F, Langenbucher A, Behrens A, Suarez E. Posterior corneal curvature changes after myopic laser in situ keratomileusis. *Ophthalmology.* 2001;108:666-673.