

Detection of Awareness with the Bispectral Index: Two Case Reports

Martin Luginbühl, M.D., D.E.A.A.,* Thomas W. Schnider, M.D., Ph.D.*

AWARENESS is a rare but potentially harmful incident during general anesthesia. The reported incidence is 0.2% in general surgery and up to 1.5% in obstetric¹ and cardiac² surgery. In a recent review, Ghoneim³ described several potential causes for anesthetic drug doses not being adequate to suppress awareness and offered a number of suggestions for prevention. Unrecognized interruption of anesthetic drug delivery was identified as an important contributing factor, and development of an awareness monitor was given as one proposed solution. Reliance on traditional vital signs has been shown to be ineffective in identifying such unexpected events in time to prevent intraoperative awareness.

The BIS monitor (Aspect Medical Systems, Inc., Newton, MA) provides a drug-independent index for sedation and hypnosis (Bispectral Index [BIS])⁴⁻⁶ that correlates with both the incidence of explicit (spontaneous recall) and implicit awareness (recall only after priming or hypnosis).⁷⁻⁹ A BIS between 40 and 60 is recommended for adequate depth of anesthesia,¹⁰ and at a value higher than 80, patients regain consciousness. We report two cases of explicit awareness of events during anesthesia due to interrupted anesthetic drug delivery.

Case Reports

Case 1

An 80-yr-old woman (American Society of Anesthesiologists physical status II) was scheduled for right shoulder surgery during general anesthesia combined with an interscalene block. The night before surgery, she was given her usual sleeping pill (1 mg temazepam).

At the time of arrival in the operating room at 7:15 AM, the patient was fully awake. After institution of the standard monitoring, 1,000 ml lactated Ringer's solution was connected to an intravenous catheter on the back of her left hand. An interscalene block was performed using a nerve stimulator without administration of sedative drugs. Thirty milliliters bupivacaine, 0.375%, was injected when the appropriate motor response was observed.

Zip-Prep electroencephalographic electrodes (Aspect Medical Systems, Inc.) were then fixed at the frontal positions as recommended for BIS monitoring (Aspect-1000, BIS version 3.2; Aspect Medical Corp., Newton, MA). After confirming establishment of the regional block, a

target-controlled infusion of propofol (Diprifuor; Astra-Zeneca Ltd., London, United Kingdom) was started at an initial target plasma concentration of 6 $\mu\text{g/ml}$ together with an infusion of remifentanyl at a rate of 0.25 $\mu\text{g} \cdot \text{kg}^{-1} \cdot \text{min}^{-1}$. After intubation facilitated with 30 mg atracurium, the patient underwent ventilation with 30 vol% oxygen in air, and the target propofol concentration was reduced to 3 and then 2 $\mu\text{g/ml}$, which was sufficient to maintain the BIS between 40 and 60. No further relaxants were administered thereafter. The remifentanyl infusion was adjusted according to the blood pressure.

With the patient in the beach chair position, the anesthetist had no direct access to the patient's head and left hand, and the infusion line was not directly visible. Forty-five minutes after induction of anesthesia, surgery was started. Because 10 min after skin incision the BIS increased from 45 to 65, the propofol target concentration was increased to 3 $\mu\text{g/ml}$, which decreased the BIS again to 45. However, only a few minutes later, the BIS increased again to 65 and then suddenly to 90 without hemodynamic changes. No movement of the patient was observed at that time, 1 h after the induction dose of atracurium. Although the target propofol concentration was immediately increased from 2.5 to 6 $\mu\text{g/ml}$, the BIS remained at 90. Only a few minutes later, heart rate suddenly increased from 66 to 110 beats/min, and systolic blood pressure increased from 105 to 170 mmHg. Isoflurane administration was started, and it was recognized that propofol (and remifentanyl) were backed up in the intravenous tubing. After repositioning of the left hand, the intravenous catheter flowed freely, the BIS decreased to 35, isoflurane was discontinued, and the target propofol concentration was again reduced.

After completion of the operation (2 h later), the propofol and remifentanyl infusions were discontinued. The patient woke up 4 min later and underwent extubation. When asked about her anesthetic experience, she reported that she had woken up during surgery, hearing the surgeons talking about politics. She spontaneously mentioned the name Schroeder, which could be related to the surgeons' discussion on the German chancellor during the first part of the operation. She did not feel any pain or discomfort but was unable to speak with the tube in her trachea. At the postoperative visit, an explanation for the awareness was given to the patient. She was not worried about the event because she did not feel pain.

Case 2

A 40-yr-old man (American Society of Anesthesiologists physical status I) was scheduled for lower back surgery. Because he was enrolled in an anesthesia research protocol, a Dräger Xenon Cicero EM anesthesia work station (Drägerwerke AG, Lübeck, Germany) was used with a charcoal filter inserted after the inspiratory valve of the circle system to allow for rapid elimination of volatile anesthetics. The filter was normally bypassed by closing a valve manually.

After institution of the standard monitoring and the BIS monitor (Aspect-1000, BIS version 3.2), anesthesia was induced with 2.5 mg/kg propofol, 100 μg remifentanyl, and 0.1 mg/kg vecuronium. Immediately after loss of consciousness, the desflurane vaporizer (Dräger Devapor; Drägerwerke AG) was set at 4 vol% (fresh gas flow 3 l/min) and the patient underwent mask ventilation without difficulty. However, no desflurane or expired carbon dioxide was detected by the gas monitor (Datex AS3 Compact; Datex-Ohmeda, Instrumentarium Corp., Helsinki, Finland). The sampling tube was checked for kinking or obstruction, and an improper fit of the water trap at the sampling port

* Staff Anesthesiologist.

Received from the Department of Anesthesiology, University Hospital of Bern, Bern, Switzerland. Submitted for publication October 6, 2000. Accepted for publication February 14, 2001. Supported by the Departmental Research Fund, University Hospital of Bern.

Address reprint requests to Dr. Luginbühl: Department of Anesthesiology, University Hospital, CH-3010 Bern, Switzerland. Address electronic mail to: martin.luginbuehl@dkf2.unibe.ch. Individual article reprints may be purchased through the Journal Web site, www.anesthesiology.org.

of the monitor was detected. End-tidal carbon dioxide was now evident, but still no desflurane was detected, although the vaporizer output had been increased to 18 vol%.

Two minutes after injection of propofol, the BIS reached a nadir of 30 and slowly increased to 64 over the next 5 min. An additional dose of remifentanyl (50 µg) was administered before tracheal intubation. We suspected that there was a technical problem with the display of the desflurane concentration, particularly because there were no clinical signs of inadequate anesthesia and because the BIS remained stable between 60 and 70. At the time of tracheal intubation, the BIS was 68. After intubation, systolic blood pressure increased from 119 to 160 mmHg, and heart rate increased from 76 to 113 beats/min. The gas analyzer still did not detect desflurane, although the capnography curve was normal. Only after another 10 min, it was discovered that the charcoal filter was not bypassed. Meanwhile, the BIS had remained stable below 70 and promptly decreased from 66 to 48 after the charcoal filter was bypassed and the desflurane concentration increased.

The rest of anesthesia and surgery were uneventful. Immediately after extubation, the patient spontaneously recalled tracheal intubation as an unpleasant but not a painful event, but he did not recall further events during surgery. The patient was then followed up for 6 months, and there were no psychological sequels.

Discussion

Both cases of explicit awareness were caused by an unrecognized interruption of anesthetic drug delivery and illustrate typical clinical situations in which awareness during general anesthesia may occur. Neither patient initially demonstrated hemodynamic or motor reaction as evidence of inadequate anesthesia. However, at least the second patient may have been paralyzed. Laryngoscopy with intubation as illustrated by the second case is a situation especially prone to awareness.¹¹

The BIS value in the first patient was at 90 for several minutes. Propofol and remifentanyl are drugs with rapid redistribution and elimination. If infusion is accidentally stopped, the patient's state of hypnosis, as in this case, changes rapidly from unconscious to fully awake. Because hemodynamic response to surgical stimulation may occur only after the patient is awake, electroencephalographic monitoring, such as BIS monitoring, is a useful tool for early detection of an unintended decrease of hypnotic drug effect. If an increase of the BIS does not respond to immediate increase in anesthetic drug concentration, the infusion line used for drug delivery should be checked immediately. The injection site should be made visible as much as possible and antireflux valves must be used to allow an uninterrupted drug supply. Unfortunately, an antireflux valve was not available in the first case.

The desflurane remaining undetectable for more than 20 min in the second patient would have prompted intravenous administration of a hypnotic drug if the BIS had increased above 70. Glass *et al.*⁶ reported a small probability of recall during propofol sedation at a BIS below 70 ($BIS_{95(\text{absence of recall})} = 77$; 95% confidence interval, 72–83). In their series of 90 trauma patients, Lubke *et al.*⁹ detected an increasing risk of auditory

information processing and implicit recall as BIS values increase above a range of 40–60. They failed to define a BIS level with a significantly increased risk of explicit recall, probably because of the low number of patients with a BIS higher than 60. Flaishon *et al.*¹² reported that 50% of their study patients responded to command within 4 min when the BIS increased to 65, although none had an explicit recall of any event before regaining consciousness after a bolus of propofol. Aware of the data mentioned herein, the anesthesiologist accepted a moderately increased BIS (between 60 and 70) for more than 15 min while searching for the technical problem with desflurane measurement. In retrospect, end-tidal monitoring was effective in identifying an interruption in anesthetic delivery, but previous technical problems in obtaining an adequate capnography curve led the anesthesiologist to conclude incorrectly that the agent analyzer was malfunctioning.

The current cases illustrate the results of Flaishon *et al.*,¹² indicating that the probability of awareness and recall is not only related to the absolute BIS level but also to the duration of an increased BIS. The time lag between the increase of the BIS above 60 in the both patients and the event of explicit recall corresponds exactly to the 4 min reported in their article.

In a recent prospective survey,¹¹ the use of end-tidal anesthetic gas analyzers apparently did not reduce the incidence of awareness. In contrast, education of personnel, regardless of monitoring, was more effective.^{1,2} The use of anesthesia depth monitors, such as BIS⁵ and midlatency auditory-evoked potentials,¹³ are thus to be considered in that context. They add important information to clinical signs of inadequate anesthesia and to measurement of anesthetic gas concentrations. To be effective in prevention of awareness and recall, depth-of-anesthesia monitors should be used according to rational practice guidelines when situations with an increased risk for awareness should be identified. One of them is laryngoscopy with intubation,¹¹ which implies that depth-of-anesthesia monitors should already be installed for induction. Another is increase of the BIS above 60 for more than 3 min. If not attributable to an increase in electromyographic activity, this should be treated promptly by increasing the hypnotic drug concentration.¹⁴ If an increased BIS does not respond to the increase of the hypnotic drug, an accidental interruption of drug delivery³ has to be suspected, and another hypnotic drug should be administered by another route. We conclude that depth-of-anesthesia monitors may be useful in prevention of awareness but only together with rational practice guidelines and continuous education.

References

1. Lyons G, Macdonald R: Awareness during caesarean section. *Anaesthesia* 1991; 46:62–4

2. Ranta S, Jussila J, Hynynen M: Recall of awareness during cardiac anaesthesia: Influence of feedback information to the anaesthesiologist. *Acta Anaesthesiol Scand* 1996; 40:554-60
3. Ghoneim MM: Awareness during anesthesia. *ANESTHESIOLOGY* 2000; 92:597-602
4. Sigl JC, Chamoun N: An introduction to bispectral analysis for the electroencephalogram. *J Clin Monit* 1994; 10:392-404
5. Rampil IJ: A primer for EEG signal processing in anesthesia. *ANESTHESIOLOGY* 1998; 89:980-1002
6. Glass PS, Blom M, Kearse LA, Rosow C, Sebel PS, Manberg P, Bloom M, Kearse L, Sebel P: Bispectral analysis measures sedation and memory effects of propofol, midazolam, isoflurane, and alfentanil in healthy volunteers. *ANESTHESIOLOGY* 1997; 86:836-47
7. Kearse LAJ, Rosow C, Zaslavsky A, Connors P, Dershwitz M, Denman W: Bispectral analysis of the electroencephalogram predicts conscious processing of information during propofol sedation and hypnosis. *ANESTHESIOLOGY* 1998; 88:25-34
8. Liu J, Singh H, White PF: Electroencephalographic bispectral index corre-

lates with intraoperative recall and depth of propofol-induced sedation. *Anesth Analg* 1997; 84:185-9

9. Lubke GH, Keressens C, Phaf H, Sebel PS: Dependence of explicit and implicit memory on hypnotic state in trauma patients. *ANESTHESIOLOGY* 1999; 90:670-80
10. BIS Clinical Reference Manual. Newton, Massachusetts, Aspect Medical Systems, Inc., 1998
11. Sandin RH, Enlund G, Samuelsson P, Lennmarken C: Awareness during anaesthesia: A prospective case study. *Lancet* 2000; 355:707-11
12. Flaishon R, Windsor A, Sigl J, Sebel PS: Recovery of consciousness after thiopental or propofol. *ANESTHESIOLOGY* 1997; 86:613-9
13. Dutton RC, Smith WD, Rampil IJ, Chortkoff BS, Eger EI: Forty-hertz mid-latency auditory evoked potential activity predicts wakeful response during desflurane and propofol anesthesia in volunteers. *ANESTHESIOLOGY* 1999; 91:1209-20
14. Bruhn J, Bouillon TW, Shafer SL: Electromyographic activity falsely elevates the bispectral index. *ANESTHESIOLOGY* 2000; 92:1485-7

Anesthesiology 2002; 96:243-5

© 2002 American Society of Anesthesiologists, Inc. Lippincott Williams & Wilkins, Inc.

Perioperative Anterior Interosseous Neuropathy

Michael G. Contreras, M.D.,* Mark A. Warner, M.D.,† Stephen W. Carmichael, Ph.D.,‡ Robert J. Spinner, M.D.§

ANTERIOR interosseous neuropathy is an uncommon perioperative neuropathy. Although two large series from the American Society of Anesthesiologists Closed Claims Project have categorized anesthetic-related perioperative neuropathies, neither has included cases involving the anterior interosseous nerve.^{1,2} However, perioperative anterior interosseous neuropathy has been described in isolated case reports.^{3,4}

The anterior interosseous nerve lies primarily in the proximal forearm (fig. 1). Symptoms of neuropathy involving this nerve include weakness or paralysis in the thumb and index finger. Anterior interosseous neuropathy does not present with any sensory disturbance because the nerve does not contain cutaneous sensory fibers. Signs of neuropathy found through physical examination include weakened flexion of the interphalangeal joint of the thumb and distal interphalangeal joint of the index or middle finger, and weakened pronation with the elbow in a flexed position. The clinical situation causes a characteristic square pinch rather than an "O" when the thumb and index finger are opposed (fig. 2).⁵

In this report, we present four patients with anterior interosseous neuropathy that developed in the perioperative period whom we have evaluated over a 3-yr period at the Mayo Clinic (Rochester, MN) and elsewhere. The purpose of this report is to alert anesthesiologists of the

potential for anterior interosseous neuropathy in the perioperative period.

Case Reports

The four cases described illustrate anterior interosseous neuropathy occurring in the perioperative period. The case reports have varied etiologies as the causes of neuropathy.

Case 1

A 43-yr-old healthy male anesthesiologist who was donating blood before undergoing surgery experienced a block of his anterior interosseous nerve function after the injection of 1 ml lidocaine, 1%, into his right antecubital fossa. The local anesthetic was injected to produce anesthesia for insertion of a 12-gauge needle for blood collection. He noticed an inability to flex the distal interphalangeal joint of his right index finger while squeezing a sponge ball approximately 2 min after injection. Further inspection showed that he also was unable to flex the interphalangeal joint of his right thumb. There was no sensory loss. The nerve dysfunction lasted approximately 75 min.

Case 2

A 42-yr-old healthy man underwent a 90-min appendectomy performed with him in the supine position while receiving a general anesthetic. Multiple attempts to cannulate veins on the right hand and mid-forearm and the antecubital fossa were unsuccessful. The intravenous cannula was eventually placed in the left forearm, and the procedure continued uneventfully. Both arms were tucked at the side and reportedly padded. Two hours after discontinuation of the anesthetic, the patient noted an inability to hold a pencil in his right hand. Examination of his right upper limb showed that he was unable to oppose his thumb and index finger or to flex the distal phalanx of both these digits. He had no sensory disturbance. A neurologist confirmed these findings 24 h later. The weakness resolved over the next 6 days and was no longer detectable by postoperative day 7.

Case 3

A 63-yr-old woman with hypertension and asthma underwent a 30-min cervical dilation and curettage performed with her in a litho-

* Resident in Anesthesiology, Mayo Graduate School of Medicine, Rochester, Minnesota. † Professor of Anesthesiology, ‡ Professor of Anatomy, § Assistant Professor of Neurologic Surgery and Orthopedics, Mayo Medical School, Rochester, Minnesota.

Received from the Departments of Anesthesiology, Anatomy, and Neurologic Surgery, Mayo Foundation, Rochester, Minnesota. Submitted for publication April 25, 2001. Accepted for publication July 19, 2001. Supported by the Mayo Foundation, Rochester, Minnesota.

Address reprint requests to Dr. Warner: Department of Anesthesiology, Mayo Clinic, 200 First Street Southwest, Rochester, Minnesota 55905. Address electronic mail to: warner.mark@mayo.edu. Individual article reprints may be purchased through the Journal Web site, www.anesthesiology.org.

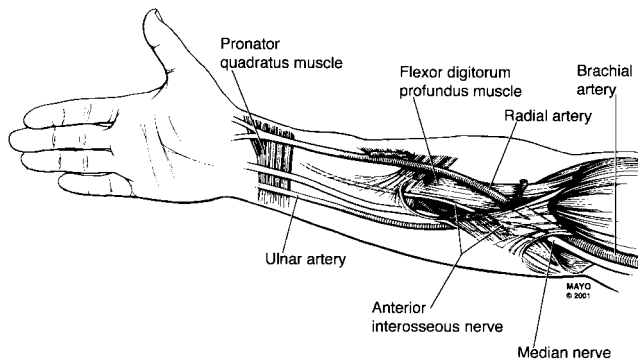


Fig. 1. Anatomic drawing of the deep structures of the right forearm with superficial tissue, the median cubital vein, the flexor pollicis longus, and the brachioradialis muscles removed. The anterior interosseous nerve separates from the median nerve in the proximal forearm. It innervates the flexor pollicis longus, the flexor digitorum profundus, and the pronator quadratus muscles.

omy position while receiving general anesthesia. One milliliter lidocaine, 1%, was injected subcutaneously in the right antecubital fossa for an unsuccessful attempt at intravenous cannula placement. A cannula subsequently was placed in the left upper limb. Both limbs were positioned on padded arm boards, with her elbows extended and her arms abducted approximately 45°. Twenty minutes after discontinuation of the anesthetic, the patient noted a weak grasp of her right hand. Examination showed that she had severe weakness during opposition of her right thumb and index finger. She also was noted to be unable to flex the distal phalanx of both of these digits, but no sensory loss or paresthesia could be detected. A 3 × 5-cm hematoma was noted in the right antecubital fossa surrounding the failed catheter placement site. The weakness of opposition resolved over the next 45 min, and she had no residual weakness the next day.

Case 4

A 26-yr-old healthy man underwent a 2-h arthroscopic repair of his left anterior cruciate ligament while he was in a supine position and receiving general anesthesia. He was a competitive weightlifter, and it was noted that he was unable to extend his elbows completely during the preanesthetic evaluation. After successful placement of an intravenous cannula into the dorsum of his left hand, he was anesthetized, and his arms were padded and tucked at his sides. Six hours after discontinuation of the anesthetic, he found that he was unable to hold a

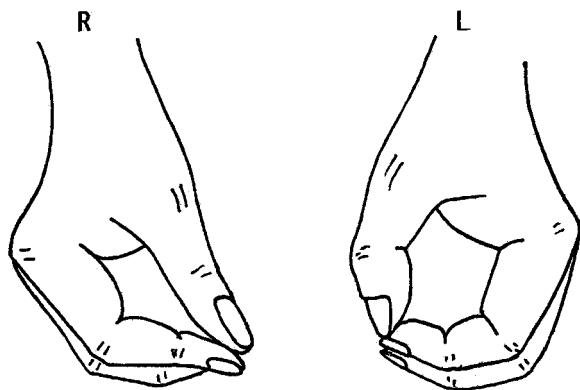


Fig. 2. Characteristic square pinch in the right hand due to a lesion of the anterior interosseous nerve. The left hand demonstrates a normal pinch. Used with permission.⁵

pencil easily in his right hand. Examination showed that he had weakness of opposition of his right thumb and index finger and was unable to flex the distal phalanx of both of these digits fully. There was no sensory loss. A neurologist confirmed these findings 1 day later. An electromyogram 4 weeks after the initial procedure showed denervation of the flexor pollicis longus and flexor digitorum profundus. The patient had slow resolution of the neuropathy, with complete recovery of strength of opposition in 4 months.

Discussion

These four patients all experienced anterior interosseous neuropathy in the extended perioperative period. Perioperative neuropathies have been directly associated with various events, such as needle stick, hematomas, and positioning.⁶ In addition, perioperative neuropathies of the upper extremities also have been described as part of idiopathic brachial neuritis (or Parsonage-Turner syndrome).⁷ This condition, thought to be immune mediated, usually presents with pain in the shoulder region followed by diffuse neurologic findings; occasionally, it may affect only one nerve, including the anterior interosseous nerve. The etiologic factors in these four cases are speculative. Our following remarks represent our reflections on possible mechanisms of anterior interosseous neuropathy based on these cases.

Case 1

Local anesthetic infiltration of the subcutaneous tissue in the antecubital fossa may lead to transient block of the anterior interosseous nerve. This patient experienced a block of his anterior interosseous nerve function after injection of 1 ml lidocaine, 1%, into the antecubital fossa.

Case 2

Direct penetrating trauma to a nerve may cause neuropathy. The median nerve fibers supplying the anterior interosseous nerve may be vulnerable to trauma during

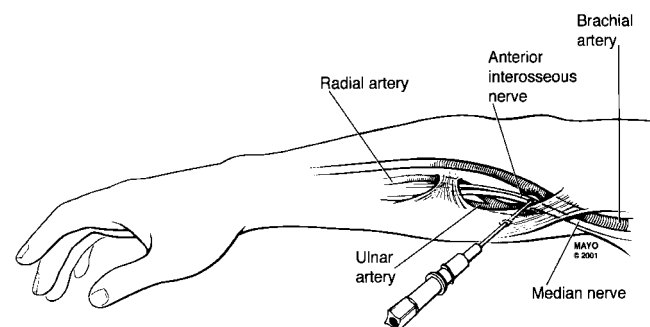


Fig. 3. Anatomic drawing of right forearm with the median cubital vein removed shows how a steep trajectory during intravenous cannulation in the proximal forearm could directly traumatize the anterior interosseous nerve. The anterior interosseous nerve fascicles of the median nerve also could be injured in the antecubital fossa by a needle stick. In addition, edema or hematoma could cause nerve compression in the forearm if compartment expansion is limited by fibrous sheaths or bands.

placement of intravenous cannula,⁸ needle sticks, cut-downs,⁹ or arterial blood collections performed in the antecubital fossa (fig. 3). This patient had a neuropathy after multiple needle sticks of the right forearm. In an awake patient, direct injury typically would produce immediate pain in the distribution of the nerve. However, it is not clear whether any needle stick directly injured the nerve in this patient.

Case 3

Compression of the anterior interosseous nerve or the anterior interosseous nerve fibers within the median nerve by hematoma or compartmentalized edema can occur during or up to several days after surgery. For example, infiltration of an intravenous fluid has been reported with a case of anterior interosseous neuropathy.⁵ In our patient, a hematoma seemed to develop at the sight of an unsuccessful intravenous cannulation. We speculate this hematoma may have transiently compressed the anterior interosseous nerve.

Case 4

Stretch of most nerves, especially to lengths greater than 10% of their normal resting lengths, can cause neuropraxia.⁶ We speculate that extension of the elbows beyond the normally tolerated limits of motion may stretch the anterior interosseous nerve sufficiently to

cause transient dysfunction. We recommend that anesthesia providers assess elbow range of motion before anesthetizing patients, extending the elbows, and wrapping their forearms on arm boards.

In summary, anterior interosseous neuropathy is a rarely reported perioperative event. The symptoms are unique because the anterior interosseous nerve is a pure motor nerve with no cutaneous distribution sensory fibers. The symptoms of anterior interosseous neuropathy in several of these patients resolved early in the perioperative period; however, there may be patients with prolonged disability. The etiology of anterior interosseous neuropathy in many cases is unclear, but our cases suggest potential preventable causes to consider.

References

1. Cheney F, Domino K, Caplan R, Posner K: Nerve injury associated with anesthesia: A closed claims analysis. *ANESTHESIOLOGY* 1999; 90:1062-4
2. Kroll DA, Caplan RA, Posner K, Ward RS, Cheney FW: Nerve injury associated with anesthesia. *ANESTHESIOLOGY* 1990; 73:202-7
3. Albanese S, Buterbaugh G, Palmer A, Lubicky J, Yuan H: Incomplete anterior interosseous nerve palsy following spinal injury. *Spine* 1986; 11:1037-8
4. Saeed M, Gatens P: Anterior interosseous nerve syndrome: Unusual etiologies. *Arch Phys Med Rehabil* 1983; 64:182
5. Seror P: Anterior interosseous nerve lesions: Clinical and electrophysiologic features. *J Bone Joint Surg* 1996; 78-B:238-41
6. Dawson D, Krarup C: Perioperative nerve lesions. *Archives of Neurology* 1989; 46:1355-60
7. Malamut RI, Marques W, England JD, Sumner AJ: Postsurgical idiopathic brachial neuritis. *Muscle Nerve* 1994; 17:320-4
8. Tobias E: Eli's pearls. *Surg Neurol* 1998; 49:112
9. Finelli PF: Anterior interosseous nerve syndrome following cutdown catheterization. *Ann Neurol* 1977; 1:205-6

Anesthesiology 2002; 96:245-7

© 2002 American Society of Anesthesiologists, Inc. Lippincott Williams & Wilkins, Inc.

Isolated Bilateral Paralysis of the Hypoglossal Nerve after Transoral Intubation for General Anesthesia

Eduardo Rubio-Nazábal, M.D.,* José Marey-Lopez, M.D.,* Soledad Lopez-Facal, M.D.,* Purificación Alvarez-Perez, M.D.,† Antonio Martínez-Figueroa, M.D.,‡ Pablo Rey del Corral, M.D.*

HYPOGLOSSAL nerve palsy is a rare occurrence usually associated with other cranial nerve palsies and long tract signs. Twelfth-nerve palsies have frequently been reported in association with the following conditions: tumors (metastatic, chordoma, nasopharyngeal mass, lymphoma), head trauma, stroke, hysteria, multiple sclerosis, carotid endarterectomy, Guillain-Barré syndrome, and infection. Hypoglossal nerve palsies usually present unilaterally, associated with involvement

of other cranial nerves and neurologic structures, and present as signs rather than symptoms.^{1,2}

Isolated bilateral 12th-nerve palsy is an unusual finding. These patients have dysarthria; accumulation of saliva, forcing the patient to swallow frequently; dysphagia due to inability to propel food to the pharynx; and respiratory embarrassment due to prolapse of the tongue into the pharynx (mainly in the supine position). Examination shows bilateral tongue atrophy and fasciculations.

We describe a patient with isolated bilateral 12th-nerve paralysis complicating transoral intubation for general anesthesia presenting with breathing distress and airway obstruction after extubation. To our knowledge, a bilateral hypoglossal nerve palsy after transoral intubation has not been reported previously.

* Neurologist, † Primary Care, Department of Neurology, ‡ Neurophysiologist, Department of Neurophysiology.

Received from the Departments of Neurology and Neurophysiology, Hospital Juan Canalejo, La Coruña, Spain. Submitted for publication February 22, 2001. Accepted for publication July 26, 2001. Support was provided solely from institutional and/or departmental sources.

Address reprint requests to Dr. Rubio-Nazábal: Servicio de Neurología, Hospital Juan Canalejo, 15006 La Coruña, Spain. Address electronic mail to: med028715@nacom.es. Individual article reprints may be purchased through the Journal Web site, www.anesthesiology.org.

Case Report

A 63-yr-old man with a history of hypertension and an abdominal aortic aneurysm was admitted to hospital for sudden onset of abdominal pain. Examination showed that the patient was hypotensive (blood pressure, 90/60 mmHg), diaphoretic, and tachycardic. A diagnosis of rupture of the aneurysm and hypovolemic shock (systolic arterial pressure decreasing to 50 mmHg) was made, requiring emergency surgery and rapid infusion of plasma expanders, platelets, and erythrocytes. The patient underwent aneurysm excision and replacement with a graft *via* a standard open procedure. Administration of general anesthesia and endotracheal intubation proceeded without difficulty: laryngoscopy was performed with a Macintosh blade, and an 8-mm-diameter endotracheal tube was inserted atraumatically on the first try and was then fixed to the right angle of the mouth. The cuff of the tube was inflated and attached to a pressure gauge to keep the cuff pressure less than 20 cm H₂O. No adjustment of cuff volume was made postoperatively. A Guedel airway was in place during surgery. Surgery was performed with the patient in the supine position and lasted 240 min.

The patient tolerated the procedure well. He was taken to the intensive care unit and underwent mechanical ventilation. The patient was sedated postoperatively with morphine, and there was no significant period of coughing or gagging before the first attempted extubation. Four days after surgery, before removal of the endotracheal tube, the patient was breathing adequately. He was weaned from ventilatory support gradually, but after extubation, respiratory obstruction, dysphagia, dysarthria, and pooling of saliva in the mouth developed. He underwent reintubation. The patient continued to have airway obstruction each time extubation was attempted. The situation remained unchanged 2 weeks after surgery, so a tracheostomy was performed, and nasogastric tube feeding was started.

Neurologic assessment was performed 5 days after surgery. Examination revealed pronounced dysarthria and slurred speech and inability to move and protrude his tongue, which was observed at rest in the floor of the mouth. Bilateral atrophy and fasciculations, dysphagia, and pooling of saliva in the mouth with frequent swallowing were noted. Detailed neurologic examination revealed no other evidence of central or cranial nerve involvement. Therefore, a diagnosis of isolated bilateral hypoglossal nerve paralysis was considered. The electromyographic examination (6 days after surgery) showed denervation of the tongue with minimal active contraction of single motor units, fibrillation potentials, and positive sharp waves.

Laboratory tests, including serologic studies to exclude infections, such as herpes viruses or *Borrelia*, yielded normal results. Radiography of the skull and the chest, computerized tomography of the head, and magnetic resonance imaging of the brain and cervical spine showed no abnormalities.

No specific treatment was administered. The hypoglossal palsy improved slowly. The patient was able to extend his tongue symmetrically 1 month after surgery. He was placed on a soft food diet and experienced no difficulty with swallowing either saliva or food 2 months after surgery. Closing of the tracheostomy was tolerated 3 months after surgery. Three months later, mobility of the tongue was normal. In an electromyogram 8 months after the initial episode, normal potentials were observed on minimal and on maximal contractions.

Discussion

Palsies of the hypoglossal cranial nerve rarely occur in isolation and are usually accompanied by other cranial neuropathies. Keane¹ summarized his experience with 100 cases of 12th cranial nerve palsy encountered over a 26-yr period. In the majority, the 12th cranial nerve involvement was of minor discomfort to the patient.

Twelfth cranial nerve palsies usually presented as signs rather than symptoms, but their appearance was ominous (tumors were involved in almost half of the cases).

Isolated hypoglossal nerve palsies are an uncommon complication after otolaryngologic procedures, such as prolonged direct laryngoscopy,^{3,4} tonsillectomy,⁵ aortic arch surgery,⁶ use of a laryngeal mask airway,⁷ extraction of a tooth,⁸ or transoral intubation for general anesthesia.⁹ These patients usually experience an excellent outcome. To our knowledge, development of an isolated severe bilateral 12th cranial nerve palsy as a result of transoral intubation for general anesthesia has not been previously reported. The following mechanisms of injury have been proposed in published cases: pressure to the lateral roots of the tongue during routine intubation using the McIntosh blade with hyperextension of the head,⁵ and a difficult intubation in which cricoid pressure or forceful laryngoscopy are used,¹⁰ which can result in hypoglossal nerve injury.

Anatomically, the hypoglossal nerve rests on the most lateral prominence of the anterior surface of the transverse process of C1. If hyperextension of this joint occurs, it is possible that this nerve would be stretched against this prominence.⁸ This case does not follow this pattern, but the mechanism has been reported frequently in cases of traumatically induced hypoglossal nerve palsy in which initial plain radiographs and computed tomography scans have failed to show any causative lesion.¹¹ Inadvertent extubation of the trachea with the cuff inflated, leading to compression and stretch of the nerve against the greater horn of the hyoid bone, has been postulated as the cause of the hypoglossal palsy.¹² Two factors have been reported influencing 12th-nerve damage: a calcified ligamentum stylohyoideum⁹ and the presence of a skull base malformation.¹³ Both were excluded in this patient. There was no clear mechanism of injury to the hypoglossal nerves in this patient. Because all other nerves were spared and the computed tomography scan and magnetic resonance image of the brain were normal, intracranial pathology was unlikely. We postulate that low blood pressure and prolonged but unnoticed overinflation of an endotracheal cuff resting high in the larynx, just below the cords, might have been a source of bilateral nerve compression. A change in the position of the neck at some point, compression by the endotracheal tube, and pressure to the lateral roots of the tongue with the McIntosh blade could be additional mechanisms. The progressive recovery of function suggests a neuropraxic type of nerve damage.

Isolated bilateral hypoglossal nerve palsy is a rare finding. It should be considered in patients after transoral intubation for general anesthesia who report respiratory obstruction, dysphagia, and dysarthria when extubation is attempted.

References

1. Keane JR: Twelfth-nerve palsy: Analysis of 100 cases. *Arch Neurol* 1996; 53:561-6
2. Tommasi-Davenas C, Vighetto A, Confavreux C, Aimard G: Causes des paralysies du nerf grand hypoglosse. *Presse Medicale Paris* 1990; 19:864-8
3. Agnoli A, Strauss P: Isolierte Hypoglossus und kombinierte Hypoglossus-lingualisparesie nach intubation und direkter laryngoskopie. *HNO* 1970; 18:237-9
4. Condado MA, Morais D, Santos J, Alonso-Vielba J, Miyar V: Hypoglossal nerve paralysis after intubation and direct laryngoscopy. *Acta Otorhinolaryngol Esp* 1994; 45:477-9
5. Michel O, Brusis T: Hypoglossal nerve paralysis following tonsillectomy. *Laryngorhinootologie* 1990; 69:267-70
6. Konrad RM, Lakomy J: Kombinierte periphere Hypoglossuslähmung nach Intubationsnarkose. *Anaesthesist* 1960; 9:206-8
7. Nagai K, Sakuramoto C, Goto F: Unilateral hypoglossal nerve paralysis following the use of the laryngeal mask airway. *Anaesthesia* 1994; 49:603-4
8. Kenrich MM, Bredfeldt RC, Sheridan CD, Munroe AD: Bilateral injury to the hypoglossal nerve. *Arch Phys Med Rehabil* 1977; 58:578-82
9. Streppel M, Bachmann G, Stennert E: Hypoglossal nerve palsy as a complication of transoral intubation for general anesthesia (letter). *ANESTHESIOLOGY* 1997; 86:1007
10. Evers KA, Eindhoven GB, Wierda JMKH: Transient nerve damage following intubation for trans-sphenoidal hypophysectomy. *Can J Anesth* 1999; 46:1143-5
11. Delamont RS, Boyle RS: Traumatic hypoglossal nerve palsy. *Clin Exp Neurol* 1989; 26:239-241
12. Venkatesh B, Walker D: Hypoglossal neuropraxia following endotracheal intubation. *Anaesth Intensive Care* 1977; 25: 699-700
13. Matthia PH, Coudray C, Cornec J, Leclech G, Bourdinière J: Traumatisme cervical indirect et paralysie des deux dernières paires crâniennes: A propos de deux observations. *Rev Oto Neuro Ophthalmol* 1980; 52:43-51

Anesthesiology 2002; 96:247-8

© 2002 American Society of Anesthesiologists, Inc. Lippincott Williams & Wilkins, Inc.

A Unique Case of Subconjunctival Hemorrhage in a Patient Undergoing Decompressive Lumbar Laminectomy

Jon B. Obray, M.D.,* Timothy R. Long, M.D.,† C. Thomas Wass, M.D.‡

EYE injury after nonocular surgery is rare, with an incidence of approximately 0.06%.¹ To elucidate the frequency of eye injury, Roth *et al.*¹ surveyed the records of 60,965 patients undergoing nonocular surgery. They observed that 34 patients sustained eye injury (*e.g.*, corneal abrasion, conjunctivitis, blurred vision, red eye, chemical injury, direct trauma, eyelid hematoma, permanent visual loss) during the perioperative period.¹ Of these, corneal abrasion and blindness were the most and least commonly reported injuries, respectively.¹ Of additional interest, Gild *et al.*² reported that 3% of all claims in the American Society of Anesthesiologists Closed Claims Database were due to ocular injury. Further, they reported that the payment frequency for eye injury claims was significantly greater than for non-ocular-related injuries.² Taken together, although perioperative eye injury is rare, it can result in serious patient morbidity. We present a unique case in which we observed subconjunctival hemorrhage after uneventful general anesthesia for decompressive lumbar laminectomy.

Case Report

A 67-yr-old woman with American Society of Anesthesiologists physical status III and a 3-week history of left foot drop secondary to severe lumbar spinal stenosis was scheduled to undergo surgical decompression and fusion of the L4-L5 disk space. Preoperative medical exami-

nation revealed an obese patient (weight, 120 kg; body mass index, 47 kg/m²) with a history of gastroesophageal reflux disease and deep venous thrombosis after a previous pregnancy. Her current medications included famotidine and acetaminophen as needed. She was allergic to penicillin and had no previous anesthesia-related complications.

General anesthesia was induced with intravenous fentanyl, propofol with lidocaine, and succinylcholine. Cricoid pressure was applied. After induction of general anesthesia, the patient's eyes were taped shut before atraumatic orotracheal intubation. In addition to standard American Society of Anesthesiology monitors, right internal jugular vein and right radial arterial artery catheters were placed. She was positioned prone on a Jackson table with her face carefully positioned in a Gentletouch® 7" Headrest Pillow (Orthopedic Systems, Inc., Union City, CA) with a T-shaped cutout for the eyes, nose, and mouth. Her orbits and abdomen were noted to be pressure-free after prone positioning and throughout the surgical course. Anesthesia was maintained with inhaled isoflurane and nitrous oxide plus intravenous oxymorphone and vecuronium.

Hemodynamically, she was stable throughout surgery, with brief episodes of hypertension (maximum systemic blood pressure, 195/100 mmHg) during laryngoscopy and emergence. Both episodes of hypertension were promptly treated with intravenous esmolol and hydralazine. Blood loss was estimated to be 900 ml. She received 500 ml hetastarch, 2,800 ml lactated Ringer's solution, and 425 ml intraoperatively salvaged blood. Central venous pressure measurements ranged from 7 to 13 mmHg during surgery. Urinary output was 900 ml.

At the conclusion of surgery (after being prone for approximately 6 h), the patient was returned to the supine position, and the eye tapes were removed. Because the patient appeared somnolent, we elected to assess the level of narcosis by evaluating the magnitude of pupillary miosis. However, while doing this, we observed what seemed to be severe scleral injection or subconjunctival hemorrhage in her left eye (fig 1). The orbit was devoid of overt trauma, and the eye was free of purulence and lacrimation. It deserves mention that these findings were observed before emergence from general anesthesia. That is, the patient had not coughed or strained during use of the endotracheal tube.

Subsequently, the patient underwent uneventful extubation, and an ophthalmology consultation was obtained in the postanesthesia recovery room. The ophthalmologist reported subconjunctival hemorrhage of the left eye with intact visual acuity, normal intraocular pressures, and normal funduscopic examination. The ophthalmologist's conclusion was subconjunctival hemorrhage of unclear etiology that would resolve spontaneously. In a follow-up telephone interview 2 weeks

* Resident in Anesthesiology, Mayo Clinic. † Instructor in Anesthesiology, ‡ Assistant Professor of Anesthesiology, Mayo Medical School, Rochester, Minnesota.

Received from the Department of Anesthesiology, Mayo Clinic, Rochester, Minnesota. Submitted for publication March 14, 2001. Accepted for publication July 26, 2001. Support was provided solely from institutional and/or departmental sources. Presented at the Midwest Anesthesia Residents Conference, Milwaukee, Wisconsin, March 23-25, 2001.

Address reprint requests to Dr. Wass: Department of Anesthesiology, Mayo Clinic, 200 First Street Southwest, Rochester, Minnesota 55905. Address electronic mail to: wass.thomas@mayo.edu. Individual article reprints may be purchased through the Journal Web site, www.anesthesiology.org.

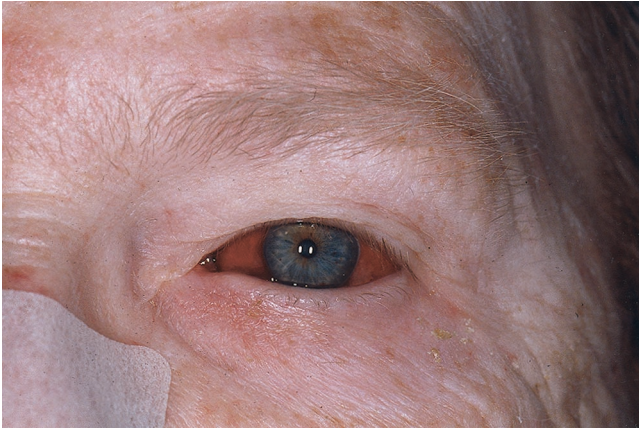


Fig. 1. Subconjunctival hemorrhage of the left eye, observed immediately after resuming the supine position at the conclusion of decompressive lumbar laminectomy.

after surgery, the patient reported complete resolution of her subconjunctival hemorrhage without long-term sequelae.

Discussion

We report a case of atraumatic perioperative subconjunctival hemorrhage. To elucidate the uniqueness of the current case, we performed an extensive search of the medical literature and were unable to find previously cited cases of perioperative subconjunctival hemorrhage. Although this physical finding is extremely distressing at first glance, the downstream implications are typically of little, if any, consequence. That is, the usual clinical course of subconjunctival hemorrhage is that of spontaneous resolution without long-term sequelae.

Subconjunctival hemorrhage results from tearing of small vessels bridging the potential space between the episcleral and conjunctival tissues. These events are usually spontaneous and unilateral in nature. Other causes include extremes of patient positioning (*e.g.*, head-down vertical inversion), blunt trauma (*e.g.*, a patient rubbing their eye postoperatively), vigorous coughing (*e.g.*, paroxysms associated with pertussis infection) or sneezing, Valsalva maneuver (*e.g.*, bearing down during labor or in patients with bulimia), systemic hypertension, ocular amyloidosis, aspirin intoxication, and acute conjunctivitis.³⁻⁸

After an extensive ophthalmologic evaluation, we were unable to determine the etiology of subconjuncti-

val hemorrhage in our patient. Potential etiologies include prone positioning and transient systemic hypertension. Patients undergoing spinal surgery are often placed in the prone position for extended periods of time. In the healthy patient, this is probably without consequence; however, in the patient with retinal vascular abnormalities, macular degeneration, ocular hypertension, glaucoma, and other similar disorders, this may contribute to serious postoperative ocular complications. Because the current patient's abdominal region was free of pressure during prone positioning, we doubt that her obesity was a causative factor. Specifically, care was taken to ensure that her abdomen was free of compression, thereby avoiding thoracic and ocular vascular congestion.

Fortunately, subconjunctival hemorrhage usually resolves spontaneously over 2 or 3 weeks with no long-term sequelae. Nonetheless, appropriate ophthalmologic examination is indicated to rule out the possibility of concurrent and more serious ocular injuries. In the current patient, ophthalmologic examination revealed no significant change in visual acuity and normal intraocular pressure, and she recovered from this event without adversity.

In summary, we present a unique case of perioperative subconjunctival hemorrhage. Despite the unsightly physical appearance of this disorder, long-term sequelae rarely occur. Nonetheless, careful ophthalmologic examination is essential to rule out more serious pathology.

References

1. Roth S, Thisted RA, Erickson JP, Black S, Schreider BD: Eye injuries after nonocular surgery. *ANESTHESIOLOGY* 1996; 85:1020-7
2. Gild WM, Posner KL, Caplan RA, Cheney FW: Eye injuries associated with anesthesia: A closed claims analysis. *ANESTHESIOLOGY* 1992; 76:204-8
3. Fukuyama J, Hayasaka S, Yamada K, Setogawa T: Causes of subconjunctival hemorrhage. *Ophthalmologica* 1990; 200:63-7
4. Paysse EA, Coats DK: Bilateral eyelid ecchymosis and subconjunctival hemorrhage associated with coughing paroxysms in pertussis infection. *J Am Assoc Pediatr Ophthalmol Stabismus* 1998; 2:116-9
5. Weinstein HD, Halabis JA: Subconjunctival hemorrhage in bulimia. *J Am Optom Assoc* 1986; 57:366-7
6. Lee HM, Naor J, DeAngelis D, Rootman DS: Primary localized conjunctival amyloidosis presenting with recurrence of subconjunctival hemorrhage. *Am J Ophthalmol* 2000; 129:245-7
7. Black RA, Bensinger RE: Bilateral subconjunctival hemorrhage after acetylsalicylic acid overdose. *Ann Ophthalmol* 1982; 14:1024-5
8. Wright PW, Strauss GH, Langford MP: Acute hemorrhagic conjunctivitis. *Am Fam Physician* 1992; 45:173-8