

Late Onset of Cortical Blindness in a Patient with Severe Preeclampsia Related to Retained Placental Fragments

Didier Delefosse, M.D.,* Emmanuel Samain, M.D., Ph.D.,† Annick Hélias, M.D.,‡ Jean-Marc Regimbeau, M.D.,§ Bruno Deval, M.D.,|| Eviane Farah, M.D.,* Jean Marty, M.D.#

CORTICAL blindness occurs in approximately 1–3% of preeclampsia and eclampsia patients.^{1–3} It was reported to occur either before or during the first few days after delivery.⁴ We report a case of a preeclamptic parturient who suffered transient cortical blindness 26 days after cesarean delivery, related to undiagnosed retained placental fragments.

Case Report

A 33-yr-old, gravida 2, para 1 parturient was admitted at 38 weeks' gestation with a chief complaint of abdominal pain. Preeclampsia was diagnosed by the presence of elevated systemic arterial blood pressure (170/100 mmHg) and proteinuria. Physical examination revealed hyperreflexic limbs. Blood tests showed a moderate elevation in liver enzymes (aspartate aminotransferase, 121 U/l) and hyperuricemia (343 μM). Hypertension was controlled with intravenous nicardipine, and an emergent cesarean delivery was performed on the day of admission, using general anesthesia. The patient recovered rapidly from anesthesia, and the results of a neurologic examination performed 2 h later were normal, except for hyperreflexic limbs.

The patient's clinical condition worsened during the first three postoperative days (POD), with the onset of severe hemolysis, elevated liver enzymes, and low platelet count syndrome (aspartate aminotransferase, 4,238 U/l; platelet count, 50,000/ml; and hemolysis, confirmed by elevated nonconjugated bilirubin concentration [59 μM] and decreased haptoglobin concentration). Respiratory distress with severe hypoxemia related to pulmonary edema occurred on POD1, requiring tracheal intubation, mechanical ventilation, and sedation. Acute renal failure (oliguria and creatinine clearance < 5 ml/min) was observed on POD2. A transesophageal echocardiogram ruled out left ventricular dysfunction, and pulmonary artery monitoring was used to optimize hemodynamic status. A head computed tomography (CT) scan without contrast, performed on POD 1 to eliminate intracerebral hemorrhage as a possible diagnosis, was within the normal limits. Three days after admission, a sudden decrease in arterial blood pressure led to the diagnosis of intraabdominal hemorrhage, as well as a subcapsular hematoma of the liver. At this time, CT scan morphology of the uterus was considered normal, with a hyperdensity in the uterine cavity, only suggesting a small amount of

intrauterine blood. Intraabdominal blood was surgically evacuated, but the liver was left intact since the Glisson capsule was not ruptured.

The patient's condition improved gradually thereafter. Arterial blood pressure, renal and respiratory function, liver enzyme concentration, and platelet count were all normal by 15 days after delivery. Intravenous sedation was stopped after 1 week, but recovery was slow, and the level of consciousness was sufficient to allow tracheal extubation on POD 14 only. The patient was sleepy, able to be aroused only after verbal stimulation, and confused. The results of a cerebral CT scan performed at this time were normal, and an electroencephalogram revealed diffuse slow waves. The patient's state of consciousness improved gradually, and she was able to perform everyday tasks such as washing, eating without any help, and pouring water into a glass. The results of formal neurologic examinations, repeated several times during this period, were normal.

Three weeks after delivery, hypertension recurred, and treatment with nicardipine was reinitiated. On POD 26, the patient was suddenly unable to perform routine tasks because of complete blindness. Results of a fundoscopic examination were normal, pupils were symmetrical and reacted normally to light, and the patient did not react to threat. The results of the remainder of her neurologic examination were normal. Electroencephalography revealed focal posterior paroxysmal spike activity that was unresponsive to intravenous clonazepam and sodium valproate and could only be suppressed with intravenous phenytoin. Head CT scan revealed bilateral occipital hypodensity. Axial T₂-weighted magnetic resonance (MR) images with fluid-attenuated inversion recovery sequences showed bilateral hypersignal in the occipital, temporal, and parietal regions, suggesting focal cerebral edema (fig. 1). A recurrence of preeclampsia was suspected. Ultrasound evaluation of the uterus detected echogenic fragments in the uterine cavity. These were removed during a hysteroscopic procedure with general anesthesia. Histologic analysis revealed the presence of placental tissues, including necrotized villi.

The patient's clinical condition rapidly improved after surgery. She was able to distinguish bright light 12 h after curettage, and she could identify the shape of usual items after 48 h. Visual function was considered normal by the ophthalmologist after 4 days. Within 1 week, arterial blood pressure was normalized, level of consciousness was improved, and electroencephalographic abnormalities disappeared. A week later, occipital hypersignal on T₂-weighted MR imaging had nearly disappeared. The patient was discharged 38 days after cesarean section delivery.

Discussion

The present case illustrates an uncommon evolution of severe preeclampsia with secondary onset of neurologic symptoms associated with intrauterine retention of placental products.

An initial improvement in preeclampsia-related symptoms is common after delivery, but relapse often occurs within 24 h. In our case, severe hepatic, hematologic, cardiovascular, and renal complications occurred in a classic timing, within the first 3 days after delivery.⁵ Our

* Staff Anesthesiologist, † Professor, ‡ Professor and Department Head, Department of Anesthesiology, § Staff Radiologist, Department of Radiology, ¶ Assistant Professor, Department of General Surgery, || Staff Obstetrician, Department of Obstetrics and Gynecology.

Received from the Department of Anesthesiology, Beaujon Hospital, Assistance Publique-Hôpitaux de Paris, Clichy, France. Submitted for publication March 6, 2002. Accepted for publication July 30, 2002. Support was provided solely from institutional and/or departmental sources.

Address reprint requests to Dr. Samain: Department of Anesthesiology, Beaujon Hospital, Assistance Publique-Hôpitaux de Paris, University Xavier Bichat Paris 7, 100 Boulevard Général Leclerc, 92118 Clichy Cedex, France. Address electronic mail to: emmanuel.samain@bjn.ap-hop-paris.fr. Individual article reprints may be purchased through the Journal Web site, www.anesthesiology.org.

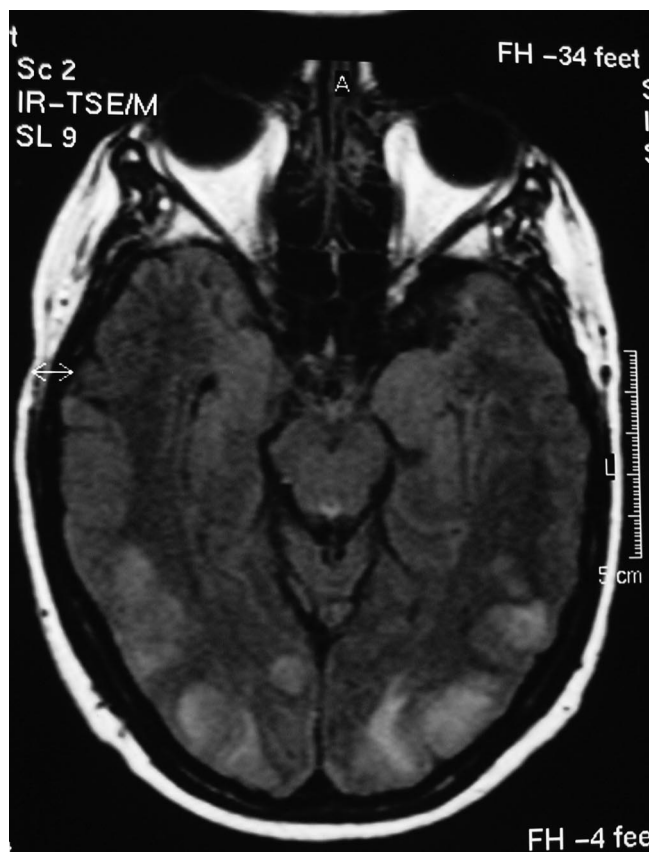

Fig. 1. Axial T₂-weighted magnetic resonance (MR) image of the brain with fluid-attenuated inversion recovery sequences performed at the onset of cortical blindness on postoperative day 26. The MR image shows bilateral hypersignal in the occipital, temporal, and parietal regions, suggesting focal cerebral edema.

patient's very slow clinical improvement during the first 3 weeks was less expected, since recovery is usually complete within 1 week. However, persistent elevated blood pressure related to preeclampsia has been described 6 weeks postpartum.⁶

In contrast, the recurrence of hypertension and delayed onset of focal occipital seizures and cortical blindness are very uncommon. Because preeclampsia can only occur in the presence of a placenta, the hypothesis of placental tissue retention should be considered when unusual evolution is observed after delivery. In our case, it should have been suggested as soon as hypertension returned on POD 21. Physiopathologic alterations of preeclampsia and eclampsia are the result of an initial placental trigger and a maternal systemic response.⁷ Maternal symptoms are related to the synthesis of placentally derived vasoactive substances and to abnormal maternal systemic inflammatory response to an overload of placental debris shed from the syncytiotrophoblast into maternal circulation.^{8,9} Our case shows that even a small quantity of necrotized villous tissue retained in the uterine cavity can result in persistent preeclampsia and lead to further worsening of neurologic symptoms.

We arrived at the diagnosis of retained placenta very

late in our observation of the patient. Despite spontaneous separation and controlled cord traction, it is sometimes difficult to ascertain that the entire placenta has been delivered.¹⁰ Placental retention has been reported to result in several complications, including bleeding, sepsis, and pain. In our case, postoperative uterine contraction and bleeding were considered to be nonspecific, despite severe blood coagulation disorders. An abdominal CT scan performed on POD 3 only showed hyperdensity in the uterine cavity, suggesting a small amount of intrauterine blood, and the diagnosis of retained placental products was suspected because of the recurrence of preeclampsia-related symptoms.

Although visual disturbances are common in severe preeclampsia, cortical blindness is rare, with an incidence of 1-3% and 3-14% in preeclamptic and eclamptic patients, respectively.² Blindness may be the primary clinical presentation of preeclampsia and may be isolated or associated with an altered state of consciousness.⁴ In eclampsia, it may precede seizures for several hours.² Patients may experience a complete loss of vision or may still perceive bright light shone directly into their eyes.¹¹ The diagnosis should be evoked in the presence of loss of vision when (1) normal ophthalmoscopic examination results rule out retinal disease and (2) normal pupillary response to light and absence of blinking in response to threat suggest postgeniculate insult. Several pathologic features have been proposed to explain the neuropathologic mechanism of cerebral insult in eclampsia-related cortical blindness. Cerebral vasogenic edema in the cortex and subcortical white matter in the occipital lobes is commonly seen on MR imaging.¹¹⁻¹³ An alteration in posterior cerebral blood flow autoregulation also has been suggested to favor arterial vasoconstriction and cerebral ischemia.¹⁴ Rarely, microinfarctions and focal hemorrhage may contribute to cerebral dysfunction.^{2,15} Cerebral imaging is of major importance in the diagnosis of cortical blindness. Head CT scan may reveal occipital hypodensities suggesting cerebral edema, described recently as posterior leukoencephalopathy syndrome.¹⁶ It is helpful to rule out hemorrhage and to detect thromboembolic phenomena. Occasionally, the head CT scan may be within normal limits, suggesting that the transient and limited extent of increased fluid shift may be beyond the resolution of a CT scan.¹¹ MR imaging is increasingly used for the diagnosis of cortical blindness, since it exhibits superior soft tissue contrast and multiplanar resolution. It is the technique of choice to obtain images of the visual pathways.¹¹ Hyperintense signal lesions on T₂-weighted MR images are consistent with focal edema.

Management of preeclamptic or eclamptic women in whom cortical blindness develops is the same as for patients without this complication, and the management guidelines are now straightforward.⁶ Delivery should not be postponed unnecessarily, and the prognosis of corti-

cal blindness is good, with a mean (\pm SD) duration of blindness of 34 ± 27 and 92 ± 67 h in eclamptic and preeclamptic patients, respectively.² Scotomas or long-lasting alterations in visual function are uncommon and are typically related to severe focal ischemia or hemorrhage.

In conclusion, this case illustrates that retention of placental tissue should be suspected in the presence of an unusual evolution of preeclampsia-related symptoms. Uterine vacuity should be assessed even when placental delivery is considered to be complete, since it is the key to treating preeclampsia.

References

- Nalliah S, Thavarashah AS: Transient blindness in pregnancy induced by hypertension. *Int J Gynaecol Obstet* 1989; 29:249-51
- Cunningham FG, Fernandez CO, Hernandez C: Blindness associated with preeclampsia and eclampsia. *Am J Obstet Gynecol* 1995; 172:1291-8
- Borromeo CJ, Blike GT, Wiley CW, Hirsch JA: Cortical blindness in a preeclamptic patient after a cesarean delivery complicated by hypotension. *Anesth Analg* 2000; 91:609-11
- Goodlin RC, Strieb E, Sun SF, Cox TA, Williams NE: Cortical blindness as the initial symptom in severe preeclampsia. *Am J Obstet Gynecol* 1983; 147:841-2
- Ebert AD, Hopp HS, Entezami M, Runkel S, Weitzel HK: Acute onset of blindness during labor: Report of a case of transient cortical blindness in association with HELLP syndrome. *Eur J Obstet Gynecol Reprod Biol* 1999; 84:111-3
- Walker JJ: Pre-eclampsia. *Lancet* 2000; 356:1260-5
- Meekins JW, Pijnenborg R, Hanssens M, McFadyen IR, van Asshe A: A study of placental bed spiral arteries and trophoblast invasion in normal and severe pre-eclamptic pregnancies. *Br J Obstet Gynaecol* 1994; 101:669-74
- Jankowski J, Yoon MS, Stephan N, Zidek W, Schluter H: Vasoactive diadenosine polyphosphates in human placenta: Possible candidates in the pathophysiology of pre-eclampsia? *J Hypertens* 2001; 19:567-73
- Redman CW, Sargent IL: The pathogenesis of pre-eclampsia. *Gynecol Obstet Fertil* 2001; 29:518-22
- Wilkinson C, Enkin MW: Manual removal of placenta at caesarean section. *Cochrane Database Syst Rev* 2000; 2:CD000130
- Herzog TJ, Angel OH, Karram MM, Evertson LR: Use of magnetic resonance imaging in the diagnosis of cortical blindness in pregnancy. *Obstet Gynecol* 1990; 76:980-2
- Kesler A, Kaneti H, Kidron D: Transient cortical blindness in preeclampsia with indication of generalized vascular endothelial damage. *J Neuroophthalmol* 1998; 18:163-5
- Schwartz RB, Jones KM, Kalina P, Bajakian RL, Mantello MT, Garada B, Holman BL: Hypertensive encephalopathy: Findings on CT, MR imaging, and SPECT imaging in 14 cases. *AJR Am J Roentgenol* 1992; 159:379-83
- Torres PJ, Antolin E, Gratacos E, Chamorro A, Cararach V: Cortical blindness in preeclampsia: Diagnostic evaluation by transcranial Doppler and magnetic resonance imaging techniques. *Acta Obstet Gynecol Scand* 1995; 74:642-4
- Drislane FW, Wang AM: Multifocal cerebral hemorrhage in eclampsia and severe pre-eclampsia. *J Neurol* 1997; 244:194-8
- Pavlikis SG, Frank Y, Chusid R: Hypertensive encephalopathy, reversible occipitoparietal encephalopathy, or reversible posterior leukoencephalopathy: Three names for an old syndrome. *J Child Neurol* 1999; 14:277-81

Anesthesiology 2003; 98:263-5

© 2003 American Society of Anesthesiologists, Inc. Lippincott Williams & Wilkins, Inc.

The Use of WuScope Fiberoptic Laryngoscopy for Tracheal Intubation in Complex Clinical Situations

Juraj Sprung, M.D., Ph.D.,* Toby Weingarten, M.D.,† John Dilger, M.D.‡

THE WuScope system (Achi Corp., Fremont, CA, and Asahi Optical Co., Pentax, Tokyo, Japan) is a fiberoptic laryngoscopy system composed of a curved, tubular, bivalved, rigid blade and a flexible fiberscope.¹ The WuScope system integrates the features of both rigid and flexible laryngoscopy and eliminates the shortcomings of each. We describe two complex clinical situations in which the use of a WuScope laryngoscope resulted in successful endotracheal intubations.

Case Reports

Case 1

A 67-yr-old, morbidly obese woman (160 cm, 125 kg) was brought to the emergency room by a paramedic unit after developing acute neck expansion at home. She had undergone left carotid endarterectomy 6 days previously. While in the ambulance, her neck swelling continued to expand despite the external compression applied by paramedic

personnel. Her breathing became stridulous, resulting in severe respiratory distress, and she became unconscious. The paramedic team attempted tracheal intubation without success, and they performed mask ventilation until arrival at the emergency room. An emergency room physician attempted tracheal intubation without success; therefore, an emergency cricothyrotomy was performed, and a 6-mm endotracheal tube (ETT) was inserted into the trachea. After tube insertion, an electrocardiogram revealed asystole, and cardiopulmonary resuscitation was initiated. Two minutes later, sinus tachycardia was established, and the patient was transferred to the operating room for carotid artery repair. Throughout the entire emergency room course and transfer to the operating room, a surgical resident maintained pressure over the expanding neck and cricothyrotomy site, which also was bleeding. The patient was anesthetized with isoflurane and fentanyl, and muscle relaxation was achieved with cisatracurium. Lung ventilation through the small ETT became extremely difficult, requiring ventilation with peak inspiratory pressures of 65 cm H₂O. The oxyhemoglobin saturation, assessed by pulse oximetry, ranged between 85 and 89% on fraction of inspired oxygen (FIO₂) 1.0. As soon as the surgeon controlled the carotid artery bleeding, we decided to exchange the ETT. The large adult WuScope was preloaded with an 8.0-mm ETT. With uninterrupted lung ventilation, the WuScope blade was inserted through the middle of the mouth, and the vocal cords were visualized despite the fact that the posterior left pharyngeal wall was bulging toward the glottis. Under direct vision, the new ETT was placed through the glottic opening without difficulty. After confirming adequate lung ventilation, the original ETT was withdrawn. The new ETT was then advanced beyond the cricothyrotomy incision (fig. 1). Lung ventilation immediately improved, with peak pressures below 30 cm H₂O, while oxyhemoglobin saturation increased to 99%. Examination of the removed ETT revealed blood clots that narrowed its internal diameter, explaining the difficulty in ventilating.

* Senior Associate Consultant and Professor of Anesthesiology, † Resident in Anesthesiology, ‡ Senior Associate Consultant and Assistant Professor of Anesthesiology.

Received from the Department of Anesthesiology, Mayo Clinic, Rochester, Minnesota. Submitted for publication May 14, 2002. Accepted for publication July 30, 2002. Support was provided solely from institutional and/or departmental sources.

Address reprint requests to Dr. Sprung: Department of Anesthesiology, Mayo Medical School, Charlton 1-145, Mayo Clinic, 200 First Street Southwest, Rochester, Minnesota 55905. Address electronic mail to: Sprung.juraj@mayo.edu. Individual article reprints may be purchased through the Journal Web site, www.anesthesiology.org.

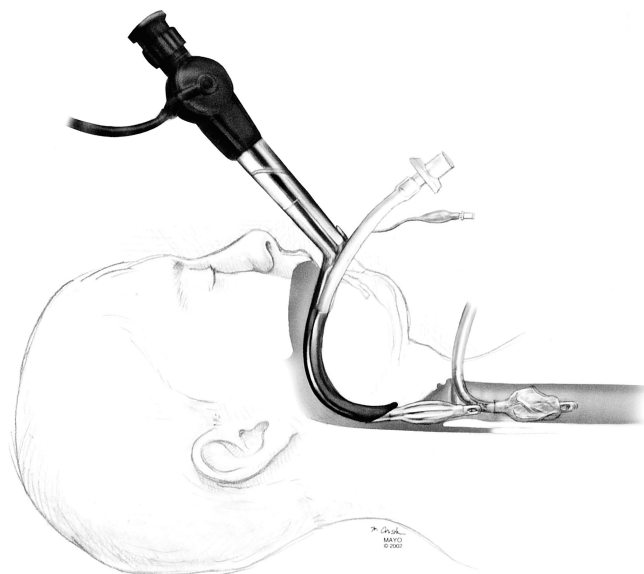


Fig. 1. Schematic representation of an endotracheal tube (ETT) inserted through the cricothyrotomy site and simultaneous ETT exchange *via* oral intubation aided by the WuScope laryngoscope (see Case 1).

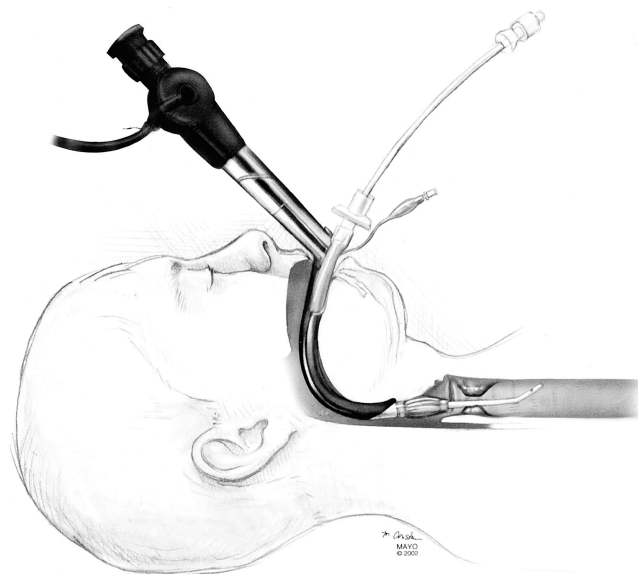


Fig. 2. WuScope system-aided tracheal intubation in a patient with a glottic tumor. Endotracheal tube placement was preceded by airway exchange catheter (see Case 2).

Case 2

A 58-yr-old woman (162 cm, 60 kg) with a history of laryngeal papillomatosis was admitted for her third laryngeal surgery—laser tumor debulking. While sitting in the bed, her voice was hoarse, and her breathing was stridulous. After anesthesia was induced for the first surgery, the vocal cords could not be visualized with direct laryngoscopy. At that time, the ETT was placed blindly, aided by an intubating stylet, which resulted in bleeding from the traumatized tissues. For her second surgery, fiberoptic intubation was attempted, and although the fiberoptic bronchoscope was successfully placed into trachea without bleeding, the ETT could not be passed through the glottis. Attempts to forcefully insert the ETT over the fiberoptic bronchoscope resulted in massive oral bleeding, necessitating the establishment of an emergency surgical airway. For the present surgery, the plan for tracheal intubation included WuScope-assisted, awake intubation, with an otolaryngologist standing by to perform an emergency tracheostomy if needed. After sedation with 1 mg midazolam and 50 μ g fentanyl, we anesthetized the oropharynx with the patient in the sitting position. Once we had achieved adequate oropharyngeal anesthesia, we lowered the bed to a semisitting position and inserted the adult WuScope blade through the middle of the mouth. The patient's glottic opening was narrow due to extensive tumor growth. We introduced an airway exchange catheter (AEC; Cook Critical Care, Bloomington, IN), first through the WuScope preloaded ETT and then through the narrow glottic opening. The placement of the AEC through the glottis was achieved without bleeding, and the patient tolerated it well. Then we used a well-lubricated, 5.5-mm laser ETT and passed it with some difficulty through the narrow vocal cords (fig. 2). This was followed by administration of propofol. The glottic bleeding, present after the placement of the ETT, was controlled with laser coagulation. During a 60-min laser surgery, total intravenous anesthesia was maintained with propofol-alfentanil infusion and an air-oxygen mixture ($F_{IO_2} = 0.25$). At the completion of the surgery and prior to tracheal extubation, we instilled 2% lidocaine through the ETT and allowed the patient to awaken. With the patient fully awake, we deflated the tracheal cuff and tested her ability to breathe around the occluded

ETT. Then we reintroduced the AEC through the ETT into the trachea. The ETT was taken out, with the AEC left in the trachea and taped to the face with a depth marker showing 23 cm at the lip, and the patient was sent to the recovery room. The AEC was removed 1 h later, when there were no signs of breathing difficulty. The patient was discharged to home the next day.

Discussion

The WuScope system is a fiberoptic intubating device that combines a fiberoptic scope with a rigid laryngoscope.¹ It allows tracheal intubation without the need for head extension, tongue lifting, or forceful jaw opening, because a 110° handle-to-blade angle allows easy visualization of the glottis in many difficult clinical situations.²⁻⁵ The WuScope is typically inserted in the midline of the mouth. The handle is then rotated toward the laryngoscopist, with the blade gently advanced across the convexity of the tongue. Once the larynx is visualized, the ETT may be advanced between the cords under direct vision, as we did in our first patient. Manipulating the scope side to side or back and forth may be needed to optimize the laryngeal view and to facilitate direction of the ETT toward the glottis. Alternatively, a suction catheter or AEC may be advanced through the ETT into the trachea. This catheter serves as a stylet, which directs the ETT through the glottis.

Expanding neck hematoma after carotid endarterectomy represents one of the most emergent and difficult situations for tracheal intubation. Attempts to intubate the trachea by direct laryngoscopy may be impossible

when the airway anatomy is distorted. ETT exchange in these cases may pose substantial risk for the patient. We were unable to perform adequate ventilation through the small and obstructed (because of blood clots) ETT inserted through the cricothyroidotomy; therefore, we needed to replace the ETT. Bleeding around the cricothyroidotomy incision and low oxyhemoglobin saturations were viewed as risks for the ETT exchange through the same incision, as even a short period of interrupted ventilation could have had catastrophic consequences for this patient. We decided to exchange the ETT by using WuScope rigid laryngoscopy. In this case, tracheal intubation was performed without the use of stylet guidance. The design of the WuScope overcomes some complex anatomic obstacles, and the blade design offers both easy entrance into the oropharynx and visualization of the anteriorly positioned glottic opening. At the same time, the tubular blade protects the fiberscope lens from secretions, blood, or redundant tissues better than during flexible fiberoptic intubation.

In our second patient, conventional fiberoptic intubation and attempts to place the ETT resulted in massive glottic hemorrhage during her previous surgery. We opted to use the WuScope system for intubation. The WuScope allowed direct visualization of the tumorous glottis and atraumatic insertion of the jet-endotracheal tube exchanger. Once passed beyond the glottis, this

exchanger would have allowed the use of jet ventilation if difficulties had occurred. We consequently successfully intubated the trachea with minimal trauma. Because laser surgery can result in delayed swelling with consequent airway compromise,^{6,7} we monitored the patient for 24 h before her uneventful discharge.

In conclusion, WuScope rigid laryngoscopy may be used in some very complex clinical situations. However, as with any other technique, failure to intubate may occur even with this technique. Experience with the WuScope system should be acquired first on uncomplicated airways before attempting its use on difficult airways.

References

1. Wu TL, Chou HC: A new laryngoscope: The combination intubating device. *ANESTHESIOLOGY* 1994; 81:1085-7
2. Wu TL, Chou HC: WuScope versus conventional laryngoscope in cervical spine immobilization. *ANESTHESIOLOGY* 2000; 93:588-9
3. Andrews SR, Norcross SD, Mabey MF, Siegel JB: The WuScope technique for endotracheal tube exchange. *ANESTHESIOLOGY* 1999; 90:929-30
4. Andrews SR, Mabey MF: Tubular fiberoptic laryngoscope (WuScope) and lingual tonsil airway obstruction. *ANESTHESIOLOGY* 2000; 93:904-5
5. Smith CE, Kareti M: Fiberoptic laryngoscopy (WuScope) for double-lumen endobronchial tube placement in two difficult-intubation patients. *ANESTHESIOLOGY* 2000; 93:906-7
6. Dumon JF, Shapshay S, Bourcereau J, Cavaliere S, Meric B, Garbi N, Beamis J: Principles for safety in application of neodymium-YAG laser in bronchology. *Chest* 1984; 86:163-8
7. Chakraverty SC, Rafferty PR: Laser therapy for endobronchial tumours. *Scott Med J* 1992; 37:141-3

Anesthesiology 2003; 98:265-8

© 2003 American Society of Anesthesiologists, Inc. Lippincott Williams & Wilkins, Inc.

Hemodynamic Instability and Delayed Emergence from General Anesthesia Associated with Inadvertent Intrathecal Baclofen Overdose

Michael A. Lyew, M.D.,* Christina Mondy, M.S., C.R.N.A.,† Susan Eagle, M.D.,‡ Sandra E. Chernich, P.A.§

MUSCLE spasticity is a feature of cerebral palsy that is due to simultaneous contraction of agonist and antagonist muscle groups. Descending inhibitory interneurons are affected, causing an excess of excitatory neurotransmitters and inadequate release of γ -aminobutyric acid (GABA) in the spinal cord. Overstimulation of α motor neurons results in these contractions. Baclofen (Novartis Pharma AG, Basel, Switzerland) acts as an agonist at the

GABA_B receptors in the dorsal horn of the spinal cord and reduces the tone and pain associated with muscle spasms.¹ Intrathecal administration of the drug reduces spasticity at lower doses than are needed orally and with fewer side effects. These side effects include bradycardia and hypotension during general anesthesia and delayed arousal after surgery, all of which have been reported in patients who were taking oral baclofen preoperatively.^{2,3} We describe a case in which these features occurred in association with the intrathecal administration of baclofen.

Case Report

A 9-yr-old, 19.4-kg child with cerebral palsy was admitted with a history of fluid accumulation over a SynchroMed[®] (Medtronic, Minneapolis, MN) baclofen infusion pump. The pump had been subfascially implanted 3 yr prior to this event. The catheter entered the intrathecal space in the lumbar region, and its tip was located in the mid to upper thoracic region. An abdominal roentgenogram showed a fracture of the catheter at its hub connection to the port of the pump. The patient was

* Associate Clinical Professor, † Staff Anesthetist, ‡ Resident, Department of Anesthesiology, Children's Medical Center, § Physician Assistant, Department of Neurosurgery.

Received from the Department of Anesthesiology, Children's Medical Center, and the Department of Neurosurgery, Medical College of Georgia, Augusta, Georgia. Submitted for publication April 22, 2002. Accepted for publication July 31, 2002. Support was provided solely from institutional and/or departmental sources.

Address reprint requests to Dr. Lyew: Department of Pediatric Anesthesiology, Children's Medical Center, Medical College of Georgia, BT 2651, 1446 Harper Street, Augusta, Georgia 30912. Address electronic mail to: mlyew@mail.mcg.edu. Individual article reprints may be purchased through the Journal Web site, www.anesthesiology.org.

alert, with a history of increased muscle spasms. His other medications included oral ranitidine and transdermal scopolamine for control of gastroesophageal reflux and nausea. The patient's blood pressure and heart rate were 113/85 mmHg and 89 beats/min, respectively. No premedication was given.

Anesthesia was induced with 100 mg thiopental and 50 μ g fentanyl. Rocuronium, 20 mg, was used to facilitate tracheal intubation. Anesthesia was initially maintained with 0.5% isoflurane and 70% nitrous oxide in oxygen. The pump was programmed to stop infusing baclofen (2,000 μ g/ml) shortly after induction. Over the next 30 min, the patient's blood pressure and heart rate were noted to decrease to 55-60/30-40 mmHg and 55 beats/min, respectively, despite discontinuation of the inhalational agent and the onset of surgery. Volume administration and intravenous glycopyrrolate, 0.1 mg, increased the heart rate to 100 beats/min and increased the blood pressure to 80/45 mmHg. The oxygen saturation remained at 98-100% throughout the procedure. The fractured hub connector was removed and replaced with a two-piece catheter that was trimmed and spliced to the existing catheter. Residual baclofen solution and cerebrospinal fluid was allowed to drain back through the repaired catheter before it was attached to the pump. The pump was then reprogrammed to deliver a bolus of 777 μ g baclofen (0.3 ml) to prime the catheter and then to infuse at a rate of 15.6 μ g/h. At the end of the procedure, which lasted 1 h, we noticed that the patient was unresponsive despite adequate reversal of neuromuscular blockade. The pupils were 2 mm in size. Intravenous naloxone was given in 20- μ g increments to a total of 120 μ g. Spontaneous ventilation and airway reflexes subsequently returned. When the patient started to awaken, he was extubated and transferred to the recovery room, with a blood pressure of 100/70 mmHg, a heart rate of 100 beats/min, and a respiratory rate of 20 breaths/min.

The patient then became more somnolent in the recovery room, despite gentle stimulation. His blood pressure and heart rate gradually decreased to 75/31 mmHg and 59-62 beats/min, respectively, 70 min after the pump was activated. His respiratory rate was 10 breaths/min, and his oxygen saturation, as measured by pulse oximetry, was 100% on 30% inhaled oxygen. Venous blood glucose concentration was 90 mg/dl. No improvement in consciousness level occurred after administration of 5 g dextrose or after further administration of naloxone. The pupils were midsized. Volume administration and atropine, 0.3 mg, increased the heart rate to 80-90 beats/min and increased the blood pressure to 80/40 mmHg. At this time, it was realized that the administered bolus dose of baclofen may have been greater than was necessary to prime the catheter. The pump was turned off, and the patient, still unconscious but breathing at 15-20 breaths/min, was admitted overnight to the pediatric intensive care unit for observation. Two further doses of atropine, 0.3 mg, were given to maintain the heart rate in the 80-90 beats/min range.

Twelve hours after the bolus dose was given, the patient began to awaken. The intrathecal baclofen infusion was resumed at a rate of 375 μ g/24 h. However, the patient again became unconscious 4 h after starting at this rate, so the infusion was stopped again. When consciousness returned, the infusion was started at 99.8 μ g/24 h, with no further recurrence of coma. The patient's blood pressure and heart rate returned to baseline values. A subsequent increase in the infusion rate to 150 μ g/24 h also did not affect consciousness. The patient was discharged in stable condition at a final rate of 250 μ g/24 h on the third postoperative day.

Discussion

There are two major indications for the use of intrathecal baclofen in patients with cerebral palsy. The first is to improve the ability of patients with spastic diplegia or quadriplegia to ambulate with or without external

aids. The second indication is a reduction of tone in nonambulatory patients with severe spasticity to expedite their nursing care.⁴ At a preoperative screening trial, bolus doses of 25-100 μ g of the drug are given intrathecally to assess their effect on muscle tone (Ashworth scale). The pump is later implanted if an improvement in tone is demonstrated. The pump is programmed with an external computer to deliver a bolus of drug, which fills the dead space of the pump and the intrathecal catheter, and then to provide a continuous infusion at a predetermined daily dosage. The priming bolus is calculated from the drug concentration, the internal pump tubing volume, and the implanted catheter volume, which is dependent on its length. The daily dosage is adjusted periodically to achieve the most optimal effect on tone. This dosage is not related to age or weight.⁵ A large variation in dose, ranging from 22 to 869 μ g/24 h, has been reported.⁴

Intrathecal infusion of baclofen results in much higher concentrations of the drug in cerebrospinal fluid than are achieved with oral administration; thus, there is a greater reduction in spastic tone and a lower incidence of cerebral side effects.⁶ When the intrathecal catheter tip is located in a midthoracic rather than a lower thoracic position, there is a greater improvement in upper extremity tone, without a decrease in the drug's effect on lower extremity tone, in children with quadriparetic spasticity. The midthoracic position also allows a reduction in daily dosages to achieve this effect because of the more even distribution of the drug in the cervical and lumbar cerebrospinal fluid.⁷ Intrathecal baclofen has a half-life of 5 h and a clearance rate of 30 ml/h when it is given either as a bolus or as an infusion.⁴

The anesthetic agents potentiated the central nervous system effects of baclofen to cause hypotension and bradycardia during surgery. In awake patients, baclofen does not have pronounced cardiovascular effects, although a mild hypotensive action occasionally is seen.⁸ In anesthetized animals, GABA and drugs that stimulate GABA receptors cause a decrease in arterial pressure and heart rate.⁹ Baclofen, which acts in part by stimulating central nervous system GABA receptors, may be synergistic with general anesthetics that potentiate GABA action on synaptic transmission. The result is a reduction in sympathetic outflow to the vasculature and to the heart.¹⁰ The effect may be augmented by fentanyl, which stimulates central vagal nuclei.¹¹ In addition, intrathecal baclofen is antinociceptive in several animal models.¹² GABA_b agonists may regulate the excitability of the primary afferent terminal in the dorsal gray matter of the spinal cord by reducing the release of transmitters from these terminals and by causing postsynaptic hyperpolarization. Spinal baclofen produces a dose-dependent inhibition of the C fiber-evoked activity in dorsal wide-dynamic range neurons.¹³ In contrast to animal studies,

a comparable analgesic effect of intrathecal baclofen has not, however, been consistently reported in humans.¹⁴

The effect of the baclofen bolus dose was superimposed on the increased sensitivity to anesthetic agents to cause unconsciousness to persist in the postoperative period. Bolus administration is more likely than infusion of the intrathecal drug to be associated with adverse events, such as sedation, bradycardia, hypotension, and respiratory depression. The side effects depend on the degree of the overdose, which determines the amount of drug that reaches and affects supraspinal receptors.¹⁵ Bolus administration at the upper to midthoracic level may cause earlier supraspinal diffusion and effects of the drug. In contrast to slow infusion, the initial drug distribution is influenced by the drug volume and density during bolus injection.¹⁶ The density of the 2,000- $\mu\text{g}/\text{ml}$ baclofen solution was determined to be 1.003 g/ml at 24°C. The value is similar to that previously obtained for the 500- $\mu\text{g}/\text{ml}$ solution at the same temperature.¹⁷ The specific gravity of the latter solution at 37°C was reported to be 0.9996. The specific gravity of the 2,000- $\mu\text{g}/\text{ml}$ solution is likely to be similar at body temperature. Thus, the solution, which is made up in normal saline, is isobaric or slightly hypobaric in relation to cerebrospinal fluid. The subsequent distribution of the drug is determined by its hydrophilic nature. Clearance rates obtained from bolus and infusion studies are similar, indicating that baclofen is cleared by rostral bulk flow of cerebrospinal fluid.⁴

Overdoses are more likely to be caused by human error in the programming or refill procedure than by pump malfunction.¹ The use of a high-concentration solution causes an overdose to occur easily because of the small priming volume. In our case, the calculated priming bolus was appropriate to fill the dead space of the pump and the catheter. As the pump was undisturbed, its dead space was already filled with baclofen, so that a smaller dose (0.1–0.15 ml) was needed to fill the catheter. Thus, about 0.2 ml (400 μg) was administered by bolus into the spinal fluid. Alternative factors that cause delayed awakening after general anesthesia, such as other medications, metabolic disturbances, and neurologic injury, were excluded.³ Naloxone was given to fully reverse the sedative and respiratory depressant effects of fentanyl. Blood glucose and electrolyte concentrations were normal. Systemic uptake and redistribution to the brain were considered unlikely causes of early postoperative coma, although plasma baclofen concentrations were not measured. Systemic absorption of the high-concentration drug would most likely have occurred from the fluid pocket around the pump during surgery, as baclofen administered intrathecally is not associated with significant concentrations in the systemic circulation.⁴ The preoperative awake status of the patient suggests that plasma concentrations resulting from any absorption were insufficient to affect the con-

sciousness level. The lack of increased spasticity in the upper extremities in the early postoperative period indicated that there was rostral migration of the bolus dose to the cervical and supraspinal intrathecal areas, which was facilitated by the high spinal position of the catheter. The recurrence of coma, after initiation of the intrathecal infusion at the previous rate on the first postoperative day, may have indicated increased receptor sensitivity secondary to the decreased intrathecal baclofen concentrations caused preoperatively by leakage from the fractured catheter.¹⁸ Postoperative reduction in the infusion rate was therefore required.

Preoperative discontinuation of oral baclofen therapy has been advised to prevent the occurrence of severe hemodynamic instability during anesthesia.² However, similar discontinuation of intrathecal therapy may cause an increase in tone and muscle spasms before surgery in patients with cerebral palsy. Rapid withdrawal of intrathecal baclofen after chronic administration also has been associated with seizures, psychosis, hallucinations, and visual disturbances.¹⁹ Ephedrine, atropine, and epinephrine all have been reported to be effective in treating baclofen-induced hypotension and bradycardia during general anesthesia.² The emergency protocol, recommended in the case of an intrathecal baclofen overdose that causes coma and respiratory depression, advises maintaining the airway, breathing, and circulation; terminating the pump infusion (if necessary, by emptying the pump); and administering physostigmine, 0.02 mg/kg, at a rate of no more than 0.5 mg/min. The dose is repeated at 5–10-min intervals until a therapeutic effect is obtained or a maximum dose of 2 mg is given.²⁰ The drug was not given in our case. We decided to allow the patient to recover spontaneously with airway and circulatory support, as long as spontaneous ventilation and oxygenation were maintained. Lumbar puncture and withdrawal of 30–40 ml of cerebrospinal fluid, which can be assayed to show an abnormally high concentration, has also been used to reverse unconsciousness.⁴

In conclusion, intrathecal baclofen overdose should be considered as a possible cause of hemodynamic instability during pump or catheter revision procedures or of delayed emergence in the postoperative period. Increased sensitivity to anesthetic and analgesic agents warrants caution in the use of these drugs during surgery. Appropriate therapy should be readily available to treat cardiovascular, neurologic, and respiratory disturbances that may occur in association with the intrathecal medication.

References

1. Nolan J, Chalkiadis GA, Low J, Olesch CA, Brown TCK: Anesthesia and pain management in cerebral palsy. *Anaesthesia* 2000; 55:32–41
2. Sill JC, Schumacher K, Southorn PA, Reuter J, Yaksh TL: Bradycardia and hypotension associated with baclofen used during general anesthesia. *ANESTHESIOLOGY* 1986; 64:255–8

3. Gomar C, Carrero EJ: Delayed arousal after general anesthesia associated with baclofen. *ANESTHESIOLOGY* 1994; 81:1306-7
4. Albright AL: Baclofen in the treatment of cerebral palsy. *J Child Neurol* 1996; 11:77-83
5. Albright AL, Cervi A, Singletary J: Intrathecal baclofen for spasticity in cerebral palsy. *JAMA* 1991; 265:1418-22
6. Muller H, Zierski J, Dralle D, Kraub D, Mutschler E: Pharmacokinetics of intrathecal baclofen, Local Spinal Therapy of Spasticity. Edited by Muller H, Zierski J, Penn RD. New York, Springer, 1988, pp 223-6
7. Grabb PA, Guin-Renfroe S, Meythalen JM: Midthoracic catheter tip placement for intrathecal baclofen administration in children with quadriparetic spasticity. *Neurosurgery* 1999; 45:833-7
8. Pinto OD, Polikar M, Debono G: Results of international clinical trials with Lioresal. *Postgrad Med J* 1972; 48:18-23
9. Yamada KA, Normal WP, Hamosh P, Gillis RA: Medullary ventral surface GABA receptors affect respiratory and cardiovascular function. *Brain Res* 1982; 248:71-8
10. Williford DJ, Hamilton BL, Dias Souza J, Williams TP, DiMicco JA, Gillis RA: Central nervous system mechanisms involving GABA influence arterial pressure and heart rate in the cat. *Circ Res* 1980; 47:80-7
11. Bovill JG, Sebel PS, Stanley TH: Opioid analgesics in anesthesia: With reference to their use in cardiovascular anesthesia. *ANESTHESIOLOGY* 1984; 61: 731-55
12. Yaksh TL, Reddy SV: Studies in the primate on the analgesic effects associated with intrathecal actions of opiates, alpha-adrenergic agonists and baclofen. *ANESTHESIOLOGY* 1981; 54:451-67
13. Dickenson AH, Brewer CM, Hayes NA: Effects of topical baclofen on C fiber-evoked neuronal activity in the rat dorsal horn. *Neuroscience* 1985; 14: 557-62
14. Yaksh TL: A drug has to do what a drug has to do. *Anesth Analg* 1999; 89:1075-7
15. Armstrong RW, Steinbok P, Cochrane DD, Kube SD, Fife SE, Farrell K: Intrathecally administered baclofen for treatment of children with spasticity of cerebral origin. *J Neurosurg* 1997; 87:409-14
16. Kroin JS, Ali A, York M, Penn RD: The distribution of medication along the spinal canal after chronic intrathecal administration. *Neurosurgery* 1993; 33: 226-30
17. Nicol ME, Holdcroft A: Density of intrathecal agents. *Br. J Anaesth* 1992; 68:60-3
18. Delhaas EM, Brouwers JR: Intrathecal baclofen overdose: Report of 7 events in 5 patients and review of the literature. *Int J Clin Pharmacol Ther Toxicol* 1991; 29:274-80
19. Fromm GH, Terrence CF: Comparison of L-baclofen and racemic baclofen in trigeminal neuralgia. *Neurology* 1987; 37:1725-8
20. Medtronic: Lioresal Intrathecal (Baclofen Injection). Product Monograph. Minneapolis, MN, Medtronic, 2001

Anesthesiology 2003; 98:268-70

© 2003 American Society of Anesthesiologists, Inc. Lippincott Williams & Wilkins, Inc.

Selective Lobar Bronchial Blockade following Contralateral Pneumonectomy

Ju-Mei Ng, F.A.N.Z.C.A.,* Philip M. Hartigan, M.D.†

SINGLE-LUNG isolation is commonly utilized to facilitate surgical access for various thoracic procedures. In post-pneumonectomy patients requiring surgery in the remaining lung, selective isolation of a lobe may afford enhanced surgical access and may minimize injury to the lung tissue during surgical manipulation. We report two patients who had undergone left pneumonectomy—one who was scheduled for a partial sternotomy and exploration of a right neck mass, and another who was scheduled for right-sided pleurectomy—and the methods used for selective lobar blockade.

Case Report

Case 1

A 62-yr-old woman (162.5 cm, 44.5 kg) was diagnosed with recurrent cervicothoracic sarcoma. She had undergone a left pneumonectomy in 1989, followed by chemotherapy and radiotherapy; sternotomy with resection of mediastinal sarcoma in 1996; and distal pancreatectomy, splenectomy, left hemicolectomy, and left nephrectomy in 2000. She had developed stridor of 1 week's duration, and magnetic resonance imaging showed a 5 × 4 × 5 cm mass lying to the right of the esophagus, displacing and narrowing the trachea to the left, and 50% of its normal caliber just below the level of the clavicular

heads. The surgeon requested selective right upper lobe collapse to aid exploration and dissection of the right neck mass. Preoperative pulmonary function tests showed a forced vital capacity of 1.84 l and a forced expiratory volume in 1 s (FEV₁) of 1.48 l.

After induction of anesthesia, an 8.5-mm ID endotracheal tube (ETT) was inserted into the trachea without difficulty. Bronchoscopy showed a short left main bronchial stump, and both the right main bronchus and the bronchus intermedius were estimated to be 20 mm long.

The single-lumen ETT was removed; a 37-French left-sided double-lumen tube (DLT; Bronchopart®; Rüschi Inc., Duluth, GA) was inserted into the trachea during direct laryngoscopy and guided into the bronchus intermedius with a fiberoptic bronchoscope. The DLT was rotated 180° in the process. The bronchial orifice of the DLT was positioned just above the right middle and lower lobe orifices, with the proximal end of the inflated bronchial cuff at the upper lobe take off. With both cuffs inflated, the right middle and lower lobes were ventilated through the bronchial lumen, and the right upper lobe was allowed to collapse. Partial sternotomy was performed, with the incision extended to the right chest. The right upper lobe was well deflated, and good surgical access was obtained. Pressure control ventilation with a fraction of inspired oxygen (FIO₂) of 1.0 was utilized (peak inspiratory pressures kept < 30 cm H₂O, with adjustment of respiratory rate to maintain normocapnia), and oxygen saturation remained at 98-100%. Right neck exploration was performed. Prior to closure, the right upper lobe was reinflated by ventilating the tracheal lumen.

Case 2

A 65-yr-old woman (178 cm, 97 kg) had undergone a left extrapleural pneumonectomy for malignant mesothelioma 20 months earlier. She developed a recurrent right pleural effusion and underwent right pleuroscopy. Pleural biopsy showed recurrent malignant mesothelioma.

After induction of anesthesia with easy mask ventilation, direct laryngoscopy with a Macintosh blade revealed a Cormack and Lehane Grade 3 larynx. An 8/22-French bronchial blocker (Fogarty Occlusion Catheter model #62080822F; Baxter Healthcare Corp., Irvine, CA) was inserted into the trachea, utilizing a 45° bend at its tip, and an 8.5-mm

* Thoracic Anesthesia Fellow, † Assistant Professor of Anesthesia.

Received from the Department of Anesthesiology, Perioperative and Pain Medicine, Brigham and Women's Hospital, Harvard Medical School, Boston, Massachusetts. Submitted for publication April 24, 2002. Accepted for publication August 20, 2002. Support was provided solely from institutional and/or departmental sources.

Address reprint requests to Dr. Ng: Department of Anesthesiology, Perioperative and Pain Medicine, Brigham and Women's Hospital, Harvard Medical School, 75 Francis Street, Boston, MA 02115. Address electronic mail to: jng1@partners.org. Individual article reprints may be purchased through the Journal Web site, www.anesthesiology.org.

ETT was advanced over a fiberoptic bronchoscope and placed alongside the blocker. The blocker was guided into the bronchus intermedius fiberoptically, with its tip at the right middle and lower lobe orifices.

During stripping of the pleura from the upper lobe, the ETT was guided into the bronchus intermedius fiberoptically, and the cuff was inflated to occlude the right upper lobe orifice. Despite incomplete deflation of the right upper lobe, surgery proceeded easily, utilizing ventilation with small tidal volumes (300–350 ml) and adjusting the respiratory rate to maintain adequate minute ventilation. FiO_2 was 1.0 throughout. End-tidal carbon dioxide levels were between 38 and 45 mmHg, and oxygen saturation was maintained between 96 and 98%. The ETT was withdrawn into the trachea during surgery involving the lower half of the lung. During stripping of the pleura from the lower lobe and diaphragm, the Fogarty catheter could not be maneuvered into the right lower lobe bronchus to selectively collapse the lower lobe. It was therefore removed, and a wire-guided endobronchial blocker (WEB; Cook Inc., Bloomington, IN), coupled to a bronchoscope through a guide loop, was advanced until it exited the bronchoscope and entered the right lower lobe bronchus. Under direct visualization, the balloon was inflated with 6 ml of air to occlude the lower lobe bronchus. Airway pressures were kept below 30 cm H_2O , and oxygen saturation was maintained between 95 and 98%.

Discussion

The fine balance between providing satisfactory surgical exposure and maintaining adequate oxygenation is a challenge in postpneumonectomy patients presenting for surgery involving the contralateral hemithorax. Selective lobar bronchial blockade offers an attractive solution for targeted surgical access with preservation of ventilation of as much lung as possible.¹ However, not all postpneumonectomy patients will tolerate selective lobar bronchial blockade, and alternative solutions include low-tidal volume ventilation or high-frequency jet ventilation.²

Selective lobar bronchial blockade can be provided by endobronchial intubation with a single-lumen tube, DLTs, bronchial blockers, or a single-lumen endotracheal tube with an enclosed bronchial blocker (Univent[®] tube; Vitaid, New York, NY). The choice depends on the anatomy of the patient's tracheobronchial tree, airway pathology, and the physician's familiarity with the equipment and planned surgery. Selective lobar bronchial blocking with a bronchial blocker has been used in pediatric video-assisted thoracic surgery,^{3,4} to improve arterial oxygen saturation during hemorrhage in a patient who has undergone a previous contralateral lobectomy,⁵ in the management of bronchopleural fistula,⁶ and in emergency pulmonary hemorrhage.⁷ An intentionally malpositioned right-sided DLT has been used to selectively block the right upper lobe bronchus in life-threatening hemoptysis.⁸

The use of a left-sided DLT on the right side has been used to occlude the right upper lobe orifice in hemorrhage^{9,10} and during bilateral sequential lung transplantation, after transplantation of the right lung.¹¹ This is the first report of the use of a left-sided DLT on the right

side to selectively occlude the right upper lobe bronchus during thoracic surgery in a patient who had undergone a left pneumonectomy.

To collapse the right upper lobe, a DLT was chosen over a bronchial blocker, as we felt that it might be difficult to guide the blocker into the right upper lobe bronchus due to the acute angle of the bronchus to the right main stem and the risk of dislodgement from this short upper lobe bronchus during surgical manipulation. Endobronchial intubation with a single-lumen ETT would necessitate repositioning if the right upper lobe needed to be reinflated emergently or at the end of surgery, and it also will not allow application of continuous positive airway pressure (CPAP) if required. A malpositioned right-sided DLT can be used to occlude the right upper lobe orifice,⁸ and the upper lobe can be reinflated by deflating the bronchial cuff, but CPAP cannot be applied to the right upper lobe.

Although problems with the use of a left-sided DLT on the right side may arise,¹¹ we did not experience any difficulty in placing the left-sided DLT into the bronchus intermedius, and the DLT did not kink in the oropharynx. With the bronchial lumen just above the middle and lower lobe orifices and the tracheal lumen above the carina, selective ventilation of the right upper lobe (*via* the tracheal lumen) and both the middle and lower lobes through the bronchial lumen was achievable without having to reposition the tube. The distance from the bronchial orifice to the proximal end of the bronchial cuff of the 37-French DLT (selected according to the patient's height) used was 21 mm, and that was ideal in our patient whose bronchus intermedius was estimated to be 20 mm long. This method worked well to give good deflation of the right upper lobe during surgery, and the lobe reinflated readily before chest closure on ventilation through the tracheal lumen. If the length of the bronchus intermedius is shorter than the distance from the bronchial tip to the proximal end of the bronchial cuff in the particular DLT used, the cuff itself occludes the right upper lobe orifice. Although this may give good deflation of the right upper lobe, more precise positioning of this small bronchial cuff may be required, and, similar to a malpositioned right-sided DLT, CPAP cannot be applied.

A Fogarty occlusion catheter was utilized in the second patient primarily for right lower lobe collapse to gain better surgical access to the diaphragm. Surgery involving the right upper lobe was assisted by partial collapse of the right upper lobe, with the single-lumen ETT advanced into the bronchus intermedius. No attempt was made to selectively block the right upper lobe orifice with the catheter due to the reasons previously mentioned. Although placement of the Fogarty catheter into the right lower lobe bronchus was achieved easily,⁴ we had problems directing the unguided catheter into the specific lobar bronchus. We therefore switched to the

WEB, and placed the blocker in the lower lobe bronchus without difficulty. Although the upper end of the 3-cm elliptical balloon was visible above the lower lobe bronchus, the seal was tight, and ventilation of the middle lobe was not impeded.

Compared to the Fogarty occlusion catheter, placement of the WEB into the lower lobe bronchus was easy, and the multiport adaptor allowed simultaneous ventilation and bronchoscopy while providing an effective seal and locking device for the catheter. Upon removal of the guide loop, the lumen of the WEB allows for CPAP when required, which can be especially important in patients with limited pulmonary reserve. Maximum contact of the balloon with the bronchial wall provided a tight seal, which might not have been as good with the spherical balloon of the Fogarty catheter.

We have described the methods used to selectively occlude the right lobar bronchi according to the site of surgery in order to maintain adequate ventilation in patients with previous left pneumonectomy. The use of a left-sided DLT on the right side is presented, and some practical problems associated with bronchial blocking devices are discussed.

Anesthesiology 2003; 98:270-2

References

1. Campos JH: Effects on oxygenation during selective lobar versus total lung collapse with or without continuous positive airway pressure. *Anesth Analg* 1997; 85:583-6
2. King BW, Gross KP: Right upper lobe resection after left pneumonectomy. *ANESTHESIOLOGY* 1994; 81:771-3
3. Takahashi M, Yamada M, Honda I, Kato M, Yamamuro M, Hashimoto Y: Selective lobar-bronchial blocking for pediatric video-assisted thoracic surgery. *ANESTHESIOLOGY* 2001; 94:170-2
4. Takahashi M, Kurokawa Y, Toyama H, Hasegawa R, Hashimoto Y: The successful management of thoracoscopic thoracic duct ligation in a compromised infant with targeted lobar deflation. *Anesth Analg* 2001; 93:96-7
5. Campos JH, Ledet C, Moyers JR: Improvement of arterial oxygen saturation with selective lobar bronchial block during hemorrhage in a patient with previous contralateral lobectomy. *Anesth Analg* 1995; 81:1095-6
6. Otruba Z, Oxorn D: Lobar bronchial blockade in bronchopleural fistula. *Can J Anaesth* 1992; 39:176-8
7. Kabon B, Walt B, Leitgeb J, Kapral S, Zimpfer M: First experience with fiberoptically directed wire-guided endobronchial blockade in severe pulmonary bleeding in an emergency setting. *Chest* 2001; 120:1399-402
8. Morell RC, Prielipp RC, Foreman AS, Monaco TJ, Royster RL: Intentional occlusion of the right upper lobe bronchial orifice to tamponade life-threatening hemoptysis. *ANESTHESIOLOGY* 1995; 82:1529-31
9. Carron H, Hill S: Anesthetic management of lobectomy for massive pulmonary hemorrhage. *ANESTHESIOLOGY* 1972; 37:658-9
10. Alfery DD: Use of a left-sided double-lumen tube to occlude the right upper lobe orifice (letter). *ANESTHESIOLOGY* 1995; 83:1131
11. Horan BF, Cutfield GR, Davies IM, Harrison GA, Hughes E, Matheson JN, Scarf M, Spratt P: Problems in the management of the airway during anesthesia for bilateral sequential lung transplantation performed without cardiopulmonary bypass. *J Cardiothorac Vasc Anesth* 1996; 10:387-90

© 2003 American Society of Anesthesiologists, Inc. Lippincott Williams & Wilkins, Inc.

Convulsions and Refractory Ventricular Fibrillation after Intrathecal Injection of a Massive Dose of Tranexamic Acid

Huei-Ming Yeh, M.D.,* Hon-Ping Lau, M.D.,* Pei-Lin Lin, M.D.,* Wei-Zen Sun, M.D.,† Martin S. Mok, M.D.,‡

TRANEXAMIC acid (trans-4-aminomethyl cyclohexane carboxylic acid) is a synthetic amino acid commonly used in treating various kinds of bleeding disorders.^{1,2} It produces an antifibrinolytic effect by competitively inhibiting the activation of plasminogen to plasmin. As a result of this inhibition, fibrin is not broken down, and this allows the formation of a more stable clot, thereby reducing the risk of recurrent bleeding. We report a case of accidental intrathecal administration of a large dose of tranexamic acid with a fatal outcome despite aggressive resuscitation.

Case Report

The patient was a 49-yr-old, 52-kg woman with rectal adenocarcinoma who had undergone resection of the colon. She was admitted for

management of sacrococcygeal dyesthesia and left sciatica, which had developed gradually over 3 yr despite several courses of adjuvant chemotherapy. A bone scan showed local recurrence of tumor in the lower lumbar spine and in both sacroiliac joints. Neither oral morphine, 300 mg/day, nor intravenous morphine for patient-controlled analgesia (infusion of 7 mg/h plus bolus dose of 8 mg) provided sufficient pain relief. After obtaining satisfactory analgesia with a trial of epidural morphine, we implanted an indwelling intrathecal access device, with the intrathecal catheter tunneled subcutaneously and inserted 12 cm into the L3-L4 interspace. The patient had received a bolus injection of 0.5 mg morphine diluted in 2 ml normal saline through an angled Huber needle with an extension line twice daily for 3 days. The attached line was used because she could not tolerate repetitive transcutaneous punctures. The patient also received tranexamic acid, 500 mg diluted in 10 ml normal saline, intravenously four times daily for persistent hematuria; no adverse effect associated with the tranexamic acid was reported by the patient. By accident, an intern injected the third dose of tranexamic acid into the line connected to the intrathecal device. Immediately after the injection, the patient complained of severe pain in the back and the gluteal region. Her blood pressure increased to 200/130 mmHg (her baseline blood pressure was 130/80 mmHg). Generalized convulsions developed 2 min later. The seizure abated after intravenous injection of 10 mg diazepam. However, the patient became pulseless and cyanotic. The resuscitation team instituted closed-chest cardiac massage and ventilation through a mask immediately. An electrocardiographic monitor was attached, and ventricular fibrillation was noted. The patient was treated with direct-current electrical shocks of 300 J, 360 J, and 360 J consecutively, which failed to convert the rhythm into sinus rhythm.

* Staff Anesthesiologist, Department of Anesthesiology, † Associate Professor and Chair, National Taiwan University Hospital. ‡ Professor, Taipei Medical University, Taipei, Taiwan.

Received from the Department of Anesthesiology, National Taiwan University Hospital, and National Taiwan University College of Medicine, Taipei, Taiwan. Submitted for publication May 28, 2002. Accepted for publication August 29, 2002. Support was provided solely from institutional and/or departmental sources.

Address reprint requests to Dr. Sun: Department of Anesthesiology, National Taiwan University Hospital, No. 7, Chung-Shan S. Road, Taipei 10016, Taiwan. Address electronic mail to: wzsun@ccms.ntu.edu.tw. Individual article reprints may be purchased through the Journal Web site, www.anesthesiology.org.

The patient was then intubated and mechanically ventilated. However, the ventricular fibrillation was refractory to subsequent resuscitation attempts, including the administration of drugs and more electrical shocks with continued closed-chest cardiac massage. The drugs used during the procedure included cumulative doses of 400 mg lidocaine, 8 mg epinephrine, 1 mg atropine, and 300 mg amiodarone. The ventricular fibrillation persisted despite the resuscitative measures, and the patient was pronounced dead after 1.5 h of resuscitation attempts. The patient's family refused to allow an autopsy to be performed. The patient did not have any other major systemic diseases other than rectal cancer. Her chemotherapy did not involve any cardiac-toxic agents. The patient's laboratory data on the day before the fatal episode were as follows: hemoglobin, 12.5 mg/dl; leukocyte count, 7,520/mm³; glucose, 86 mg/dl; sodium, 134 mEq/l; potassium, 4.5 mEq/l; calcium, 4.8 mEq/l; chloride, 105 mEq/l; and normal electrocardiographic results, with regular sinus rhythm.

Discussion

Tranexamic acid has a low acute toxicity at therapeutic doses. The lethal oral dose exceeds 3–10 g/kg body weight in all species studied, and the 50% lethal dose after intravenous injection is approximately 1–1.5 g/kg body weight in mice, rats, rabbits, and dogs.³ However, when applied topically to the cerebral cortex in animal studies, tranexamic acid produced powerful seizures.^{4–6}

Little is known about the effect of direct intrathecal administration of tranexamic acid in humans. Wong *et al.*⁷ reported a case of inadvertent intrathecal injection of 75 mg tranexamic acid in a healthy, 18-yr-old man. The patient had satisfactory anesthesia with sensory block level to T10 for a scheduled appendectomy. When the patient returned to the ward 4 h after the spinal injection, he experienced persistent motor and sensory block of both lower extremities, restlessness, and urinary incontinence. He developed clonic convulsions that progressed to a generalized seizure with hyperthermia of 40.5°C 5.5 h after the injection. His seizure and fever gradually subsided over the next 5 h after treatment with intravenous diazepam and diclofenac. He recovered completely, without any sequelae, the next day. de Leede-Van der Maarl *et al.*⁸ also reported a case of a 68-yr-old man who accidentally received an intrathecal injection of 50 mg tranexamic acid instead of the intended anesthetics. He developed status epilepticus immediately after administration of the drug, which had to be treated with midazolam, phenytoin, and thiopental infusion for 2 days. His medical course was complicated, with multiorgan dysfunction and hypotonic paresis of all four extremities, which eventually resolved but resulted in residual bilateral peroneal palsy. In our case, the patient reported severe back pain, and convulsions developed immediately after intrathecal injection of 500 mg tranexamic acid, which was a much larger dose compared with those in the former two case reports. The seizure was controlled with prompt administration of intravenous diazepam. However, the patient quickly developed ventricular fibrillation, which was not amena-

ble to aggressive resuscitative efforts. It has been reported that intravenous injection with 1 g tranexamic acid results in a concentration of 5–20 mg/l in the plasma^{9–11} and 2–5 mg/l in the cerebrospinal fluid.¹² Assuming that the drug was thoroughly diluted within the thecal space containing 500 ml of cerebrospinal fluid, 500 mg tranexamic acid would produce a concentration of 1,000 mg/l in the cerebrospinal fluid, which is 500 times greater than the therapeutic level (2–5 mg/l).³ Yamamura *et al.*⁵ reported that intracisternal injection of tranexamic acid at a dose of 5 mg/kg in cats causes seizure activities within 45 to 60 s. In the present case, the patient received an intrathecal injection of tranexamic acid at a dose of 10 mg/kg, which far exceeded the epileptogenic dose of 5 mg/kg in the report by Yamamura *et al.*⁵ The most disturbing aspect of this case is the rapid development of ventricular fibrillation despite successful management of the patient's seizure. The ventricular fibrillation was refractory to all resuscitative efforts.

We do not know the mechanism by which tranexamic acid induces convulsions or ventricular fibrillation. One may postulate that very high doses of tranexamic acid would cause massive sympathetic discharge, as evidenced by the initial hypertensive response and the subsequent ventricular arrhythmia in this patient. The concomitant administration of 15 mg tetracaine in the case reported by Wong *et al.*⁷ seemed to ameliorate the central nervous system effects of the 75 mg tranexamic acid when compared with that reported by de Leede-van der Maarl *et al.*⁸ with 50 mg tranexamic acid.

An intrathecal drug administration system is a well-accepted method of delivering morphine. On rare occasions, the line attached to the intrathecal access device could be misused as an intravenous line. Fatal or near-fatal catastrophes after inadvertent intrathecal injection of contrast media (amidotrizoate),¹³ penicillin,¹⁴ muscle relaxants (gallamine triethiodide),¹⁵ and chemotherapy agents (vincristine)¹⁶ have been reported. Among the patients who were successfully resuscitated, the treatments included administration of anticonvulsants, cerebrospinal fluid lavage, and subsequent intensive monitoring.^{13–16} In the present case, we found that the convulsions were responsive to benzodiazepine. However, refractory ventricular fibrillation and subsequent cardiovascular collapse precluded the possibility of cerebrospinal fluid lavage therapy. To prevent this iatrogenic complication, we have since begun labeling lines with different colors so that the intrathecal drug administration line is clearly identified, and we strongly recommend taking these precautionary measures.

References

1. Dubber AHC, McNicol GP, Douglas AS: Amino methyl cyclohexane carboxylic acid (AMCA): A new synthetic fibrinolytic inhibitor. *Br J Haematol* 1965; 11:237–45

2. Dunn CJ, Koa CL: Tranexamic acid: A review of its use in surgery and other indications. *Drugs* 1999; 57:1005-32
3. Siren MJ: Study on the acute toxicity of tranexamic acid (AMCA: trans-4-aminomethylcyclohexanecarboxylic acid) in mice. Kabi Confidential Report No. 441, 1966
4. Pellegrini A, Giaretta D, Chemello R, Zanoto L, Testa G: Feline generalized epilepsy induced by tranexamic acid (AMCA). *Epilepsia* 1982; 23:35-45
5. Yamamura A, Nakamura T, Makino H, Hagihara Y: Cerebral complication of antifibrinolytic therapy in the treatment of ruptured intracranial aneurysm: Animal experiment and a review of literature. *Eur Neurol* 1980; 19:77-84
6. Schlag MG, Hopf R, Redl H: Convulsive seizure following subdural application of fibrin sealant containing tranexamic acid in a rat model. *Neurosurgery* 2000; 47:1463-67
7. Wong J, Yang S, Tsai M: Accidental injection of tranexamic acid (Transamin) during spinal anesthesia [in Chinese]. *Ma Zui Xue Za Zhi* 1988; 26:249-52
8. de Leede-Van der Maarl MG, Hilken P, Bosch F: The epileptogenic effect of tranexamic acid. *J Neurol* 1999; 246:843

9. Pilbrant A, Schannong M, Wessman J: Pharmacokinetics and bioavailability of tranexamic acid. *Eur J Clin Pharmacol* 1981; 20:65-72
10. Svahn CM, Schannong M, Stenberg U, Widlund L: Absorption of tranexamic acid as a prodrug in healthy volunteers. *Arzneimittelforschung* 1988; 38:735-8
11. Astedt B: Clinical pharmacology of tranexamic acid. *Scand J Gastroenterol Suppl* 1987; 137:22-5
12. Tovi D, Thulin CA: Ability of tranexamic acid to cross the blood-brain barrier and its use in patients with ruptured intracranial aneurysm. *Acta Neurol Scand* 1972; 48:257
13. Nakazawa K, Yoshinari M, Kinefuchi S, Amaha K: Inadvertent intrathecal administration of amidetizoate. *Intensive Care Med* 1988; 15:55-7
14. Mesry S, Baradaran J: Accidental intrathecal injection of gallamine triethiodide. *Anesthesia* 1974; 29:301-4
15. Marks C, Cummins BH: Rescue after 2 megaunits of intrathecal penicillin. *Lancet* 1981; 1:658-9
16. Dyke RW: Vincristine must not be administered intrathecally. *JAMA* 1982; 248:171-2

Anesthesiology 2003; 98:272-4

© 2003 American Society of Anesthesiologists, Inc. Lippincott Williams & Wilkins, Inc.

Open Chest Tension Pneumothorax during Lung Volume Reduction Surgery *via* Sternotomy

Matt Schlossberg, M.D.,* Patrick Ross, M.D., Ph.D.,† Mark A. Gerhardt, M.D., Ph.D.‡

TENSION pneumothorax is a life-threatening emergency that rapidly results in cardiopulmonary arrest. Although often associated with trauma or central line placement, tension pneumothorax can also occur intraoperatively from positive pressure ventilation or from the surgical procedure. Although some case reports have described tension pneumothorax during video-assisted thoracoscopic surgery,^{1,2} we report a tension pneumothorax that developed while the chest was open following median sternotomy and entrance into the contralateral pleural space.

Case Report

A 66-yr-old man (84.5 kg, 170 cm) with severe chronic obstructive pulmonary disease (COPD) presented for lung volume reduction surgery (LVRS). His past medical history was significant for tobacco abuse and severe COPD. On physical examination, the patient had conversational dyspnea, clubbing, peripheral cyanosis, and bilateral expiratory wheezing in all lung fields. A preoperative chest radiograph showed a normal-sized heart, increased anteroposterior diameter, and flattening of the hemidiaphragms. A computed tomography scan showed evidence of severe emphysema with bilateral upper lobe predominance. The bullae were the target lesions for the surgical procedure.³ Preoperative pulmonary function test results are shown in table 1. The patient's arterial blood gas data while breathing room air were as follows: pH, 7.40; PaCO₂, 48 mmHg; PaO₂, 63 mmHg; bicarbonate,

29 mEq/L; and arterial oxygen saturation, 93%. Right heart catheterization (table 2) indicated elevated pulmonary artery pressures.

A thoracic epidural catheter was placed at the T6 level using a right paramedian hanging drop technique without difficulty and was dosed with 10 ml ropivacaine, 0.5%, in divided doses. The patient had an uneventful induction, and maintenance anesthesia was achieved with sevoflurane in oxygen. A 39-French, left-sided, double-lumen endotracheal tube was placed without difficulty, and positioning was confirmed *via* fiberoptic bronchoscopy. Ventilation was provided *via* pressure control mode (peak pressure = 30 cm H₂O) at a rate of 14 breaths/min. Delivered tidal volumes during left one-lung ventilation were approximately 375 ml, with a set inspiratory to expiratory ratio of 1:3.5. A central venous catheter was placed without complication *via* the right subclavian vein.

A midline sternotomy was performed, and the surgeon opened the right lung pleura. Approximately 25 min after initiating right pulmonary resection, there was a sudden, significant loss of tidal volume and rapid (over several seconds) development of pulseless electrical activity. The patient exhibited profound hypotension (nonpulsatile arterial line with pressures < 30 mmHg), a sinus rhythm without ST segment changes, and decreased end-tidal carbon dioxide. Initial treatment consisted of open cardiac massage and a bolus dose of epinephrine (250 µg) while determining the cause of the hypotension. Inspection of the operative field revealed that the left pleura tented (under pressure) past the midline. Opening of the left pleura was associated with a rush of air and resolution of the hypotension within seconds. Following an initial transient sinus tachycardia and hypertension secondary to the epinephrine, the vital signs returned to baseline, and surgery continued. There was a continual large air leak from the left lung. A ruptured bulla of the left upper lobe was noted and excised with other diseased lung tissue. The patient was extubated at the conclusion of the procedure. A persistent bronchopleural fistula of the left upper lobe required reoperation 3 weeks after the initial procedure. The remainder of the perioperative course was unremarkable.

* Clinical Instructor, ‡ Assistant Professor, Department of Anesthesiology, † Assistant Professor, Department of Cardiothoracic Surgery.

Received from the Departments of Anesthesiology and Cardiothoracic Surgery, The Ohio State University Medical Center, Columbus, Ohio. Submitted for publication January 8, 2002. Accepted for publication August 23, 2002. Support was provided solely from institutional and/or departmental sources.

Address reprint requests to Dr. Gerhardt: Department of Anesthesiology, N412 Doan Hall, The Ohio State University Medical Center, 410 West Tenth Avenue, Columbus, Ohio 43210-1228. Address electronic mail to: Gerhardt-1@medctr.osu.edu. Individual article reprints may be purchased through the Journal Web site, www.anesthesiology.org.

Discussion

A tension pneumothorax may occur when intrapleural pressure exceeds atmospheric pressure. This usually occurs from pleural injury in which a conduit acts like a

Table 1. Preoperative Pulmonary Function Test Results

	Prebronchodilator			Postbronchodilator	
	Predicted	Actual	% Predicted	Actual	% Change
FVC (l)	3.89	1.01	26	1.33	32
FEV ₁ (l)	2.87	0.45	16	.55	22
FEV ₁ /FVC (%)	83.8	44.6	—	—	—
FEF ₂₅₋₇₅ (l/s)	3.09	0.15	5	0.20	33
Peak flow (l/s)	8.02	2.86	36	3.22	13
MVV (l/min)	127	37	29	—	—
ERV (l)	1.20	0.73	61	—	—
Thoracic gas volume (l)	3.46	5.41	156	—	—
RV (l)	2.26	4.68	207	—	—
TLC (l)	6.61	7.00	106	—	—
RV/TLC (%)	34.5	66.9	—	—	—

Because the patient had emphysematous target lesions on chest computed tomography scan, a carbon monoxide diffusing capacity was not performed.

ERV = expiratory reserve volume; FEF₂₅₋₇₅ = midexpiratory (25–75%) forced expiratory flow; FEV₁ = forced expiratory volume in 1 s; FVC = forced vital capacity; MVV = maximum voluntary ventilation; RV = residual volume; TLC = total lung capacity.

one-way valve, allowing air to escape into the pleural space. Expansion of the pneumothorax forces the lung to collapse, with resultant increasing airway pressures. Increasing intrathoracic pressure exceeds venous and cardiac end-diastolic pressures, limiting cardiac filling, stroke volume, and blood pressure (pulseless electrical activity). Tension pneumothorax is a medical emergency and requires immediate decompression. Although case reports of tension pneumothorax exist in the setting of thoracotomy and video-assisted thoracoscopic surgery,^{1,2} there are no published case reports of tension pneumothorax in a patient with an open chest following sternotomy.

The differential diagnosis in our case includes pulmonary thromboembolism, venous air embolism, torsion of the heart or great vessels, compression of the heart by the surgeon, primary cardiac etiologies (dysrhythmia, myocardial ischemia), “pulmonary tamponade” resultant from air trapping, acute right heart failure secondary to marked pulmonary hypertension, malposition of the double-lumen endotracheal tube, and iatrogenic pneumothorax from the thoracic epidural or central venous cannulation procedures. The rapid resolution of the hypotension and the rush of air associated with opening of the left pleura confirm the diagnosis of tension pneumothorax. Iatrogenic causes do not seem likely. The central

line was placed on the contralesional side. Bilateral dermatomal anesthesia, low volatile agent requirements intraoperatively, and excellent postoperative analgesia suggest placement of the epidural catheter into the epidural space rather than the pleural space. Malposition of the double-lumen endotracheal tube can result in barotrauma. Fiberoptic bronchoscopy was performed before and after the development of the pneumothorax and demonstrated proper positioning of the endotracheal tube. The most likely cause of the pneumothorax was rupture of a pulmonary bulla secondary to positive pressure ventilation. Because the left pleura was not yet opened, a tension pneumothorax ensued.

The LVRS population is selected for severe obstructive disease and is therefore at high risk for intraoperative pneumothorax. LVRS has had limited success as a palliative procedure for severe COPD, with 30-day mortality rates ranging from 0 to 15%.⁴⁻⁶ Pneumothorax-related complications accounted for approximately 3% of the American Society of Anesthesiologists' closed claims database.⁷ Barotrauma was responsible for 20% of the pneumothorax cases, with placement of brachial plexus blocks and central lines comprising the majority of claims.⁷ Pneumothorax may occur in 3–5% of mechanically ventilated patients and is life-threatening if a tension pneumothorax develops. Patients with COPD have an increased risk of pneumothorax.⁸ Previous reports of LVRS *via* sternotomy did not report intraoperative pneumothorax but did advocate ventilator management of pressure control ventilation (20–25 cm H₂O) with a prolonged inspiratory to expiratory ratio of 1:4,⁴ for example, which was similar to our management. The prolonged inspiratory to expiratory ratio is critically important, as air trapping can result in a physiologic process that resembles tension pneumothorax.

Early postoperative extubation in LVRS patients decreases work of breathing and airway resistance and increases dynamic compliance.⁹ Extubation also protects

Table 2. Preoperative Right Heart Cardiac Catheterization Results

Right atrium	8 mmHg
Right ventricular outflow	42/8 mmHg
Main pulmonary artery	42/20 mmHg
Pulmonary capillary wedge	11 mmHg
Main pulmonary artery oxygen saturation	69%

Additional preoperative cardiac workup was unremarkable. Electrocardiogram demonstrated a normal sinus rhythm and low voltage QRS complexes consistent with pulmonary disease. A dobutamine-thallium scan showed no scintigraphic evidence of myocardial ischemia or prior myocardial infarction. Transthoracic echocardiography showed no significant valvular disease and a left ventricular ejection fraction of 60%.

the lungs from prolonged barotrauma and its associated risks, such as persistent air leaks and pneumothorax. Although the majority of LVRS patients are extubated in the early postoperative period, approximately 6–10% require reintubation. This group of patients has significantly higher morbidity and mortality rates.¹⁰ Because the patient described here met our extubation criteria, he was extubated without complication. Many thoracic anesthesiologists feel that a thoracic epidural block is the most appropriate method of achieving postoperative analgesia. This is relevant because thoracic epidural catheter placement can result in pneumothorax if the needle is off midline and enters the pleural space.¹¹

This is a case of tension pneumothorax during median sternotomy. *A priori*, this would seem impossible with an open chest. However, the human anatomy is characterized by two separate pleural cavities. Anesthesiologists routinely capitalize on this anatomic arrangement when using one-lung ventilation. One-lung ventilation would not be technically feasible without the use of positive end-expiratory pressure on the dependent lung if the pleura were contiguous. Furthermore, the pericardium was intact; thus, the heart and great vessels were exposed to the pressure effects of the two pleural spaces rather than atmospheric pressure. We believe that the mechanism was compression and displacement of the heart, leading to decreased venous return. Normal hemodynamic parameters were immediately restored following release of the left-sided pneumothorax. The les-

son to be learned from this case is that whenever the pleural cavity is intact, conditions for the development of a tension pneumothorax exist and must be considered in the event of hemodynamic collapse.

References

1. Zollinger A, Zaugg M, Weder W, Russi EW, Blumenthal S, Zalunardo MP, Stoehr S, Thurnheer R, Stammberger U, Spahn DR, Pasch T: Video-assisted thoroscopic volume reduction surgery in patients with diffuse pulmonary emphysema: Gas exchange and anesthesiological management. *Anesth Analg* 1997; 84:845–51
2. Roush TF, Crawford AH, Berlin RE, Wolf RK: Tension pneumothorax as a complication of video-assisted thoracoscopic surgery for anterior correction of idiopathic scoliosis in an adolescent female. *Spine* 2001; 26:448–50
3. National Emphysema Treatment Trial Research Group: Patients at high risk of death after lung-volume-reduction surgery. *N Engl J Med* 2001; 345:1075–83
4. Buettner AU, McRae R, Myles PS, Snell GI, Bujor MA, Silvers A, Weeks AM: Anaesthesia and postoperative pain management for bilateral lung volume reduction surgery. *Anaesth Intensive Care* 1999; 27:503–8
5. Flaherty KR, Kazerooni EA, Curtis JL, Iannettoni M, Lange L, Schork MA, Martinez FJ: Short-term and long-term outcomes after bilateral lung volume reduction surgery: Prediction by quantitative CT. *Chest* 2001; 119:1337–46
6. Flaherty KR, Martinez FJ: Lung volume reduction surgery for emphysema. *Clin Chest Med* 2000; 21:819–48
7. Cheney FW, Posner KL, Caplan RA: Adverse respiratory events infrequently leading to malpractice suits. A closed claims analysis. *ANESTHESIOLOGY* 1991; 75:932–9
8. Jantz MA, Pierson DJ: Pneumothorax and barotrauma. *Clin Chest Med* 1994; 15:75–91
9. Tschernko EM, Gruber EM, Jaksch P, Jandrasits O, Jantsch U, Brack T, Lahrmann H, Klepetko W, Wanke T: Ventilatory mechanics and gas exchange during exercise before and after lung volume reduction surgery. *Am J Respir Crit Care Med* 1998; 158:1424–31
10. Keller CA, Naunheim KS: Perioperative management of lung volume reduction patients. *Clin Chest Med* 1997; 18:285–300
11. Zaugg M, Stoehr S, Weder W, Zollinger A: Accidental pleural puncture by a thoracic epidural catheter. *Anaesthesia* 1998; 53:69–71