

## Anesthesia-related Cardiac Arrest in Children

*To the Editor:*—Murray *et al.*<sup>1</sup> are to be congratulated in trying to sort out some of the issues regarding intraoperative cardiac arrest in children. However, I am concerned with the conclusions regarding cardiac arrests related to anesthetic agents. The authors freely admit that they do not know the numerator or denominator and therefore cannot say that sevoflurane is safer than halothane, but they have suggested that because sevoflurane is reported to be less cardiac depressant than halothane, perhaps this is a contributory factor. I suggest another mechanism, and that is a systems issue, *i.e.*, the minimum alveolar concentration (MAC) multiples that can be administered with most halothane vaporizers is approximately 5 in a newborn or infant, whereas the number of MAC multiples allowable with a sevoflurane vaporizer is only approximately 2½. Thus, the potential to deliver twice as much drug with halothane sets up the potential for rapid cardiovascular depression because of greater overpressurization at the beginning of anesthesia.

As one would expect, the majority of cardiac arrests reported occur during induction, and many of them occur only after control of respirations. It should be noted that the two patients who had arrests with sevoflurane also had controlled ventilation. Thus, the real culprit here may not be the drug but rather how the drug is used and the concentration of the drug that is used, *i.e.*, high concentrations of halothane with controlled ventilation or even moderate concentrations of halothane or sevoflurane with controlled ventilation.

It would be interesting to determine how many cardiac arrests occur with low doses of halothane while allowing the patient to breathe spontaneously. In my experience, most patients autoregulate their depth of anesthesia, and as long as the bag is not squeezed and the patient is allowed to breathe spontaneously, it is rare to see significant cardiovascular depression with halothane. However, as soon as one begins to control ventilation, rapid cardiac depression may follow.

Examination of the original MAC studies of halothane and similar

MAC studies of sevoflurane from Toronto shows that the incidence of hypotension was similar in both groups of neonates. In fact, there was a higher incidence of hypotension in the sevoflurane neonate group (8 of 12) compared with the halothane neonate group (4 of 12).<sup>2-3</sup> Admittedly, these studies were performed many years apart, and perhaps there were some differences in patient population, but the degree of myocardial depression reported in the literature when comparing sevoflurane and halothane is quite minimal, especially in infants. These differences in cardiovascular effects are likely less in children younger than 3 yr of age, the most vulnerable group, because they tend not to have an increase in heart rate with sevoflurane compared with older children.<sup>3</sup>

My caution is to not condemn halothane at this time, particularly because this drug is the most widely used around the world, and sevoflurane is not affordable to many countries or hospitals. Instead of condemning the drug, perhaps we should teach people how to administer anesthesia more safely to infants. I was taught that it is difficult to "kill" a spontaneously breathing patient.

**Charles J. Coté, M.D.**, Children's Memorial Hospital, Northwestern University Medical School, Chicago, Illinois. ccote@northwestern.edu

## Reference List

1. Murray JP, Geiduschek JM, Ramamoorthy C, Haberkern CM, Hackel A, Caplan RA, Domino KB, Posner K, Cheney FW: Anesthesia-related cardiac arrest in children: Initial findings of the Pediatric Perioperative Cardiac Arrest (POCA) Registry. *ANESTHESIOLOGY* 2000; 93:6-14
2. Lerman J, Robinson S, Willis MM, Gregory GA: Anesthetic requirements for halothane in young children 0-1 month and 1-6 months of age. *ANESTHESIOLOGY* 1983; 59:421-4
3. Lerman J, Sikich N, Kleinman S, Yentis S: The pharmacology of sevoflurane in infants and children. *ANESTHESIOLOGY* 1994; 80:814-24

(Accepted for publication November 16, 2000.)

## Did Anesthetics Trigger Cardiac Arrests in Patients with Occult Myopathies?

*To the Editor:*—We appreciate the excellent analysis by Murray *et al.*<sup>1</sup> of 150 anesthesia-related pediatric cardiac arrests reports submitted to the Pediatric Perioperative Cardiac Arrest Registry from 1994-1997. In his editorial, Rothstein<sup>2</sup> suggests a multicenter prospective epidemiologic study to improve our understanding of the causes of pediatric perioperative anesthesia-related arrests and to develop a strategy to diminish their incidence.

We have some questions about the etiology of the hyperkalemic cardiac arrests reported to the Pediatric Perioperative Cardiac Arrest Registry. How many pediatric arrests were attributed to hyperkalemia? How many were unrelated to massive transfusion, liver reperfusion, and renal insufficiency? Did an additional three patients with unrecognized cardiomyopathy have arrests after halothane induction? Was skeletal muscle for histologic examination and dystrophin analysis obtained in any of these children? Was a positive family history of muscular dystrophy revealed when parents were inter-

viewed after their child's arrest? Do the reports indicate whether the etiology of occult myopathy was considered by the reporting institutions for these eight children and the eight additional children in whom no specific cardiovascular cause could be determined?

We ask because of our findings from a smaller study of all pediatric cardiac arrests ( $n = 25$ ) reported predominantly from community hospitals for the years 1990-1993 to the databases of The North American Malignant Hyperthermia Registry and the Malignant Hyperthermia Association of the United States Hotline.<sup>3</sup> Our analysis showed the presence of unrecognized myopathy in 12 arresting patients (48%), with 8 of these 12 cardiac arrests associated with hyperkalemia. Only 5 patients (20%) in our series experienced a malignant hyperthermia event before arrest.

To understand the causes of pediatric perioperative cardiac arrest better, we proposed<sup>3</sup> that postarrest evaluation should include analysis

of body fluids for electrolyte abnormality and skeletal muscle for myopathy and absence of normal dystrophin. As a strategy to decrease the incidence of myopathy-associated cardiac arrest, we urged pediatricians to screen young male patients for occult myopathy before their referral for elective anesthetics. We also asked whether presymptomatic diagnosis of Duchenne and Becker muscular dystrophies might be accomplished with neonatal creatine kinase testing.<sup>4</sup>

Based on the study of Morray *et al.*<sup>1</sup> and our findings, we concur that a large, multicenter prospective epidemiologic study that seeks to determine the etiology of all pediatric perioperative cardiac arrests would be of great value to the anesthesia community. We would be happy to collaborate in that venture.

**Marilyn Green Larach, M.D., F.A.A.P.,\* Henry Rosenberg, M.D., Gerald A. Gronert, M.D., Gregory C. Allen, M.D., F.R.C.P.C.**  
\*The North American Malignant Hyperthermia Registry, Pittsburgh, Pennsylvania, and Penn State University College of Medicine, Hershey, Pennsylvania. mlarach@psu.edu

Anesthesiology 2001; 94:934-5

*In Reply*—Dr. Larach *et al.* have reported that of the 25 cardiac arrest patients reported to The North American Malignant Hyperthermia (MH) Registry and MH Association of the United States Hotline from 1990–1993, 48% showed evidence for a previously unrecognized myopathy, and 32% had hyperkalemia-associated arrests. In contrast, 6.7% (10/150) of the Pediatric Perioperative Cardiac Arrest Registry patients were hyperkalemic at the time of arrest. All but one of these cases was associated with either massive transfusion ( $n = 5$ ), reperfusion after liver transplant ( $n = 2$ ), or renal insufficiency ( $n = 2$ ). In one patient, succinylcholine administration resulted in hyperkalemia and cardiac arrest. This was a patient with severe neurologic deterioration from subacute sclerosing panencephalitis. No laboratory data or muscle biopsy data were provided to confirm the presence of a myopathy. The same was true for the 3 children found to have cardiomyopathy and for the 18 children whose arrest was assumed to be cardiovascular in origin but could not have a specific cause assigned.

The fact that fewer hyperkalemia-associated arrests have been reported to the Pediatric Perioperative Cardiac Arrest Registry than to The North American MH Registry is not surprising, given the different focus and entry criteria of the two registries. In fact, no cases of MH have been reported to the Pediatric Perioperative Cardiac Arrest Registry, perhaps because we have become more knowledgeable about MH prevention and therapy such that few MH-susceptible patients progress to cardiac arrest. In addition, the decreasing use of succinylcholine during the past decade as faster-acting nondepolarizing relaxants have become available may have resulted in the diagnosis of fewer patients with occult myopathy or MH susceptibility.

We agree with Dr. Larach *et al.* that more information is required. As suggested in Dr. Rothstein's editorial,<sup>1</sup> this sort of information can come only with a prospective multicenter epidemiologic study of anesthesia-related cardiac arrest.

Dr. Cote argues that we should not condemn halothane because it remains the most widely used anesthetic agent for children around the world, has a long track record of safety, and is inexpensive relative to other agents, such as sevoflurane. His points are well-taken. However, pediatric anesthesiologists recognize that halothane can cause bradycardia and hypotension in their patients, occasionally to the degree that cardiopulmonary resuscitation is required. The impact of halothane on heart rate, blood pressure, and cardiac output has been well-documented in many animal<sup>2-4</sup> and human<sup>5-7</sup> studies. Recently, studies comparing the cardiovascular responses in newborns, infants, and children to whom either halothane or sevoflurane was administered have suggested important differences, particularly with respect

## References

1. Morray JP, Geiduschek JM, Ramamoorthy C, Haberkern CM, Hackel A, Caplan RA, Domino KB, Posner K, Cheney FW: Anesthesia-related cardiac arrest in children: Initial findings of the Pediatric Perioperative Cardiac Arrest (POCA) Registry. *ANESTHESIOLOGY* 2000; 93:6-14
2. Rothstein P: Bringing light to the dark side (editorial). *ANESTHESIOLOGY* 2000; 93:1-3
3. Larach MG, Rosenberg H, Gronert GA, Allen GC: Hyperkalemic cardiac arrest during anesthesia in infants and children with occult myopathies. *Clin Pediatr* 1997; 36:9-16
4. Planchu H, Dorche C, Carrier H, Cordier MP, Guibaud P, Lauras B, Robert JM: Systematic neonatal screening for Duchenne muscular dystrophy: Results of a ten year study in Lyon, France, *Advances in Neonatal Screening*. Edited by Therell BL Jr. Amsterdam, Elsevier Sciences, 1987, pp 371-4

(Accepted for publication November 16, 2000.)

© 2001 American Society of Anesthesiologists, Inc. Lippincott Williams & Wilkins, Inc.

to heart rate and cardiac contractility and output.<sup>8-10</sup> As Dr. Cote points out, another important difference between these two agents is that it is possible to deliver roughly twice the number of minimum alveolar concentration multiples of halothane than of sevoflurane.

Halothane continues to be a frequently used agent in our institution, as in other institutions around the world that care for children. We hope that information provided by the Pediatric Perioperative Cardiac Arrest Registry about halothane's role in contributing to occasional cardiac arrest will improve the safety of its use. As an example, the use of controlled ventilation was an associated factor in approximately half of the patients in which halothane-related cardiovascular depression caused cardiac arrest; the remainder had arrests during spontaneous or assisted ventilation. Thus, the classic teaching that spontaneously breathing patients do not have arrests caused by inhalation agent-induced cardiovascular depression is not always true.

As anesthetic agents with the promise of improved efficacy or fewer side effects become available, we would be remiss not to compare them with the gold standard. We do not know whether sevoflurane is associated with less risk compared with halothane, but there is reason to think this might be so. At the moment, each of us must apply an incomplete data set to our practices. Cost is certainly an issue and may be the decisive issue if sevoflurane is unaffordable. Those of us with the luxury of choice are charged with analyzing our outcomes as rigorously as possible and making the information available to others.

**Jeffrey Morray, M.D.**, Children's Hospital and Regional Medical Center, Seattle, Washington, and University of Washington School of Medicine, Seattle, Washington. jmorray@chmc.org

## References

1. Rothstein, P: Bringing light to the dark side (editorial). *ANESTHESIOLOGY* 2000; 93:1-3
2. Cook DR, Brandom BW, Shiu G, Wolfson B: The inspired median effective dose, brain concentration at anesthesia, and cardiovascular index for halothane in young rats. *Anesth Analg* 1981; 60:182-5
3. Rao CC, Boyer MS, Krishna G, Paradise RR: Increased sensitivity of the isometric contraction of the neonatal isolated rat atria to halothane, isoflurane, and enflurane. *ANESTHESIOLOGY* 1986; 64:13-8
4. Krane EJ, Su JY: Comparison of the effects of halothane on newborn and adult rabbit myocardium. *Anesth Analg* 1987; 66:1240-4
5. Barash PG, Glanz S, Katz JD, Taunt K, Talner NS: Ventricular function in children during halothane anesthesia. *ANESTHESIOLOGY* 1978; 49:79-85
6. Friesen RH, Lichter JL: Cardiovascular depression during halothane anesthesia in infants: A study of three induction techniques. *Anesth Analg* 1983; 61:42-5
7. Murray DJ, Forbes RB, Mahoney LT: Comparative hemodynamic depression of halothane versus isoflurane in neonates and infants: An echocardiographic study. *Anesth Analg* 1992; 74:329-37

8. Johannesson G, Floren M, Lindahl G: Sevoflurane for ENT surgery in children. *Acta Anaesthesiol Scand* 1995; 39:546-50

9. Wodey E, Pladys P, Copin C, Lucas M, Chaumont A, Carre P, LeLong B, Azzis O, Ecoffey C: Comparative hemodynamic depression of sevoflurane versus halothane in infants. *ANESTHESIOLOGY* 1997; 87:795-800

10. Holtzman R, van der Velde M, Kaus S, Body S, Colan S, Sullivan L, Soriano S: Sevoflurane depresses myocardial contractility less than halothane during induction of anesthesia in children. *ANESTHESIOLOGY* 1996; 85:1260-70

(Accepted for publication November 16, 2000.)

Anesthesiology 2001; 94:935

© 2001 American Society of Anesthesiologists, Inc. Lippincott Williams & Wilkins, Inc.

## Is Difficult Mask Ventilation Only Correlated to the Physical Status of the Patient?

*To the Editor:*—It was with great interest that we read the article by Langeron *et al.*<sup>1</sup> published in the May 2000 issue of *ANESTHESIOLOGY*. This was a well-designed study evaluating the incidence of difficult mask ventilation during the induction of general anesthesia in a general adult population. The authors emphasize the significant frequency of difficult mask ventilation (5%) in their study and its potential relation with difficult intubation; they also define an easy and simple clinical criteria to detect difficult mask ventilation.<sup>2</sup> This study was performed in a French university hospital. However, the authors provided no data regarding the degree of clinical experience or years of training of the anesthesiologists involved in the study. In addition, clinical case loads for individual anesthesiologists differ a great deal within France, from 300 patients per year in some public hospitals to 120 per year in some private institutions.<sup>3,4</sup> I suggest that the rate of clinical activity of the practitioners may influence the “diagnosis” of difficult mask ventilation and perhaps may lead to an overestimate of its incidence in comparison with previous studies.<sup>5</sup> Regardless of these concerns, the five

criteria defined by Langeron *et al.*<sup>1</sup> now must be considered along with others’ airway assessment in the preoperative assessment of patients.

**Marc E. Gentili, M.D.**, Centre Medico-chirurgical Saint-Vincent, Sint-Gregoire, France. Marc.Gentili@wanadoo.fr

### References

1. Langeron O, Masso E, Huraux C, Guggiari M, Bianchi A, Coriat P, Riou B: Prediction of difficult Mask Ventilation. *ANESTHESIOLOGY* 2000; 92:1229-36
2. Adnet F: Difficult mask ventilation: An underestimated aspect of the problem of the difficult airway? *ANESTHESIOLOGY* 2000; 92:1217-8
3. Clergue F, Laxenaire MC: La Pratique de l’anesthésie en France: *Ann Fr Anesth Reanim* 1998; 17:1299-403
4. Clergue F, Auroy, Pequignot F, Jouglu E, Lienhart A, Laxenaire MC: French Survey of Anesthesia 1999; 9:1509-20
5. Benumof JL: Management of the difficult airway. *ANESTHESIOLOGY* 1991; 75:1087-110

(Accepted for publication December 13, 2000.)

Anesthesiology 2001; 94:935

© 2001 American Society of Anesthesiologists, Inc. Lippincott Williams & Wilkins, Inc.

## Mandibular Protrusion Test for Prediction of Difficult Mask Ventilation

*To the Editor:*—We read with great interest the article by Dr. Langeron *et al.*<sup>1</sup> providing the first large study attempting to assess the incidence of difficult mask ventilation and to establish the difficult mask ventilation prediction score. The authors suggest two important factors contributing to difficulty in mask ventilation, which are inability to fit a face mask and inability to overcome obstruction of the upper airway after general anesthesia or muscle relaxation. Unfortunately, the difficult mask ventilation prediction score cannot sufficiently reflect factors related to the latter. The main causes of obstruction of the upper airway are known to be posterior displacement of the base of the tongue or the epiglottis and collapse of the laryngeal inlet.<sup>2-6</sup> The jaw-thrust maneuver can lift these tissues and restore airway patency.<sup>2-6</sup> Thus, we consider that assessment of ability to thrust the jaw fully is necessary to predict difficult mask ventilation. Calder *et al.*<sup>7</sup> have suggested the mandibular protrusion test. The test evaluates the degree of protrusion of the mandible when the patient protrudes the mandible as far forward as possible. The degree of protrusion is classified as follows: class A: the lower incisors can be protruded anterior to the upper incisors; class B: the lower incisors can be brought edge to edge with the upper incisors but not anterior to them; class C: the lower incisors cannot be brought edge to edge with the upper incisors. This test is simple and has little interobserver variations because there is a clearer endpoint. Although Calder *et al.*<sup>7</sup> have demonstrated that impaired mandibular protrusion is a good predictor

of difficult laryngoscopy, we believe that the test may be useful for prediction of difficult mask ventilation.

**Ichiro Takenaka, M.D.,\* Kazuyoshi Aoyama, M.D., Tatsuo Kadoya, M.D.** \*Nippon Steel Yawata Memorial Hospital, Kitakyushu, Japan. itaken@d4.dion.ne.jp

### References

1. Langeron O, Masso E, Huraux C, Guggiari M, Bianchi A, Coriat P, Riou B: Prediction of difficult mask ventilation. *ANESTHESIOLOGY* 2000; 92:1229-36
2. Morikawa S, Safer P, De Carlo J: Influence of head-jaw position on upper airway patency. *ANESTHESIOLOGY* 1961; 22:265-70
3. Boidin MP: Airway patency in the unconscious patient. *Br J Anaesth* 1985; 57:306-10
4. Aoyama K, Takenaka I, Sata T, Shigematsu A: The triple airway manoeuvre for the laryngeal mask airway in paralyzed patients. *Can J Anaesth* 1995; 42:1010-6
5. McGee JP, Vender JS: Nonintubation management of the airway: Mask ventilation, Airway Management Principles and Practice. Edited by Benumof JL. St. Louis, Mosby, 1995, pp 228-54
6. Murashima K, Fukutome T: Effect of jaw-thrust manoeuvre on the laryngeal inlet. *Anaesthesia* 1998; 53:203-4
7. Calder I, Calder J, Crockard HA: Difficult direct laryngoscopy in patients with cervical spine disease. *Anaesthesia* 1995; 50:756-63

(Accepted for publication December 13, 2000.)

Anesthesiology 2001; 94:936-7

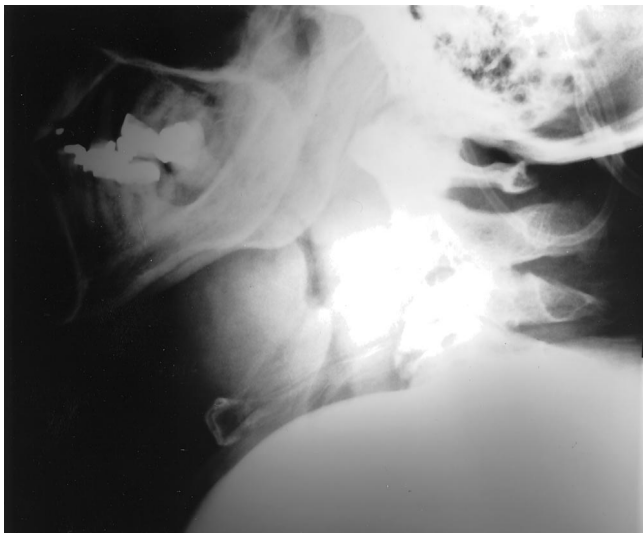
© 2001 American Society of Anesthesiologists, Inc. Lippincott Williams &amp; Wilkins, Inc.

## Large Hypopharyngeal Tongue: A Shared Anatomic Abnormality for Difficult Mask Ventilation, Difficult Intubation, and Obstructive Sleep Apnea?

*To the Editor:*—We applaud the recent landmark investigation by Langeron *et al.*<sup>1</sup> regarding difficult mask ventilation (DMV). We find three of the established independent DMV risk factors (age > 55 yr, body mass index > 26 kg/m<sup>2</sup>, and history of snoring) particularly interesting and believe they merit further discussion.

The current study by Langeron *et al.*<sup>1</sup> has shown that DMV is correlated significantly with both obstructive sleep apnea (OSA) and difficult intubation (DI). Previous literature<sup>2,3</sup> also indicated a significant correlation between DI and OSA. Therefore, although we recognize that DMV, DI, and OSA are complex clinical entities, each with their own multiple contributing anatomic or pathologic factors, DMV, DI, and OSA apparently are correlated with one another. It is then quite reasonable to postulate that they may share a common anatomic abnormality.

In 1983, the cephalometric analysis by Riley *et al.*<sup>4</sup> showed that the distance from the mandibular plane to the hyoid (MP-H) tended to be longer in patients with OSA. They suggested the presence of a relatively inferior hyoid. In 1993, we conducted a radiographic study<sup>5</sup> of DI patients and found that the rostrocaudal position (in relation to the cervical vertebrae) and vertical distance between the mandible and hyoid (MHD) varied widely among the adult population. However, DI patients tended to have a longer MHD—a greater rostrocaudal separation of the mandible and hyoid—which indicated the presence of a relatively shorter mandibular ramus or more caudally positioned hyoid. We then proposed that the longer MHD and MP-H most likely signified the presence of a similar anatomical abnormality in both the DI and OSA patients.<sup>5</sup>



**Fig. 1.** Cervical soft tissue study of a 63-yr-old morbidly obese man (123 kg, 170 cm, body mass index = 43 kg/m<sup>2</sup>) with obstructive sleep apnea, difficult mask ventilation, and difficult intubation. Atlanto-occipital gap = 0 mm; very long mandibulo-hyoid distance = 43 mm (normal male mean, 21 mm); unusually rostral mandibular angle at upper C2 (normal level, lower C2 or C2-C3); unusually caudally positioned hyoid at lower C4 (normal level, C3-C4). Radiograph confirms the presence of a relatively short mandibular ramus and a caudally positioned hyoid. A large hypopharyngeal tongue is evident. Also note the markedly reduced posterior airway space and increased prevertebral soft tissue caused by the coexisting obesity.

The fact that the laryngeal structure is positioned relatively more rostrally in children than in adults is well-known. Schwartz and Keller<sup>6</sup> have documented that maturational descent of the epiglottis and larynx (in relation to the cervical vertebrae) occurs in a predictable pattern from infancy into adulthood. Maltais *et al.*<sup>7</sup> have found that although the MP-H is consistently longer in patients with OSA, the length of MPH also correlates with age: the older adults tend to have a longer MPH, indicating a more caudally positioned hyoid in the older population.

The clinical implication of these observations is that because the tongue muscle is hinged to the hyoid, the base of the tongue also tends to descend caudally with increase in age and to bring down a portion of the tongue from the oral cavity into the hypopharynx. The more caudally the hyoid is positioned, the larger the tongue mass that is collected in the hypopharyngeal space. This large hypopharyngeal tongue then tends to proportionally compromise the posterior airway space and create supraglottic soft tissue obstruction during sleep or anesthesia, thus resulting in various degrees of snoring, OSA, DMV, and DI. The effect of a large hypopharyngeal tongue on airway obstruction can be aggravated when combined with other unfavorable anatomic or pathologic factors, such as a small atlanto-occipital gap, temporomandibular joint problems, obesity, or lingual tonsil.

We have studied lateral cervical soft tissue radiographs of normal individuals and heavy snoring, OSA, DMV, and DI patients, which illustrate the effect of a relatively longer MHD and its associated large hypopharyngeal tongue. Here, because of space limitations, we will show only one patient (fig. 1). Interested readers are welcome to contact us privately to share more of our radiographs and for details about our radiographic method.

The theoretical explanation and clinical evidence regarding the large hypopharyngeal tongue in OSA, DMV, and DI are in accordance with the findings by Langeron *et al.*<sup>1</sup> that older, obese, or snoring individuals tend to have DMV and DI. However, a relatively longer MHD, with its associated large hypopharyngeal tongue, usually is not visible as an obvious external physical feature,<sup>5</sup> such as a receding jaw, bucked teeth, or a long maxilla. Thus far, practitioners have not paid much attention to this anatomic characteristic. Langeron *et al.*<sup>1</sup> also did not consider it a possible DMV risk factor in their study. Perhaps the unawareness of this important anatomic abnormality may account for the low prediction rate of DMV and DI. We have found that because the mandible and hyoid are identifiable anatomic landmarks, with experience, patients with a relatively longer MHD can be identified in a routine physical examination without cervical radiography. We believe that the role of a large hypopharyngeal tongue in the understanding and management of difficult airway should be duly assessed.

**Hsiu-chin Chou, M.D.,\* Tzu-lang Wu, M.D.** \*Kaiser Permanente Medical Center, Hayward, California. hsiuchin.chou@achi.com

### References

1. Langeron O, Masso E, Huraux C, Guggiari M, Bianchi A, Coriat P, Riou B: Prediction of difficult mask ventilation. *ANESTHESIOLOGY* 2000; 92:1229-36
2. Riley RW, Powell NB, Guilleminault C, Pelayo R, Troell RJ, Li KK: Obstructive sleep apnea surgery: Risk management and complications. *Otolaryngol Head Neck Surg* 1997; 117:648-52
3. Hiremath AS, Hillman DR, James AL, Noffsinger WJ, Platt PR, Singer SL: Relationship between difficult tracheal intubation and obstructive sleep apnoea. *Br J Anaesth* 1998; 80:606-11
4. Riley R, Guilleminault C, Herran J, Powell N: Cephalometric analyses and flow-volume loops in obstructive sleep apnea patients. *Sleep* 1983; 6:303-1

5. Chou H-C, Wu T-L: Mandibulohyoid distance in difficult laryngoscopy. *Br J Anaesth* 1993; 71:335-9

6. Schwartz DS, Keller MS: Maturational descent of the epiglottis. *Arch Otolaryngol Head Neck Surg* 1997; 123:627-8

Anesthesiology 2001; 94:936

*In Reply:*—We greatly appreciate the interest expressed by Drs. Chou and Wu regarding our article.<sup>1</sup> As reported previously,<sup>2</sup> some subjects in whom the trachea is difficult to intubate are at increased risk of obstructive sleep apnea (OSA). Moreover, patients who have difficult intubation (DI) and OSA may share upper airway anatomical abnormalities with a difficult mask ventilation (DMV) situation. In our study, we identified five independent factors (age > 55 yr, body mass index > 26 kg/m<sup>2</sup>, beard, lack of teeth, and history of snoring) associated significantly with DMV. Some of these risk factors for DMV (age > 55 yr, body mass index > 26 kg/m<sup>2</sup>, and history of snoring) are related to malproportion of overall body size or malproportion between the oropharyngeal free space and internal structures of the oropharynx, as in OSA. Our first comment in response to Drs. Chou and Wu is that the purpose of our study was to identify factors predicting DMV and not to correlate DMV to OSA. Second, Drs. Chou and Wu reported that a longer mandible and hyoid distance (MHD) indicated an increased tongue mass in the hypopharynx, compromising the posterior airway space.<sup>3</sup> Unfortunately, measurement of MHD may be difficult because of its wide variation among the adult population and the need for experience as mentioned in their letter. Moreover in their previous study,<sup>3</sup> MHD was obtained from lateral cervical spine radiograph measurements and not from clinical findings. Last, in a more recent study,<sup>2</sup> MHD was not significantly different in DI and non-DI patients and was not related to OSA. Nevertheless, we are convinced that MHD could be valuable information in predicting an OSA-DMV-DI situation if it could be validated in a clinical setting without performing measurements from radiographs. Therefore, further studies are required to determine if MHD could be a reliable clinical predictor of OSA-DMV-DI cases.

We thank Dr. Takenaka *et al.* for the interest in our work and their valuable comments. We fully agree that the jaw-thrust maneuver can reopen the obstructed airway by lifting up the base of the tongue and the epiglottis in anesthetized patients. Moreover, Calder *et al.*<sup>4</sup> reported that impaired mandibular protrusion was associated with a more difficult laryngoscopy in patients with cervical spine disease. Indeed, in patients with an occipito-atlanto-axial disease as in the study of Calder *et al.*,<sup>4</sup> a poor mandibular protrusion is recognized. Conse-

7. Maltais F, Carrier G, Cormier Y, Series F: Cephalometric measurements in snorers, non-snorers, and patients with sleep apnoea. *Thorax* 1991; 46:1419-23

(Accepted for publication December 13, 2000.)

© 2001 American Society of Anesthesiologists, Inc. Lippincott Williams & Wilkins, Inc.

quently, we may assume that decreased mandibular protrusion in an awake patient is a good predictor of a reduced cervical spine mobility associated with impaired laryngoscopy. In addition, this test may not assess reliably a potential decreased airway patency in the anesthetized patient without spine disease. Therefore, we cannot extrapolate information related to difficult laryngoscopy and difficult intubation to those with DMV requiring specific investigation. In our opinion, the relation between a reduced mandibular protrusion in the awake state and DMV remains to be shown.

We thank Dr. Gentili for his interest in our work and the comments. The purpose of our study was to identify factors predicting DMV *per se* and not to determine the influence of the degree of clinical experience of the anesthesiologist in a DMV situation. Consequently, as mentioned in the article, this study involved staff anesthesiologists. Nevertheless, we agree with Dr. Gentili that the annual clinical case loads for an individual anesthesiologist may influence his or her clinical practice. However, this is true for any daily clinical activity for a physician and was not the purpose of our study. Last, incidence of DMV has been assessed rarely in previous studies related to airway management, and no specific investigation has been performed to study DMV. This point may explain largely the discrepancy for the DMV incidence in our study in comparison with other studies.

Olivier Langeron, M.D., Groupe Hospitalier Pitié-Salpêtrière, Paris, France. olivier.langeron@psl.ap-hop-paris.fr

## References

1. Langeron O, Masso E, Huraux C, Guggiari M, Bianchi A, Coriat P, Riou B: Prediction of difficult mask ventilation. *ANESTHESIOLOGY* 2000; 92:1229-36
2. Hiremath AS, Hillman DR, James AL, Noffsinger WJ, Platt PR, Singer SL: Relationship between difficult tracheal intubation and obstructive sleep apnoea. *Br J Anaesth* 1998; 80:606-11
3. Chou HC, Wu TL: Mandibulohyoid distance in difficult laryngoscopy. *Br J Anaesth* 1993; 71:335-9
4. Calder I, Calder J, Crockard HA: Difficult direct laryngoscopy in patients with cervical spine disease. *Anaesthesia* 1995; 50:756-63

(Accepted for publication December 13, 2000.)

Anesthesiology 2001; 94:937

© 2001 American Society of Anesthesiologists, Inc. Lippincott Williams & Wilkins, Inc.

## The Costs of Medicare Compliance

*To the Editor:*—Williams *et al.*<sup>1</sup> describe their technique of performing anesthetic procedures before operating room entry to decrease “anesthesia-controlled time” and costs. Unfortunately, the authors did not warn of the potential economic, fraud, and abuse problems that could result if other practices adopted their methods. While medically directing a case under Medicare rules, an anesthesiologist is not permitted to perform a nerve block in another patient (unless it is a labor epidural). If an anesthesiologist performs or supervises a block with a resident while medically directing care in the operating room, only 50% of the Medicare anesthesia reimbursement for that case can be billed because residents are not permitted to bill Medicare part B for their services.

In the practice of Williams *et al.*,<sup>1</sup> this does not seem to be a concern because the mean age of their patients is 26.6 yr, suggesting that Medicare patients did not constitute even a small fraction of the patients in the study. Many other practices have significant amounts of

Medicare patients, and issues of concurrency, reimbursement, and fraud and abuse must be considered when deciding whether anesthesiologists should start regional anesthesia procedures in a holding room while medically directing anesthesia care in other operating rooms.

Scott Bradley Groudine, M.D., Albany Medical College, Albany, New York. groudin@mail.amc.edu

## Reference

1. Williams BA, Kentor KL, Williams JP, Figallo CM, Sigl JC, Anders JW, Bear BS, Tullock WC, Bennett CH, Harner CD, Fu FH: Process analysis in outpatient knee surgery: Effects of regional anesthesia and general anesthesia on anesthesia-controlled time. *ANESTHESIOLOGY* 2000; 93:529-38

(Accepted for publication January 3, 2001.)

Anesthesiology 2001; 94:938

*In Reply:*—We commend Dr. Groudine for a thoughtful comment on competing interests in delivering institution-specific quality care. One goal of our article was to evaluate associated postoperative outcomes and expended nursing resources based on the anesthetic techniques used. Another purpose of our manuscript was to review the economic (time) impact of performing blocks in the holding area. These blocks were performed (most commonly) by a resident who was assigned for 6 weeks on a regional anesthesia resident rotation. This staffing detail was integral to our published discussion because we deemed that there was little use in describing a care process that did not comply with established care guidelines. However, we did not use the discussion as a forum to address the issue of compliance with such guidelines.

Indeed, the intent of our article was not to advise health care systems regarding compliance to guidelines established by Medicare or

© 2001 American Society of Anesthesiologists, Inc. Lippincott Williams & Wilkins, Inc.

the Health Care Financing Administration as they relate to regional anesthesia care delivery. However, Dr. Groudine astutely notes that such issues were less relevant in the patient population of our article, as noted by the patients' mean age of just less than 27 yr. Each institution should examine its own compliance with regard to Health Care Financing Administration regulations and personnel issues as they relate to the specific patient populations for which the institution provides care.

**Brian A. Williams, M.D., M.B.A.,\* Michael L. Kentor, M.D., John P. Williams, M.D.** \*University of Pittsburgh, Pittsburgh, Pennsylvania. williamsba@anes.upmc.edu

(Accepted for publication January 3, 2001.)


Anesthesiology 2001; 94:938

© 2001 American Society of Anesthesiologists, Inc. Lippincott Williams & Wilkins, Inc.

## An Intubating Airway with Teeth

*To the Editor:*—An intubating airway is a useful aid in fiberoptic intubation. While recently preparing to perform an urgent awake oral fiberoptic intubation, a 10-cm Williams Fiberoptic Intubating Airway (Anesthesia Associates, Inc., San Marcos, CA) was readied for insertion. At this time, it was noted that the airway was defective, with two plastic tooth-like spikes protruding inside the airway's lumen, approximately 2 cm from the flange (fig. 1). Two additional airways from the same package were found to have identical defects. A fourth airway without such a defect was used, and fiberoptic endotracheal intubation was accomplished easily with it.

Inspection of the Williams airway before placement prevented the use of this defective device. Later, an attempt to pass a 7.5-mm endotracheal tube through this airway resulted in a large tear of the endotracheal cuff and dislodgment of one of the protruding plastic pieces. In a patient, this could have resulted in two potential problems: a leaking endotracheal cuff and a foreign object in the airway. All of the defective Williams airways that we found came in the same package and were from the same batch. A careful check of our remaining stock did not reveal additional defective airways. The plastic spikes appeared to have been formed during the manufacturing process, perhaps as a result of a defective mold. Because several of our Williams airways had this defect, it is possible that other practitioners may encounter such a manufacturing defect, and, therefore, we wanted to alert readers to this potential problem. We have also informed the manufacturer about this defect. This experience illustrates that even under emergency situations, it is important to check equipment for unexpected flaws that may endanger the patient.



**Fig. 1.** Side-by-side comparison of a normal Williams intubating airway (*left*) and the faulty one (*right*). Note a protruding plastic piece (“tooth”) in the circular lumen of the faulty airway, at approximately the 2 o'clock position. A second “tooth” was located at the 10 o'clock position and has been dislodged after passing an endotracheal tube.

**Luis G. Michelsen, M.D.,\* Honorio Valdes-Murua, M.D.** \*Emory University School of Medicine, Atlanta, Georgia. Luis\_Michelsen@emory.org

(Accepted for publication December 4, 2000.)

Anesthesiology 2001; 94:938-9

© 2001 American Society of Anesthesiologists, Inc. Lippincott Williams & Wilkins, Inc.

*In Reply:*—The 10-cm Williams Fiberoptic Intubating Airway is a disposable device manufactured by 349556 Alberta Inc. (Calgary, Alberta, Canada) and distributed in the United States by Anesthesia Associates, Inc., as well as by several other firms. The recent incident, referred to by Drs. Michelsen and Valdes-Murua in their letter, occurred with products that may have been distributed by Anesthesia Associates, Inc.

The products in question were reported to have been pulled from a hospital cart repackaged ziplock bag (not the original packaging) and no longer had any distributor lot number identification attached. However, apparently the bag did contain a copy of an Anesthesia Associ-

ates, Inc. product insert titled “Williams™ Airway Intubator.” It has been determined through the obsolete telephone area code shown on the product insert that the insert in question was printed for distribution with products that would have been shipped during the year 1996 or earlier. Although not a substitute for the missing lot number identification, it does indicate that it is probable that the products in question were shipped from our facility in 1996 or before.

It is of note that in 1995, a concern was acknowledged by the manufacturer of the airways (349556 Alberta Inc.) regarding manufacturing mold wear leading to internal “teeth” identical to those described by Drs. Michelsen and Valdes-Murua in their letter. At that time,

Anesthesia Associates, Inc. (as well as other distributors of the product) identified the affected lot numbers of all products that exhibited this deficiency. Specific action was taken to notify all affected Anesthesia Associates, Inc. dealers that there was a concern, and it was further requested that all inventories be returned for reinspection. All units returned and found to be deficient were destroyed; however, some dealers had inventory that already had made its way to the end user and had been discarded or lost. No patient injuries or problems were reported from this issue.

The manufacturer took appropriate steps in 1995 to eliminate the deficiency that had been noted. The molds were completely rebuilt to eliminate the existing wear, and more stringent mold inspection criteria were established. Inspection levels for the finished devices were changed from a statistical sampling to a 100% full inspection level to eliminate any question of deficient products. The distributor also increased their inspection level an additional safety check. To date,

there have been no known reoccurrences of the issue other than the referenced letter.

From the apparent age (1996 or earlier) of the devices of Drs. Michelsen and Valdes-Murua, it appears that they may have been part of the group of products in 1995 that generated the actions indicated herein. The particular units that they had in their cart most probably circumvented the 1995 retrieval program. The specifics of whether they were in the hospital storage system during this entire period or arrived more recently from a vendor are not known. The concern of Drs. Michelsen and Valdes-Murua regarding the products is understandable, and we applaud their efforts to alert others regarding safety issues. However, we are firm in our belief that this is an isolated event that is a holdover from a previously corrected situation.

**R. Lockwood Williams, P.E.**, Anesthesia Associates, Incorporated, San Marcos, California. solutions@AincA.com

(Accepted for publication December 4, 2000.)

Anesthesiology 2001; 94:939

© 2001 American Society of Anesthesiologists, Inc. Lippincott Williams & Wilkins, Inc.

## Head Extension Angle Required for Direct Laryngoscopy with the McCoy Laryngoscope Blade

*To the Editor:*—In patients with cervical spine injuries, laryngoscopy is usually difficult because of reduced mobility of the neck. Recently, new devices for laryngoscopy, such as the Bullard (Circon AMCI, Stamford, CT) and McCoy (Penlon Ltd., Abingdon, UK) laryngoscopes<sup>1,2</sup> and the WuScope (Pentax Precision Instruments, Orangeburg, NY),<sup>3</sup> have been available in cases of difficult laryngoscopy. Hastings *et al.*<sup>4</sup> compared head extension and laryngeal view obtained with the Bullard, Macintosh (Penlon Ltd.), and Miller (Penlon Ltd.) laryngoscopes and concluded that the Bullard laryngoscope caused less head extension than a conventional laryngoscope. The McCoy laryngoscope is a modification of the Macintosh laryngoscope. The hinged tip controlled by a lever causes elevation of the epiglottis, thus facilitating visualization of the larynx.<sup>2</sup> In the current study, we compared the McCoy and Macintosh laryngoscopes with regard to head extension angles required for direct laryngoscopy.

Twenty adult patients (aged  $24 \pm 8$  yr) with normal cervical spines who were scheduled to undergo elective oral and maxillofacial surgery with general anesthesia participated in this study after institutional review board approval and written informed consent. After intravenous administration of thiamylal and vecuronium, laryngoscopy was performed using the McCoy blade or the Macintosh blade at random in the same patient. The patient's head was placed on a flat board in a neutral position so that the eye-ear plane (Frankfort horizontal plane) was perpendicular to the board. Then, head extension angle, based on the tilt of the eye-ear plane, was measured during laryngoscopy. In each trial, head extension angle was recorded in grade 1 (most of the glottis visible) and grade 2 (no more than the arytenoid cartilages visible) of the Cormack and Lehane classification of laryngoscopic view.<sup>5</sup> Cricoid pressure was not applied. Head and neck stabilization was not used, but the laryngoscopist was not allowed to lift the patient's head off the board during laryngoscopy.

Values were expressed as mean  $\pm$  SD. The differences in head extension angles produced by the two laryngoscope blades were analyzed using the Wilcoxon signed rank test. A *P* value of less than 0.05 was considered significant.

Head extension angles required for arytenoid exposure were  $15.4 \pm 3.8^\circ$  for the Macintosh blade and  $9.3 \pm 4.1^\circ$  for the McCoy blade. The angles needed to obtain the best view of the vocal cords were  $26.3 \pm 3.6^\circ$  for the Macintosh blade and  $18.0 \pm 4.4^\circ$  for the McCoy blade. These results showed that the McCoy laryngoscope reduced the head extension angle required to visualize the arytenoid cartilages and vocal cords approximately  $6-8^\circ$  in comparison with the Macintosh laryngoscope ( $P < 0.0001$ ). Several investigators reported that the McCoy laryngoscope improved the view of the larynx in patients with simulated cervical injuries.<sup>6-8</sup> With regard to head extension angle, our study showed that the McCoy blade was more useful than the Macintosh blade in patients with limited neck extension.

**Kazuna Sugiyama, D.D.S., Ph.D.,\*** **Kozo Yokoyama, D.D.S., Ph.D.** \*Kagoshima University Dental Hospital, Kagoshima, Japan. sugi@dentc.hal.kagoshima-u.ac.jp

## References

1. Cooper SD, Benumof JL, Ozaki GT: Evaluation of the Bullard Laryngoscope using the new intubating stylet: Comparison with conventional laryngoscopy. *Anesth Analg* 1994; 79:965-70
2. Tuckey JP, Cook TM, Render CA: An evaluation of the levering laryngoscope. *Anaesthesia* 1996; 51:71-3
3. Smith CE, Pinchak AB, Sidhu TS, Radesic BP, Pinchak AC, Hagen JF: Evaluation of tracheal intubation difficulty in patients with cervical spine immobilization: Fiberoptic (WuScope) versus conventional laryngoscopy. *ANESTHESIOLOGY* 1999; 91:1253-9
4. Hastings RH, Vigil AC, Hanna R, Yang BY, Sartoris DJ: Cervical spine movement during laryngoscopy with the Bullard, Macintosh, and Miller laryngoscopes. *ANESTHESIOLOGY* 1995; 82:859-69
5. Cormack RS, Lehane J: Difficult tracheal intubation in obstetrics. *Anaesthesia* 1984; 39:1105-11
6. Laurent SC, de Melo AE, Alexander-Williams JM: The use of the McCoy laryngoscope in patients with simulated cervical spine injuries. *Anaesthesia* 1996; 51:74-5
7. Uchida T, Hikawa Y, Saito Y, Yasuda K: The McCoy levering laryngoscope in patients with limited neck extension. *Can J Anaesth* 1997; 44:674-6
8. Gabbott DA: Laryngoscopy using the McCoy laryngoscope after application of a cervical collar. *Anaesthesia* 1996; 51:812-4

(Accepted for publication November 29, 2000.)

Support was provided solely from institutional and/or departmental sources.

Anesthesiology 2001; 94:940

© 2001 American Society of Anesthesiologists, Inc. Lippincott Williams &amp; Wilkins, Inc.

## Electrical Short Circuit As a Possible Cause of Death in Patients on PCA Machines: Report on an Opiate Overdose and a Possible Preventive Remedy

*To the Editor:*—Patient-controlled analgesia (PCA) machines are used commonly for postoperative pain management, largely because of their tremendous clinical benefits. A typical PCA machine contains an embedded computer that is programmed using a keypad to give, for example, 1 mg morphine every time the patient pushes the analgesic demand push button (pain pendant). (This is a push button on the end of a cable that usually looks and feels much like a nurse call button.) To help prevent excessive drug administration, the on-board computer ignores further patient demands until a “lockout” period has passed. This period usually is set at between 5 and 10 min.

Unfortunately, misadventures have been attributed to inadvertent misprogramming or other problems associated with these devices.<sup>1-8</sup> We report herein a case in which intermittent short circuits from frayed wires in the pendant resulted in a drug unintentionally being delivered automatically.

A 62-yr-old retired grain inspector was diagnosed with carcinoma of the prostate after a transurethral resection of prostate (TURP) procedure and subsequently presented to the hospital for radical prostatectomy. His previous medical health had been unremarkable except for a 20-yr history of smoking and remote appendectomy. He took no regular medications and had no allergies. Routine preoperative laboratory studies were unremarkable except for some unifocal ventricular premature beats on the electrocardiograph.

The anesthesia and surgery were uneventful, as was his stay in the postanesthesia care unit, where he was given an Abbott Lifecare 4100 PCA Plus II PCA machine (Abbott Laboratories, Abbott Park, IL) that was programmed to deliver conditionally 1 mg morphine intravenously each time the pain pendant was activated. The lockout period was set at 6 min. After his stay in the postanesthesia care unit, the patient was admitted to the general urology ward, where he spent an uneventful night.

Late the following morning, the nursing staff was alerted by the patient's wife, who indicated that she was unable to wake her husband. The nurses found the patient to be “unresponsive, diaphoretic, and with labored breathing.” A “code blue” was called. The responding team noted the following vital signs: blood pressure, 152/70 mmHg; heart rate, 62 beats/min; and respiratory rate, 8 breaths/min. The pupils were noted to be miotic. Pulse oximetry was not immediately available. Naloxone, 0.4 mg, was administered intravenously, resulting in a marked clinical improvement. No harm came to the patient. The patient subsequently was placed on close observation, and PCA was discontinued. The PCA machine was sent to the medical engineering department for inspection.

The medical engineering technicians noted that the wires in the pain pendant were frayed and determined that the machine would register analgesic demands without the push button being depressed. They concluded that the frayed wires in the pendant were short-circuiting

intermittently, creating a false triggering situation. The defective pendant was replaced.

Numerous clinical problems with PCA technology have been identified.<sup>1-8</sup> Some of these problems are caused by human error, with some of these errors being a consequence of a hostile user interface (unforgiving and unintuitive).<sup>5,9,10</sup>

However, in our situation, machine failure, not human error, was the source of the problem. We note that a partial solution for this problem (beyond mere periodic inspection and testing of the push button) would be for the manufacturer to add a software safety self-check routine in the embedded microcomputer in the PCA pump to check the push button signal line for lengthy periods of continuous assertion (e.g., for more than 10 s). As well, such safety software could also check for instances in which the interval between the end of the lockout period and the next analgesic demand is unreasonably short (such as less than 100 ms). Such solutions require only a software upgrade in existing PCA machines. Another partial solution applicable to new designs is to also use a double-pole, single-throw push button and two signal lines, with software to check that the lines always carry an identical signal. Finally, we emphasize that by disseminating these safety concepts widely through this communication, we are making the idea unpatentable and thus freely available for all to use at no cost.

**D. John Doyle, M.D., Ph.D., F.R.C.P.C., P.Eng.,\* Kim J. Vicente, Ph.D., P.Eng.** \*University of Toronto and Toronto General Hospital, Toronto, Ontario, Canada. djdoyle@home.com

### References

- Jennings N: Patient-controlled analgesia: A serious incident. *Anaesthesia* 1992; 47:1093-4
- Notcutt W: Overdose of opioid from patient controlled analgesia pumps (letter). *Br J Anaesth* 1992; 68:450
- White E: A problem with the Graseby 3300 PCA pump. *Anaesthesia* 1993; 48:1013-4
- Kwan A: Overdose of morphine during PCA (letter). *Anaesthesia* 1995; 50:919
- ECRI: Abbott PCA Plus II patient-controlled analgesia pumps prone to misprogramming resulting in narcotic overinfusions. *Health Devices* 1997; 26: 389-91
- Christie L, Cranfield KA: A dangerous fault with a PCA pump (letter). *Anaesthesia* 1998; 53:827
- Ma M, Chen PP, Chan S, Chung D: A potential PCA hazard (letter). *Anaesthesia* 1998; 53:314
- Chan S, Chen PP, Chui PT, Ma M: Unintentional bolus with Graseby 9300 pump (letter). *Anaesth Intensive Care* 1998; 26:117
- Brown SL, Bogner MS, Parmentier CM, Taylor JB: Human error and patient-controlled analgesia pumps. *J Intraven Nurs* 1997; 20:311-6
- Lin L, Isla R, Doniz K, Harkness H, Vicente KJ, Doyle DJ: Applying human factors to the design of medical equipment: patient-controlled analgesia. *J Clin Monit Comput* 1998; 14:253-63

(Accepted for publication November 29, 2000.)

Support was provided solely from institutional and/or departmental sources.

Anesthesiology 2001; 94:940-1

© 2001 American Society of Anesthesiologists, Inc. Lippincott Williams &amp; Wilkins, Inc.

## Accidental Extreme Neck Extension during Repositioning of an Operating Room Table

*To the Editor:*—We would like to present a report of two cases with an unusual intraoperative complication. A 12-yr-old boy with American Society of Anesthesiologists physical status I presented for tonsillectomy and adenoidectomy. After induction of anesthesia, the operating room (OR) table was rotated 90° to facilitate surgery. While moving the table, the head attachment of the table came off, causing the patient's

tomomy and adenoidectomy. After induction of anesthesia, the operating room (OR) table was rotated 90° to facilitate surgery. While moving the table, the head attachment of the table came off, causing the patient's



head to drop into an extreme extended position. When the headpiece was repositioned, cervical and upper thoracic spine radiography was performed, and the patient was allowed to awaken until he was seen to be moving all four limbs. An emergency neurosurgical consult was sought, and serious injury was ruled out. The incident was discussed with the family, and surgery was performed without complications. The postoperative course was uneventful.

A 3-yr-old boy with American Society of Anesthesiologists physical status I presented for tonsillectomy and adenoidectomy with general anesthesia. Again, while rotating the OR table to facilitate surgery, the headpiece of the table came away, resulting in hyperextension of the patient's neck. Radiographs of the cervical and thoracic spine were examined by a neuroradiologist, who detected no abnormalities. The depth of anesthesia was decreased to facilitate neurologic examination.

---

Support was provided solely from institutional and/or departmental sources.

After confirming absence of injury, anesthesia depth was increased, and surgery was completed. The postoperative course was uneventful.

The operating table used in our OR (Quantum 3080; Steris Ltd., Mentor, OH) has the headpiece attached with two polished stainless steel pins. The manufacturer does not recommend moving the OR table while holding the headpiece. Obviously, in these two cases, the fixating screws were not tight enough, permitting the head attachment to come off during table repositioning. This situation has a potential for traumatic extubation, cervical spinal cord injury, and head trauma. Operating room personnel should be aware of the possibility of this complication, which can occur with any OR table with a detachable headpiece, and they are encouraged to verify attentively the integrity of the OR table.

**Peter Szmuk, M.D.,\* David Abramson, M.B.Ch.B., F.A.A.P., David R. Warters, M.D., Kevin Pereira, M.D., M.S.(O.R.L.), Jeffrey Katz, M.D.** \*The University of Texas-Houston Medical School, Houston, Texas. Peter.Szmuk@uth.tmc.edu

*(Accepted for publication January 4, 2001.)*