

## Recurrent Pulmonary Embolism during Liver Transplantation: Possible Role of Hepatitis B Immune Globulin As a Causative Agent

Weng H. Wong, M.Med. (Anesth.),\* Michelle Braunfeld, M.D.,† Philip Levin, M.D.‡

MASSIVE pulmonary embolism (PE), although an uncommon complication in liver transplant surgery is associated with a high mortality rate. Five of nine patients reported to have massive PE in the past 12 yr died from this complication.<sup>1,2</sup> We report a case of PE that occurred in the same patient during two consecutive liver transplant procedures in association with the use of an antifibrinolytic and hepatitis B immune globulin (HBIG).

### Case Report

A 52-yr-old man was admitted for orthotopic liver transplantation because of end-stage liver disease secondary to hepatitis B and C and recurrent hepatocellular carcinoma. Two years before admission, he had intractable ascites and severe portal hypertension for which a transjugular intrahepatic portosystemic shunt procedure was performed.

Previous operations for repair of inguinal and umbilical hernias as well as a splenectomy 7 yr before the current admission for thrombocytopenia were without complications. Physical examination revealed a well-nourished patient with no abnormalities of the cardiovascular or respiratory systems. An echocardiogram showed normal cardiac function with an ejection fraction between 55 and 60% and no discrete vegetations, mural thrombi, or intracardiac masses. Laboratory results included prothrombin time of 17.6 s, international normalized ratio (INR) of 1.7, partial thromboplastin time of 31.1 s, fibrinogen of 128 mg/dl, and platelet count of  $128 \times 10^9/l$ .

Anesthesia was induced in a rapid-sequence manner with thiopental and succinylcholine and was maintained with isoflurane and cisatracurium. A loading dose of 5 g  $\epsilon$ -aminocaproic acid followed by an infusion of 1 g/h was started as per our usual practice. A  $CaCl_2$  infusion at 1 g/h was also started. A right radial arterial catheter was placed, and two 9-French ports (Arrow, Reading, PA) were inserted in the right internal jugular vein through which a 7.5-French pulmonary artery (PA) catheter (Baxter, Oakland, CA) was inserted in one without difficulty. Initial blood pressure was 140/70 mmHg; heart rate was 75 beats/min; pulmonary arterial pressure was 37/25 mmHg; cardiac output was 6.4 l/min, and central venous pressure was 16 mmHg. Venovenous bypass with a centrifugal pump (Biomedicus; Medtronic, Eden Prairie, MN) and nonheparinized tubing was started at a flow of 1.8-2

l/min. The surgery proceeded uneventfully until the liver was removed and a 2-ml test dose of HBIG (Nabi, Boca Raton, FL) was administered *via* one of the internal jugular ports. Blood pressure decreased from 115/54 mmHg to a low of 58/20 mmHg within 10 min after HBIG administration. Simultaneously, pulmonary arterial pressure increased from 37/25 to 50/32 mmHg, and end-tidal carbon dioxide ( $ETCO_2$ ) decreased to 18 mmHg. Cyanosis and venous engorgement of the upper torso were observed. HBIG and  $\epsilon$ -aminocaproic acid infusions were discontinued immediately. A transesophageal echocardiographic probe inserted to confirm a clinical diagnosis of PE showed a large thrombus in the right atrium. Resuscitation with intravenous ephedrine and epinephrine was instituted with return to baseline level hemodynamics and resolution of thrombus after 30 min. The new graft was transplanted successfully. The patient was transfused with a total of 16 units of erythrocytes, 18 units of fresh frozen plasma, 20 units of cryoprecipitate, and 10 units of platelets. The coagulation profile at the end of surgery was prothrombin time of 21.3 s, INR of 2.2, platelet count of  $94 \times 10^9/l$ , and fibrinogen of 73 mg/dl.

Unfortunately, the liver graft did not function well postoperatively. Despite fresh frozen plasma and platelet infusions, the patient remained coagulopathic. The results of postoperative radiologic imaging and ultrasound studies excluded any clots in the heart, extremities, or the vena cavae. Four days after the first transplant, the patient underwent subsequent transplantation for primary nonfunction.

The patient arrived in the operating room with the same invasive monitors from the previous operation in place. Induction with isoflurane, midazolam, and fentanyl was uneventful. Variables were as follows: blood pressure, 150/70 mmHg; pulmonary arterial pressure, 35/18 mmHg; central venous pressure, 8 mmHg; and cardiac output, 12.6 l/min. The surgical team believed the first PE to be caused by migration of a thrombus adherent to the patient's transjugular intrahepatic portosystemic shunt. After discussion with the surgeon, it was decided that an antifibrinolytic should be used in anticipation of bleeding. A loading dose of 2 g  $\epsilon$ -aminocaproic acid and infusion of 1.5 g/h were administered. The dissection phase of the operation was uneventful. The patient was again placed on venovenous bypass and was pretreated with hydrocortisone, famotidine, and diphenhydramine in anticipation of HBIG administration. Ten thousand units of HBIG was administered *via* the right internal jugular port over 15 min during the anhepatic period as the suprahepatic vena cava was being reanastomosed. Blood pressure was then noted to decrease precipitously from 110/55 mmHg to 60/33 mmHg soon after HBIG infusion was completed. Pulmonary arterial pressure and central venous pressure were increased at 63/33 mmHg and 40 mmHg, respectively.  $ETCO_2$  was not recordable. PE was again suspected, and a transesophageal echocardiographic probe was inserted, showing large thrombi in the right atrium and right ventricle. The patient was resuscitated with 35 mg epinephrine, 12 mg norepinephrine, 3 g  $CaCl_2$ , 0.4 mg atropine, 100 ml  $NaHCO_3$ , and 200 mg lidocaine. Despite an infusion of epinephrine, the patient remained hypotensive, acidotic, and coagulopathic. Laboratory results in the intensive care unit showed prothrombin time greater than 100 s, INR greater than 10, platelet count of  $50 \times 10^9/l$ , pH of 7.17, partial pressure of oxygen ( $PO_2$ ) of 108, partial pressure of carbon dioxide ( $Pco_2$ ) of 40, and base excess of -13. Two hours after arrival in the intensive care unit, pulseless electrical activity developed in the patient, and he died after unsuccessful resuscitation efforts.

\* Fellow, Department of Anesthesiology, University of California-Los Angeles School of Medicine, Los Angeles, California. Current position: Associate Consultant, Department of Anesthesiology, National University Hospital, Singapore. † Associate Professor, ‡ Assistant Professor, Department of Anesthesiology, University of California-Los Angeles School of Medicine.

Received from the Department of Anesthesiology, University of California-Los Angeles School of Medicine, Los Angeles, California. Submitted for publication July 16, 2001. Accepted for publication October 30, 2001. Supported by the Department of Anesthesiology, University of California-Los Angeles School of Medicine, and the Department of Anesthesiology, National University Hospital, Singapore.

Address reprint requests to Dr. Wong: Department of Anesthesiology, National University Hospital, 5 Lower Kent Ridge Road, Singapore 119074. Address electronic mail to: whwkc@yahoo.com. Individual article reprints may be purchased through the Journal Web site, www.anesthesiology.org.

## Discussion

We report an unusual case of PE occurring in the same patient during two consecutive liver transplant procedures. Our patient was fairly healthy with normal cardiopulmonary function before the first transplant. An echocardiogram did not reveal any thrombi or vegetations. He had no history of deep vein thrombus or cerebrovascular accidents and was mildly coagulopathic preoperatively. The use of a PA catheter has been documented to be associated with massive thrombosis.<sup>3</sup> Trauma to the endothelium with a dilator and the use of a protective sheath may trigger clot formation. We did not encounter any difficulty when inserting the ports or PA catheter through the right internal jugular vein. Furthermore, ultrasound study performed in the intensive care unit with the PA catheter in place did not reveal any blood clots in the vena cavae or the heart.

The advantages of using antifibrinolytics must always be weighed against the risk of thrombosis, particularly in patients with known thrombotic tendency, such as in Budd-Chiari syndrome, disseminated intravascular coagulopathy (DIC), and antiphospholipid syndrome. Preoperatively, there was no evidence to suggest that our patient was in a thrombotic state. He had an INR of 1.7 and a prothrombin time of 17.6 s. At the time of the first PE, he had received 6 units of fresh frozen plasma but no platelets or cryoprecipitate. Nonheparinized venovenous bypass with a heat exchanger was used during both surgeries. There were no clots seen through the clear tubing or in the heat exchanger, and flow was well-maintained until the thrombus obstructed right ventricular outflow. PE occurred both times in this patient during the anhepatic phase when a fibrinolytic state was anticipated.

Violi *et al.*<sup>4</sup> discovered that patients with moderate or severe hepatic insufficiency had higher values of endotoxemia. Endotoxemia promotes tumor necrosis factor synthesis, which activates the extrinsic clotting pathway. This factor may have played a role in the second episode of PE when the patient was severely ill for 4 days with a nonfunctioning graft.

Administration of HBIG has a close temporal association with the onset of PE on both occasions in our patient. HBIG is a solution of immunoglobulin containing antibodies to hepatitis B surface antigen. It is prepared from plasma donated by individuals with high antibody titers and is formulated in sodium chloride, glycine, and polysorbate 80. Adverse effects associated with the use of intravenous immunoglobulin include headache, low-grade fever, transient hypotension, and deep vein thrombosis.<sup>5</sup> A high infusion rate has been correlated with a higher incidence of adverse reactions. HBIG was administered to this patient to reduce the hepatitis B viral load before the donor liver was reperfused. Kang *et al.*<sup>1</sup> reported a case of PE during ortho-

topic liver transplantation when HBIG was administered during the anhepatic phase during venovenous bypass. They suggested that antibody-antigen complexes formed may have activated the intrinsic pathway. Results of an experiment conducted in rabbits by Nakamura *et al.*<sup>6</sup> suggested that antibody-antigen complexes in the microcirculation may initiate activation of platelets and neutrophils with release of mediators responsible for triggering DIC. Fibrin thrombi first appeared in the rabbits' organs, including the lungs, 2 h after challenge with an antiserum and antigen. The time frame may have been compressed in our patient in the presence of an antifibrinolytic, endotoxemia, and DIC. The ferritin-antiferritin complexes in this animal model were phagocytized by Kupffer cells, splenic macrophages, and neutrophils. The authors postulated that saturation of capacity of the reticuloendothelial system to remove circulating immune complexes promoted the progression of DIC. This may explain the paradoxical occurrence of PE during the fibrinolytic, anhepatic phase of the operation in our patient. Although no thrombi were found at autopsy, the patient's lungs were noted to be heavy, a finding consistent with descriptions of similar patients in whom PE developed during orthotopic liver transplantation and who died.<sup>7</sup> No macroscopic pulmonary emboli were detected in these patients, but the lungs were heavy, rubbery, and congested. Numerous platelet aggregates were also found occluding the capillaries. It is possible that prompt termination of HBIG and antifibrinolytic infusion in the current patient allowed natural fibrinolytics, such as tissue plasminogen activator and plasmin, to act on the clot, resulting in its resolution intraoperatively.

Heparin-induced thrombocytopenia type II, in which immunoglobulin G antibodies bind to platelet factor 4 heparin complexes, is a clinical example of antibody-antigen complex-induced platelet aggregation leading to release of procoagulant mediators from platelets.<sup>8</sup> Previous exposure to heparin leads to formation of immunoglobulin G antibodies, and further administration of heparin may result in this phenomenon. Acute systemic reactions, such as fever, chills, and rigors, to an initial dose of heparin may be an early indicator of heparin-induced thrombocytopenia type II.<sup>9</sup> Similar nonspecific symptoms, such as myalgia and arthralgia, have been described in patients given HBIG and are attributed to immune precipitation and formation of immune complexes.<sup>10</sup> Whether HBIG-hepatitis B antigen complexes are able to initiate platelet activation and aggregation leading to thrombi formation that is similar to the animal model of Nakamura and the clinical example of heparin-induced thrombocytopenia type II is unclear. Heparin-induced thrombocytopenia type II is often associated with thrombosis and embolism of the venous system, arterial system, or both. Stroke, myocardial and mesenteric infarction, and PE have been reported in patients

undergoing cardiac surgery when this phenomenon occurs.

In conclusion, we find that a combination of factors, including the use of a PA catheter, endotoxemia and DIC, the use of an antifibrinolytic, and HBIG may have induced a thrombotic state in this patient. Further studies on the use of HBIG in liver transplant patients with similar predisposing factors may ensure its safer use in this group of patients.

The authors thank C. Philip Larson, M.D. (Professor, Department of Anesthesiology, University of California–Los Angeles, Los Angeles, California), for reviewing the manuscript and Daisy Valdez (Administrative Assistant, Department of Anesthesiology, University of California–Los Angeles) for her assistance in the preparation of this manuscript.

## References

1. Navalgund AA, Kang Y, Sarnar JB, Jahr JS, Gieraerts R: Massive pulmonary thromboembolism during liver transplantation. *Anesth Analg* 1988; 67:400–2
2. Sopher M, Braunfeld M, Shackleton C, Busuttill RW, Sangwan S, Cssete M:

Fatal pulmonary embolism during liver transplantation. *ANESTHESIOLOGY* 1997; 87:429–32

3. Chastre J, Cornud F, Bouchama A, Viau F, Benacerraf R, Gibert C: Thrombosis as a complication of pulmonary artery catheterization via the internal jugular vein. Prospective evaluation by phlebography. *N Engl J Med* 1982; 306:278–81

4. Violi F, Ferro D, Basili S, Saliola M, Quintarelli C, Alessandri C, Cordova C: Association between low-grade disseminated intravascular coagulation and endotoxemia in patients with liver cirrhosis. *Gastroenterology* 1995; 109:531–9

5. Sherer Y, Levy Y, Langevitz P, Rauova L, Fabrizzi F, Shoenfeld Y: Adverse effects of intravenous immunoglobulin therapy in 56 patients with autoimmune diseases. *Pharmacology* 2001;62:133–7

6. Nakamura S, Shimokama T, Yoshikawa Y, Watanabe T: Immune complex-induced disseminated intravascular coagulation (DIC): An experimental study. *Acta Pathol Jpn* 1990; 40:476–85

7. Sankey EA, Crow J, Mallett SV, Alcock RJ, More L, Burroughs AK, Rolles K: Pulmonary platelet aggregates: Possible cause of sudden perioperative death in adults undergoing liver transplantation. *J Clin Pathol* 1993; 46:222–7

8. Suh JS, Malik MI, Aster RH, Visentin GP: Characterization of the humoral immune response in heparin-induced thrombocytopenia. *Am J Hematol* 1997; 54:196–201

9. Warkentin TE, Soutar RL, Panju A, Ginsberg JS: Acute systemic reactions to intravenous bolus heparin therapy: Characterization and relationship to heparin-induced thrombocytopenia. *Immunohematology* 1997; 160a:80

10. Shouval D, Samuel D: Hepatitis B immune globulin to prevent hepatitis B virus graft reinfection following liver transplantation: A concise review. *Hepatology* 2000;32:1189–95

*Anesthesiology* 2002; 96:1263–5

© 2002 American Society of Anesthesiologists, Inc. Lippincott Williams & Wilkins, Inc.

# Unilateral Cerebral Oxygen Desaturation during Emergent Repair of a DeBakey Type 1 Aortic Dissection: Potential Aversion of a Major Catastrophe

Gregory M. Janelle, M.D.,\* Stephen Mnookin, M.D.,† Nikolaus Gravenstein, M.D.,‡ Tomas D. Martin, M.D.,§ Felipe Urdaneta, M.D.\*

EMERGENT repair of a dissecting or ruptured DeBakey type 1 aortic aneurysm is associated with mortality rates ranging from 17–88%, with adverse neurologic sequelae as a leading cause of major life-altering morbidity.<sup>1</sup> Neurologic monitoring has been advocated to minimize the potential for neurologic damage. The approach at our institution includes a combination of retrograde cerebral perfusion techniques with neurologic monitoring consisting of a two-channel bipolar electroencephalogram along with bifrontal regional cerebral oxygen saturation (rSO<sub>2</sub>) sensors (INVOS<sup>®</sup> Cerebral Oximeter 5100; Somanetics, Troy, MI). The Somanetics cerebral oximetry device uses near-infrared spectroscopy to determine the ratio of oxyhemoglobin to deoxyhemoglobin in the underlying frontal cerebral cortical blood. It assumes a relative ratio of 25:75 arterial to venous cerebral blood

volume at two predetermined depths from the sensor to determine regional saturation.<sup>2</sup> We report a case in which rSO<sub>2</sub> monitoring prompted a change in surgical therapy, early detection of hemispheric hypoperfusion, and avoidance of a potentially catastrophic neurologic complication.

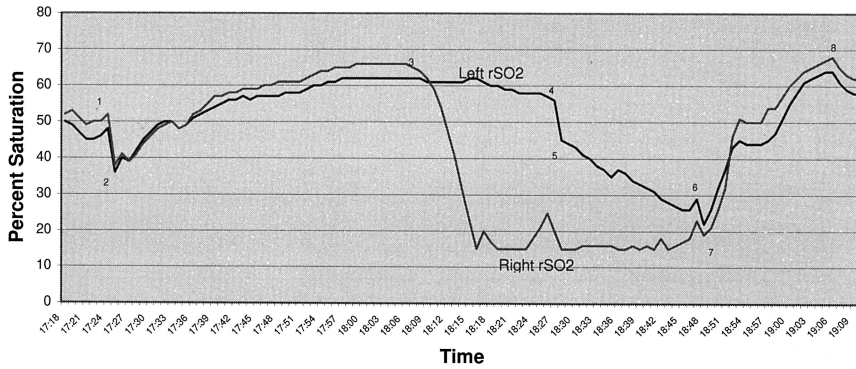
## Case Report

A 75-yr-old man presented with a presumptive diagnosis of an acute DeBakey type 1 aortic dissection. Eight months earlier, he had undergone three-vessel coronary artery bypass graft surgery. Cardiac catheterization at the referring institution showed 80% stenosis of the vein graft to the right coronary artery and an aortic dissection originating in the proximal aortic root. At the time of arrival at our hospital, a preoperative transesophageal echocardiographic examination revealed a 4.9-cm-diameter aortic root, with an aortic dissection extending from just distal to the left main coronary ostium to as far into the descending aorta as the examination permitted. In addition, moderate aortic insufficiency was noted. The patient was brought to the operating room for redosternotomy, coronary artery bypass graft, aortic valve replacement, and repair of the type 1 aortic dissection. General anesthesia was induced with a combination of midazolam, fentanyl, sodium thiopental, and pancuronium. Hemodynamic monitoring included a left radial artery catheter, an oximetric, pulmonary artery catheter, and continuous transesophageal echocardiography (Hewlett-Packard Omniplane, Sonos 5500; Hewlett-Packard, Andover, MA). Continuous two-channel bipolar electroencephalographic monitoring was performed (A1000; Aspect Medical Systems, Newton, MA) with a ground lead (Fz), a left

\* Assistant Professor, † Fellow, Cardiothoracic Anesthesia, ‡ Professor and Chairman, Department of Anesthesiology, § Associate Professor, Division of Thoracic Surgery, Department of Surgery, University of Florida College of Medicine.

Received from the Department of Anesthesiology, University of Florida College of Medicine, Gainesville, Florida. Submitted for publication June 1, 2001. Accepted for publication October 31, 2001. Support was provided solely from institutional and/or departmental sources.

Address reprint requests to Dr. Janelle: PO Box 100254, Gainesville, Florida 32610–0254. Address electronic mail to: Janelle@anest1.anest.ufl.edu. Individual article reprints may be purchased through the Journal Web site, www.anesthesiology.org.



**Fig. 1.** Cerebral oximetry values during cardiopulmonary bypass. 1 = Begin cardiopulmonary bypass; 2 = begin cooling; 3 = sudden right hemispheric desaturation; 4 = begin deep hypothermic circulatory arrest; 5 = begin retrograde cerebral perfusion; 6 = begin deep hypothermic circulatory arrest; 7 = begin anterograde cerebral perfusion; 8 = begin rewarming.

channel (Fp1-A1), and a right channel (Fp2-A2). In addition, bifrontal  $rSO_2$  sensors were used for central nervous system monitoring.

Cardiopulmonary bypass was achieved *via* left femoral arterial cannulation and two-stage right atrial cannulation. Systemic hypothermia was initiated to reach a target temperature of 18°C, with crushed ice packs surrounding the head to aid in homogenous cooling. To this point, electroencephalographic activity and  $rSO_2$  values had been bilaterally symmetrical (fig. 1). After approximately 40 min of cardiopulmonary bypass, while the aortic valve was being replaced, profound right hemispheric desaturation occurred abruptly despite a nasopharyngeal temperature of 18°C and an isoelectric electroencephalogram (fig. 1). The surgeon was immediately notified. The aortic valve replacement was temporarily aborted, and hypothermic circulatory arrest was initiated with a subsequent decrease in contralateral  $rSO_2$  values. The aortic arch was opened, and the dissection was visualized. The false lumen was noted to extend from the ascending aorta through the right innominate artery and into the right common carotid artery. The arch was repaired under retrograde cerebral perfusion, during which no improvement in ipsilateral  $rSO_2$  values was noted while the contralateral values continued to decrease. After reinstatement of anterograde cardiopulmonary bypass flow *via* cannulation of the ascending graft,  $rSO_2$  values promptly improved symmetrically (fig. 1).

The total time from right hemispheric cerebral desaturation to restoration of anterograde blood flow with consequent resaturation was approximately 35 min and occurred during deep hypothermia with 22 min of retrograde cerebral perfusion. The aortic valve was replaced, and the remainder of the operation continued without incident. The patient emerged from anesthesia in the intensive care unit without obvious neurologic deficits. He was discharged on the 11th hospital day.

## Discussion

Cerebral oximetry is a relatively new monitoring modality that has undergone much criticism since its advent. Both the confounding contribution of external carotid flow and variations in the ratio of cerebral arterial/venous blood flow have been reported to result in inaccurate absolute  $rSO_2$  values.<sup>2,3</sup> In fact, normal values have been reported in brain-dead patients, presumably because of either the contribution of external carotid flow or because of the decrease in cerebral oxygen consumption.<sup>3</sup> Interpretation of low  $rSO_2$  values remains controversial as well. Using somatosensory evoked potential changes as a control, Beese *et al.*<sup>4</sup> determined no critical threshold value after carotid cross clamping that would reliably indicate the need for shunting. Similarly, Samra *et al.*<sup>5</sup> reported that in a group of awake patients

undergoing carotid endarterectomy, no consistent relative change from baseline  $rSO_2$  values reliably accompanied neurologic changes. In addition, abnormal  $rSO_2$  values with simultaneously normal mean velocity flows—documented by transcranial Doppler insonation of the middle cerebral artery during ipsilateral carotid occlusion—could potentially result in an increased number of unnecessary shunts during carotid surgery.<sup>6</sup> In fact,  $rSO_2$  values have even been reported in a pumpkin species (presumably from pigments present in the pumpkin).<sup>7</sup>

Although absolute values may not be accurately measured, decreasing  $rSO_2$  trends seem to reliably reflect decreasing cerebral hemoglobin oxygen saturation.<sup>8</sup> Significant intraoperative cerebral oxygen desaturations have been related to postoperative cognitive dysfunction as well as prolonged hospital and intensive care unit durations of stay.<sup>9,10</sup> A recent interventional study showed an 80% reduction in the incidence of stroke by optimization of the oxygen supply/demand ratio during bypass to maintain baseline  $rSO_2$  values.<sup>11</sup> Cerebral oximetry has previously been advocated as a helpful neurophysiologic monitor during cases necessitating hypothermic circulatory arrest and retrograde cerebral perfusion to assure optimal brain cooling and bihemispheric delivery of retrograde perfusion. Blas *et al.*<sup>12</sup> recently reported such a case during which  $rSO_2$  monitoring detected suboptimal global retrograde cerebral perfusion due to a loose retrograde cannula suture, which resulted in leakage of perfusate into the right atrium and inferior vena cava.

At our institution, advocates of cerebral oximetry tend to use the device during cardiopulmonary bypass, especially as a trend monitor when the procedure involves retrograde cerebral perfusion to assess the balance of cerebral oxygen supply and demand in much the same fashion that mixed venous oximetry readings from a pulmonary artery catheter can be used to assess global oxygen supply and demand. We apply bilateral sensors to diagnose hemispheric differences that may occur during bypass, including embolic events, aortic cannula malposition, unilateral venous obstruction, or, as in this case, extension of a false lumen into a carotid artery resulting in inadequate hemispheric cerebral blood flow.

Despite uncertainty as to the absolute values that should be cause for alarm, the sudden precipitous and unilateral  $r\text{SO}_2$  decrease prompted sufficient alarm to change the sequence of the surgery. It is our belief that the cerebral oximeter enabled early detection of hemispheric ischemia and prevented what could have been a prolonged ischemic insult if the course of the operation had not been altered.

## References

1. Matsumura JS, Pearce WH, Cabellon A, McCarthy WJ, Yao JS: Reoperative aortic surgery. *Cardiovasc Surg* 1999; 7:614-21
2. Watzman HM, Kurth CD, Montenegro LM, Rome J, Steven JM, Nicolson SC: Arterial and venous contributions to near-infrared cerebral oximetry. *ANESTHESIOLOGY* 2000; 93:947-53
3. Kytta J, Ohman J, Tanskanen P, Randell T: Extracranial contribution to cerebral oximetry in brain dead patients: A report of six cases. *J Neurosurg Anesth* 1999; 11:252-4
4. Beese U, Langer H, Lang W, Dinkel M: Comparison of near-infrared spec-

troscopy and somatosensory evoked potentials for the detection of cerebral ischemia during carotid endarterectomy. *Stroke* 1998; 29:2032-7

5. Samra SK, Dy EA, Welch K, Dorje P, Zelenock GB, Stanley JC: Evaluation of a cerebral oximeter as a monitor of cerebral ischemia during carotid endarterectomy. *ANESTHESIOLOGY* 2000; 93:940-70
6. Grubhofer G, Plochl W, Skolka M, Czerny M, Ehrlich M, Lassnigg A: Comparing Doppler ultrasonography and cerebral oximetry as indicators for shunting in carotid endarterectomy. *Anesth Analg* 2000; 91:1339-44
7. Litscher G, Schwarz G: Transcranial cerebral oximetry: Is it clinically useless at this moment to interpret absolute values obtained by the INVOS 3100 cerebral oximeter? *Biomed Tech* 1997; 42:74-7
8. Pollard V, Prough DS, DeMelo AE, Deyo DJ, Uchida T, Stoddart HF: Validation in volunteers of a near-infrared spectroscope for monitoring brain oxygenation in vivo. *Anesth Analg* 1996; 82:269-77
9. Monk TG, Reno KA, Olsen DC, Koney-Laryea D: Postoperative cognitive dysfunction is associated with cerebral oxygen desaturations (abstract). *ANESTHESIOLOGY* 2000; 93:A167
10. Yao F-SF, Tseng C-C, Braverman JM, Levin SK, Illner P: Cerebral oxygen desaturation is associated with prolonged lengths of stay in the intensive care unit and hospital (abstract). *ANESTHESIOLOGY* 1999; 91:A123
11. Schmahl TM: Operative changes affecting incidence of perioperative stroke using cerebral oximetry and aortic ultrasonography (abstract). *ANESTHESIOLOGY* 2000; 93:A399
12. Blas ML, Lobato EB, Martin T: Noninvasive infrared spectroscopy as a monitor of retrograde cerebral perfusion during deep hypothermia. *J Cardiothorac Vasc Anesth* 1999; 13:244-5

Anesthesiology 2002; 96:1265-6

© 2002 American Society of Anesthesiologists, Inc. Lippincott Williams & Wilkins, Inc.

## Ketamine Combined with Morphine for the Management of Pain in an Opioid Addict

Guy Haller, M.D.,\* Jean-Luc Waeber, M.D.,† Nicoline Kooger Infante, M.D.,‡ François Clergue, M.D.‡

WITH an estimated prevalence of 3-8 problem drug users (mainly heroin) per 1,000 inhabitants in the European Union,<sup>1</sup> it is not unusual to see patients with opioid addictions undergoing elective or emergency surgery. They can sometimes be difficult to treat in the postoperative period because they may have increased pain scores and opioid requirements.<sup>2</sup> Recently, some authors suggested that morphine-induced analgesia could be enhanced by adding low-dose ketamine.<sup>3</sup> We report the successful treatment of an opioid addict patient with this drug combination.

### Case Report

A 26-yr-old woman was admitted for trauma after a suicide attempt. Fractures of several lumbar vertebral bodies, without spinal injury, were diagnosed. The patient had no history of surgery for chronic pain but was known to have chronic substance abuse (heroin and methadone). Spinal fusion at T12-L1 was performed during general anesthesia. As the patient recovered, soon after the operation, she reported intense low-back pain evaluated as 10 out of 10 on a visual analog scale (VAS). During the first 7 hours after the procedure, she received a cumulative intravenous dose of 4 g paracetamol, 0.45 mg clonidine, and, by a patient-con-

trolled analgesia device, 290 mg morphine. She became sedated, with only partial pain relief (VAS, 5 out of 10). During the next 24 h, despite proparacetamol (8 g), clonidine (0.45 mg), and her usual methadone substitution (40 mg), morphine consumption increased to 430 mg/day without any improvement in pain relief (VAS, 5-7 out of 10).

No respiratory depression was observed, but the patient became slightly confused and opened her eyes only to tactile stimulation. A continuous low-dose ketamine regimen was then initiated according to a previously published protocol.<sup>4</sup> Ketamine infusion was started at  $10 \mu\text{g} \cdot \text{kg}^{-1} \cdot \text{min}^{-1}$  and then was progressively reduced by steps of  $2.5 \mu\text{g}$ , over a period of 45 min, to a final dose of  $2.5 \mu\text{g} \cdot \text{kg}^{-1} \cdot \text{min}^{-1}$ . Improvement in pain relief became evident in the hour after the beginning of the infusion (VAS, 2 out of 10), and morphine consumption (patient-controlled analgesia) decreased to 160 mg/day. There were no ketamine-related adverse effects (psychotomimetic effects or impairment in cognitive functioning), and the patient had oriented verbal response and movements to orders. The same ketamine-morphine regimen was used until the fifth postoperative day, with a daily morphine consumption (patient-controlled analgesia) between 120 and 160 mg. The VAS score remained between 2 and 4 out of 10 while the patient was at rest and moving in bed.

On the fifth postoperative day, as she started to move out of bed, she felt intractable pain (VAS, 7-10 out of 10) and did not respond to the usual treatment. A computed tomography scan showed two misplaced screws at the T12-L1 level. They were removed on the same day. After this second operation, a continuous infusion of ketamine at  $2.5 \mu\text{g} \cdot \text{kg}^{-1} \cdot \text{min}^{-1}$  was used for a period of 2 days, combined with oral morphine (on demand), 8 g paracetamol, and 40 mg/day methadone substitution. The patient used 200 mg (equivalent to 66 mg intravenous morphine) the first 48 h and progressively reduced the dose to 150, 60, 50, and 20 mg, respectively. Morphine was then stopped and replaced by 200 mg tramadol and 4 g paracetamol. The VAS pain score remained at 3 out of 10 or below, and no neurologic sequelae were observed. Follow-up was performed by a psychiatrist and our drug addiction support unit, and the patient left the hospital with a substitution treatment of 40 mg/day methadone.

\* Staff Anesthesiologist, † Chief Anesthesiologist, ‡ Professor and Chairman.

Received from the Division of Anesthesiology, Department of Anesthesiology, Pharmacology, Intensive Care of Surgery (APSIC), University Hospitals Geneva, Geneva, Switzerland. Submitted for publication June 18, 2001. Accepted for publication October 31, 2001. Support was provided solely from institutional and/or departmental sources.

Address reprint requests to Dr. Haller: Division of Anesthesiology, Department APSIC, University Hospitals, CH-1211 Geneva 14, Switzerland. Address electronic mail to: Guy.Haller@hcuge.ch. Individual article reprints may be purchased through the Journal Web site, www.anesthesiology.org.

## Discussion

The combination of low-dose ketamine and morphine provides clinicians with an interesting tool to improve pain management in postoperative patients and to reduce opioid-related adverse effects.<sup>5</sup> Our observation illustrates the new potentialities offered by this combination for patients with increased opioid requirements, particularly patients addicted to heroin.

Ketamine interacts as an antagonist-agonist of the  $\mu$  and  $\kappa$  opioid receptors and an agonist of the noradrenergic ( $\alpha_2$ ) and 5-hydroxytryptamine receptors (antinociceptive brain stem and midbrain descending pathways).<sup>6</sup> Ketamine is also a noncompetitive antagonist of the *N*-methyl-D-aspartate receptors.<sup>7</sup> Located in supraspinal and spinal structures, mainly within the substantia gelatinosa of the dorsal horn, *N*-methyl-D-aspartate receptors are a part of the postsynaptic excitatory system (nociceptive neurone). Their activation after repeated C-fiber stimulation results in an important increase of activity of the nociceptive neurone, underlying many forms of central sensitization and hyperalgesia.<sup>8</sup> Repeated or even single opiate administration seems to be able to initiate or enhance the activation of *N*-methyl-D-aspartate receptors in exactly the same way as repeated C-fiber stimulation.<sup>9,10</sup> This results in the reduced potency of the analgesic effects of opiates, defined as tolerance. This may explain the morphine-sparing effect of an *N*-methyl-D-aspartate antagonist, such as ketamine, and its potential benefits in treating a number of painful conditions, such as acute postoperative pain. Ketamine does not only prevent the development of tolerance, but it can also reverse systematically induced morphine tolerance and restore morphine effectiveness.<sup>11</sup> This latter point is particularly interesting in opioid addict patients who differ from usual postoperative patients by

their high preoperative tolerance to opiate analgesia and their potential risk for development of tolerance-associated hyperalgesia.

As pain relief increases, morphine requirements are reduced (from 430 mg to 160 mg in our case), as are the incidence of drug-related adverse side effects. Therefore, we recommend considering the use of low-dose ketamine associated with morphine in patients with a detrimental shift of the dose-response curve for morphine.

The authors thank Martin Tramer, M.D., D.Phil. (Chief Anesthesiologist, Department APSIC, University Hospitals Geneva, Geneva, Switzerland), for his advice.

## References

1. European Monitoring Center for Drugs and Drug Addiction: Extended annual report on the state of the drugs problem in the European Union. Luxembourg, Office for Official Publications of the European Communities, 2000
2. Rapp SE, Ready LB, Nessly ML: Acute pain management in patients with prior opioid consumption: A case-controlled retrospective review. *Pain* 1995; 61:195-201
3. Suzuki M, Tsueda K, Lansing PS, Tolan MM, Fuhrman TM, Ignacio CI, Sheppard RA: Small-dose ketamine enhances morphine-induced analgesia after outpatient surgery. *Anesth Analg* 1999; 89:98-103
4. Adriaenssens G, Vermeyen KM, Hoffmann VLH, Mertens E, Adriaensen HF: Postoperative analgesia with i.v. patient-controlled morphine: Effect of adding ketamine. *Br J Anaesth* 1999; 83:393-6
5. Schmid RL, Sandler AN, Katz J: Use and efficacy of low dose ketamine in the management of acute postoperative pain. *Pain* 1999; 82:111-25
6. Hirota K, Lambert DG: Ketamine: Its mechanism(s) of action and unusual clinical use (editorial). *Br J Anaesth* 1996; 77:441-4
7. Rogawski MA: Therapeutic potential of excitatory amino acid antagonists: Channel blockers and 2,3-benzodiazepines. *Trends Pharmacol Sci* 1993; 14: 325-31
8. Dickenson AH: Spinal cord pharmacology of pain. *Br J Anaesth* 1995; 75:193-200
9. Mao J, Price DD, Mayer DJ: Mechanisms of hyperalgesia and morphine tolerance: A current view of their possible interactions. *Pain* 1995; 62:259-74
10. Larcher A, Laulin JP, Celerier E, Le Moal M, Simonet G: Acute tolerance associated with a single opiate administration: Involvement of *N*-methyl-D-aspartate-dependant pain facilitatory systems. *Neuroscience* 1998; 84:583-9
11. Schimoyama N, Schimoyama M, Inturrisi CE, Elliott KJ: Ketamine attenuates and reverses morphine tolerance in rodents. *ANESTHESIOLOGY* 1996; 85:1357-66

Anesthesiology 2002; 96:1266-8

© 2002 American Society of Anesthesiologists, Inc. Lippincott Williams & Wilkins, Inc.

## Potential Disaster in Airway Management: A Misguided Airway Exchange Catheter *via* a Hole Bitten into a Univent Endotracheal Tube

John H. Eisenach, M.D.,\* Roxann D. Barnes, M.D.†

PATIENTS requiring prolonged mechanical ventilation may need replacement of an endotracheal tube (ETT) for various reasons, including a cuff leak or a tube laceration.

A common technique used is to change the ETT over a semirigid tube exchanger, also known as a bougie, or an airway exchange catheter (AEC).<sup>1</sup> One problem with this technique is that it is difficult to confirm quickly and confidently the correct placement of the tube exchanger. If the old ETT is removed over a misplaced tube exchanger, airway control is threatened.

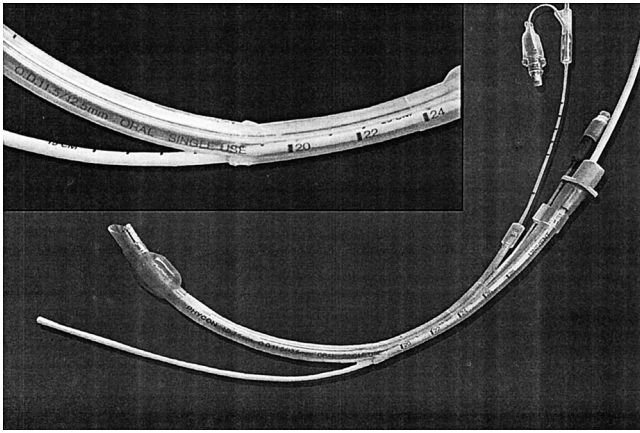
\* Anesthesiology Resident, † Assistant Professor.

Received from the Mayo Graduate School of Medicine, Department of Anesthesiology, Mayo Clinic and Foundation, Rochester, Minnesota. Submitted for publication July 18, 2001. Accepted for publication October 31, 2001. Supported in part by the Mayo Foundation, Rochester, Minnesota.

Address reprint requests to Dr. Barnes: Department of Anesthesiology, Mayo Clinic/Mayo Foundation, 200 First Street Southwest, Rochester, Minnesota 55905. Address electronic mail to: barnes.roxann@mayo.edu. Individual article reprints may be purchased through the Journal Web site, www.anesthesiology.org.

### Case Report

The anesthesia team was called to examine a 69-yr-old woman who remained intubated in the cardiac surgical intensive care unit 2 days



**Fig. 1.** An airway exchange catheter inadvertently exiting from a bitten hole in the convex wall of a Univent endotracheal tube during endotracheal tube exchange. This led to loss of airway control in a sedated, paralyzed patient.

after thoracoabdominal aortic aneurysm repair. A 7.5-mm Univent endotracheal tube (Fuji Systems, Tokyo, Japan) had been placed intraoperatively under direct laryngoscopy with “moderate” difficulty. The patient required postoperative mechanical ventilation secondary to slow neurologic recovery. She was sedated with continuous intravenous propofol. Muscle relaxants were not used. An oral bite block had not been placed, and the patient would occasionally bite the ETT. The respiratory therapist expressed concern about a cuff leak. Before our arrival, worsening arterial oxygen saturation had developed in the patient, and there was a discrepancy between inspiratory and expiratory tidal volumes. We performed fiberoptic bronchoscopy to confirm proper ETT placement and absence of mucous plugging. Attempts at reinflating the ETT cuff to prevent continued volume loss were unsuccessful. We elected to change the Univent tube to a standard single-lumen ETT. After bag-valve ventilation increased oxygen saturation measured by pulse oximetry ( $\text{SpO}_2$ ) to 100%, intravenous boluses of propofol and succinylcholine were administered. An 83-cm-long airway exchange catheter (Cook Critical Care, Bloomington, IN) was advanced with minor resistance. The Univent tube was withdrawn over the AEC until discovery of the exchange catheter exiting from a tear in the convex wall of the Univent tube at approximately 19 cm from the distal end (fig. 1). The ETT laceration had not been noted at the time of fiberoptic bronchoscopy. Because of the uncertainty of the location of the AEC, both the catheter and the Univent tube were withdrawn. Direct laryngoscopy was immediately performed, followed by successful oral tracheal intubation. Oxygenation and ventilatory parameters improved.

## Discussion

Anesthesiologists are frequently called on to perform endotracheal tube replacement. With this procedure, there is significant risk of losing control of the airway. Two separate but interrelated airway management issues are raised by this case report. The first issue is the patient biting the tube, which led to a complication. The second is that there was a failure of the AEC system.

There are numerous reports in the literature of complications related to ETTs being damaged by biting.<sup>2,3</sup> These complications are separated into tube occlusion and tube laceration. Occluded tubes may lead to acute hypoxemia and hypoventilation, and negative-pressure

pulmonary edema. Lacerated tubes can also lead to hypoxemia and hypoventilation, plus aspiration and inability to suction the trachea for secretions. Intraoral separation might be the most devastating, as in one case report of a 4-yr-old girl who bit the ETT after emergence from anesthesia; on extubation, the distal portion of the ETT remained below the glottis, causing airway obstruction.<sup>2</sup> Particular to this situation are reports of the Univent tube being easily damaged.<sup>4</sup>

To prevent biting the ETT, many authors advocate using some apparatus, such as an oropharyngeal airway, oral bite block, or roll of gauze in the mouth.<sup>5,6</sup> However, these techniques are not foolproof because oral airways can soften and fail to prevent biting.<sup>7</sup> Furthermore, oral airways compete with endotracheal tubes for a central position in the mouth, which can lead to dislodgment, pressure sores, or lip, tongue, and tooth trauma.<sup>8,9</sup> Gauze packs are less traumatic but must be placed securely in the molars and packed with enough gauze to ensure a bite block effect.<sup>5</sup>

The second issue raised is that as a result of the biting, the tube exchange system failed. Different methods to exchange ETTs have been used in the past. Initially, ETT exchangers were urethral or suction catheters, nasogastric tubes, or stylets.<sup>10-12</sup> Creative mechanisms have been constructed to facilitate exchange from a double- to a single-lumen ETT.<sup>13</sup> An AEC is a hollow, semirigid catheter that can be used to intubate, change endotracheal tubes, provide oxygen insufflation and jet ventilation, or be left *in situ* for “trial” extubation.<sup>1,14,15</sup> However, these are not without risk because complications include the following: (1) misplacement, (2) tracheobronchial trauma or lung laceration, (3) jet ventilation-associated barotrauma and pneumothorax, and (4) laryngeal or vocal cord trauma from a new ETT “hanging up” during exchange.<sup>16-19</sup>

In summary, biting of ETTs in nonparalyzed and sedated or lightly anesthetized patients is a potential problem and can lead to numerous complications if not recognized. Also, airway exchange catheters, although useful, are not foolproof, and misuse may be harmful. Potentially, combining AECs and fiberoptic bronchoscopy may prove to be the best method for safe endotracheal tube exchange. Anesthesiologists are reminded that they must have an algorithm available for extubation as well as intubation of the difficult airway.<sup>20</sup>

## References

1. Cooper RM: Extubation and changing endotracheal tubes, *Airway Management: Principles and Practice*. Edited by Benumof J. St. Louis, Mosby-Yearbook, 1996, pp 874-85
2. Rodriguez R, Gonzalez H, Carranza A: Intraoral separation of a reinforced endotracheal tube (letter). *ANESTHESIOLOGY* 2000; 93:908-9
3. Hoffmann CO, Swanson GA: Oral reinforced endotracheal tube crushed and perforated from biting (letter). *Anesth Analg* 1989; 69:552-3
4. Doi Y, Uda R, Akatsuka M, Tanaka Y, Kishida H, Mori H: Damaged Univent® tubes. *Anesth Analg* 1998; 87:732-3
5. Negus B: Gauze bite block (letter). *Anaesth Intensive Care* 1997; 25:589
6. Kwan KM, Kok P, Koay CK: Prevention of tube occlusion caused by biting:

Oral bite block versus oropharyngeal airway (letter). *Anaesth Intensive Care* 2000; 28:227-30

7. King HK, Lewis K: Guedel oropharyngeal airway does not prevent patient biting on the endotracheal tube (letter). *Anaesth Intensive Care* 1996; 24:729-30

8. Kandasamy R, Sivalingam P: Endotracheal tube damage in the presence of bite block (letter). *ANESTHESIOLOGY* 1999; 90:637

9. Alkire MT: Ventilatory compromise secondary to occlusion of an endotracheal tube's balloon air channel by a malpositioned bite block (letter). *ANESTHESIOLOGY* 1998; 88:1419

10. Finucane BT, Kupshik HL: A flexible stilette for replacing damaged tracheal tubes. *Can Anaesth Soc J* 1978; 25:153-4

11. Desai SP, Fencel V: A safe technique for changing endotracheal tubes. (letter). *ANESTHESIOLOGY* 1980; 53:267

12. Cherian MN, Mathews MP: Use of a J-wire cover as an endotracheal tube changer. *J Clin Anesth* 1997; 9:586-588

13. Griffin PR, Mitchell MR, Viswanathan S, Riopelle JM, Campbell CE, Karpan DJ: Use of plastic rod/sleeve combination to facilitate double- to single-lumen

tracheal tube exchange in patients with difficult glottic visualization (letter). *Anesth. Analg* 1998; 87:744

14. Millen JE, Glauser FL: A rapid, simple technique for changing endotracheal tubes. *Anesth Analg* 1978; 57:735-6

15. Cooper RM: The use of an endotracheal ventilation catheter in the management of difficult extubations. *Can J Anaesth* 1996; 43:90-3

16. Benumof JL: Additional safety measures when changing endotracheal tubes (letter). *ANESTHESIOLOGY* 1991; 75:921-2

17. deLima LGR, Bishop MJ: Lung laceration after tracheal extubation over a plastic tube changer. *Anesth Analg* 1991; 73:350-1

18. Baraka AS: Tension pneumothorax complicating jet ventilation *via* a Cook airway exchange catheter. *ANESTHESIOLOGY* 1999; 91:557-8

19. Seitz PA, Gravenstein N: Endobronchial rupture from endotracheal re-intubation with an endotracheal tube guide. *J Clin Anesth* 1989; 1:214-7

20. Caplan RA, Benumof JL, Berry FA, Blitt CD, Bode RH, Cheney FW, Connors RT, Guidry OF, Ovassapian A: Practice guidelines for management of the difficult airway: A report by the American Society of Anesthesiologists Task Force on Management of the Difficult Airway. *ANESTHESIOLOGY* 1993; 78:597-602

*Anesthesiology* 2002; 96:1268-70

© 2002 American Society of Anesthesiologists, Inc. Lippincott Williams & Wilkins, Inc.

## Mitochondrial Defects and Anesthetic Sensitivity

Phil G. Morgan, M.D.,\* Charles L. Hoppel, M.D.,† Margaret M. Sedensky, M.D.\*

MITOCHONDRIA are the principal source of cellular energy metabolism. The cellular machinery necessary for the Krebs cycle, fatty acid oxidation, and, most importantly, oxidative phosphorylation, reside within mitochondria. Mutations in mitochondrial proteins cause striking clinical features in the two tissues types requiring the most energy, muscle and nerve. These features include myopathies, cardiomyopathies, encephalopathies, seizures, and cerebellar ataxia. It is increasingly common for children with documented mitochondrial disease to undergo surgery. Often, a muscle biopsy is required for diagnosis, but a wide array of surgical procedures is possible. Such procedures usually involve a general anesthetic for these young children. Although many different anesthetic techniques have been used successfully for patients with mitochondrial disease,<sup>1,2</sup> there are reports of serious complications occurring during and after anesthetic exposure.<sup>3,4</sup> As a result, there is a general belief among anesthesiologists that these patients are at increased risk from the stress of surgery and anesthesia.<sup>5</sup>

Mitochondrial dysfunction most commonly affects function of the nervous system and of the muscular system. Because volatile anesthetics exert much of their

effects through these same tissues, it is possible that patients with mitochondrial disease may have an abnormal sensitivity to volatile anesthetics. General anesthetics have their main clinical effect in tissues such as brain and heart, tissues that are highly dependent on oxidative metabolism. General anesthetics have been shown to depress oxidative phosphorylation in cell-free studies of isolated mitochondria.<sup>6,7</sup> These reports indicate that anesthetics depress mitochondria only at concentrations higher than those used clinically. However, even at doses commonly used in the operating room, general anesthetics may cause significant depression of mitochondria in normal patients.<sup>8</sup> An investigation in a model organism has also shown that a mutation in a mitochondrial protein leads to increased sensitivity to volatile anesthetics.<sup>9</sup>

To limit the anesthetic dose for surgery to only that absolutely necessary for patients with mitochondrial disease, we have been using a Bispectral Index<sup>®</sup> monitor (BIS<sup>®</sup>; Aspect Medical Systems, Inc., Newton, MA) during surgery for patients with putative mitochondrial disorders. We induced anesthesia in 16 children who had tentative diagnoses of mitochondrial disease and who presented to our operating room for general anesthesia. Most of the scheduled procedures were skeletal muscle biopsies to assess oxidative phosphorylation and electron transport. We report herein our observations of BIS values noted during routine induction of these 16 children with mitochondrial myopathies. The sensitivities of the patients to sevoflurane were related to their diagnoses of mitochondrial function.

### Case Reports

Institutional Review Board approval was provided by the University Hospitals of Cleveland. We induced anesthesia in 16 children under-

\* Professor, Departments of Anesthesiology and Genetics, University Hospitals and Case Western Reserve University, Cleveland, Ohio. † Professor, Departments of Pharmacology and Medicine, Louis Stokes Department of Veterans Affairs Medical Center, Case Western Reserve University, Cleveland, Ohio.

Received from the Department of Anesthesiology, University Hospitals, Cleveland, Ohio. Submitted for publication July 13, 2001. Accepted for publication November 12, 2001. Supported by the Department of Anesthesiology, University Hospitals, Cleveland, Ohio, and the Department of Medicine, Department of Veterans Affairs Medical Center, Cleveland, Ohio. Reference to this work was made at the annual meeting of the Association of University Anesthesiologists, Rochester, New York, May 18, 2001.

Address reprint requests to Dr. Morgan: Department of Anesthesiology, 2400 Bolwell Building, University Hospitals, 11100 Euclid Avenue, Cleveland, Ohio 44106. Address electronic mail to: philip.morgan@uhhs.com. Individual article reprints may be purchased through the Journal Web site, www.anesthesiology.org.



**Table 1. Sensitivity of 16 Children with Mitochondrial Defects to Sevoflurane**

| Patient No. | Age (yr) | Procedure                   | % Sevoflurane (BIS = 60) | Diagnosis                            |
|-------------|----------|-----------------------------|--------------------------|--------------------------------------|
| 1           | 1        | Skin biopsy, line placement | 0.4                      | <b>Leigh disease</b>                 |
| 2           | 3        | Herniorrhaphy               | 3.0                      | Complex III                          |
| 3           | 5        | Herniorrhaphy               | 3.1                      | Complex III                          |
| 4           | 1        | Muscle biopsy               | <b>0.8</b>               | <b>Complex I</b>                     |
| 5           | 2        | Muscle biopsy               | 3.1                      | No complex identified                |
| 6           | 5        | Muscle biopsy               | 3.2                      | Complex III                          |
| 7           | 1        | Muscle biopsy               | 3.5                      | No complex identified                |
| 8           | 3        | Muscle biopsy               | 4.0                      | No complex identified                |
| 9           | 2        | Muscle biopsy               | 3.2                      | No complex identified                |
| 10          | 1        | Muscle biopsy               | 2.9                      | No complex identified                |
| 11          | 2        | Muscle biopsy               | 3.4                      | No complex identified                |
| 12          | 1        | Muscle biopsy               | <b>1.6</b>               | <b>Decreased pyruvate oxidation</b>  |
| 13          | 4        | Muscle biopsy               | <b>1.0</b>               | <b>Decreased glutamate oxidation</b> |
| 14          | 2        | Muscle biopsy               | 3.1                      | Complex III                          |
| 15          | 10       | Muscle biopsy               | 3.5                      | Complex III                          |
| 16          | 5        | Muscle biopsy               | 3.0                      | Complex III                          |

BIS = Bispectral Index.

going surgery for treatment relating to or diagnosis of defects in mitochondrial function. These patients were receiving their normal care and were not part of a prospective study. Preoperatively, all children had clinical findings consistent with mitochondrial disease. Their symptoms included hypotonia, developmental delay, failure to thrive, and lactic acidosis. In most cases, the surgeries were for muscle biopsies to determine the specific aspect of mitochondrial function, which was affected. Because patients with mitochondrial dysfunction are believed to be at increased risk during anesthesia,<sup>5</sup> we elected to induce anesthesia in these patients slowly using a BIS® monitor to indicate their depth of anesthesia. No preoperative sedation was given, and sevoflurane (in 100% oxygen) was the sole agent for induction of anesthesia in all cases. All inductions were performed by the same anesthesiologist (P. G. M.) using a tight-fitting mask with continuous monitoring of end-tidal gas concentrations. During induction, inspired sevoflurane was slowly increased by 0.5% every 2 min until a BIS value of 60 or less was reached. Inspired sevoflurane was increased only after end-tidal concentration of sevoflurane was constant for at least 1 min. Each induction (except in the patients requiring very low doses of sevoflurane) took approximately 10 min. When a patient reached a BIS value of 60, loss of consciousness was confirmed by lack of response to voice and by loss of eyelash reflexes. This approach was not intended to reach a true steady state, but to approximate one; we did not alter the induction to a great degree from normal, and we did not subject these patients to an unusual practice. When a BIS value of 60 or less was reached, nitrous oxide (70%) and 1–2 µg/kg fentanyl were added, and the surgeons prepared the patient and proceeded with the case. Maintenance of anesthesia for surgery was conducted using sevoflurane, nitrous oxide, and fentanyl when indicated. Local analgesia with lidocaine at the surgical site was used in all cases. Maintenance, emergence, and recovery from anesthesia were normal in all cases.

In each patient, mitochondrial function was evaluated *via* assays of oxidative phosphorylation and electron transport. Oxidative phosphorylation was evaluated by supplying the isolated mitochondria with substrates specific for each complex of the electron transport chain.<sup>10</sup> For example, glutamate and pyruvate plus malate were used to evaluate complex I, whereas succinate was used to evaluate complex II. Oxidative phosphorylation was measured using the rate of oxygen uptake in the presence and absence of adenosine diphosphate with the

specific substrates. Failure to oxidize with use of a particular substrate was indicative of a problem with the associated complex or an enzyme or complex interacting with the associated complex.

Electron transport chain enzymes were evaluated by solubilizing the mitochondria. When solubilized, the enzyme complexes were evaluated by their ability to accept electrons from electron donors specific for the isolated complexes and enzymes and transfer them to specific electron acceptors.<sup>10</sup> These studies and the oxidative phosphorylation studies were part of the planned care for all of these patients and were performed in the laboratory of Dr. Charles Hoppel (Professor, Department of Pharmacology and Medicine, Case Western Reserve University, Cleveland, Ohio).

No specific defects in oxidative phosphorylation were found in six children. Six other patients were diagnosed with complex III dysfunction. Three patients had mitochondrial defects associated with complex I function. The remaining child had morphologic and metabolic features of Leigh disease but was not tested for complex I function. Remarkably, these last four patients required a very low dose of sevoflurane to reach an anesthetic depth (BIS value of 60) associated with loss of consciousness (table 1).

## Discussion

The oxidative phosphorylation pathway consists of five protein complexes (I–V). Complexes I and II independently transfer electrons to coenzyme Q and then sequentially to complexes III, IV, and V. In isolated mitochondria, complex I is capable of using several carbon sources as fuel, among them pyruvate (when coupled with malate) and glutamate. Complex II is restricted to the use of succinate as an energy source. The remaining complexes can also be independently analyzed with specific electron donors. The constellation of presenting symptoms in these patients did not distinguish their underlying defect in these complexes (table 1).

Surprisingly, four patients required very low doses of sevoflurane to reach a BIS value of 60. Each of these patients had changes that potentially involve the function of complex I, the first complex of the electron transport chain. Our observations are consistent with reports of the effects of volatile anesthetics on *in vitro* assays of mitochondrial function. These studies showed that complex I was the most sensitive of any step in oxidative phosphorylation to inhibition by volatile anesthetics.<sup>6,7</sup> However, the *in vitro* changes were relatively modest, even on exposure of mitochondria to large doses of volatile anesthetics. What is striking to us is that these observations in humans match those seen in a simple animal model, *Caenorhabditis elegans*. In this animal, a nematode, a defect in complex I function reduces the EC<sub>50</sub> of volatile anesthetics to approximately one fifth that of wild type. A defect in complex II function had no effect on anesthetic sensitivity in *C. elegans*. With either defect, the animals move normally but are short-lived and very sensitive to hyperoxia.<sup>3</sup>

It is important to note that the end point measured herein does not correspond to the classic minimum anesthetic concentration (MAC) end point of immobility

to a painful stimulus, nor do the values represent equilibrium values or EC<sub>50</sub>s for sevoflurane concentrations. Determining such an end point in these patients would increase difficult ethical questions and necessitate altering the induction. However, the current end point used was determined during a normal anesthetic induction and only required proceeding somewhat slower than usual to obtain an end-tidal sevoflurane concentration that was not changing quickly. Such an approach may represent a method for approximating anesthetic sensitivity during pilot studies without exposure of patients to increased risk or discomfort. We did not obtain these data during a prospective study. Therefore, we do not have matched controls of patients without mitochondrial disease. However, we have induced anesthesia in more than 25 presumably healthy children of the same age range by the same method and found that a typical value of 3–3.5% sevoflurane is needed to reach a BIS value of 60.

Because mitochondria provide most of the energy used by mammalian cells, it is possible that anesthetics affect patients with mitochondrial disease by causing decreased energy supplies. Because the central nervous system has a high demand for energy, changes in level of consciousness might be highly susceptible to anesthetics in patients with mitochondrial dysfunction. Complex I is the primary entry point for electrons into the electron transport chain in normal mitochondria, so changes affecting complex I may intensely affect central nervous system metabolism. However, the profound hypersensitivity of a subset of patients with mitochondrial disease to volatile anesthetics was unexpected, even in light of

our studies with a model organism. If this observation can be corroborated in a large study, it would represent a change in sensitivity to volatile anesthetics in humans due to a well-characterized genetic defect. The mechanisms of action of volatile anesthetics are not yet known; alterations in anesthetic sensitivity may indicate important molecular species involved in anesthetic action. These findings also indicate that patients with mitochondrial disease resulting from a variety of molecular changes are varied in their response to anesthetics and possibly in their risk during surgery.

## References

1. Kitoh T, Mizuno K, Otogiri T, Ichinose A, Sasao J, Goto H: Anesthetic management for a patient with Kearns-Sayre syndrome. *Anesth Analg* 1995; 80:1240–2
2. Cheam EWS, Critchley LAH: Anesthesia for a child with complex I respiratory chain enzyme deficiency. *J Clin Anesth* 1998; 10:524–7
3. Casta A, Quackenbush EJ, Houck CS, Korson MS: Perioperative white matter degeneration and death in a patient with a defect in mitochondrial oxidative phosphorylation. *ANESTHESIOLOGY* 1997; 87:420–5
4. Grattan-Smith PJ, Shield LK, Hopkins IJ, Collins KJ: Acute respiratory failure precipitated by general anaesthesia in Leigh's syndrome. *J Child Neurol* 1990; 5:137–41
5. Wallace JJ, Perndt H, Skinner M: Anaesthesia and mitochondrial disease. *Paed Anaesth* 1998; 8:249–54
6. Cohen PJ: Effects of anesthetics on mitochondrial function. *ANESTHESIOLOGY* 1973; 39:153–64
7. Harris RA, Munroe J, Farmer B, Kim KC, Jenkins P: Action of halothane upon mitochondrial respiration. *Arch Biochem Biophys* 1971; 142:435–44
8. Miro O, Barrientos A, Alonso JR, Casademont J, Jarreta D, Urbano-Marquez A, Cardellach F: Effects of general anaesthetic procedures on mitochondrial function of human skeletal muscle. *Eur J Clin Pharmacol* 1999; 55:35–41
9. Kayser E-B, Morgan PG, Sedensky MM: GAS-1: A mitochondrial protein controls sensitivity to volatile anesthetics in *C. elegans*. *ANESTHESIOLOGY* 1999; 90:545–54
10. Hoppel CL, Kerner J, Turkaly P, Turkaly J, Tandler B: The malonyl-CoA sensitive form of carnitine palmitoyltransferase is not localized exclusively in the outer membrane of rat liver mitochondria. *J Biol Chem* 1998; 273:23495–503

Anesthesiology 2002; 96:1270–2

© 2002 American Society of Anesthesiologists, Inc. Lippincott Williams & Wilkins, Inc.

## Febrile Reaction to Subarachnoid Baclofen Administration

Shyh-Shiun Wu, M.D.,\* Kevin A. Dolan, M.D.,† F. Michael Ferrante, M.D.‡

CONTINUOUS subarachnoid administration of baclofen is a major advance in the treatment of spasticity for patients refractory to more conservative therapy, or for patients with intolerable side effects of such therapy.<sup>1–3</sup> Baclofen is a specific  $\gamma$ -aminobutyric acid receptor (type

B) agonist. Its therapeutic effects are due to presynaptic inhibition of monosynaptic and polysynaptic spinal reflexes *via* blockade of neurotransmitter release from afferent terminals.<sup>4–6</sup>

Before implantation of the subarachnoid catheter and pump for baclofen infusion, the drug is customarily first administered by bolus injection *via* lumbar puncture as a trial to determine therapeutic efficacy.<sup>1–3</sup> In premarketing and postmarketing clinical trials of Lioresal® Intrathecal (baclofen for injection; Medtronic, Minneapolis, MN), fever was observed to occur as an adverse event in 3 of 576 patients (0.5%) during trial screening and in 1 of 474 patients (0.2%) during the 2-month period after delivery system implant.<sup>7</sup> However, these were uncontrolled trials in which many of the observed events were known to occur in association with patients' underlying

\* Fellow, Pain Medicine Center, † Clinical Professor of Anesthesiology, Department of Anesthesiology, Hospital of the University of Pennsylvania, University of Pennsylvania School of Medicine. ‡ Professor of Clinical Anesthesiology, Department of Anesthesiology, University of California, Los Angeles.

Received from the Pain Medicine Center, Department of Anesthesiology, Hospital of the University of Pennsylvania, Philadelphia, Pennsylvania, and the Pain Medicine Center, Department of Anesthesiology, University of California, Los Angeles, California. Submitted for publication July 31, 2001. Accepted for publication November 19, 2001. Support was provided solely from institutional and/or departmental sources.

Address reprint requests to Dr. Ferrante: Pain Medicine Center, 200 Medical Plaza, Suite 660, Los Angeles, California 90095-6954. Address electronic mail to: sdiacz@mednet.ucla.edu. Individual article reprints may be purchased through the Journal Web site, www.anesthesiology.org.

primary medical conditions. There are no published reports of fever directly caused by subarachnoid baclofen administration.

We present a case report suggesting a direct causal link between subarachnoid baclofen administration and the genesis of fever, during trial and after delivery system implantation.

### Case Report

A 33-yr-old woman underwent thoracoscopic-assisted T6-T7 discectomy and fusion with autologous rib bone grafting in February, 1998. Postoperatively, retropulsion of the bone graft resulted in spinal cord compression. Surgical reexploration was performed, and the bone graft was removed, but she continued to show signs of myelopathy with a gait disturbance. Magnetic resonance imaging showed syringomyelia extending from T5 to T7 in the spinal cord, and in August 1999, a T5-T6 laminectomy was performed for drainage of the syrinx. Unfortunately, her symptoms persisted after the third surgery. Subsequent imaging studies showed adequate decompression of the syrinx but also myelomalacia in the left lateral portion of the cord.

The patient presented to the Pain Medicine Center with findings reminiscent of a Brown-Sequard syndrome. There was loss of pain and temperature sensation below the T6 dermatome on the right with spasticity and subjective weakness in the left lower extremity. She also reported a burning dysesthesia below T6 on the left, refractory to multiple medications. Attempts to treat her spasticity with oral medications (including diazepam, baclofen, and tizanidine) resulted in excessive negative effects.

The patient was admitted for an inpatient trial of subarachnoid baclofen administration during which she received a single bolus dose of 50  $\mu\text{g}$  baclofen *via* lumbar puncture. This dosage resulted in complete resolution of her spasticity for nearly 24 h. However, a fever developed immediately with a maximum temperature of 39.0°C (measured orally) within 2 h of injection. No source of fever was determined. The patient experienced flu-like symptoms, and a child was concurrently at home with the flu. An allergist concluded that the fever might represent an idiosyncratic reaction to the subarachnoid injection of baclofen, although flu was more likely. If the origin of the fever was indeed related to baclofen, it was hypothesized that the fever was unlikely to recur with slow, gradual, continuous dosing (as delivered *via* a pump) in lieu of a single "large" bolus. Moreover, her response to subarachnoid administration of baclofen was substantive, and the potential for improved quality of life was significant. She also underwent a successful, separate, outpatient trial of spinal cord stimulation as treatment for her dysesthesia.

Combined implantation of an InDura<sup>®</sup> intraspinal catheter with SynchroMed<sup>®</sup> EL pump and a Pisces Quad<sup>®</sup> epidural neurostimulator lead with Itrel<sup>®</sup> 3 implantable pulse generator (Medtronic) was subsequently performed at a single operation. The SynchroMed<sup>®</sup> pump was filled with 500  $\mu\text{g}/\text{ml}$  baclofen before implantation. It was programmed to deliver a single, calculated bolus of 232  $\mu\text{g}$  (to fill the total catheter and pump tubing volume of 0.46 ml) and to run thereafter in a simple continuous infusion mode at a rate of 2.08  $\mu\text{g}/\text{h}$  (50  $\mu\text{g}/24$  h). Twelve hours later, the patient's temperature suddenly spiked to 40.4°C. She also reported bilateral lower extremity weakness. The subarachnoid baclofen infusion was immediately stopped, and a full workup for the source of the fever was initiated. Within several hours, she had defervesced, and her lower extremity strength had improved significantly.

By the next morning, her neurologic examination results had returned to baseline, and another attempt was made to restart the subarachnoid baclofen infusion. The baclofen was removed from the pump reservoir and replaced with a lower concentration of 250  $\mu\text{g}/\text{ml}$ .

The side port of the pump was aspirated to remove the concentrated baclofen solution (500  $\mu\text{g}/\text{ml}$ ) from the catheter and to replace it with cerebrospinal fluid (CSF). The pump was programmed to deliver a bolus of 116  $\mu\text{g}$  over 21 min to refill the catheter volume with baclofen. (Because the internal pump tubing has a volume of 0.26 ml that still contained 500  $\mu\text{g}/\text{ml}$  baclofen, the patient actually received a subarachnoid bolus of 14  $\mu\text{g}$ . Customarily, a "bridging bolus" is performed to correct for the internal pump tubing, so only the length of the catheter is refilled [without administration of a bolus] before initiation of the infusion. In this situation, it would have required 221 h to complete.) A simple continuous infusion was programmed to run at a rate of 1.04  $\mu\text{g}/\text{h}$  (25  $\mu\text{g}/24$  h). Two hours after the infusion was begun, lower extremity weakness and fever with a maximum temperature of 38.8°C again developed in the patient. The infusion was stopped, and the patient rapidly defervesced and regained lower extremity spasticity.

During her hospital stay, the patient's leukocyte count remained within the normal range, varying from 6,000 to 10,100/ $\mu\text{l}$ , with a normal differential. Erythrocyte sedimentation rate obtained on the third postoperative day was increased at 57 mm/h. No infectious source for the fever could be identified. Mammography and abdominopelvic computed tomography revealed no evidence of malignancy. CA-125 tumor marker was negative. Chest radiography and subsequent computed tomography showed bilateral hilar adenopathy. Skin testing revealed anergy. Angiotensin-converting enzyme concentrations were increased, and sarcoidosis was thought to be the likely etiology of the radiographic findings. Definitive histologic diagnosis was made by bronchoscopy after discharge from the hospital.

The subarachnoid baclofen infusion was halted from postoperative day 3 through postoperative day 6 during diagnostic evaluation of the lymphadenopathy. During this period, the patient remained afebrile, with a maximum temperature of 37.8°C. On postoperative day 7, another attempt was made to restart the subarachnoid baclofen infusion at a rate of 1.04  $\mu\text{g}/\text{h}$  (25  $\mu\text{g}/24$  h). A fever to 38.5°C developed 7 h after the start of the infusion, and the infusion was again halted. The patient was afebrile overnight and was discharged to home the next morning.

Fourteen months after implantation, the patient continued to have significant relief of her dysesthesia with spinal cord stimulation. Subarachnoid administration of baclofen was never resumed.

### Discussion

Fever or hyperthermia has been described to occur as a result of withdrawal from intrathecal baclofen.<sup>8,9</sup> Several cases have been reported of a syndrome resembling malignant hyperthermia or neuroleptic malignant syndrome. The manifestations of baclofen withdrawal syndrome include severe spasticity, high fever, hypotension, mental status changes, and rhabdomyolysis.<sup>8,9</sup>

There have been no previous published case reports of hyperthermia occurring in association with the administration of subarachnoid baclofen by bolus or continuous infusion. On four separate occasions, fever with maximum temperatures ranging from 38.5 to 40.4°C consistently developed in this patient after administration of subarachnoid baclofen by bolus injection or continuous infusion, thereby suggesting causation.

Baclofen has been reported to cause marked increases of body temperature in the rat when injected directly into the cerebral ventricles.<sup>10,11</sup> If such thermoregulatory physiology was operant in this patient, a potential

mechanism underlying the genesis of fever could be the spread of baclofen within the CSF to higher rostral centers. Longitudinal spread along the neuraxis after drug administration is dependent on (1) diffusion into nervous tissue, (2) uptake into blood vessels (both are facilitated by enhanced lipid solubility), and (3) CSF bulk flow. Baclofen is hydrophilic, allowing greater distribution along the neuraxis *via* rostral CSF bulk flow.

There was a delay in the onset of fever associated with all baclofen infusions. The onset of fever in each case corresponds with the time required for a hydrophilic agent to reach the ventricular systems *via* CSF bulk flow (3–12 h).<sup>12,13</sup> The second febrile episode was associated with a 14- $\mu$ g subarachnoid bolus of baclofen, which may explain the hastened onset of fever (2 h). The rapid injection (seconds) of a “large” bolus dose (50  $\mu$ g) at time of trial may have facilitated both longitudinal spread within the neuraxis and systemic uptake, explaining the rapid onset of fever. There is no known association between baclofen and sarcoidosis with respect to the genesis of fever.

The decision to proceed with implantation was obfuscated by the patient’s flu-like symptoms at the time of trial and the reassurance of the allergy consultation. In the case of fever with undetermined etiology at the time of trial screening in an otherwise healthy individual, it may be wise to repeat the trial with percutaneous subarachnoid catheterization in lieu of bolus injection. Incremental stepped infusions of baclofen may be administered at 12-h intervals (*i.e.*, the time for a hydrophilic drug to reach higher rostral centers *via* CSF bulk flow). With the use of stepped, increasing infusion rates for baclofen administration, (1) the presence or absence of a causal link between baclofen and fever can possibly be shown; (2) a threshold dose of baclofen that must be reached to achieve fever can possibly be shown (although not demonstrated in this patient, such a pharmacologic relation is possible); or (3) the absence of fever

can reaffirm that slow, gradual, continuous dosing can avert fever in lieu of a single “large” bolus, if fever is generated by a subsequent bolus injection through the catheter. (If the hypothesized mechanism of fever genesis *via* CSF bulk flow due to the hydrophilic character of baclofen is correct, the third possibility will not occur.)

Continuous subarachnoid administration of baclofen to a spastic patient can represent a dramatic improvement in his or her quality of life and is therefore difficult to withhold in the case of a successful trial. In rare situations in which baclofen administration may be causally linked to fever, percutaneous subarachnoid catheterization with incremental, increasing, stepped infusions of baclofen may facilitate the decision to proceed or to abort implantation.

## References

1. Penn RD, Savoy SM, Corcos D, Latash M, Gottlieb G, Parke B, Kroin JS: Intrathecal baclofen for severe spinal spasticity. *N Engl J Med* 1989; 320:1517–21
2. Albright AL, Barron WB, Fasick MP, Polinko P, Janosky J: Continuous intrathecal baclofen infusion for spasticity of cerebral origin. *JAMA* 1993; 270:2475–77
3. Penn RD: Intrathecal baclofen for spasticity of spinal origin: Seven years experience. *J Neurosurg* 1992; 77:236–40
4. Young RR, Delwaide PJ: Drug therapy: Spasticity. *N Engl J Med* 1981; 304:96–9
5. Katz RT: Management of spasticity. *Am J Phys Med Rehabil* 1988; 67:108–16
6. Davidoff RA: Antispasticity drugs: Mechanism of action. *Ann Neurol* 1985; 17:107–16
7. Lioresal® Intrathecal (baclofen injection) package insert. Minneapolis, Medtronic, 1997
8. Green LB, Nelson VS: Death after acute withdrawal of intrathecal baclofen: Case report and literature review. *Arch Phys Med Rehabil* 1999; 80:1600–4
9. Reeves RK, Stop-Smith KA, Christopherson MW: Hyperthermia, rhabdomyolysis, and disseminated intravascular coagulation associated with baclofen pump catheter failure. *Arch Phys Med Rehabil* 1998; 79:353–6
10. Zarrindast MR, Oveissi Y: GABA<sub>A</sub> and GABA<sub>B</sub> receptor sites involvement in rat thermoregulation. *Gen Pharmacol* 1988; 19:223–6
11. Sancibrian M, Serrano JS, Miñano EJ: Opioid and prostaglandin mechanisms involved in the effects of GABAergic drugs on body temperature. *Gen Pharmacol* 1991; 22:259–62
12. Drayer BP, Rosenbaum AE: Studies of the third circulation: Amipaque CT cisternography and ventriculography. *J Neurosurg* 1978; 48:946–56
13. DiChiro G: Observations on the circulation of cerebrospinal fluid. *Acta Radiol Diag* 1966; 5:988–1002