

Acute Failure of Oxygen Delivery

To the Editor:—The ability to supply oxygen to the patient under anesthesia is vital. We report five cases of sudden cessation of oxygen delivery during general anesthesia.

A 21-yr-old Chinese woman was scheduled to undergo emergency appendectomy. The anesthesia machine (Ohmeda Excel 210; Ohmeda, Madison, WI) was checked according to the protocol of the safety subcommittee of the Singapore Society of Anaesthesiologists. The patient was preoxygenated before rapid sequence induction and tracheal intubation. Mechanical ventilation was started with the oxygen fresh gas flow set at 1%. The isoflurane vaporizer (Isotec 5; Datex-Ohmeda) dial was then set to 1%, after which the oxygen fresh gas flow rapidly decreased to 0. Neither nitrous oxide nor air were available (zero flow when the respective flowmeters' dials were turned). Values shown by the pipeline and cylinder pressure gauges of the three gases were normal. A self-inflating resuscitation bag was quickly brought in, and the patient underwent manual ventilation with room air. The anesthesia was maintained using intravenous propofol. Her oxygen saturation was maintained between 95 and 100%. Another Excel 210 anesthesia machine was brought in, and anesthesia and surgery proceeded uneventfully. The biomedical engineers inspected the first Excel 210 machine but could not find any fault with it.

Within the year, we had four other similar cases. All machines were checked at the start of anesthesia. All involved the Excel 210 anesthesia machine and Isotec 5 vaporizers. The patients all received uneventful intravenous anesthetic inductions followed by planned isoflurane-nitrous oxide-oxygen mixture maintenance. However, when the isoflurane vaporizer was turned on, the anesthesiologist noticed a rapid decrease in the oxygen and nitrous oxide flows in the flowmeters. The oxygen and nitrous oxide pipeline gauges recorded no change in wall supply pressure. In all cases, the event was quickly discovered, and no patient injuries resulted.

In two of the events, the total failure of fresh gas flow occurred within seconds of turning on the isoflurane vaporizer. In the remaining three cases, the loss of fresh gas flow was more gradual and occurred over 1-2 min. In one of these cases, the anesthesiologist noticed that the isoflurane output was 0% according to the agent monitor, although the vaporizer was turned on and set to 2%. In another case, the anesthesiologist attempted to increase gas flow by turning up the flowmeter dial, which resulted in a more rapid loss of gas supply. In the last of these three cases, the anesthesiologist noticed that fresh gas flow was immediately restored when the isoflurane vaporizer was turned off and replaced with a sevoflurane vaporizer.

The five cases involved five different Ohmeda Excel 210 anesthesia machines and five different Isotec 5 vaporizers. When each involved Isotec 5 vaporizer was replaced with another Isotec 5 vaporizer, normal oxygen delivery was restored. However, when the five "faulty" Isotec 5 vaporizers were mounted on other Excel 210 machines, fresh gas delivery failure was replicated.

During close examination of the "faulty" Isotec 5 vaporizers, we found that the two actuating spindles on the back of the vaporizer were not of equal length. The function of the actuating spindle is to divert fresh gas flow from the Select-a-Tec vaporizer manifold of the Excel into the vaporizer when the vaporizer is turned on, even when it is set at 0%. The actuating spindles act by depressing the ball valve system in the vaporizer manifold of the Excel machine. When the spindle in the upstream side was excessively long, the ball valve in the vaporizer manifold was completely depressed, and the fresh gas flow pathway into the vaporizer became occluded (fig. 1). The complete

obstruction of fresh gas flow resulted in back pressure. Equalization of the pressure difference across the flowmeter bobbin occurred, and the output decreased to 0. Gas delivery through the flowmeter then ceased. Our biomedical engineers tested the postulated cause of the fresh gas flow failure due to the length of the upstream actuating spindle in the "faulty" vaporizer by adding O-rings around the port valve. The inserted O-rings increased the upstream level of the vaporizer on the back bar and compensated for the excessive length of the affected actuating spindle. The vaporizer then functioned normally.

When the longer actuating spindle was the downstream spindle, there was correct diversion of the fresh gas flow into the vaporizer. However, gas return from the vaporizing chamber to the vaporizer manifold was blocked. Fresh gas then leaked from the port valve into the atmosphere, causing a slower increase in back pressure. This resulted in a slower loss of fresh gas flow (fig. 2). When additional O-rings were added to increase this downstream valve port slightly, the gas leak lessened. This was associated with faster buildup of back pressure and cessation of fresh gas flow. When sufficient O-rings were added to elevate the vaporizer position to completely compensate for the excessively long downstream spindle, the back pressure effect and gas flow delivery were again normalized.

Intraoperative awareness has been reported as a result of malfunctioning of the vaporizer attached to the Siemens 900B ventilator¹ (Siemens-Elementa, Sweden) and also on the Select-a-Tec Vaporizing System.² Riendl³ described a case in which a hypoxic gas mixture was delivered to the patient as a result of a faulty spring in the Ohmeda Modulus I gas machine. However, there are no reports of total fresh gas

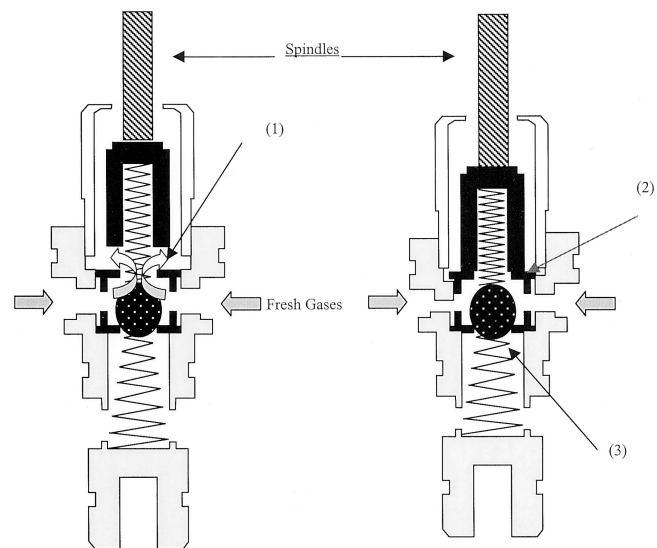


Fig. 1. Enlarged diagram of the upstream vaporizer port valve when the vaporizer spindle is in the actuated position. Control is achieved by a ball bearing enclosed in a cage-like metal can as shown. The left vaporizer spindle shows the normal function of the spindle when it is actuated. The ball bearing is pushed down, and fresh gas is diverted into the vaporizing chamber (1). The right vaporizer spindle shows the situation when the spindle is too long or protrudes too far downward. An obstruction occurs (2), and the fresh gas cannot flow into the vaporizing chamber. At the same time, the ball bearing is pushed down and occludes the bypass path into the vaporizer manifold (3). Complete obstruction to fresh gas flow results with resultant back pressure in all flowmeters.

Support was provided solely from institutional and/or departmental sources.

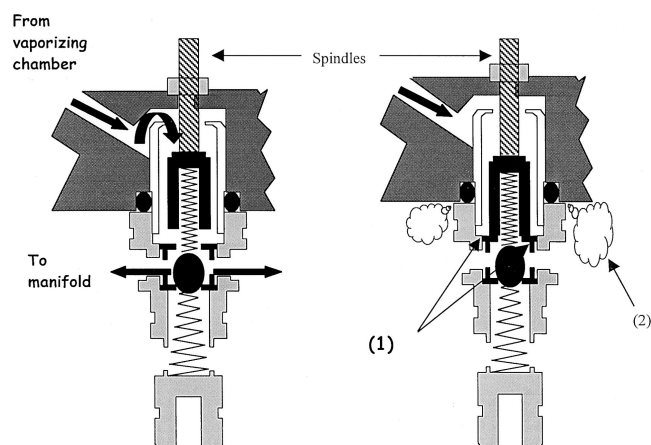


Fig. 2. Diagram showing the “excessively long” spindle in the downstream port valve of the affected vaporizer. The left spindle shows the normal situation when fresh gas returns to the anesthesia machine Select-a-Tec vaporizer manifold from the vaporizing chamber. The right spindle shows what happens when the spindle protrudes excessively and causes obstruction (1). Fresh gas is able to leak out through the port valve O-rings (2). This allows back pressure buildup to be retarded, resulting in a slower decrease in fresh gas flow from the flowmeter.

delivery failure resulting from a fault in the vaporizer system. All the vaporizers involved in our description were approximately 7 yr old and

Anesthesiology 2001; 95:1039

In Reply:—The completion of a preoperative checkout of anesthesia equipment is clearly supported by Datex-Ohmeda (Madison, WI). The authors state that the anesthesia system was checked in accordance with the protocol adopted by the safety subcommittee of the Singapore Society of Anaesthesiologists. However, Datex-Ohmeda believes that, if available, the anesthesia system’s specific preoperative checkout procedures should be used instead of generic guidelines. This is true both for the protocol adopted by the safety subcommittee of the Singapore Society of Anaesthesiologists and for the generic 1993 Food and Drug Administration Anesthesia Apparatus Checkout Recommendations. The Food and Drug Administration supports this position as described in their introduction to the Food and Drug Administration

Anesthesiology 2001; 95:1039–40

To the Editor:—I read with interest the editorial by Donati and Guay,¹ who comment about an accompanying paper that examined the use of intramuscular rapacuronium in children.² Although they correctly note that this study shows the limitations of intramuscular administration of nondepolarizing neuromuscular blocking agents, they also include what I believe to be some unfortunate recommendations regarding the treatment of laryngospasm. For laryngospasm that occurs with mask induction without previous intravenous access, they seem to recommend against administering intramuscular succinylcholine. To support this recommendation, they quote an earlier study, which states that “In an already asphyxiated child, the 3 or 4 min required for maximum relaxation after 4 mg/kg [succinylcholine] argues against its use.”³ Rather, they advocate attempting to gain intravenous access (using for example the femoral route) and perhaps administering propofol. This suggestion contradicts the advice of anesthesia texts⁴ and recent re-

Anesthesiology, V 95, No 4, Oct 2001

had been maintained on a regular basis by the Australian Datex-Ohmeda service center. Our suspicion that the fault was caused by excessively long actuating spindles was later confirmed by Datex-Ohmeda in four of the vaporizers. Datex-Ohmeda found that the locknuts and lock-tites holding the top of the actuating spindle in its proper place were loose or missing in the affected vaporizers. This allowed the actuating spindle to migrate downward, functioning effectively as “excessively long” spindles. The actual spindles were, in fact, of normal length. This could have occurred when the locknuts became old or when they were not replaced or tightened adequately after a routine service as reported by Datex-Ohmeda. In two of the vaporizers, the fault was in the upstream spindle. In one vaporizer, the problem involved the downstream spindle, and in the other, the exact spindle was not specified.

Biauw-Chi Ong, M.Med.,* Johari bin Katijo, Diploma of Electrical Engineering, Boon-Leong Tan, Diploma of Electrical Engineering, Cheng-Chuan Lee, I.T.C., Yew-Weng Chan, M.Med. *Singapore General Hospital, Singapore. ganobc@sgh.com.sg

References

1. Slinger PD, Scott WA, Kliffer AP: Intraoperative awareness due to malfunction of a Siemens 900B ventilator. *Can J Anaesth* 1990; 37:258–61
2. Lum ME, Ngan Kee WD, Robinson BJ: Fault in a Selectatec manifold resulting in awareness. *Anaesth Intensive Care* 1992; 20:501–3
3. Riendl J: Hypoxic gas mixture delivery due to malfunctioning inlet port of a Select-a-Tec vaporiser manifold (letter). *Can J Anaesth* 1987; 34:431

(Accepted for publication April 12, 2001.)

© 2001 American Society of Anesthesiologists, Inc. Lippincott Williams & Wilkins, Inc.

checkout, which states, “This is a guideline which users are encouraged to modify to accommodate differences in equipment design and variations in local clinical practice. Such local modifications should have appropriate peer review. Users should refer to the operator’s manual for the manufacturer’s specific procedures and precautions.” If the user had performed the preoperative checkout described in the *Excel 210 SE Operation and Maintenance* manual, the situation would have been identified before use.

Daniel Kosednar, R.A.C., Datex-Ohmeda, Madison, Wisconsin

(Accepted for publication April 12, 2001.)

© 2001 American Society of Anesthesiologists, Inc. Lippincott Williams & Wilkins, Inc.

Intramuscular Succinylcholine and Laryngospasm

views^{5,6} and is contrary to the clinical experience of most pediatric anesthesiologists, including myself. Although surprisingly little research is extant regarding the treatment of laryngospasm, case reports and experience both show that even small doses of succinylcholine suffice to quickly relieve laryngospasm, and that “maximum relaxation” is not required.⁷ In fact, the reference quoted by the editorial says in the next sentence that “Nevertheless, clinical experience with intramuscular succinylcholine in children has been that airway control after laryngospasm is achieved in less time than the time to maximum depression [of the twitch response].”³ Furthermore, as shown by the excellent work of Dr. Donati *et al.*,⁸ the onset of neuromuscular blockade is generally more rapid at the larynx compared with the peripheral muscles, a factor advantageous in the treatment of laryngospasm. In contrast, under the best of circumstances (and a blue child does not represent the best of circumstances), the establishment of

intravenous access for the administration of drugs to treat laryngospasm requires a minimum of several seconds, seconds which are precious in this situation.

I fully appreciate the risks of succinylcholine. However, a balanced approach to its risk and benefits must be maintained, and we must not succumb to a sort of "sux-o-phobia" aided and abetted by pharmaceutical manufacturers eager to supplant its use with their newer products. My parents, both pediatric anesthesiologists with more than 60 yr of experience between them, taught me that intramuscular succinylcholine (administered with atropine to avoid cholinergic side effects) quickly relieves laryngospasm in children. My own experience and that of my colleagues has proven them correct. Given the potential for catastrophic injury if severe laryngospasm is not rapidly treated, we should not recommend the abandonment of an effective therapy, especially when measures of questionable practicality and unknown efficacy (e.g., propofol) are substituted. I fear that removing this valuable tool from our armamentarium could result in harm to our little ones.

David O. Warner, M.D., Mayo Clinic, Rochester, Minnesota.
warner.david@mayo.edu

Anesthesiology 2001; 95:1040

References

1. Donati F, Guay J: No substitute for the intravenous route. *ANESTHESIOLOGY* 2001; 94:1-2
2. Denman WT, Kaplan RF, Goudsouzian NG, Uejima T, Barcelona SL, Cote CJ, Ginsberg B, Hannallah RS: Intramuscular rapacuronium in infants and children. *ANESTHESIOLOGY* 2001; 94:3-7
3. Liu LMP, DeCook TH, Goudsouzian NG, Ryan JF, Liu PL: Dose response to intramuscular succinylcholine in children. *ANESTHESIOLOGY* 1981; 55:599-602
4. Berry FA: Neonatal anesthesia, *Clinical Anesthesia*, 3rd edition. Edited by Barash PG, Cullen BF, Stoelting RK. Philadelphia, Lippincott-Raven, 1997, pp 1091-114
5. Seah TG, Chin NM: Severe laryngospasm without intravenous access: A case report and literature review of the non-intravenous routes of administration of suxamethonium. *Singapore Med J* 1998; 39:328-30
6. Cook DR: Can succinylcholine be abandoned? *Anesth Analg* 2000; 90(suppl 5):S24-8
7. Chung DC, Rowbottom SJ: A very small dose of suxamethonium relieves laryngospasm. *Anaesthesia* 1993; 48:229-30
8. Donati F, Meistelman C, Plaud B: Vecuronium neuromuscular blockade at the adductor muscles of the larynx and adductor pollicis. *ANESTHESIOLOGY* 1991; 74:833-7

(Accepted for publication May 23, 2001.)

© 2001 American Society of Anesthesiologists, Inc. Lippincott Williams & Wilkins, Inc.

Anesthesiology 2001; 95:1040

© 2001 American Society of Anesthesiologists, Inc. Lippincott Williams & Wilkins, Inc.

The Substitute for the Intravenous Route

To the Editor:—In their editorial "No substitute for the Intravenous Route," Donati and Guay¹ come to the conclusion that, apart from succinylcholine, the intramuscular route is a poor alternative for administration of neuromuscular blocking agents in life-threatening situations in pediatric anesthesia. We fully agree with this conclusion and with the statement that all possible strategies to relieve laryngospasm should be considered. It is unfortunately true that there are still situations in which intravenous access cannot be obtained quickly. Indeed, the fact that all new neuromuscular blocking drugs have been investigated for rapidity of action after intramuscular administration indicates the continuing interest in finding ways of reliable and rapid neuromuscular blockade in the absence of venous access. Rather than continue to search for a neuromuscular blocker with rapid onset of action after intramuscular administration, we believe that the intraosseous route already offers an efficient alternative by which good intubating conditions can be rapidly obtained using currently available neuromuscular blocking drugs. Therefore, we disagree with the authors' final statement that all efforts should be focused on a search for intravenous access and no site, including the femoral route, should be rejected to relieve laryngospasm.¹ We are convinced that in the dreaded "cannot insert the intravenous catheter, cannot ventilate" scenario, the intraosseous route offers an excellent substitute. Ample scientific evidence proves that this route is easy, fast, and devoid of serious complications.² Instead of losing time with repeated futile attempts at venous cannulation in emergency situations, intraosseous access should be established right away. The intraosseous infusion technique is proven, quick, and efficient in the emergency care of both children and adults.² It is simple and has been used successfully by paramedical personnel. Parenteral access is obtained within 30-60 s, and there are few complications. Essentially, all fluids and drugs can be administered by the intraosseous route with faster central circulation times and better pharmacokinetics compared with peripheral intravenous injection. In prehospital emergency medicine, emergency departments, and pediatric intensive care units, its use is recommended in critically ill pediatric patients when intravenous access cannot be

established within 90-120 s. The newly published Pediatric Advanced Life Support guidelines suggest it be the route of first choice in cardiocirculatory arrest.³ Nonetheless, intraosseous infusion remains a technique rarely used in operating rooms. Although elective use of intraosseous infusion in children with difficult vascular access during anesthesia remains debatable, there is no question that it provides simple, safe, and highly successful parenteral access in all emergency situations.^{4,5} Pediatric anesthesiologists take pride in their ability to establish intravenous access in difficult circumstances; however, we should not let this pride stand in the way of more rapid access by use of the intraosseous needle. This technique should be part of basic anesthesia training to ensure better management of pediatric emergencies when intravenous access is not available. Every anesthesiologist should become proficient in intraosseous technique and should not hesitate to use it in an emergency. Sets with all equipment required should be readily available in all locations where children are anesthetized.

Markus Weiss, M.D., Andreas Gerber, M.D.* *University Children's Hospital, Zurich, Switzerland. andreas.gerber@kisp.unizh.ch

References

1. Donati F, Guay J: No substitute for the intravenous route. *ANESTHESIOLOGY* 2001; 94:1-2
2. Kruse JA, Vyskocil JJ, Haupt MT: Intraosseous infusions: A flexible option for the adult or child with delayed, difficult or impossible conventional vascular access. *Crit Care Med* 1994; 22:728-9
3. American Heart Association: Pediatric advanced life support. *Circulation* 2000; 102:305-6
4. Stewart FC, Kain ZN: Intraosseous infusion: Elective use in pediatric anesthesia. *Anesth Analg* 1992; 75:626-9
5. Schwartz RE, Pasquariello CA, Stayer SA: Elective use in pediatric anesthesia of intraosseous infusion: Proceed only with extreme caution. *Anesth Analg* 1993; 76:918-9

(Accepted for publication May 23, 2001.)

Anesthesiology 2001; 95:1041

© 2001 American Society of Anesthesiologists, Inc. Lippincott Williams & Wilkins, Inc.

In Reply:—We appreciate the opportunity to respond to the excellent comments made about our editorial. The situation of laryngospasm without previous intravenous access is difficult to tackle, and the fact that two very different suggestions were made in letters to the editor indicates that the answers are not easy. Drs. Weiss and Gerber propose the intraosseous route, and Dr. Warner suggests using intramuscular succinylcholine. As we have mentioned, all possible strategies to relieve laryngospasm should be considered.¹ The option retained by the individual practitioner will depend on experience and skill. However, we wish to point out that the intraosseous route involves more complications than the intravenous route, and its use should be limited to emergency situations. Extravasation,² compartment syndrome,³ and osteomyelitis⁴ have been reported. In fact, one of the references quoted by Drs. Weiss and Gerber suggests an inhalational induction with halothane and nitrous oxide with intramuscular pancuronium in a case of a child with difficult intravenous access instead of intraosseous infusion of drugs.⁵ In this case, securing intraosseous access is probably better than intramuscular pancuronium, a drug whose dosage and time course is not known when administered *via* this route. In emergency situations, the body of evidence suggests that if one chooses to administer intramuscular relaxants, succinylcholine is the best choice. The time course of blockade is faster than with rapacuronium, which is faster than rocuronium. Intramuscular pancuronium is probably even slower. Rapacuronium has recently been withdrawn. We fully agree with Dr. Warner that the potential benefits of succinylcholine (relief of laryngospasm) outweigh its risks in a hypoxic child. Contrary to nondepolarizing muscle relaxants, laryngeal muscles are particularly sensitive to succinylcholine.⁶ It would be an error to remove succinylcholine from our armamentarium. However, we would like to stress again that both the intraosseous route and intra-

muscular succinylcholine are not substitutes for poor planning. An intravenous line should be inserted before the airway is manipulated and before surgery commences. Intravenous access management is analogous to airway management. If one becomes familiar with several airway devices, the last resort measure (cricothyroidotomy or tracheostomy) should be learned, but hardly ever used. Similarly, if one becomes proficient at accessing the venous system at several sites, intraosseous infusions and intramuscular succinylcholine are techniques to be learned, but hopefully used infrequently.

François Donati, Ph.D., M.D., F.R.C.P.C.,* Joanne Guay, M.D., F.R.C.P.C. *Université de Montréal, Hôpital Maisonneuve-Rosemont, Montréal, Québec, Canada. francois.donati@umontreal.ca

References

1. Donati F, Guay J: No substitute for the intravenous route. *ANESTHESIOLOGY* 2001; 94:1-2
2. Glaeser PW, Hellmich TR, Szewczuga D, Losek JD, Smith DS: Five-year experience in prehospital intraosseous infusions in children and adults. *Ann Emerg Med* 1993; 22:1119-24
3. Wright R, Reynolds SL, Nachtsheim B: Compartment syndrome secondary to prolonged intraosseous infusion. *Pediatr Emerg Care* 1994; 10:157-9
4. Rosovsky M, FitzPatrick M, Goldfarb CR, Finestone H: Bilateral osteomyelitis due to intraosseous infusion: Case report and review of the English-language literature. *Pediatr Radiol* 1994; 24:72-3
5. Schwartz RE, Pasquariello CA, Stayer SA: Elective use in pediatric anesthesia of intraosseous infusion: Proceed only with extreme caution. *Anesth Analg* 1993; 76:918-9
6. Meistelman C, Plaud B, Donati F: Neuromuscular effects of succinylcholine on the vocal cords and adductor pollicis muscles. *Anesth Analg* 1991; 73:278-82

(Accepted for publication May 23, 2001.)

Anesthesiology 2001; 95:1041-2

© 2001 American Society of Anesthesiologists, Inc. Lippincott Williams & Wilkins, Inc.

Combitube and Similar Devices Should Undergo Long-term Safety Evaluation before Their Routine Use in Clinical Practice

To the Editor:—I was interested to read the article by Gaitini *et al.*¹ There are many products similar to the Combitube (Tyco-Kendall-Sheridan, Mansfield, MA) that have been designed to maintain a patent airway in anesthetized or unconscious patients. One such product (fig. 1), called the Airway Management Device (AMD; Nagor Limited, Isle of Man, British Isles) has been marketed recently in the United Kingdom.

The common features of these devices include one oropharyngeal cuff and one esophageal cuff. We encountered problems with these

inflated cuffs while conducting our audit on the AMD™ during general anesthesia.

We noticed that the inflated oropharyngeal cuff was causing congestion, protrusion, and bluish discoloration of the tongue. These problems were noted even with an oropharyngeal cuff pressure of less than 15 cm H₂O. None of our patients experienced any damage. However, a congested and swollen tongue is a potential cause of airway obstruction after extubation. Long-term congestion may result in ischemic injury to the tongue. Concern has also been expressed about the possibility of lingual nerve damage and venous thrombosis due to high intracuff pressure.² Gaitini *et al.*¹ overinflated the oropharyngeal cuff with an additional 15-20 ml air. A very high intracuff pressure could have developed with overinflation. Even an under-inflated cuff with half of the recommended volume of air recorded a pressure of 110 cm H₂O.³ A high intracuff pressure could seriously compromise the circulation of the tongue, especially in association with hypotension. It has been recommended to monitor the intracuff pressure, but the safe level of pressure has not been well-defined.³

An inflated cuff placed in the upper end of the esophagus should adequately provide airway protection against gastric regurgitation.⁴ However, this may not happen in practice. An inflated upper esophageal cuff could prevent regurgitation by mechanical obstruction, but it could make the upper esophageal sphincter incompetent. In our audit, we found unexpected regurgitation in two patients. Fortunately, none of them had signs or symptoms of aspiration. These unexpected inci-

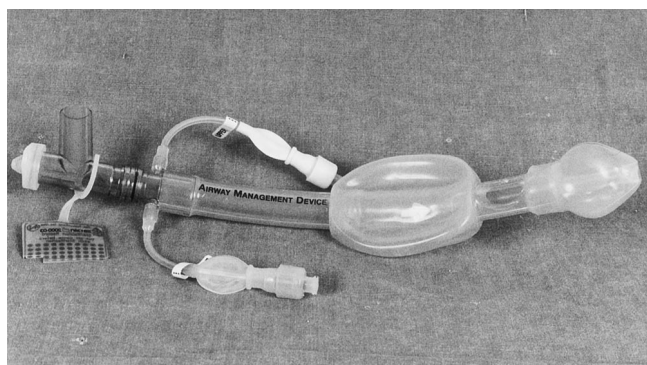

Fig. 1. The Airway Management Device (AMD; Nagor Limited, Isle of Man, British Isles).

dents may be due to incompetent esophageal sphincter caused by the inflated cuff. In their study, Urtubia *et al.*⁴ also noted an unexpected case of regurgitation. Thus, these devices could be useful in difficult airway situations.³ However, because of those potential problems, they should be used with caution until more studies are available to prove their safety especially for long-term use. Also, a clear guideline in relation to the safe level of intracuff pressure should be in place.

Nanda G. Mandal, M.B.B.S., M.D., D.A., F.R.C.A., Poole Hospital National Health Service Trust, Poole, Dorset, United Kingdom. n_mandal@hotmail.com

Anesthesiology 2001; 95:1042

In Reply:—We appreciate the interest and the comments of Dr. Mandal regarding our findings pertaining to the Combitube (Tyco-Kendall-Sheridan, Mansfield, MA). We agree that it is important to conduct a thorough safety evaluation of the various supraglottic airway devices, and it is to this end that we have conducted this and other studies. Indeed, our article suggests only that continued airway management with a Combitube that has been previously placed is a reasonable option in many cases. Having thus secured the airway, it may not be necessary to abort the anesthetic or to continue with further airway management efforts. The point of our study was not to advocate or promote the use of the Combitube as a preferred method of airway management, but rather to address the question “What now?” after one has used the device, typically in a difficult airway situation. We have shown that in most cases, the device can be used as the definitive airway for an anesthetic of at least moderate duration with the use of either spontaneous or mechanical ventilation.

Certainly, the issue of aspiration is of concern, and in cases of increased risk of aspiration (*e.g.*, full stomach, obesity), it may be wise to awaken the patient or secure an endotracheal tube, such as we have described previously.¹ However, we note that in these 200 cases and in the many other cases in which we have used the Combitube, aspiration has not occurred. One of the advantages of the Combitube in comparison with other supraglottic airway devices is, in fact, that it is designed to allow regurgitated gastric contents to be diverted away from the airway as well as to be suctioned.

We share Dr. Mandal's concern regarding potential injury from excessive pressure exerted by the oropharyngeal balloon of the Combitube. The high intracuff pressure of the supraglottic airway devices is a common feature, and awareness of this problem is increasing. For example, the new Laryngeal Tube[®] (VBM Medizintechnik GmbH, Sulz

References

1. Gaitini LA, Vaida SJ, Mostafa S, Yanovski B, Croitoru M, Capdevila MD, Sabo E, Ben-David B, Benumof J: The Combitube in elective surgery: A report of 200 cases. *ANESTHESIOLOGY* 2001; 94:79–82
2. Johnson R, Bailie R: Airway Management Device (AMD™) for airway control in percutaneous dilatational tracheostomy. *Anaesthesia* 2000; 55:596–7
3. Enlund M, Miregard M, Wennmala K: The Combitube for failed intubation: Instructions for use. *Acta Anaesthesiol Scand* 2001; 45:127–8
4. Urtubia RM, Aguilu CM, Cumsille MA: Combitube: A study for proper use. *Anesth Analg* 2000; 90:958–62

(Accepted for publication May 28, 2001.)

© 2001 American Society of Anesthesiologists, Inc. Lippincott Williams & Wilkins, Inc.

a.n, Germany) has a high-volume, low-pressure oropharyngeal balloon that is inflated by the aid of a manometer to a intracuff pressure of 60 cm H₂O. In this study, we tried to avoid excessive pressure on the pharyngeal mucosa and tongue by deflating the oropharyngeal balloon every 20 min for 1 min. Overinflation of the oropharyngeal balloon with an additional 15–20 ml of air was not performed routinely, but only in 15 of 200 patients when a gas leak was detected at a ventilation pressure of 25 cm H₂O. Recently, we have shown that in most patients, significantly smaller cuff volumes than those recommended by the manufacturer are needed to form an effective seal by the oropharyngeal balloon of the Combitube.² Smaller filling volumes of the oropharyngeal balloon result in lower cuff pressures and may thus reduce mucosal or lingual injury. As Urtubia and Medina³ suggest, a redesigned Combitube with a high-volume, low-pressure oropharyngeal balloon could minimize this problem.

Luis A. Gaitini, M.D.,* Sonia J. Vaida, M.D., Somri Mostafa, M.D., Bruce Ben-David, M.D. *B'nai Zion Medical Center, Haifa, Israel. gaitini@netvision.net.il

References

1. Gaitini LA, Vaida SJ, Somri M, Fradis M, Ben-David B: Fiberoptic-guided airway exchange of the Esophageal-Tracheal Combitube in spontaneously breathing vs. mechanically ventilated patients. *Anesth Analg* 1999; 88:193–6
2. Gaitini LA, Vaida SJ, Somri M, Croitoru M, Ben-David B: Minimal inflation volume for adequate filling of the Combitube Pharyngeal Balloon. *ANESTHESIOLOGY* 2000; 93(suppl):A1318
3. Urtubia RM, Medina J: The Combitube should be redesigned for anesthetic use. *Anaesthesia* 2001, 56:272

(Accepted for publication May 28, 2001.)

Anesthesiology 2001; 95:1042–3

© 2001 American Society of Anesthesiologists, Inc. Lippincott Williams & Wilkins, Inc.

The “Sniffing Position” Facilitates Tracheal Intubation

To the Editor:—I read with interest the recent article by Adnet *et al.*¹ wherein magnetic resonance imaging of eight awake subjects was used in an attempt to determine whether the “sniffing position” aligns the axes of the upper airway. The authors compared the neutral position to both simple extension and the sniffing position. Using the magnetic resonance images, axes were drawn through the mouth (MA), the pharynx (PA), and the larynx (LA). The angle between MA and PA was defined as α , that between PA and LA was defined as β , and δ was defined as the angle between the line of vision and LA. No subjects were anesthetized or paralyzed, and no laryngoscopies or tracheal intubations were performed.

The authors noted that angle δ was significantly greater in the neutral position than in the other two positions, demonstrating a disadvantage to the neutral position and an advantage that seemed to

be equal for simple extension and the sniffing position. A larger study is necessary to determine whether the sniffing position is better than simple extension.

The authors did not note that the sum of α and β was numerically the lowest in the sniffing position. This indicates that the sniffing position does seem advantageous in aligning the axes.

Adnet *et al.*¹ concluded, “Anatomic alignment of the LA, PA, and MA axes is impossible to achieve in any of the three positions tested.” This statement seems to contradict the fact that anesthesiologists perform laryngoscopies every day and are usually able to align these axes satisfactorily for visualization of the vocal cords and tracheal intubation. Moreover, it is obvious that simply placing a patient in the sniffing position or any other position does not automatically align the axes of the upper airway. Indeed, this is the reason that a laryngoscope is

required for successful tracheal intubation. Therefore, perhaps a more important question for anesthesiologists is, Does the sniffing position facilitate laryngoscopy and tracheal intubation? This question is not addressed by this study.

I plan to continue positioning my patients in the sniffing position for tracheal intubation for four reasons: (1) the study of Adnet *et al.*¹ shows a lower value of δ in the sniffing position than in the neutral position; (2) the sum of α and β is lowest in the sniffing position; (3) patients are generally more comfortable with a pillow under their head; and (4) this position has been successfully used for endotracheal intubation in a large number of cases.

Anesthesiology 2001; 95:1043-4

© 2001 American Society of Anesthesiologists, Inc. Lippincott Williams & Wilkins, Inc.

Reevaluating the "Cornerstone of Training in Anesthesiology"

To the Editor:—We read with interest the article by Adnet *et al.*¹ entitled "Study of the 'Sniffing Position' by Magnetic Resonance Imaging." Although we agree with the authors' conclusion that in awake patients with normal airway anatomy, the sniffing position does not achieve alignment of the three anatomic axes as defined by them (mouth axis [MA], pharyngeal axis [PA], and laryngeal axis [LA]), we disagree with their assessment that there is no significant difference between anatomic angles observed in simple head extension *versus* the sniffing position. Any head extension from the neutral position on a flat surface inevitably results in a degree of neck flexion, hence, the sniffing position. Furthermore, Bannister and Macbeth² as a procedural improvement recommended using the sniffing position during direct laryngoscopy; therefore, analysis of the effectiveness of Bannister and Macbeth's² sniffing position for orotracheal intubation without the use of a laryngoscope is unreasonable.

The three anatomic spaces of the airway conduit, beginning at the mouth, passing through the pharynx, and ending at the laryngeal inlet, are not in a straight line. The pathway of this conduit changes its course from one segment to the next; hence, an axis may be assigned to each of these segments: laryngoscopic mouth axis (LMA), laryngoscopic pharyngeal axis (LPA), and laryngoscopic laryngeal axis (LLA) (fig. 1A). The pharynx extends from the base of the skull to the lower border of the cricoid cartilage, and the laryngeal inlet is located caudal and inferior to the inlet of the mouth. Repositioning the patient's head

It is also worth mentioning that in figure 1C,¹ the authors have not drawn axis PA correctly. This line does not contact the anterior portion of C2 as it is supposed to by their definition.

Mitchel B. Sosis, M.D., Ph.D., Campus Eye Group, Hamilton Square, New Jersey. mitchelsosis@hotmail.com

Reference

1. Adnet F, Borron SW, Dumas JL, Lapostolle F, Cupa M, Lapandry C: Study of the "sniffing position" by magnetic resonance imaging. *ANESTHESIOLOGY* 2001; 94:83-6

(Accepted for publication May 28, 2001.)

from the neutral position (fig. 1A) to the sniffing position (fig. 1B) may result in improved alignment of the LMA with both the LPA and LLA. However, adjustment of the position of the head and neck alone is not sufficient to align the three laryngoscopic axes; implementation of a laryngoscope is necessary for the creation of a straight line. The anteroad and caudad force exerted by a laryngoscope blade on the oropharyngeal structures of a patient with his or her head in the sniffing position not only displaces the soft tissues of the oropharyngeal cavity *via* the conversion of a potential space to an actual space, but also aligns the laryngoscopic axes resulting in visualization of the vocal cords. The complete alignment of these three axes results in a laryngoscopic line (LL) (fig. 1C), which we define as a straight line passing through the inferior extremity of the superior incisors and the center of the vocal cords. In contradistinction to the three anatomic axes described by Adnet *et al.*,¹ these three *laryngoscopic* axes (LMA, LPA, LLA) may be aligned and more closely represent a clinically relevant goal to be sought during orotracheal intubation. Therefore, during direct laryngoscopy, the only pertinent maneuver (head positioning) is that which facilitates the production of an LL by improving alignment of the LMA, LPA, and LLA. The true benefit of the sniffing position is that it assists the laryngoscopist in producing an LL. However, contrary to the authors' conclusion, the sniffing position is superior to simple head extension. Not surprisingly, their results (table 1)¹ do not show any significant change in the angles of the anatomic

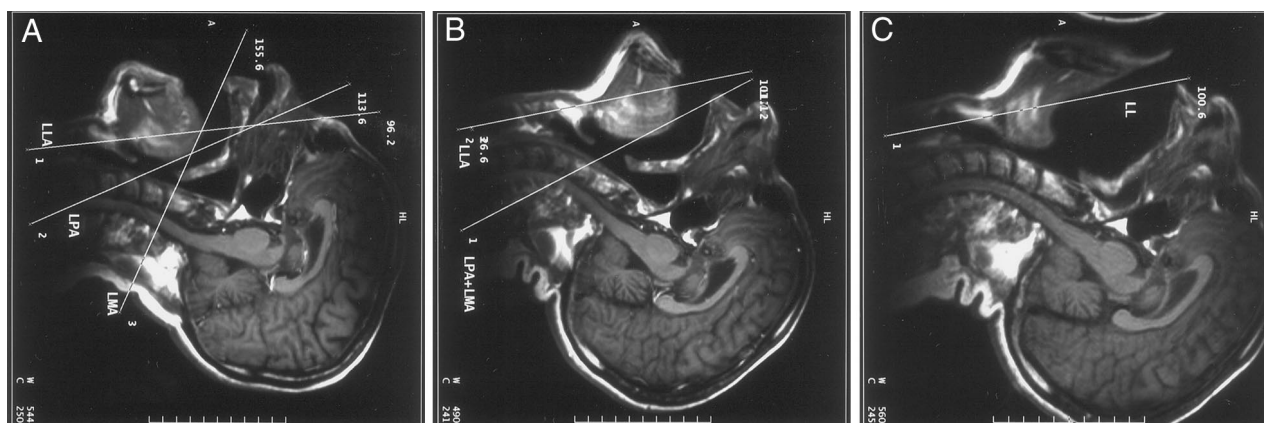


Fig. 1. Evolution of laryngoscopic axes in awake investigator (A. K.): laryngoscopic mouth axis (LMA), laryngoscopic pharyngeal axis (LPA), laryngoscopic laryngeal axis (LLA), and laryngoscopic line (LL). (A) Neutral head position. No alignment of laryngoscopic axes. (B) Sniffing position without laryngoscopy. Improved alignment of three laryngoscopic axes with complete alignment of LMA and LPA. (C) Sniffing position with laryngoscopy. Effect of the laryngoscope blade on production of the LL. Gradual advancement of the laryngoscope blade in the oropharyngeal cavity resulted in alignment of LMA, LPA, and LLA. More advancement of the laryngoscope blade is needed to displace the tongue and to produce a complete LL.

axes when comparing their simple head extension to the sniffing position.

Bannister and Macbeth² never gave a distinct definition of their "anatomical" axes used for alignment; their objective was to improve airway conduit alignment and visualization of the vocal cords. Because their alignment relies on the use of a laryngoscope and manipulation of the patient's head position, we believe they aligned the laryngoscopic axes, not the anatomic axes, as described by Adnet *et al.*¹ Consequently, Adnet *et al.*¹ should have taken into consideration the effect that a laryngoscope exerts on the anatomic structures comprising the oropharyngeal cavity during direct laryngoscopy. Therefore, we believe that although the anatomic axes described by Adnet *et al.*¹ cannot be aligned, our three laryngoscopic axes can be, and the best position for doing so remains the sniffing position as described by Bannister and Macbeth² in 1944. The optimal head positioning for direct laryngoscopy and orotracheal intubation, the so-called sniffing position, remains the true "cornerstone of training in anesthesiology" in 2001, just as it was 57 yr ago.

Anesthesiology 2001; 95:1044

The "Sniffing Position" Is Not an Anatomic Myth

To the Editor:—Recently, residents in our program have told me that they read about the "sniffing position" being an anatomic myth and of little clinical use.¹ Being a clinician who strongly advocates the sniffing position, I examined the article by Dr. Adnet *et al.*¹ to find out whether there is substance to this apparent revelation.

In their article, Dr. Adnet *et al.*¹ study the x-ray anatomy of the upper airway. The axial alignment of the mouth, the pharynx, and the larynx is measured with the head in the neutral position, in simple head extension, and in the sniffing position. The authors find no alignment of the axis of the hard palate, the upper cervical spine, the visual axis (upper incisors to posterior cricoid cartilage), and the laryngeal axis in the sniffing position and call the superiority of the sniffing position over simple head extension into question.

The most problematic part of this study is the definition of the laryngeal axis, defined as "a straight line passing through the centers of the inferior (cricoid cartilage) and superior (base of epiglottis) orifices." This definition is not an accepted standard, highly dependent on the acquisition of an exactly median-sagittal magnetic resonance image slice and the comparison of identical anatomic landmarks. The authors have published a figure that underscores my point of criticism as follows: the diameter of the "superior orifice" in the sagittal image of the subject in simple head extension connects what seems to be the superior aspect of the cricoid cartilage (posterior) to the inferior aspect of the thyroid cartilage (anterior). However, in the sagittal image of the subject in the sniffing position, the same line connects the cricoid cartilage with the center, rather than the inferior aspect of the thyroid cartilage. Thus, the course of the laryngeal axis is altered and

Anesthesiology 2001; 95:1044-5

Another View of the "Sniffing Position"

To the Editor:—The principle finding in the article by Adnet *et al.*¹ is that the oral, pharyngeal, and laryngeal axes are not aligned in an awake, supine patient in the "sniffing position." However, this finding does not contradict the common wisdom that the sniffing position facilitates intubation, because the authors did not compare laryngeal views in any of the three positions examined. After all, the proposed advantage of the sniffing position is in reducing the effort required to expose the glottis during laryngoscopy. Axis alignment may be irrele-

Anesthesiology, V 95, No 4, Oct 2001

The authors thank Mr. Billie Roberts, R.T., M.R. (Radiologic Technologist, Magnetic Resonance), and Ms. Toni Roberts, R.T., M.R. (Radiologic Technologist, Magnetic Resonance), of Cook County Hospital, Chicago, Illinois, for organizing the series of magnetic resonance imaging scans for this letter.

Kenneth D. Candido, M.D., Ahmed H. Ghaleb, M.D., Simin Saatee, M.D., Arjang Khorasani, M.D.* *Cook County Hospital, Chicago, Illinois. arjangk@clicksol.com

References

1. Adnet F, Borron SW, Dumas JL, Lapostolle F, Cupa M, Lapandry C: Study of the "sniffing position" by magnetic resonance imaging. *ANESTHESIOLOGY* 2001; 94:83-6
2. Bannister FB, Macbeth RG: Direct laryngoscopy and tracheal intubation. *Lancet* 1944; 2:651-4

(Accepted for publication May 28, 2001.)

© 2001 American Society of Anesthesiologists, Inc. Lippincott Williams & Wilkins, Inc.

deviates to a larger degree with the visual axis. This modification happens to substantiate the authors' point. In fact, almost all significant findings are related to the position of this poorly defined "laryngeal axis." Three-dimensional reconstruction of the larynx might have been superior to define the laryngeal axis with a higher degree of accuracy.

I am also not convinced that the authors studied the sniffing position in all subjects. The heads of all subjects were uniformly elevated by 7 cm. Whether this degree of head elevation (cervical protrusion) is optimal for all subjects remains unanswered. In this context, it might have been helpful to correlate the degree of head elevation with cervical length or simply patient height, a parameter that unfortunately was not disclosed.

Based on these considerations, I am not convinced that Dr. Adnet *et al.*¹ have made a case good enough to challenge the clinical usefulness of the sniffing position. My bias is that the sniffing position facilitates the anterior displacement of the tongue and submental tissues and thus frees up visualization of the glottis—the most clinically relevant axis.

Michael A. Froelich, M.D., D.E.A.A., University of Florida College of Medicine, Gainesville, Florida. froelich@anestl.anestl.ufl.edu

Reference

1. Adnet F, Borron SW, Dumas JL, Lapostolle F, Cupa M, Lapandry C: Study of the "sniffing position" by magnetic resonance imaging. *ANESTHESIOLOGY* 2001; 94:83-6

(Accepted for publication May 28, 2001.)

© 2001 American Society of Anesthesiologists, Inc. Lippincott Williams & Wilkins, Inc.

vant to ease laryngoscopy or intubation, but the article by Adnet *et al.*¹ does not address this issue.

I would like to present another perspective on the sniffing position. I believe that the neutral position (no occipital support) and simple head extension (also no occipital cushion) as described in the article are not neutral, anatomic, or even desirable for induction or intubation. Most patients in the supine position are far more comfortable with several centimeters of occipital support; this is especially true for the

elderly, who are often intolerant of lying flat on the operating table without a pillow. I believe that a pillow, which incidentally approximates the sniffing position, is preferred by supine, awake patients because it is, in effect, a reconstitution of the thoracic kyphosis and cervical lordosis found in normal, relaxed, upright posture. Therefore, the sniffing position is not a unique anatomic relation; it is how we normally carry ourselves.

Cervical flexion or extension can alter airway dynamics.² It is possible that normal posture minimizes work of breathing and length of the upper airway.³ Perhaps, for this reason the same position minimizes the effort required to achieve a line of sight to the upper airway.

Anesthesiology 2001; 95:1045

To the Editor:—Adnet *et al.*¹ have produced an article that has enhanced my understanding of our favorite organ. They believed that they had not been able to demonstrate any benefit to the “sniffing position.” However, judging from their figure 1, it seems that there may be something to it. If one draws a line parallel to the line of vision (LV) and tangential to the cephalad surface of the tongue, the distance between these two lines seems to be minimal in the sniffing position. Because this is the amount of forward displacement of the soft tissue by the laryngoscope needed to visualize the larynx, could it be that a smaller distance equates with a better view? The authors almost allude to this in their second to last paragraph.

Clinically, we recognize that the compliance of submandibular soft tissue can be the limiting factor in forward displacement. Decreased compliance (from small size, inflammation, edema, autoimmune disease, burns, or radiation fibrosis) makes it more difficult and thus makes visualizing the larynx more difficult. It is not a stretch to project that ease of laryngoscopy will be compromised if the forward displacement

Anesthesiology 2001; 95:1045-6

In Reply:—We appreciate the interest shown in our article, as evidenced by the letters from Drs. Sosis, Candido *et al.*, Froelich, Weinberg, and Lee, regarding the “sniffing position” studied using magnetic resonance imaging.¹ The commentators insist on the need for a clinical (rather than anatomic) evaluation of the sniffing position. First, our study was not intended to evaluate the sniffing position for improvement of the laryngoscopic view during general anesthesia. Our goal was only to demonstrate that the alignment of anatomic axes, as defined by Bannister and Macbeth,² was impossible in any of the three head positions tested. We agree with Dr. Sosis that the sum of α and β was numerically lowest in the sniffing position; however, this value was far from zero. Our conclusion that the sniffing position offers no improvement over simple head extension *in terms of anatomic alignment of LA, PA, and MA* has been challenged because the commentators believe that it does not correspond with the laryngoscopic view. This has no relevance in relation to our study. Again, our goal was not to evaluate the ability of head positioning to facilitate laryngoscopy (and intubation).

The pharyngeal axis is defined in our study as a line joining the anterior portion of the atlas and C2 (as illustrated in figs. 1A-C in the article), which corresponds to the axes drawn (but not defined) in the illustrations of Bannister and Macbeth,² who drew the pharyngeal axis as a line parallel to the posterior wall of the pharynx. We agree with Dr. Candido *et al.* that any head extension from the neutral position on a flat surface will inevitably result in a degree of neck

Anesthesiology, V 95, No 4, Oct 2001

Guy L. Weinberg, M.D., Chicago VA Hospital, Westside Division, Chicago, Illinois. guyw@uic.edu

References

1. Adnet F, Borron SW, Dumas JL, Lapostolle F, Cupa M, Lapandry C: Study of the “sniffing position” by magnetic resonance imaging. *ANESTHESIOLOGY* 2001; 94:83-6
2. Amis TC, O'Neill N, Wheatley JK: Oral airway flow dynamics in healthy humans. *J Physiol* 1999; 1515:293-8
3. Thut DC, Schwartz AR, Roach D, Wise RA, Permutt S, Smith DL: Tracheal and neck position influence upper airway airflow dynamics by altering airway length. *J Appl Physiol* 1993; 75:2084-90

(Accepted for publication May 28, 2001.)

© 2001 American Society of Anesthesiologists, Inc. Lippincott Williams & Wilkins, Inc.

You Can Smell the Difference

ment of the soft tissues is less than the distance required to line up the line of vision, or, put another way, a smaller distance could be enabling.

The small scale of figure 1 of Adnet *et al.*¹ makes it hard to tell for sure, so confirmation of this requires measurement of the full-scale images.

Laurence W. Lee, M.D., F.R.C.P.C., Vancouver General Hospital and Health Sciences Centre, Vancouver, British Columbia, Canada. lwlee@vanhosp.bc.ca

Reference

1. Adnet F, Borron SW, Dumas JL, Lapostolle F, Cupa M, Lapandry C: Study of the “sniffing position” by magnetic resonance imaging. *ANESTHESIOLOGY* 2001; 94:83-6

(Accepted for publication May 28, 2001.)

© 2001 American Society of Anesthesiologists, Inc. Lippincott Williams & Wilkins, Inc.

flexion, which we calculated (table 2 in the article) and stated in our article. We have pointed out that the principal limitation of our study was that it was performed in healthy, nonanesthetized volunteers, but we insist (as stated in the Discussion) that first, the determination of anatomic axes and their movements do not necessitate anesthesia or laryngoscopy, and second, that the original study was performed in nonanesthetized patients, apparently without a laryngoscope blade in the mouth.³ We stand by our assertion.

We were intrigued by the “new” laryngoscopic axes referred to but undefined by Candido *et al.* We are circumspect of their definition of the pharyngeal axis, but more importantly, we saw no fundamental difference between head extension and the sniffing position on the magnetic resonance images they provide (which incidentally do not illustrate the presence of a laryngoscope).

We agree with Dr. Froelich that our definition of the laryngeal axis is not standardized, but again, the goal of our study was to examine whether the axes that are used in the classic study of Bannister and Macbeth² and are disseminated through the general anesthesia literature actually contribute to anatomic alignment in the sniffing position. In the original study, the laryngeal axis is drawn as a straight line situated in the center of the larynx.² We have used the same representation of the study of Bannister and Macbeth² to define our axes. If one examines the original figure in the neutral position and our figure 1A, it seems that they have the same axes and the same angle between axes.^{1,2} The correlation between head position and weight was not evaluated in our study but is relevant to a clinical study.

Finally, contrary to what the commentators would have the reader believe, we never stated that the sniffing position is not superior to simple head extension during laryngoscopy. We have simply observed that, if such a clinical advantage exists, the anatomic explanation cannot be found in the alignment of axes, a concept widely propagated in the literature. Dr. Sosis states that perhaps a more important question for anesthesiologists is, "Does the sniffing position facilitate laryngoscopy and tracheal intubation?" We are pleased that Dr. Sosis recognizes that we did not attempt to answer this question in the study. However, we have recently completed a randomized clinical trial to attempt to answer this question in 456 anesthetized surgical patients, which will be published in an upcoming issue of ANESTHESIOLOGY.

Frédéric Adnet, M.D., Ph.D., Service d'Aide Médicale Urgente (SAMU 33), Hôpital Avicenne, Bobigny, France. frederic.adnet@avc.ap-hop-paris.fr

References

1. Adnet F, Borron SW, Dumas JL, Lapostolle F, Cupa M, Lapandry C: Study of the "sniffing position" by magnetic resonance imaging. ANESTHESIOLOGY 2001; 94:83-6
2. Bannister FB, Macbeth RG: Direct laryngoscopy and tracheal intubation. Lancet 1944; 2:651-4
3. Adnet F, Borron SW, Lapostolle F, Lapandry C: The three axis alignment theory and the "sniffing position": Perpetuation of an anatomical myth? ANESTHESIOLOGY 1999; 91:1964-5

(Accepted for publication May 28, 2001.)

Anesthesiology 2001; 95:1046

© 2001 American Society of Anesthesiologists, Inc. Lippincott Williams & Wilkins, Inc.

Nitroglycerine and Sphincter of Oddi Spasm

To the Editor:—It was interesting to read the case report of Toyoyama *et al.*¹ An old problem and treatment has resurfaced. Twenty-eight years ago, when I started my practice at Boston's Lahey Clinic, I first learned of this problem. We performed numerous biliary reconstructive procedures as well as cholecystectomies. Usually, these patients were premedicated with a barbiturate, an opioid, and atropine. Frequently, after morphine administration and at the time of arrival in the preoperative area, the patients experienced abdominal pain, nausea, and emesis. The diagnosis of biliary colic was made. This was seen less frequently with meperidine, and to a lesser degree with fentanyl.

We gave the patients a few drops of water sublingually to moisten the mucous membranes, followed by one sublingual 1150 nitroglycerin tablet. Within 1 min or less, the symptoms subsided. It was standard practice to administer the nitroglycerin tablet as described

whenever we encountered biliary spasm during intraoperative cholangiograms.

Today, many surgeons encountering this problem request intravenous glucagon, which takes several minutes to be effective, if at all. Glucagon and a nitroglycerin drip are costly. It would be worthwhile to reconsider this old method because it is simple and inexpensive.

David A. Bittar, M.D., Mercy Hospital, San Diego, California. susandavidbittar@netscape.net

Reference

1. Toyoyama H, Kariya N, Hase I, Toyoda Y: The use of intravenous nitroglycerin in a case of spasm of the sphincter of Oddi during laparoscopic cholecystectomy. ANESTHESIOLOGY 2001; 94:708-9

(Accepted for publication May 22, 2001.)

No financial support was involved in this work.