

Tracheal Tear Caused by Extubation of a Double-Lumen Tube

Jonathan L. Benumof, M.D.,* Dickson Wu, M.D.†

A COMPLETE tear of the posterior membrane of the trachea due to extubation of a single-lumen (SLT) or double-lumen tube (DLT) has never been described. The facts of the case reported herein show that extubation of a DLT in a patient with persistent complete collapse of the left upper lobe likely caused a 7-cm long, clean, midline tear of the posterior membrane of the trachea.

Case Report

The patient was a 76-yr-old, 153-cm, 63-kg woman who had the appearance of two new 1-cm opacifications in the left lung and was scheduled for thoracoscopic lung biopsy. The patient was on no medications, was allergic to erythromycin, had a remote history of hysterectomy, and had no significant present medical problems. On physical examination, the patient appeared frail, but all organ symptoms functioned within normal limits, and all laboratory values were within normal limits.

General anesthesia was induced with 2 mg/kg intravenous propofol, 5 µg/kg fentanyl, and 0.05 mg/kg midazolam and was maintained with 0.5-1.0% isoflurane. Paralysis was induced with 0.1 mg/kg vecuronium. After paralysis, a styletted, 8.0-mm inside diameter SLT was easily inserted (the tip of the stylet was 2 cm from the tip of the SLT and was entirely intraluminal) with the aid of conventional laryngoscopy to a depth of 20 cm at the incisors, and fiberoptic bronchoscopy (5.0-mm outside diameter) revealed a normal tracheobronchial tree. The distal 7 cm of the trachea was available for inspection. Next, a 35-French, left-sided, relatively blunt-tipped DLT (Catalog #95895; Mallinkrodt Medical, St. Louis, MO) with stylet was inserted. The stylet was entirely within the left lumen and was removed as soon as the left endobronchial cuff passed the vocal cords and before the 90° counterclockwise rotation of the DLT. Unilateral clamping and auscultation maneuvers revealed normal breath sounds and cannulation of the left lung with the endobronchial lumen of the DLT. Fiberoptic bronchoscopy (4.0-mm outside diameter) through the tracheal lumen revealed that withdrawal of the DLT by 2 cm was required in order to place the blue endobronchial cuff just below the tracheal carina. With the blue endobronchial cuff just below the tracheal carina, the distal 4 cm of the trachea was visualized and was found to be normal. Both tracheal and endobronchial cuffs were inflated so that the pilot balloons were soft (significantly compressible between the fingers with minimal effort), and there was no air leak by either cuff at a pressure of 30 cm H₂O, as demonstrated by auscultation.

The patient was disconnected from the ventilator and then easily turned to the right lateral decubitus position without deflation of the softly inflated cuffs and without any movement of the head and neck. For the next 75 min, only the right lung was ventilated with a tidal volume of 500 ml, a respiratory frequency of 12 breaths/min, a peak inspiratory pressure of 30 cm H₂O, and a fraction of inspired oxygen of 1.0. During these 75 min, the surgeon biopsied and stapled shut a site in the lingula and left lower lobe. Prior to withdrawing the thoracoscope, an attempt was made to expand the collapsed left lung with a large tidal volume and sustained peak inspiratory pressure of 40 cm H₂O for 10 s. However, the left upper lobe (LUL) remained completely atelectatic. The LUL remained collapsed after both conventional suctioning down the left lumen of the DLT and after saline lavage and suctioning of thick, bloody secretions in the LUL through a fiberoptic bronchoscope (4.0-mm outside diameter) in the left lumen of the DLT.

Next, the patient was disconnected from the ventilator and easily turned to the supine position with both pilot balloons to the cuffs of the DLT still softly inflated and without any movement of the head and neck. The patient was then reventilated with manual positive pressure ventilation for 2 min. The cuffs of the DLT were then completely deflated, and the DLT was withdrawn. During extubation of the DLT, no resistance to pulling the DLT out was noted. An 8.0-mm inside diameter, styletted SLT was easily inserted once again to a 20-cm depth at the incisors, and the cuff was inflated so that the pilot balloon was soft and no leak auscultated over three manual breaths. Fiberoptic bronchoscopy (5.0-mm outside diameter) down the new and second SLT (in order to lavage and suction the LUL) very surprisingly revealed a 7-cm long, complete, midline, clean tear of the membrane of trachea that began 2 or 3 mm above the carina and ended 7 cm cephalad. The distal 1 cm of the tear veered slightly to the right. Along the entire length of the tear, the esophagus could be seen to be bulging slightly into the lumen of the trachea. The peak inspiratory pressure was reduced to 12 cm H₂O, the respiratory frequency was increased to 20 breaths/min, and the LUL was quickly lavaged and suctioned with a larger fiberoptic bronchoscope.

A right trapdoor thoracotomy with slight left lateral body tilt was performed, the SLT was guided both fiberoptically and from within the chest into the left mainstem bronchus, and the tracheal tear was repaired by primary suture and secondary reinforcement with a pericardial flap. During the repair of the trachea, the tissues of the trachea were felt to be of normal strength and integrity. At the end of the repair of the tracheal tear, the distal end of the SLT was positioned just proximal to the proximal end of the sutured tear, and the patient was sent to the intensive care unit for postoperative mechanical ventilation. Pathologic diagnosis of the biopsy specimens was benign granuloma.

The patient was mechanically ventilated and bronchoscoped daily for 1 month prior to extubation. For the next month after the initial extubation, the patient had repeated bouts of aspiration and required reintubation and mechanical ventilation three times. After the third reintubation, the patient had a tracheostomy. Nevertheless, she died 4 months later, malnourished and septic (perhaps from infection around a jejunostomy feeding tube).

Discussion

The tracheal tear most likely occurred between the end of the thoracoscopy and the insertion of the second SLT. There are two very important reasons why the

* Professor of Anesthesia, Department of Anesthesiology, University of California San Diego Medical Center. † Assistant Professor of Anesthesia, Department of Anesthesia, Rush North Shore Medical Center, Rush Medical College.

Received from the Department of Anesthesiology, University of California San Diego Medical Center, San Diego, California; and the Department of Anesthesia, Rush North Shore Medical Center, Rush Medical College, Chicago, Illinois. Submitted for publication December 10, 2001. Accepted for publication March 19, 2002. Support was provided solely from institutional and/or departmental sources.

Address reprint requests to Dr. Benumof: Department of Anesthesiology, University of California San Diego Medical Center, 402 Dickinson Street, San Diego, California 92103-8812. Address electronic mail to: jbenumof@ucsd.edu. Individual article reprints may be purchased through the Journal Web site, www.anesthesiology.org.

tracheal tear could not have been present during and at the end of the thoracoscopy. First, when the DLT was first inserted in the supine position, the distal 4 cm of the trachea appeared normal. Second, it is extremely unlikely that the patient could survive 75 min of positive pressure ventilation with a peak inspiratory pressure of 30 cm H₂O in the lateral decubitus position without any air entering the mediastinum; indeed, the surgeon had a good view of the mediastinum, and no abnormality was noted.

The tracheal tear had to be present prior to the insertion of the second SLT. As soon as the second SLT was easily inserted and after approximately three manual positive pressure ventilations at a fraction of inspired oxygen of 1.0, almost all of the tracheal tear was visualized below the tip of the second SLT.

Only two events occurred between the end of the thoracoscopy and the insertion of the SLT—the patient was turned to the supine position, and the DLT was extubated from the trachea. It is very unlikely that turning the patient to the supine position caused the tear, because it was easily and gently accomplished, with no movement of the head and neck, and the pilot balloons of both cuffs were soft. Following the turn to the supine position, no abnormalities in positive pressure ventilation through the DLT were noted for the next 2 min.

Consequently, from a timing point of view, the extubation of the DLT very likely caused the tracheal tear. We hypothesize that the loss of left hemithorax volume due to LUL collapse pulled the posterior membrane of the trachea tight in the carinal area so that the posterior membrane lost its normal distensibility. During extubation, the tip of the relatively blunt left endobronchial lumen most likely rotated posteriorly enough to penetrate the now taut posterior membrane and slice its way through the membrane until the normal distensibility of

the membrane and rotation of the DLT allowed the tip of the left lumen to disengage from the membrane. In support of this hypothesis, a midline incision into a posterior membrane that is pulled to the left would be expected to veer to the right after relaxation of the posterior membrane by the incision (and/or subsequent reexpansion of the LUL). Furthermore, the midline incision appeared sharp and clean as opposed to the cuff-induced tears, which tend to appear ragged, bleed, and occur at the right junction of the membrane and the tracheal cartilages.¹

Heretofore, the parts of the DLT that have been considered to be culprits for tracheobronchial tree damage have been the endobronchial tip on intubation, a projecting stylet from the endobronchial lumen, and over-inflation of either of the DLT cuffs (including diffusion of nitrous oxide into the cuff).¹⁻³ This case is important because it suggests that extubation of a DLT in the presence of a complete lobar collapse may also create a risk for a tracheal tear. This makes sense because it seems logical that the tip of the DLT would have just as much a chance of causing damage in an area of pathology going in one direction as in the other direction. In this case, the pathology (complete LUL collapse causing loss of distensibility of the posterior membrane in the carinal region) was created post-DLT intubation and pre-DLT extubation. Experiments in animals under these specific conditions will be necessary to more precisely define the risks of such pathology.

References

1. Marty-Ane CH, Picard E, Jonquet O, Mary H: Membranous tracheal rupture after endotracheal intubation. *Ann Thorac Surg* 1995; 60:1367-71
2. Fitzmaurice BG, Brodsky JB: Airway rupture from double-lumen tubes. *J Cardiothorac Vasc Anesth* 1999; 13:322-9
3. Kaloud H, Smolle-Juettner FR, Prause G, Franz W: Iatrogenic ruptures of the tracheobronchial tree. *Chest* 1997; 112:774-8

Thoracic Motor Paralysis Secondary to Zoster Sine Herpete

Russell K. McAllister, M.D.,* Stanley E. Borum, M.D.,* Derek T. Mitchell, M.D.,† Timothy M. Bittenbinder, M.D.*‡

POSTHERPETIC neuralgia rarely presents as a motor deficit.¹⁻³ Even more unusual is its presentation without a history of the typical rash in the distribution of the pain (zoster sine herpete).^{4,5} We present what we believe to be an extremely rare case of zoster sine herpete with significant motor involvement.

Case Report

A 63-yr-old white man presented to the chronic pain clinic for evaluation of left-sided midabdominal and flank pain. The pain had begun approximately 2 months prior, and the patient had noticed a small "soft tissue mass" in his midabdominal area that had been gradually increasing in size. He complained of burning pain and hyperesthesia in the distribution of the bulge. A surgeon had been consulted for evaluation of what was initially thought to be a lipoma. The surgeon noted that the area had the appearance of a surgically denervated muscle, but the patient had never had surgery in this region. The patient was referred to the chronic pain clinic for further evaluation.

On physical examination, the abdominal wall was noted to be markedly asymmetric, with what appeared to be a soft mass in the left T10 distribution (fig. 1). The mass was slightly tender when palpated. No rash, vesicular eruptions, or cutaneous scarring was noted. The patient was asked to perform a Valsalva maneuver, which caused the affected area to become firm and to diminish in size. Hyperesthesia was noted in the left T10 distribution. The sensory examination was otherwise normal.

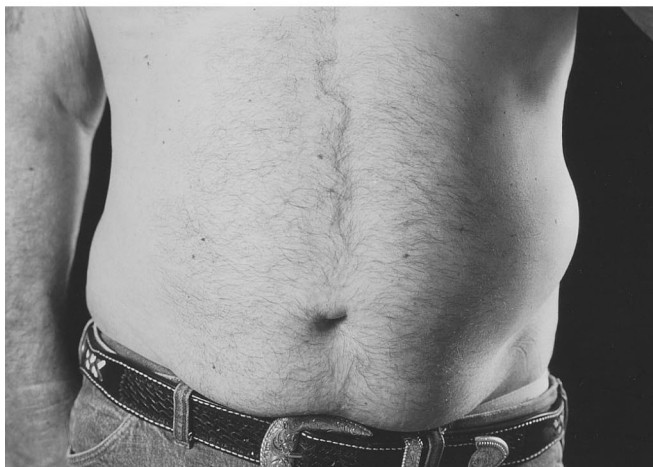Abdominal computed tomography performed previously did not show any pathologic processes, including hematoma, lipoma, or other tumor masses. Further workup included thoracic spine magnetic resonance imaging, which revealed no evidence of nerve root impingement that might explain the thoracic nerve root symptoms. Serologic studies showed that the patient had positive anti-varicella-zoster virus (VZV) immunoglobulin G titers but was negative for anti-VZV immunoglobulin M. Electromyography to evaluate the external abdominal oblique, internal abdominal oblique, rectus abdominus, and thoracic paravertebrals revealed membrane irritability in the form of positive waves and fibrillations in all of the muscle groups on the left, most prominently in the T10 distribution. Motor unit action potentials were present but were decreased in number, although the configuration and amplitude appeared essentially normal.

* Assistant Professor, † Anesthesiology Resident, ‡ Department Chairman.

Received from the Department of Anesthesiology, Scott & White Clinic and Memorial Hospital, Scott, Sherwood, and Brindley Foundation, The Texas A&M University Health Science Center College of Medicine, Temple, Texas. Submitted for publication November 9, 2001. Accepted for publication April 4, 2002. Support was provided solely from institutional and/or departmental sources. Presented at the Scott & White Memorial Hospital and The Texas A&M University Health Science Center College of Medicine Tenth Annual Anesthesia Clinical Update and Resident Research Day, Temple, Texas, April 7, 2001.

Address reprint requests to Dr. McAllister: Department of Anesthesiology, Scott & White Clinic, 2401 South 31st Street, Temple, Texas 76508. Address electronic mail to: rmcallister@swmail.sw.org. Individual article reprints may be purchased through the Journal Web site, www.anesthesiology.org.

A



B



Fig. 1. (A) Frontal view of the patient at the time of presentation. Note abdominal wall asymmetry. (B) Side view of the patient at the time of presentation.

A presumed diagnosis of zoster sine herpete (shingles without cutaneous eruption) with thoracic motor involvement was made. The patient's soft tissue mass actually represented an area of thoracic intercostal and abdominal musculature with motor paralysis secondary to VZV. Treatment with a series of thoracic epidural steroid injections, gabapentin, and nortriptyline resulted in a significant resolution of his pain.

A physical examination at 6 months revealed that the patient's thoracic motor paralysis had almost completely resolved. He also reported nearly complete resolution of the burning pain and hyperesthesia. A follow-up electromyogram performed 5 months after the initial study revealed motor unit action potentials that were essentially normal in overall number, amplitude, duration, and firing pattern. Membrane irritability in the T10 distribution was also dramatically improved.

Discussion

Varicella-zoster virus is responsible for chickenpox, during the primary infection, and shingles, during reactivation episodes later in life.⁶ Following primary infection, the virus remains latent in the dorsal root ganglia of the nervous system. Its reactivation gives rise to shingles (herpes zoster), which is usually characterized by unilateral neuralgia followed by a vesiculobullous eruption in a dermatomal distribution.⁶ The incidence of shingles is known to be higher in the elderly (> 55 yr old), in the immunocompromised, and in those originally infected prior to 1 yr of age.⁷

Rarely, patients experience shingles without the zosteriform rash (zoster sine herpette). Lewis⁵ described 120 patients that experienced "zoster-type" pain without a rash in a dermatomal distribution distant from a dermatome with a rash. There have been few well-documented cases of zoster sine herpette that have been virologically shown to be caused by VZV.⁴

Virologic evidence of herpes zoster is difficult to obtain due to a lack of specificity, and because most cases are diagnosed based on clinical features.⁶ Positive anti-VZV immunoglobulin G antibodies represent previous exposure. Positive anti-VZV immunoglobulin M antibodies are suggestive, but not specific, for herpes zoster.⁶ Sundqvist⁸ showed that increases in anti-VZV immunoglobulin M, due to zoster, are transient. In a study of 25 patients, 21 were positive for VZV immunoglobulin M; however, only one patient was still positive 46 days after the illness. Therefore, it is not surprising that the immunoglobulin M serologic results were negative in this patient, since the delay in diagnosis resulted in the serologic results not being obtained until approximately 70 days after the onset of his illness. Dahl *et al.*⁹ reported that the specificity of clinical diagnosis of zoster (with a rash) is 95% and, therefore, laboratory confirmation is not always required. The specificity of clinical diagnosis in zoster sine herpette is unclear.

Herpes zoster usually affects sensory nerves; however, it can also damage motor neurons. The incidence of motor involvement with VZV reactivation has been estimated to be 0.5^{2,10} to 5%.^{1,3} The electromyographic findings seen with thoracic motor paralysis are identical to those observed in our patient, with positive waves and fibrillations seen in the affected muscle groups.¹¹ Documented cases most commonly have involved cranial nerves; however, there are also reports of abdominal, diaphragmatic, and lower extremity paralysis.¹²⁻¹⁵ Yaszay *et al.*¹⁶ describe unilateral left C5-C6 segmental paresis associated with a zoster rash in an otherwise healthy individual.

The true incidence of thoracic motor paralysis with herpes zoster is unknown. Thomas and Howard³ reviewed 1,210 patients with herpes zoster, 61 of whom were found to have zoster-induced segmental muscle

weakness. The thoracic dermatome was involved in only two of these cases. Although the thoracic dermatome seems to be the most frequently affected in herpes zoster, it appears to have the lowest incidence of motor paralysis.⁸ This apparent low incidence may be misleading due to the fact that segmental weakness of intercostal and abdominal muscles is likely to pass unnoticed.^{8,10}

Motor paralysis secondary to herpes zoster appears to have a relatively good prognosis for recovery. Complete or nearly complete recovery has been reported in 50-70% of cases.^{2,3,10} Our patient demonstrated nearly complete resolution of his sensory symptoms and motor paralysis over a 5-month period, as evidenced by resolution of the abdominal wall asymmetry.

The differential diagnoses entertained in this case included soft tissue tumor mass (including lipoma or cyst), herniation of abdominal musculature, abdominal muscle hematoma, and lower motor neuron lesion. Tumor mass, hematoma, and muscle herniation were excluded by physical examination and abdominal computed tomography scan. Causes of lower motor neuron injury could include surgical injury, trauma, cutaneous nerve entrapment, or thoracic nerve root injury due to neural foraminal stenosis, compression fracture, or herniated nucleus pulposus. The patient had no history of surgery or trauma to the area, and magnetic resonance imaging revealed no evidence of thoracic nerve root injury. Cutaneous nerve entrapment is most commonly found in patients who have had previous surgery.¹⁷ Entrapment of these cutaneous nerves is typically noted as intermittent pain in the lateral rectus abdominis musculature with a single painful trigger point on palpation.¹⁸ A literature search revealed no descriptions of cutaneous nerve entrapment in the external or internal oblique musculature. As stated previously, electromyographic evaluation of our patient revealed involvement of the internal and external oblique, rectus abdominis, and thoracic paravertebral musculature, making cutaneous nerve entrapment an unlikely diagnosis.

As discussed, diagnoses of zoster sine herpette are most often made clinically given the difficulty of obtaining serologic evidence. Clinical evidence suggests that our patient had both zoster sine herpette and thoracic motor paralysis secondary to herpes zoster. A literature search revealed that no similar cases have been reported. In this case, serologic evidence is consistent with, but not diagnostic of, herpes zoster. The clinical symptoms of pain and thoracic motor involvement, as documented by electromyography, further strengthen the validity of the diagnosis. The patient's rapid recovery over 5 months is also consistent with the natural course of zoster motor paralysis.^{2,3,10} We believe that thoracic motor paralysis secondary to zoster sine herpette is a rare diagnosis. However, as mentioned previously, this diagnosis may be more common than is apparent due to the difficulty in diagnosing each occurrence.^{8,10}

The authors thank John C. Hendricks, M.D. (Associate Professor, Department of Surgery, Scott & White Memorial Hospital, Texas A&M University, Temple, Texas), for referral; John A. Schuchmann, M.D. (Associate Professor and Chairman, Department of Physical Medicine and Rehabilitation, Scott & White Memorial Hospital, Texas A&M University, Temple, Texas), for electromyographic evaluation; and Jolene D. Bean-Lijewski, M.D. (Associate Professor, Department of Anesthesiology, Scott & White Memorial Hospital, Texas A&M University, Temple, Texas), and Jeff R. Gibson, M.D. (Assistant Professor, Department of Anesthesiology, Scott & White Memorial Hospital, Texas A&M University, Temple, Texas), for valuable comments in the preparation of this manuscript.

References

- Grant BD, Rowe CR: Motor paralysis of the extremities in herpes zoster. *J Bone Joint Surg Am* 1961; 43A:885-96
- Gupta SK, Helal BH, Kiely P: The prognosis in zoster paralysis. *J Bone Joint Surg Br* 1969; 51:593-603
- Thomas JE, Howard FM Jr: Segmental zoster paresis—a disease profile. *Neurology* 1972; 22:459-66
- Gilden DH, Dueland AN, Devlin ME, Mahalingam R, Cohrs R: Varicella-zoster virus reactivation without rash. *J Infect Dis* 1992; 166(suppl 1):S30-4
- Lewis GW: Zoster sine herpette. *BMJ* 1958; 2:418-21
- Arvin AM: Varicella-zoster virus. *Fields Virology*, 3rd edition. Edited by Fields BN, Knipe DM, Howley PM. Philadelphia, Lippincott-Raven, 1996, pp 2547-85
- Tranoy E, Berger R, Hollander G, Bailleux R, Heimendinger P, Vuillier D, Creusvaux H: Vaccination of immunocompetent elderly subjects with a live attenuated Oka strain of varicella zoster virus: A randomized, controlled, dose-response trial. *Vaccine* 2000; 18:1700-6
- Sundqvist V: Frequency and specificity of varicella zoster virus IgM response. *J Virol Methods* 1982; 5:219-27
- Dahl H, Marcoccia J, Linde A: Antigen detection: The method of choice in comparison with virus isolation and serology for laboratory diagnosis of herpes zoster in human immunodeficiency virus-infected patients. *J Clin Microbiol* 1997; 35:347-9
- Akiyama N: Herpes zoster infection complicated by motor paralysis. *J Dermatol* 2000; 27:252-7
- Cioni R, Giannini F, Passero S, Paradiso C, Rossi S, Fimiani M, Battistini N: An electromyographic evaluation of motor complications in thoracic herpes zoster. *Electromyogr Clin Neurophysiol* 1994; 34:125-8
- Brostoff J: Diaphragmatic paralysis after herpes zoster. *BMJ* 1966; 2:1571-2
- Furuta Y, Ohtani F, Mesuda Y, Fekuda S, Inuyama Y: Early diagnosis of zoster sine herpette and antiviral therapy for the treatment of facial palsy. *Neurology* 2000; 55:708-10
- Soler JJ, Perpina M, Alfaro A: Hemidiaphragmatic paralysis caused by cervical herpes zoster. *Respiration* 1996; 63:403-6
- Spiers AS: Herpes zoster and its motor lesions, with a report of a case of phrenic nerve paralysis. *Med J Aust* 1963; 50:850-3
- Yaszay B, Jablęcki CK, Safran MR: Zoster paresis of the shoulder. Case report and review of the literature. *Clin Orthop* 2000; 377:112-8
- Hall PN, Lee AP: Rectus nerve entrapment causing abdominal pain. *Br J Surg* 1988; 75:917
- Gallegos NC, Hobsley M: Abdominal wall pain: An alternative diagnosis. *Br J Surg* 1990; 77:1167-70

Anesthesiology 2002; 97:1011-3

© 2002 American Society of Anesthesiologists, Inc. Lippincott Williams & Wilkins, Inc.

Osteogenesis Imperfecta, Perioperative Bleeding, and Desmopressin

Mark T. Keegan, M.B., M.R.C.P.I.,* Brett D. Whatcott, M.D.,† Barry A. Harrison, M.B.B.S., F.A.N.Z.C.A., F.R.A.C.P.‡

OSTEOGENESIS imperfecta (OI), also known as “brittle-bone disease,” is a genetic disorder of connective tissue that causes susceptibility to fractures. In OI, there is a 10–30% incidence of bleeding diathesis, and these individuals have an increased risk of bleeding when undergoing surgery.^{1,2} The coagulation defect is related to the effect of abnormal collagen on platelet-endothelial cell interactions and capillary strength. By its action on capillary endothelial cells, desmopressin,³ a synthetic analog of antidiuretic hormone, may improve the coagulation abnormality seen in patients with OI. We describe the use of desmopressin in a patient with OI who experienced excessive bleeding in the setting of a major surgical procedure.

Case Report

A 72-yr-old man with adenocarcinoma of the prostate and transitional cell carcinoma of the bladder presented for cystoprostatectomy.

* Assistant Professor, Department of Anesthesiology, Mayo Clinic, Rochester, Minnesota. † Chief, Department of Anesthesiology, Crawford Memorial Hospital, Van Buren, Arkansas. ‡ Assistant Professor, Department of Anesthesiology, Mayo Clinic, Jacksonville, Florida.

Received from the Department of Anesthesiology, Mayo Clinic, Rochester, Minnesota. Submitted for publication January 4, 2002. Accepted for publication April 10, 2002. Support was provided solely from institutional and/or departmental sources.

Address reprint requests to: Dr. Keegan: Department of Anesthesiology, Mayo Clinic, Charlton 1145, 200 1st Street Southwest, Rochester, Minnesota 55905. Address electronic mail to: keegan.mark@mayo.edu. Individual article reprints may be purchased through the Journal Web site, www.anesthesiology.org.

The patient had a history of OI tarda that had manifested as multiple fractures in childhood and reduced hearing on the right side. His past medical history was also significant for hypertension and bleeding hemorrhoids. There was no history of spontaneous bleeding, easy bruising, or excessive surgical bleeding. The patient was not taking aspirin or nonsteroidal antiinflammatory drugs. Physical examination revealed the presence of blue sclera, a dorsal kyphosis, and bilateral reduction in hip mobility. His prostate gland was slightly enlarged and had areas of induration at the bases and right apex. His prostate-specific antigen level was 6.9 ng/ml (reference, < 5.6). Preoperative cystoscopic examination with biopsy revealed an invasive grade 3 transitional cell carcinoma of the bladder, and prostate biopsy results were positive for adenocarcinoma of the prostate. The cardiorespiratory examination was unremarkable. The patient's preoperative platelet count was $220 \times 10^9/l$.

Standard American Society of Anesthesiologists monitors were placed. General anesthesia was induced with propofol and fentanyl and maintained with isoflurane in air and oxygen. An inline fluid warmer and Bair Hugger (Augustine Medical, Eden Prairie, MN) were used. Muscle relaxation was achieved using cisatracurium, and intermittent doses of morphine were used for analgesia. Marked vascularity and friability of the vessels complicated the dissection, leading to excessive, diffuse bleeding. Within 40 min of the incision, an estimated 1500 ml of blood had been lost, causing the patient's hemoglobin concentration to decrease from 13 g/dl (as measured preoperatively) to 8.7 g/dl. In light of the patient's hemodynamic instability and excessive, ongoing blood loss, 4 units of packed erythrocytes and 6 units of platelets were transfused. Despite this, the diffuse surgical bleeding continued, but no other bleeding sites were identified. Twenty minutes after administration of the platelets, 0.3 $\mu\text{g}/\text{kg}$ (total dose, 22 μg) desmopressin acetate was administered in an effort to improve platelet function and to decrease blood loss. The drug was infused over 20 min to avoid severe hypotension. Within minutes of

the infusion, the excessive, diffuse bleeding stopped. No further abnormal bleeding occurred, and the patient remained hemodynamically stable for the remainder of the procedure. In total, the patient received 6 units of packed erythrocytes, 6 units of platelets, 500 ml of 5% albumin, 500 ml hetastarch, and 5,600 ml lactated Ringer's solution. At the end of the case, the patient's hemoglobin concentration was 11.8 g/dl, and 4 h later his hemoglobin concentration was 11.2 g/dl, his platelet count was $199 \times 10^9/l$, his prothrombin time was 11.9 s (reference range, 8.4–12.0 s), and his activated partial thromboplastin time was 25 s (reference range, 21–33 s). Prior to the onset of bleeding, the patient's temperature was 35.9°C, and it increased to 36.6°C after the bleeding episode. The patient's recovery and postoperative course were uneventful.

Discussion

Osteogenesis imperfecta is a heterogenous group of inherited disorders of collagen type I caused by mutations of the *COL1A1* or *COL1A2* genes.⁴ Although the classic clinical description of OI is of a patient with brittle bones, blue sclera, and premature deafness, other organ systems are affected. The disease may cause cardiac valvular lesions, kidney stones, neurologic abnormalities, and metabolic derangements. In addition, the defect in collagen synthesis can cause excessive bruising and generalized oozing from wound sites. Surgical procedures performed in patients with OI carry a higher risk of bleeding complications. Laboratory investigations of patients with OI have demonstrated increased capillary fragility, decreased platelet retention, decreased levels of factor VIII, and deficient collagen-induced platelet aggregation.^{5,6} It is believed that the collagen defect results in friable tissues, small blood vessels that are unable to constrict adequately, and a defect in the platelet aggregation response around exposed subendothelium. The bleeding may occur despite normal results of coagulation studies and bleeding times, making predictions about intraoperative bleeding difficult.⁷ Coagulopathy with sudden development of widespread petechiae has been reported,⁸ as has fatal hemorrhage secondary to accidental rib fractures during spinal fusion surgery.⁹

The evaluation of platelet function and the role of platelet transfusion in OI are difficult to assess. Because OI is due to an impairment of the platelet-endothelial cell interaction, the thromboelastogram may not be useful. Indeed, we could not find a published case report regarding the use of the thromboelastogram in OI. The American Society of Anesthesiologists transfusion guidelines state, "platelet transfusion may be indicated despite an apparently adequate platelet count if there is known platelet dysfunction and microvascular bleeding."¹⁰ Bleeding time and platelet aggregation tests are not useful in the operating room,¹⁰ and "there is an urgent need for the development of clinically relevant measures of *in vivo* platelet function and bleeding risk to guide the rational use of platelet transfusion."¹¹

Desmopressin is a synthetic analog of antidiuretic hor-

mone. It has a significant antidiuretic effect mediated *via* V2 receptors and little or no vasoconstrictive effect (V1).^{3,12} The drug, mediated *via* V2 effects, causes endothelial cells to release von Willebrand factor, tissue type plasminogen activator, and factor VIII:C. Desmopressin may be used in patients with uremia, chronic liver disease, and certain types of hemophilia, in which increased release of von Willebrand factor promotes platelet adhesiveness to the vascular endothelium and, hence, increases hemostatic activity. There are conflicting reports as to the utility of desmopressin in the reduction of blood loss during operations that involve substantial bleeding. Studies involving patients undergoing coronary artery bypass grafting, spinal fusion, and hip surgery have varied in their methodology and outcome.¹³⁻¹⁶ The adverse effects associated with the use of desmopressin are few.³ They include facial flushing, headache, hypotension, tachycardia, and the possibility of thrombosis. In addition, the antidiuretic effect may increase the difficulty of assessing the intravascular volume status. There have been a few reports of hyponatremia and seizures, mostly in children.

Desmopressin works in congenital and acquired platelet disorders by increasing plasma concentrations of factor VIII, von Willebrand factor, and tissue plasminogen activator and by increasing platelet adhesiveness.^{3,12} The hemostatic effect is almost immediate after administering an intravenous dose of 0.3 $\mu\text{g}/\text{kg}$.³ Desmopressin may be useful for improving hemostasis and ultimately decreasing transfusion requirements in the surgical patient with OI. By increasing platelet deposition onto vascular subendothelium, desmopressin would seem to be an excellent adjunct to the perioperative management of patients with OI.

We cannot say definitively that desmopressin stopped the bleeding in this case, but circumstantial evidence supports this hypothesis. A review of the literature failed to reveal any previous reports of the use of desmopressin to treat the coagulopathy associated with OI. Although further investigation is warranted, due to the low incidence of OI and the difficulty in documenting the coagulopathy associated with OI, randomized, controlled trials will be difficult to perform. Qualitative tests of platelet function, performed before and after the administration of desmopressin, may help to elucidate the drug's role in this setting. However, given the relatively benign side effect profile of desmopressin and the theoretical basis for its effectiveness, consideration should be given to the use of desmopressin in patients with OI undergoing major surgery when complicated by significant microvascular bleeding.

References

1. Morton ME: Excessive bleeding after surgery in osteogenesis imperfecta. *Br J Oral Maxillofac Surg* 1987; 25:507-11

2. Siegel BM, Friedman A, Schwartz SO: Hemorrhagic disease in osteogenesis imperfecta. *Am J Med* 1957; 22:315-21
3. Lethagen S: Desmopressin (DDAVP) and hemostasis. *Ann Hematol* 1994; 69:173-80
4. Marini JC: Osteogenesis imperfecta—managing brittle bones. *N Engl J Med* 1998; 339:986-7
5. Evensen SA, Myhre L, Stormorken H: Haemostatic studies in osteogenesis imperfecta. *Scand J Haematol* 1984; 33:177-9
6. Hathaway WE, Solomons CC, Ott JE: Platelet function and pyrophosphates in osteogenesis imperfecta. *Blood* 1972; 39:500-9
7. Wong RS, Follis FM, Shively BK, Wernly JA: Osteogenesis imperfecta and cardiovascular diseases. *Ann Thorac Surg* 1995; 60:1439-43
8. Edge G, Okafor B, Fennelly ME, Ransford AO: An unusual manifestation of bleeding diathesis in a patient with osteogenesis imperfecta. *Eur J Anaesthesiol* 1997; 14:215-9
9. Sperry K: Fatal intraoperative hemorrhage during spinal fusion surgery for osteogenesis imperfecta. *Am Forensic Med Pathol* 1989; 10:54-9
10. Practice Guidelines for blood component therapy: A report by the Amer-

ican Society of Anesthesiologists Task Force on Blood Component Therapy. *ANESTHESIOLOGY* 1996; 84:732-47

11. Norfolk DR, Ancliffe PJ, Contreras M, Hunt BJ, Machin SJ, Murphy WG, Williamson LM: Consensus Conference on Platelet Transfusion, Royal College of Physicians of Edinburgh, 27-28 November 1997. *Br J Haematol* 1998; 101:609-14
12. Stoelting RK: *Pharmacology and Physiology in Anesthetic Practice*, 3rd edition. Philadelphia, Lippincott-Raven, 1999, p 424
13. Theroux MC, Corddry DH, Tietz AE, Miller F, Peoples JD, Ketrick RG: A study of desmopressin and blood loss during spinal fusion for neuromuscular scoliosis. *ANESTHESIOLOGY* 1997; 87:260-7
14. Frankville DD, Harper GB, Lake CL, Johns RA: Hemodynamic consequences of desmopressin administration after cardiopulmonary bypass. *ANESTHESIOLOGY* 1991; 74:988-96
15. Mongan PD, Hosking MP: The role of desmopressin acetate in patients undergoing coronary artery bypass surgery. *ANESTHESIOLOGY* 1992; 77:38-46
16. Guay J, Reinberg C, Poitras B, David M, Mathews S, Lortie L, Rivard GE: A trial of desmopressin to reduce blood loss in patients undergoing spinal fusion for idiopathic scoliosis. *Anesth Analg* 1992; 75:405-10

Anesthesiology 2002; 97:1013-4

© 2002 American Society of Anesthesiologists, Inc. Lippincott Williams & Wilkins, Inc.

Processed Electroencephalographic Changes Associated with Hypoglycemia during the Resection of an Insulinoma

Laurence M. Hausman, M.D.

THE Patient State Analyzer (PSA 4000; Physiometrix, North Billerica, MA) is an FDA-approved device that quantifies regional electroencephalographic data and converts them into a linear scale ("score") from 1 to 100. This score has been shown to correlate with depth of anesthesia.¹ In this report, I describe a case in which the device was instrumental in alerting the anesthesiologist to hypoglycemia.

Case Report

A 60-yr-old, 98-kg, white man presented to the operating room for a laparoscopic resection of an insulinoma. His past medical history was significant for multiple episodes of altered mental status, associated with confusion and disorientation, over a 3 to 4 month period. On each occasion, his blood glucose concentration was 30-40 mg/dl. He experienced neither seizures nor coma during these periods of profound hypoglycemia. His only medication at the time was fluvastatin (a cholesterol-lowering drug). The initial diagnostic workup revealed an inappropriately high concentration of insulin after a prolonged fast and an increased concentration of C peptide. Magnetic resonance imaging and computed tomography scan of the abdomen showed no abnormality. Despite this preoperative inability to localize the source of excess insulin, the patient was scheduled to undergo an exploratory laparoscopy, with possible resection of an insulin-secreting tumor.

Other significant past medical history included occasional gastroesophageal reflux disease and mild multiple sclerosis, causing minimal

right-sided weakness. Significant laboratory findings on the morning of surgery included a blood glucose concentration of 61 mg/dl and a potassium concentration of 4.8 mEq/l. His heart rate was 82 beats/min, and his blood pressure was 135/75 mmHg.

On arrival to the preoperative holding area, the PSA 4000 array was placed on the patient's head, and 30 ml sodium bicarbonate was given orally. He was brought into the operating room, where intravenous access was established, and an infusion of 5% dextrose in 0.9% sodium chloride was started at 100 ml/h. The device was activated, and the patient's initial PSA value was 97. The standard American Society of Anesthesiologists monitors were applied. Metoclopramide, 10 mg, and midazolam, 2 mg, were administered intravenously. After preoxygenation, a modified rapid sequence induction with 2 mg/kg propofol and 0.25 mg/kg cisatracurium was performed while maintaining cricoid pressure. The trachea was intubated approximately 90 s later.

After induction, the patient's blood pressure and heart rate remained within normal limits, and his PSA score decreased to 19. Anesthesia was maintained with 50% oxygen, 50% air, 0.2% isoflurane, and neuromuscular blockade. Several minutes later, his score increased to 38, as the effect of the induction dose of propofol diminished. His heart rate and blood pressure remained unchanged. On insertion of the urinary catheter by the surgeons, the patient's heart rate increased to 90 beats/min, and his blood pressure increased to 160/88 mmHg. Fentanyl, 250 µg, was administered intravenously. This resulted in a decrease in both heart rate and blood pressure to their baseline value. However the patient's processed electroencephalography scan remained essentially unchanged. An arterial catheter and a second intravenous catheter were placed.

Over the next 15 min, during preparation and draping of the patient, the PSA value gradually decreased to 17, and the isoflurane was discontinued. Despite this adjustment, his electroencephalography value remained essentially unchanged. During this time, there were no significant changes in heart rate or blood pressure, and the patient remained normothermic. An arterial blood sample was drawn, the analysis of which revealed a blood glucose concentration of 40 mg/dl, an arterial oxygen tension of 171 mmHg, and an arterial carbon dioxide tension of 32 mmHg. Intravenous dextrose, 12.5 g, was given rapidly. Approximately 2 to 3 min later, his PSA value increased to 48, and his blood glucose concentration was 235 mg/dl. The isoflurane was restarted at 0.2%, while the surgeons continued to prepare and drape the patient. Several minutes prior to incision, the isoflurane was titrated up

Assistant Professor of Anesthesiology.

Received from the Department of Anesthesiology, The Mount Sinai School of Medicine, New York, New York. Submitted for publication December 10, 2001. Accepted for publication April 15, 2002. The PSA 4000 machine and the head arrays were supplied by Physiometrix, North Billerica, Massachusetts. No other funds were received.

Address reprint requests to Dr. Hausman: Department of Anesthesiology, The Mount Sinai School of Medicine, 1 Gustave L. Levy Place, Box 1010, New York, New York 10029. Address electronic mail to: Laurence.Hausman@mssm.edu. Individual article reprints may be purchased through the Journal Web site, www.anesthesiology.org.

to 1.9%. The patient tolerated the incision, and the isoflurane was gradually decreased. The patient remained stable throughout the procedure and was maintained with 50% oxygen, 50% air, and isoflurane between 0.9 and 1.5%.

An infusion of 10% dextrose in water was administered intraoperatively to maintain a blood glucose concentration between 100 and 200 mg/dl. Frequent blood gas analyses were performed to direct this goal. Laparoscopy revealed a tumor of the pancreatic islet cells. After enucleation of the tumor, the patient's blood glucose concentration increased to 359 mg/dl. The 10% dextrose in water and 5% dextrose in 0.9% sodium chloride infusions were discontinued, and an infusion of a balanced salt solution was started. At the conclusion of the surgical procedure, the patient awoke, the trachea was extubated, and he was transferred to the postanesthesia care unit. In the postanesthesia care unit, his blood glucose concentration stabilized, and he was transferred to the inpatient ward later that evening. He was discharged home on the third postoperative day. The patient denied any intraoperative awareness or memory.

Discussion

There has been much controversy over glucose management during the resection of an insulinoma.²⁻⁴ Although a continuous intravenous infusion of glucose is not absolutely indicated, it is commonly used to achieve the goal of maintaining a blood glucose concentration greater than 50-60 mg/dl.⁴⁻⁶ Frequent intraoperative blood glucose measurements are necessary.⁷

Hypoglycemia can cause permanent cerebral damage.⁵ The signs of hypoglycemia include hypertension, tachycardia, sweating, change in mental status, and even bradycardia, which may be secondary to an increase in vagal tone.⁶ Many of these signs are masked by general anesthesia.^{4,7} Those available are nonspecific and have multiple etiologies. In this patient, the heart rate and blood pressure were unchanged. The only indication of possible hypoglycemia was his low PSA score. His heart rate and blood pressure remained at their baseline. The PSA score of 17 reflected a very deep anesthetic state, despite an end-tidal isoflurane of zero. The patient's blood glucose concentration at that time was 40 mg/dl, and, at this concentration, he was known to be symptomatic. Another indication that the score was affected by blood glucose concentration was its rapid increase to 48 following treatment of hypoglycemia.

The PSA 4000 monitor utilizes regional quantitative electroencephalographic data. When a general anesthetic is administered, there are regional changes in electroencephalographic activity that occur regardless of the anesthetic used.⁸ These regional electroencephalo-

graphic changes can then be quantified. A score of 100 corresponds with the awake state, whereas a score of zero corresponds with complete electroencephalographic suppression. Hypnosis during general anesthesia is reflected by a score of 25-50.

In this case, the patient's score decreased immediately on induction of anesthesia from 97 to 19. His score promptly increased to 38, indicating an adequate depth of anesthesia. However, during the period of preparation and draping, his score began to decrease to very low levels without any measurable end-tidal volatile anesthetic. The end-tidal isoflurane had been stable at 0.0%, but his score continued to decrease to well below 25. Hypoglycemia was considered as a possible cause, and the patient's blood glucose concentration was checked, confirming this etiology. When a bolus of glucose was given, the score promptly increased. Of note, hypertension and tachycardia, common signs of hypoglycemia in the anesthetized patient, were not seen. Whether these changes in vital signs would have ultimately occurred is not known.

In this case, a hypoglycemic patient had significant quantitative electroencephalographic changes, as reflected in the PSA 4000 score, while all vital signs remained within normal limits. Further studies are needed to determine if there are consistent electroencephalographic changes seen in the hypoglycemic patient, and whether these changes routinely precede alterations in hemodynamic variables.

References

1. Drover DR, Lemmens HJ, Pierce ET, Plourde G, Loyd G, Ornstein E, Prichep LS, Chabot RJ, Gugino L: Patient state index titration of delivery and recovery from propofol, alfentanil, and nitrous oxide anesthesia. *ANESTHESIOLOGY* 2002; 97:82-9
2. Tutt GO, Edes AJ, Servic FJ, van Heerden JA: Plasma glucose monitoring during operations for insulinoma. A critical reappraisal. *Surgery* 1980; 88:351-6
3. Schwartz SS, Horwitz DL, Zehfus B, Langer BG, Kaplan E: Continuous monitoring and control of plasma glucose during operation for removal of insulinomas. *Surgery* 1979; 85:702-7
4. Muir JJ, Endres SM, Offord K, van Heerden JA, Tinker JH: Glucose management in patients undergoing operation for insulinoma removal. *ANESTHESIOLOGY* 1983; 59:371-5
5. Lamont AS, Jones D: Anaesthetic management of insulinoma. *Anaesth Intensive Care* 1978; 6:261-2
6. Chari P, Pandit SK, Kataria RN, Singh H, Baheti DK, Wig J: Anaesthetic management of insulinoma. *Anaesthesia* 1977; 32:261-4
7. Roizen MF: Diseases of the endocrine system, *Anesthesia and Uncommon Diseases*. Edited by Benumof JL. Philadelphia, WB Saunders, 1998, pp 259-62
8. John ER, Prichep LS, Valdes-Sosa P, Bosch J, Aubert E, Gugino LD, Kox W, Tom M, di Michele F: Invariant reversible QEEG effects of anesthetics. *Conscious Cogn* 2001; 10:165-83

Anesthesia and Airway Management of Pediatric Patients with Smith–Lemli–Opitz Syndrome

Zenaide M. N. Quezado, M.D.,* Judith Veihmeyer, M.D.,† Lynnae Schwartz, M.D.,† Ngozi A. Nwokoro, M.D., Ph.D.,‡
Forbes D. Porter, M.D., Ph.D.§

SMITH–LEMLI–OPITZ syndrome (SLOS) is an autosomal recessive disorder with an incidence of between 1 in 26,500 pregnancies in Canada and 1 in 50,000 pregnancies in the United States.^{1,2} The syndrome results from an inborn error of cholesterol biosynthesis involving a deficiency of 3β -hydroxysterol Δ^7 -reductase, the enzyme that catalyzes the reduction of 7-dehydrocholesterol to cholesterol.^{3,4} As a result, patients with SLOS have abnormal embryonic development, high plasma concentrations of 7-dehydrocholesterol, and usually decreased plasma concentrations of cholesterol.

This biochemical defect is associated with a broad spectrum of clinical manifestations with potentially profound anesthetic implications. Patients with SLOS can have severe growth failure, congenital anomalies affecting most organ systems, early death, developmental delay, and self-injurious and ritualistic behavior.⁵⁻⁹ Of special concern to anesthesiologists are the typical dysmorphic facial features, including micrognathia, cleft palate, and a small and abnormally hard tongue, which can present a challenge in airway management of patients with SLOS.^{5,8}

The broad spectrum of congenital anomalies and potential increase in lifespan with dietary cholesterol replacement therapy make it very likely that diagnostic and therapeutic interventions requiring anesthesia will be needed in patients with SLOS. However, since the discovery of the biochemical defect in SLOS, little has been reported on the anesthetic management of these pa-

tients.¹⁰ In this report, we describe the administration of 20 anesthetics in 14 patients with confirmed biochemical diagnosis of SLOS. Our focus was on airway management, and because of previous reports of difficult intubations in some of our patients, we chose to use fiberoptic laryngoscopy as the initial technique to achieve tracheal intubation.

Report of Cases

We reviewed the anesthetic management of 14 children who were enrolled in ongoing investigations of the clinical, molecular, and biochemical features of SLOS and received 20 general anesthetics from July 2000 to February 2002. The investigation protocol was approved by the National Institutes of Child Health and Development Institutional Review Board. Clinical diagnosis was confirmed biochemically in all patients (table 1).

Demographics, including the SLOS severity score¹¹ of the 14 children, are listed in table 1. Additional details on the patients and anesthetics reported here are available on the ANESTHESIOLOGY Web site, <http://www.anesthesiology.org>. Figure 1 depicts a 9-month-old infant with SLOS and features of Pierre Robin sequence (micrognathia, glossoptosis, and high-arched and cleft soft and hard palates) who was anesthetized at 3, 9, and 15 months of age. Six patients had a history of gastroesophageal reflux predominantly associated with feedings (table 1). However, once on metoclopramide, H₂ blocker, and H⁺-K⁺ ATPase inhibitor, these patients had no clinical signs of gastric reflux. In addition, despite the history of gastric reflux, no episode of aspiration pneumonia was recorded in any of our patients. Eight patients had gastric tubes through which they were fed exclusively (table 1). Patient 9 had a history of hypertension that was treated with a calcium channel blocker. Five patients (table 1) had a documented history of difficult intubation, as described by anesthesiologists who had previously performed direct laryngoscopies. In patient 9, a previous anesthetic was aborted because we were unable to intubate after induction of anesthesia.

In this series, one anesthesiologist administered all of the anesthetics and performed all of the endotracheal intubations, with the exception of one (table 2). All patients had solids or formula discontinued 8 h before induction of anesthesia, but clear liquids were allowed for up to 3 h before induction of anesthesia. Only patient 4, an 8-yr-old boy with aggressive behavior, required premedication with oral midazolam (0.4 mg/kg) and ketamine (10 mg/kg), which yielded effective sedative effects. In patients with gastric tubes, the stomach was emptied immediately prior to induction of anesthesia.

The ability to mask ventilate was established, and intravenous access was obtained. One patient had intravenous induction with sodium thiopental. All patients had documented easy mask ventilation without oropharyngeal airways. During fiberoptic laryngoscopy and endotracheal intubation, most patients were spontaneously ventilating, and the inspired concentration of oxygen was increased to 100%. Overall, during induction of anesthesia and tracheal intubations, oxygen saturation was maintained above 99% in all patients. In two patients (patients 2 and 13), mivacurium was given just prior to the insertion of the endotracheal tube in the trachea. Succinylcholine was administered to treat one episode of laryngospasm that was evident during

Additional material related to this article can be found on the Anesthesiology Web site. Go to the following address, click on the Enhancements Index, and then scroll down to find the appropriate article and link. <http://www.anesthesiology.org>

*Associate Professor of Anesthesia, Children's National Medical Center, George Washington University, and Staff Physician, Department of Anesthesia and Surgical Services, Warren Magnuson Clinical Center. †Staff Physician, Department of Anesthesia and Surgical Services, Warren Magnuson Clinical Center, ‡Clinical Fellow, §Investigator, Heritable Disorders Branch, National Institute of Child Health and Human Development, National Institutes of Health.

Received from the Department of Anesthesia, Children's National Medical Center, George Washington University, Washington, DC; and the Department of Anesthesia and Surgical Services, Warren Magnuson Clinical Center, and the Heritable Disorders Branch, National Institute of Child Health and Human Development, National Institutes of Health, Bethesda, Maryland. Submitted for publication December 14, 2001. Accepted for publication April 16, 2002. Supported by intramural funding from the National Institutes of Health.

Address reprint requests to Dr. Quezado: Department of Anesthesia and Surgical Services, Warren Magnuson Clinical Center, National Institutes of Health, Building 10, Room 2C624, 10 Center Drive, MSC 1512, Bethesda, Maryland 20892. Address electronic mail to: zquezado@nih.gov. Individual article reprints may be purchased through the Journal Web site, www.anesthesiology.org.

Table 1. Demographics, Congenital Anomalies, and Diagnostic Plasma Sterol Levels in a Series of Patients with Smith-Lemli-Optiz Syndrome

Patient (Gender)	Age* (mo)	Weight, Kg (percentile)	Severity Score†	Congenital Heart Disease	GERD	Gastric Tube	Hypotonia	Cleft Palate	Micrognathia	Plasma Sterol Levels (normal values, mg/dL)	
										Cholesterol (100–200)	7-DHC (0.01 ± 0.005)
1 (F)	7	5 (<3 rd)	28	PDA	Y	Y	Y		Y	56	27.3
2 (F)	29	10 (<3 rd)	17	PDA, Aorta coarctation		Y	Y		Y	70	13.5
3 (M)	13	8 (<3 rd)	11	Pulmonary stenosis			Y		Y	65	12.6
4 (M)	96	25 (50 th)	11							195	0.07
5 (M)	18	7 (<3 rd)	6				Y		Y	89	12.2
6 (M)	4	6 (25 th)	11		Y	Y	Y		Y	72	8.5
7 (F)	3	3 (<3 rd)	33		Y		Y	Y	Y	8	23.7
8 (M)	9	6 (<3 rd)	6			Y	Y		Y	36	12.8
9 (F)	25	6 (<3 rd)	31	ASD		Y	Y		Y	83	15
10 (M)	27	10 (<3 rd)	6				Y		Y	114	5.4
11 (M)	8	7 (<3 rd)	33		Y	Y	Y		Y	31	13.9
12 (F)	11	5 (<3 rd)	11		Y	Y	Y		Y	20	7.8
13 (M)	39	12 (3 rd)	11				Y		Y	73	6.2
14 (F)	26	8 (<3 rd)	39	ASD	Y	Y	Y	Y	Y	21	13.7

* Age at the first anesthetic in this series. † Severity scores are based on the presence of malformations in each of 10 embryologically distinct areas.¹¹

Scores greater than 50 reflect severe disease, 25–50 reflect moderate or typical disease, and less than 25 reflect mild disease.

F, female; M, male; PDA, patent ductus arteriosus; ASD, atrial septal defect; GERD, gastroesophageal reflux disease; Y, yes (showing that the characteristic is present).

fiberoptic laryngoscopy (patient 5). All endotracheal intubations were electively performed with fiberoptic bronchoscopes (model BF-XP40 [outside diameter, 2.8 mm] for endotracheal tubes sized 3.5 or above and model LF-P [outside diameter, 2.2 mm] for those sized 3 and below, Olympus America, Melville, NY). In patients undergoing oral and dental examinations (six anesthetics), the endotracheal tube was inserted nasally, whereas in those undergoing only imaging studies, it was inserted orally (14 anesthetics). We used cuffed endotracheal tubes for 8 anesthetics and uncuffed tubes for the remaining 12 anesthetics. Most children required a smaller sized endotracheal tube than that predicted for their age (table 2).

In 19 anesthetics, fiberoptic laryngoscopy was the technique chosen for tracheal intubation from the outset. In one anesthetic, four direct laryngoscopies were performed, and an otolaryngologist was consulted to perform indirect laryngoscopy and thereby intubate the

trachea. All intubations were performed successfully and without trauma to the airway. The agents used in the maintenance phase of the anesthetics are listed in table 2. At the completion of all procedures, the patients were extubated. Only patient 7, when administered the first anesthetic, presented airway obstruction after extubation that was relieved with a nasopharyngeal airway. There were no episodes of oxygen desaturation, bradycardia, witnessed aspiration, or aspiration pneumonia.

Discussion

Given the relatively high incidence, presence of multiple congenital malformations, expansion of the pheno-

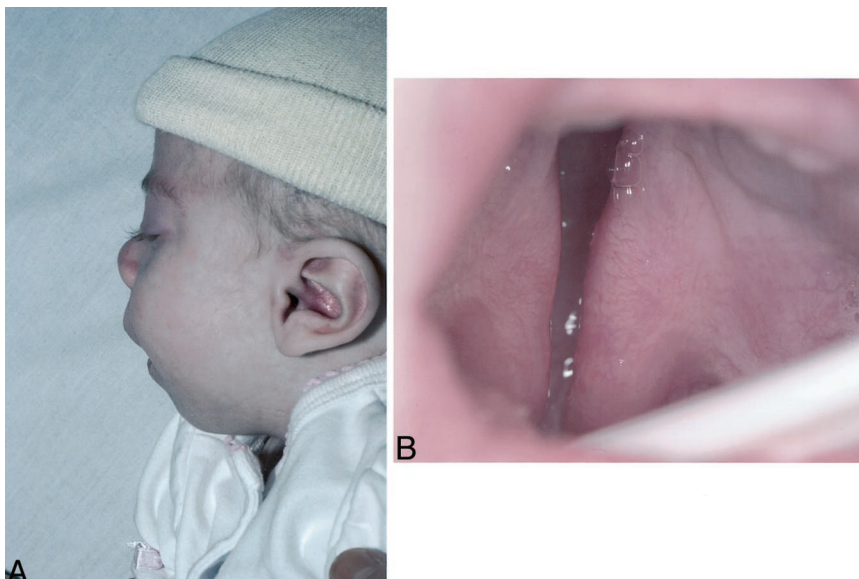


Fig. 1. (A) Nine-month-old infant with Smith-Lemli-Optiz syndrome presenting features associated with Pierre Robin sequence, including micrognathia, cleft palate (B), and pseudomacroglossia.

Table 2. Series of 20 Anesthetics in Patients with Smith-Lemli-Optiz Syndrome

Patient	History of Difficult Intubation*	Procedures	Induction Agents	Endotracheal Tube Size	Maintenance Agents	Comments
1	Y	Eye muscle surgery	Thiopental Vecuronium	3.5 Uncuffed	N ₂ O, Desflurane	Tracheal intubation by an otolaryngologist
1	Y	Brain MRI, spectroscopy	N ₂ O, Sevoflurane	3.5 Uncuffed	N ₂ O, Isoflurane	
1	Y	Brain MRI, spectroscopy	N ₂ O, Sevoflurane	3.5 Uncuffed	N ₂ O, Propofol	
2		Brain MRI, spectroscopy	N ₂ O, Sevoflurane	4.0 Uncuffed	N ₂ O, Isoflurane	
3		Brain MRI, spectroscopy Dental rehabilitation	N ₂ O, Sevoflurane	4.0 Uncuffed	N ₂ O, Isoflurane	
4		Brain MRI, spectroscopy	N ₂ O, Sevoflurane	5.0 Cuffed	N ₂ O, Isoflurane	
5		Brain MRI, spectroscopy	N ₂ O, Sevoflurane	4.0 Uncuffed	N ₂ O, Propofol	Laryngospasm during intubation
6		Brain MRI, spectroscopy	N ₂ O, Sevoflurane	3.5 Uncuffed	N ₂ O, Propofol	
6		Brain MRI, spectroscopy	N ₂ O, Sevoflurane	3.5 Cuffed	N ₂ O, Propofol	
7	Y	Brain MRI, spectroscopy	N ₂ O, Sevoflurane	3.0 Uncuffed	N ₂ O, Isoflurane	
7	Y	Brain MRI, spectroscopy	N ₂ O, Sevoflurane	3.0 Uncuffed	N ₂ O, Isoflurane	
7	Y	Brain MRI, spectroscopy eye EUA	N ₂ O, Sevoflurane	3.5 Uncuffed	N ₂ O, Propofol	
8		Brain MRI, spectroscopy	N ₂ O, Sevoflurane	3.5 Uncuffed	N ₂ O, Propofol	
9	Y	Brain MRI, spectroscopy Dental rehabilitation	N ₂ O, Sevoflurane	3.5 Cuffed	N ₂ O, Propofol	Prior procedure cancellation because of inability to intubate
10		Brain MRI, spectroscopy Dental rehabilitation	N ₂ O, Sevoflurane	4.0 Cuffed	N ₂ O, Propofol	
11	Y	Brain MRI, spectroscopy	N ₂ O, Sevoflurane	3.5 Uncuffed	N ₂ O, Propofol	
12		Brain MRI, spectroscopy	N ₂ O, Sevoflurane	3.5 Cuffed	N ₂ O, Propofol	
13		Brain MRI, spectroscopy Dental rehabilitation	N ₂ O, Sevoflurane	4.0 Cuffed	N ₂ O, Propofol	
14	Y	Brain MRI, spectroscopy Dental rehabilitation	N ₂ O, Sevoflurane	3.5 Cuffed	N ₂ O, Propofol	

* Difficult intubation as described by anesthesiologists who had previously performed direct laryngoscopies.

Y, yes; MRI, magnetic resonance imaging.

typic spectrum to include patients with milder cases, biochemical confirmation of the clinical diagnosis, and the use of dietary cholesterol replacement therapy for SLOS, the probability that an anesthesiologist will care for patients with SLOS is likely to increase. However, the literature on the anesthetic management of SLOS is scarce. Since the discovery of the biochemical defect associated with SLOS in 1994, there have been only small case series reported in the literature.^{10,12,13} In this report, we describe a series of 20 anesthetics in 14 patients with biochemically confirmed SLOS. Because of prior history of difficult intubation in 5 of our 14 patients, we prospectively decided to use fiberoptic laryngoscopy as the initial technique for tracheal intubation in the anesthetics described here. We have shown that, in skilled hands, fiberoptic intubation can be performed safely, efficiently, and without complications, and it can be used as an initial technique for airway management in patients with SLOS.

When planning to administer an anesthetic in a patient with SLOS, the anesthesiologist will have to address several issues pertinent to this complex syndrome. First, facial dysmorphic features in patients with SLOS, including those associated with Pierre Robin sequence (micrognathia and palatal anomalies) and prominent incisors, can be associated with difficulties in airway manage-

ment. In the literature, there are several reports of difficult intubation and abnormal laryngoscopic view in patients with SLOS.^{10,13,14} In our institution, we had to abort two procedures because of inability to intubate SLOS patients with direct laryngoscopy. In one patient in our series, an otolaryngologist performed fiberoptic intubation of the trachea after a pediatric anesthesiologist had attempted four direct laryngoscopies. We chose to perform fiberoptic intubation of the trachea as the initial technique for 19 of the anesthetics in this series. We were able to maintain spontaneous ventilation and adequate oxygenation and to intubate all patients without repeated direct laryngoscopies or trauma to the airway. Therefore, our experience suggests that in patients with SLOS, tracheal intubation by fiberoptic laryngoscopy is an excellent alternative for the airway management of these pediatric patients. Evidently, in order to make this a viable alternative, fiberoptic scopes that accommodate endotracheal tubes smaller than size 5.5 are required, and the staff must be trained in the technique of fiberoptic intubation.

Second, the potential for a difficult airway, when associated with the presence of gastroesophageal reflux, can be particularly concerning for the anesthesiologist. Although a common problem in patients with SLOS, gastroesophageal reflux is often a result of the combination

of small stomachs and intestinal dysmotility.⁵ After careful history taking, it was clear that, in most of our patients with SLOS, gastroesophageal reflux was predominantly associated with feedings. We felt that rapid sequence inductions were not warranted. Preoperatively, we prescribed an 8-h fast for formula and 3-h for clear liquids. Those patients on H₂ blockers and metoclopramide were given their doses 3 h prior to their anesthetics. Just prior to induction, we applied gentle suction to the gastric tube in patients who had a gastrotomy. We observed no episodes of regurgitation or aspiration of gastric contents with this regimen. Therefore, our experience with patients with SLOS suggests that if the history indicates that gastroesophageal reflux is predominantly associated with feedings and if strict fasting guidelines are followed, rapid sequence induction may not be necessary in all patients, and inhalation induction can be performed safely.

Another issue that anesthesiologists must keep in mind is the possible association of muscle rigidity and the use of inhalation agents in patients with SLOS. Petersen and Crouch¹² reported a 4-yr-old child with SLOS who exhibited muscle rigidity after the use of halothane. In that case, muscle rigidity was associated with a mild elevation in temperature but no elevation of creatinine kinase concentrations. In our series of 20 anesthetics, all patients received halogenated agents, and no episodes of muscle rigidity were observed. Furthermore, we used succinylcholine in one of these patients without any problems. Although no definitive conclusion can be made, in our experience, the use of halogenated anesthetics in this population was not associated with muscle rigidity.

Behavioral abnormalities are also issues that need to be addressed in the preoperative assessment of patients with SLOS. SLOS is known to be associated with behavioral disorders, including autism. In a study of patients with SLOS, 9 of the 17 patients without hearing deficit (53%) met the diagnostic criteria for autistic disorder, and 50 of 56 (89%) had aggressive behavior that was either self-injurious or directed against others.⁹ In that study, patients younger than 22 months did not show behavioral dysregulation.⁹ In addition, in a large series of patients with documented SLOS, the use of sedatives was reportedly ineffective.⁸ Certainly, such a high incidence of abnormal and aggressive behavior coupled with a lack of response to sedatives can pose a challenge for the pediatric anesthesiologist. In our series, only five anesthetics were administered in children older than 22 months, and only one of these children exhibited aggressive behavior. Although we did not observe any difficulty in sedating or anesthetizing our patients with SLOS, one could postulate that abnormalities of cellular membrane sterol composition in SLOS patients could alter their response to sedatives and anesthetic agents.

Some animal studies support this hypothesis. In a genetic mouse model of SLOS with biochemical and phenotypic

similarities to the human syndrome, the neurophysiologic response of frontal cortex neurons to the excitatory amino acid glutamate was significantly impaired.¹⁵ These findings in animals may suggest that in patients with SLOS, an abnormal sterol cellular membrane composition could impact the physiologic response of neurotransmitters. In turn, these abnormalities could impact the response to sedatives and anesthetic agents. Therefore, it is not surprising that patients with SLOS reportedly have an abnormal response to sedatives.⁸ From a clinical standpoint, all of our anesthetics were rather uncomplicated. However, further studies are needed to fully characterize the neuropharmacologic impact of the biochemical abnormalities of patients with SLOS.

In summary, we present a series of 20 anesthetics administered to 14 patients with SLOS. In our series, although patients with SLOS can have difficult intubations, mask airway was always adequate, and fiberoptic intubation of the trachea was a safe and reliable option as an initial technique in airway management. Despite a history of gastroesophageal reflux disease predominantly associated with feedings, we saw no cases of aspiration of gastric contents. Our findings suggest that although SLOS patients can present with a broad spectrum of phenotypes and congenital abnormalities that are potentially challenging for the anesthesiologist, they usually require rather routine anesthetic management.

The authors thank Mavra Diavatis, R.N. (Department of Anesthesia and Surgical Services, Warren Magnuson Clinical Center, National Institutes of Health, Bethesda, Maryland), for technical assistance during the anesthesia, and the members of the Department of Anesthesia and Surgical Services, Warren Magnuson Clinical Center, National Institutes of Health, Bethesda, Maryland, for their help in the care of our patients.

References

1. Nowaczyk MJ, McCaughey D, Whelan DT, Porter FD: Incidence of Smith-Lemli-Opitz syndrome in Ontario, Canada. *Am J Med Genet* 2001; 102:18-20
2. Kelley RI: A new face for an old syndrome. *Am J Med Genet* 1997; 68:251-6
3. Irons M, Elias ER, Salen G, Tint GS, Batta AK: Defective cholesterol biosynthesis in Smith-Lemli-Opitz syndrome (letter). *Lancet* 1993; 341:1414
4. Tint GS, Irons M, Elias ER, Batta AK, Frieden R, Chen TS, Salen G: Defective cholesterol biosynthesis associated with the Smith-Lemli-Opitz syndrome. *N Engl J Med* 1994; 330:107-13
5. Kelley RI, Hennekam RC: The Smith-Lemli-Opitz syndrome. *J Med Genet* 2000; 37:321-35
6. Lin AE, Ardinger HH, Ardinger RH Jr, Cunniff C, Kelley RI: Cardiovascular malformations in Smith-Lemli-Opitz syndrome. *Am J Med Genet* 1997; 68:270-8
7. Linck LM, Haylick SJ, Lin DS, Battaile KP, Ginat S, Burlingame T, Gibson KM, Honda A, Salen G, Tint GS, Connor WE, Steiner RD: Fetal demise with Smith-Lemli-Opitz syndrome confirmed by tissue sterol analysis and the absence of measurable 7-dehydrocholesterol Delta(7)-reductase activity in chorionic villi. *Prenat Diagn* 2000; 20:238-40
8. Ryan AK, Bartlett K, Clayton P, Eaton S, Mills L, Donnai D, Winter RM, Burn J: Smith-Lemli-Opitz syndrome: A variable clinical and biochemical phenotype. *J Med Genet* 1998; 35:558-65
9. Tierney E, Nwokoro NA, Porter FD, Freund LS, Ghuman JK, Kelley RI: Behavior phenotype in the RSH/Smith-Lemli-Opitz syndrome. *Am J Med Genet* 2001; 98:191-200
10. Choi PT, Nowaczyk MJ: Anesthetic considerations in Smith-Lemli-Opitz syndrome. *Can J Anaesth* 2000; 47:556-61
11. Witsch-Baumgartner M, Fitzky BU, Ogorelkova M, Kraft HG, Moebius FF, Glossmann H, Seedorf U, Gillesen-Kaesbach G, Hoffmann GF, Clayton P, Kelley RI, Utermann G: Mutational spectrum in the Delta7-sterol reductase gene and genotype-phenotype correlation in 84 patients with Smith-Lemli-Opitz syndrome. *Am J Hum Genet* 2000; 66:402-12

12. Petersen WC, Crouch ER Jr: Anesthesia-induced rigidity, unrelated to succinylcholine, associated with Smith-Lemli-Opitz syndrome and malignant hyperthermia. *Anesth Analg* 1995; 80:606-8

13. Haji-Michael PG, Hatch DL: Smith-Lemli-Opitz syndrome and malignant hyperthermia (letter). *Anesth Analg* 1996; 83:200

14. Butler MG, Hayes BG, Hathaway MM, Begleiter ML: Specific genetic dis-

eases at risk for sedation/anesthesia complications. *Anesth Analg* 2000; 91: 837-55

15. Wassif CA, Zhu P, Kratz L, Krakowiak PA, Battaile KP, Weight FF, Grinberg A, Steiner RD, Nwokoro NA, Kelley RI, Stewart RR, Porter FD: Biochemical, phenotypic and neurophysiological characterization of a genetic mouse model of RSH/Smith-Lemli-Opitz syndrome. *Hum Mol Genet* 2001; 10:555-64

Anesthesiology 2002; 97:1019-21

© 2002 American Society of Anesthesiologists, Inc. Lippincott Williams & Wilkins, Inc.

Severe Rhabdomyolysis after Laparoscopic Surgery for Adenocarcinoma of the Rectum in Two Patients Treated with Statins

François Forestier, M.D.,* Yannick Breton, M.D.,† Emmanuel Bonnet, M.D.,* Gerard Janvier, M.D., Ph.D.‡

RHABDOMYOLYSIS is a clinical and biochemical syndrome resulting from skeletal muscle injury with the release of muscle contents into the plasma. It results either from a direct muscle injury or from an altered metabolic relationship between energy production and consumption in muscle. Crush syndrome, extensive burns, electric shock, and prolonged immobilization are the main causes of direct muscle injury. Strenuous physical exercise, malignant hyperthermia, muscle ischemia resulting from compression or vascular injury, infections, myopathies, toxins, and drugs, including alcohol, which accounts for 20% of the cases, can cause nontraumatic rhabdomyolysis. This syndrome has been described with fibrates and statin lipid-lowering drugs, culminating in the recent removal of cerivastatin from the market because of a number of rhabdomyolysis-related deaths.¹ Severe cases were reported in elderly patients and in patients taking lipid-lowering drugs. We observed two consecutive cases of severe postoperative rhabdomyolysis in patients who underwent elective laparoscopic surgery for adenocarcinoma of the rectum, and for whom cumulative risk factors were identified in retrospect: long-term treatment with statins and laparoscopic surgery with prolonged immobilization under general anesthesia.

Case Reports

Case 1

A 52-yr-old male patient (body mass index, 26.6) was scheduled to undergo elective surgery for adenocarcinoma of the rectum. He had a history of myocardial infarction, moderate hypertension, pulmonary embolism, appendectomy, hypercholesterolemia, and diabetes mellitus. His usual medications included aspirin, foscipril, atenolol,

glimepiride, and pravastatin, which were discontinued the day before surgery. Preoperative evaluation of the patient did not show any biologic disturbances, and his chest radiograph was normal. The patient was premedicated with 50 mg hydroxyzine the evening before the surgery and 100 mg hydroxyzine 2 h before his admission to the operating room. Antibiotic prophylaxis (cefotaxime, 2 g) was given intravenously before the induction of anesthesia with propofol (3 mg/kg), sufentanil (0.5 µg/kg), and cisatracurium (0.15 mg/kg) for muscle relaxation. Anesthesia was maintained with isoflurane in an oxygen-air mixture supplemented with sufentanil (1.8 µg · kg⁻¹ · h⁻¹) and additional doses of cisatracurium as needed. The support points were protected by gelatin patches and checked at each change of position. The rectotomy lasted 6 h in a lithotomy position. The patient's systolic blood pressure remained above 80 mmHg during the surgery, and his perioperative blood loss was less than 500 ml. Volume replacement was ensured by administering 500 ml of a hydroxyethyl starch solution (200,000/0.5/6%/5) and 4,300 ml of crystalloids. The patient was extubated 1 h after arrival in the intensive care unit. On the first day after the surgery, the patient complained about his calves despite intravenous morphine (patient-controlled analgesia). No compartment syndrome sign was observed, and his abdomen was soft. The serum creatine phosphokinase (CPK) concentration was 7,103 IU/ml (fig. 1). On the second day, the patient's temperature increased (38°C), blood gases showed metabolic acidosis, his serum lactate concentration was 4.75 mM, and a chest radiograph revealed mixed alveolar-interstitial infiltrates. Ventilatory assistance was required as a result of acute respiratory failure. A laparotomy failed to show a surgical complication. On the third day after the surgery, the patient developed oliguric acute renal failure with a serum creatinine concentration of 272 µM and a creatinine clearance of 26 ml/min (fig. 1). Laboratory investigations revealed that his CPK concentration was 2,191 IU/l, his aspartate aminotransferase concentration was 234 IU/l, and his serum myoglobin concentration was 1.98 ng/ml. Continuous venovenous hemofiltration was initiated, and the patient's renal and respiratory function recovered slowly, as did the clinical sign of rhabdomyolysis. Serum CPK reached the maximum concentration 10 days after admission to the intensive care unit and returned to normal values 4 days later. The patient left the intensive care unit 30 days after his admission without apparent sequelae.

Case 2

A 63-yr-old male patient (body mass index, 32.8) was scheduled for the same surgery. His medical history revealed that he had undergone cardiac surgery (coronary artery bypass grafting) and an appendectomy, and that he had glaucoma and hypercholesterolemia. His usual medications included diltiazem, losartan, a potassium-sparing diuretic (furosemide-amiloride), acenocoumarol (discontinued 5 days before surgery), and fluvastatin (discontinued the day before surgery). Electrocardiogram, chest radiograph, complete blood count, coagulation

* Senior Lecturer, † Resident, ‡ Professor and Chairman.

Received from the Département d'Anesthésie-Réanimation II, Centre Hospitalier Universitaire de Bordeaux, France. Submitted for publication December 17, 2001. Accepted for publication April 16, 2002. Support was provided solely from institutional and/or departmental sources.

Address reprint requests to Dr. Forestier: Département d'Anesthésie-Réanimation II, Centre Hospitalier Universitaire de Bordeaux, Avenue de Magellan, 33604 Pessac Cedex, France. Address electronic mail to: francois.forestier@chu-bordeaux.fr. Individual article reprints may be purchased through the Journal Web site, www.anesthesiology.org.

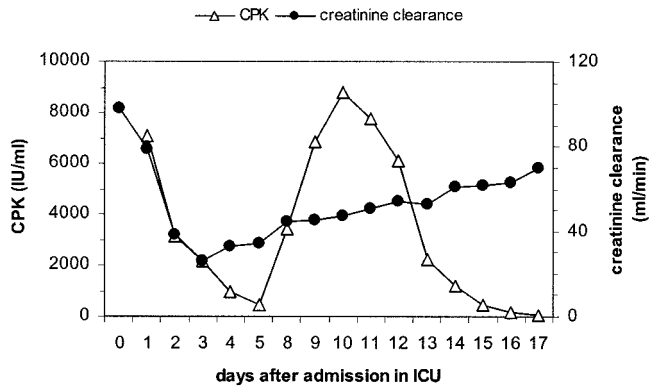


Fig. 1. Evolution in the intensive care unit of serum creatine phosphokinase concentration and creatinine clearance in case 1.

variables, and serum biochemistry results were normal. Premedication and anesthesia, type of surgery, position during surgery, duration of surgery, blood loss, volume replacement, and time to tracheal extubation were similar to those encountered in the previous case. On the first day after the surgery, the patient felt the same kind of pain he had for the past 2 months, in his left calf and his right arm, without neurologic deficit or sign of ischemia. On the second day, the patient had a raised temperature and a swollen left calf. Doppler ultrasound examination ruled out phlebitis. Nonoliguric acute renal failure was present, with a serum CPK concentration of 17,300 IU/l (fig. 2). The following day, the patient had decreased contraction of the anteroexternal muscles, which led us to perform an aponeurotomy on the left leg. The patient recovered rapidly. His serum CPK concentration decreased steadily, and the renal failure disappeared in 8 days. However, the left common peroneal nerve paralysis persisted at discharge from the intensive care unit.

Discussion

Statins are a class of drugs (HMG Co-A reductase inhibitors) that lower cholesterol and reduce the risk of coronary heart disease.^{2,3} Although they have the same mechanism of action, their pharmacokinetics and effect on plasma lipids are different. They are metabolized in the liver *via* different isoforms of the cytochrome P_{450} enzyme system. Drugs that are metabolized by the same pathways (especially cytochrome P_{450} 3A4), such as cy-

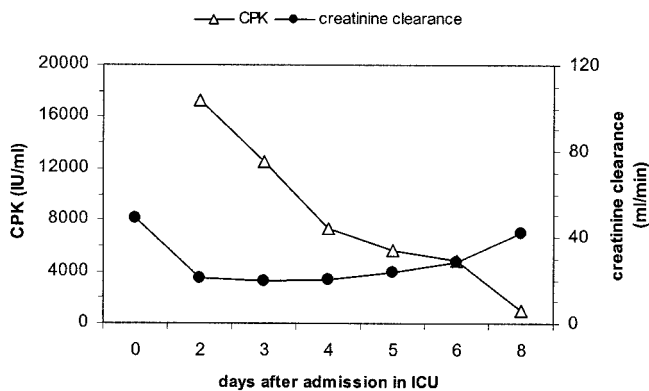


Fig. 2. Evolution in the intensive care unit of serum creatine phosphokinase concentration and creatinine clearance in case 2.

closporin, itraconazole, ketoconazole, and erythromycin, may interact with statins and increase the risk of myopathy.⁴ All statins have been associated with very rare reports of rhabdomyolysis.⁵ Fatal cases have been reported more frequently for cerivastatin, especially when it was used at higher doses, in elderly patients, or in combination with gemfibrozil, another lipid lowering drug.⁶ Pravastatin does not undergo significant hepatic metabolism, and fluvastatin is metabolized by more than one cytochrome P_{450} isoenzyme. Thus, among the statins, fluvastatin and pravastatin are the least prone to interactions. In this report, however, our patients developed severe postoperative rhabdomyolysis with these drugs. Their usual medications did not include drugs that are likely to interact with these statins. Classic risk factors for rhabdomyolysis, such as myopathy in the family or personal history, endocrine or metabolic disorders, malignant hyperthermia, chronic renal failure, and air embolism, were absent. There was no preoperative or postoperative anemia, perioperative hypotensive episode, or sepsis. Blood volume and urine output were maintained during the surgery. Other risk factors for muscular injuries were identified: a history of atherosclerotic disease, a high body mass index in the second case, and a long duration of surgery in a lithotomy position.^{7,8} The choice of a laparoscopic approach in the surgical management of colorectal cancer could have contributed to the incidence of muscular injuries in our patients. In a survey of neuromuscular injuries associated with urologic laparoscopic surgery, Wolf *et al.*⁹ reported six cases of clinical rhabdomyolysis (0.4%) among a total of 1,651 procedures completed by 18 urologists from 15 institutions in the United States. Patients with rhabdomyolysis were heavier and underwent longer procedures. As in our report, this complication occurred in patients who were not in an extreme lithotomy position. The investigators, however, did not mention their patients' usual medications. In retrospect, we believe that our patients had an increased risk of muscular injuries as a result of (1) a major surgery with a prolonged immobilization under general anesthesia, (2) a laparoscopic approach with hemodynamic consequences such as decreased regional blood flow and increased systemic vascular resistances¹⁰, and (3) prolonged treatment with a HMG Co-A reductase inhibitor. This risk was probably even higher in the second patient, who had preoperative clinical signs of myopathy.

We retrieved the case notes of 53 other patients who had undergone a similar procedure over the last year in our department. We found three other instances of statin use and no other case of rhabdomyolysis. The association of rhabdomyolysis and statin use was significant (Fisher exact test, $P = 0.0067$). Eighty percent of the patients, including the two cases of rhabdomyolysis, had received propofol during induction of anesthesia, a drug that could additionally inhibit cytochrome P_{450} 3A4.¹¹

However, this should not have impaired the metabolism of fluvastatin and pravastatin.

In this particular context, and apart from the usual measures to prevent muscular injuries, physicians should systematically look for clinical and biologic signs of rhabdomyolysis in the postoperative period. The question of the preoperative discontinuation of statins should also be raised. In our department, patients usually stopped taking statins the day before surgery. Although the half-life of statins is short (0.5–3 h), and this period seems to be reasonable, the literature on the potential interactions of statin metabolites with drugs administered during or after anesthesia and on possible muscular accumulation of these drugs is sorely lacking. Considering that these drugs are used for long-term prevention, stopping the drug for a few weeks before surgery would not significantly decrease the cardiovascular protection. We suggest much earlier discontinuation of these drugs in the hope of decreasing the risk of rhabdomyolysis.

The authors thank the Department of Pharmacology of the Centre Hospitalier Universitaire de Bordeaux, France, for assistance.

References

1. Omar MA, Wilson JP, Cox TS: Rhabdomyolysis and HMG-CoA reductase inhibitors. *Ann Pharmacother* 2001; 35:1096–107.
2. Sacks F, Pfeffer M, Moye L, Rouleau J, Rutherford J, Cole T, Braunwald E: The effect of pravastatin on coronary events after myocardial infarction in patients with average cholesterol levels. *N Engl J Med* 1996; 335:1001–9
3. Scandinavian Simvastatin Survival Study Group: Randomised trial of cholesterol lowering in 4444 patients with coronary heart disease: The Scandinavian Simvastatin Survival Study (4S). *Lancet* 1994; 344:1383–9
4. Farmer JA, Torre-Amione G: Comparative tolerability of the HMG-CoA reductase inhibitors. *Drug Saf* 2000; 23:197–213
5. Ucar M, Mjorndal T, Dahlqvist R: HMG-Co A reductase inhibitors and myotoxicity. *Drug Saf* 2000; 22:441–57
6. Lau T, Leachman D, Lufschanowski R: Severe rhabdomyolysis associated with the cerivastatin-gemfibrozil combination therapy: Report of a case. *Tex Heart Inst J* 2001; 28:142–5
7. Gabrielli A, Caruso L: Postoperative acute renal failure secondary to rhabdomyolysis from exaggerated lithotomy position. *J Clin Anesth* 1999; 11:257–63.
8. Biswas S, Gnanasekaran I, Ivatury RR, Simon R, Patel AN: Exaggerated lithotomy position-related rhabdomyolysis. *Am Surg* 1997; 63:361–4.
9. Wolf JS Jr, Marcovich R, Gill IS, Kavoussi LR, Clayman RV, McDougall EM, Shalhav A, Dunn MD, Afane JS, Moore RG, Parra RO, Winfield HN: Survey of neuromuscular injuries to the patient and surgeon during urologic laparoscopic surgery. *Urology* 2000; 55:831–6
10. Struthers AD, Cuschieri A: Cardiovascular consequences of laparoscopic surgery. *Lancet* 1998; 352:568–70
11. Hamaoka N, Oda Y, Hase I, Mizutani K, Nakamoto T, Ishizaki T, Asada A: Propofol decreases the clearance of midazolam by inhibiting CYP3A4: An *in vivo* and *in vitro* study. *Clin Pharmacol Ther* 1999; 66:110–7