

## Misuse of A Condom

*To the Editor:*—Although I accept that the cleansing and sterilization of laryngoscope blades is a nuisance to nurses and other paramedical personnel, I do not think that the use of a condom to cover the laryngoscope blade is an answer to this problem. First, the condom cannot be assumed to be a barrier against the transmission of infection between cases. Damage to its integrity unnoticeable by the naked eye can easily occur, particularly during contact with teeth or dental work in a difficult intubation. It is not an effective barrier and puts patients at risk of cross-contamination. Condoms are renowned for splitting when used for their intended purpose, and this is far more likely when used as described. Second, I also feel strongly that condom packets scattered around anesthetic rooms or empty packets in disposal bins will lead to anxiety among patients.

Anesthesiology 2001; 95:1300

*In Reply:*—The use of a condom as a blade cover was not meant to replace regular blade cleansing. However, because of the protective effect of the condom, sputum or a small blood clot could be avoided. In the situation of a difficult intubation, splitting of a condom may be unavoidable, but using two condoms at the same time may be effective. In our hospital, anesthetic drugs and equipment are locked up in an anesthesia cart when not in use, so the storage and disposal of condom packets are restricted to medical personnel only. Patients should be restrained from exposure to any kind of medical equipment while they are awake. Re-

Difficulty would also be encountered if patients inquire why an odd taste persists after anesthesia. I would certainly not like to be responsible for telling them not to worry—that is only the taste of the spermicidal jelly.

**Howard Brownlow, M.B.B.S., B.Sc., F.R.C.A.,** Royal Perth Hospital, Perth, Australia. docmandu@hotmail.com

## Reference

1. So EC: Use of a condom as a blade cover for a laryngoscope (letter). ANESTHESIOLOGY 2000; 3:906

(Accepted for publication January 4, 2001.)

© 2001 American Society of Anesthesiologists, Inc. Lippincott Williams &amp; Wilkins, Inc.

garding the odd taste suggested by Dr. Brownlow, among the 2,000 patients I have encountered, not a single patient has made this complaint. Also, condoms with fruity or mint taste are available on the market.

**Edmund C. So, M.D.,** Chi-Mei Medical Center, Yung Kang City, Tainan, Taiwan. edmundso@mail.chimei.org.tw

(Accepted for publication January 4, 2001.)

Anesthesiology 2001; 95:1300-1

© 2001 American Society of Anesthesiologists, Inc. Lippincott Williams &amp; Wilkins, Inc.

## Calculation of the Permeability Coefficient Should Take into Account the Fact That Most Drugs Are Weak Electrolytes

*To the Editor:*—In a recent article, Bernards *et al.*<sup>1</sup> measured separately the flux of <sup>3</sup>H-labelled R- and S-bupivacaine through the spinal meninges of the monkey and concluded that the meningeal permeability for the enantiomers did not differ. However, their method of calculation of the permeability coefficient does not take into account the fact that bupivacaine exists in solution as a mixture of conjugated acid (ionized) and base (unionized) forms under the chosen conditions of pH 7.4 (fig. 1).

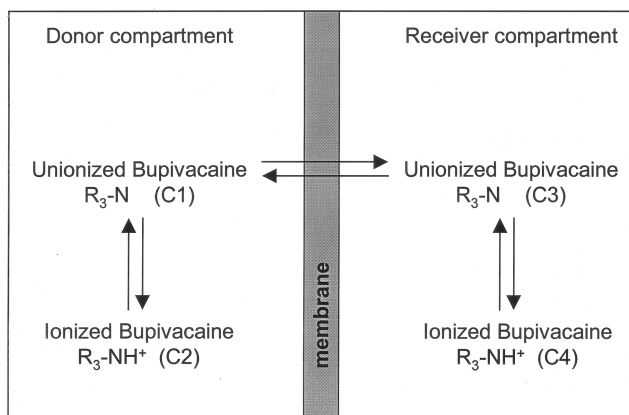
Partial ionization complicates the calculation of the permeability coefficient. It is known for many substances, and we have shown for local anesthetics that the unionized form of the local anesthetic predominantly diffuses through the meninges, with the contribution of the ionized form being essentially negligible.<sup>2</sup> By calculating the permeability coefficient (P [cm/min]) according to the equation

$$P = Q/(C \times A)$$

where Q = bupivacaine flux ( $\mu\text{g}/\text{min}$ ), C = total bupivacaine concentration (= C1 + C2) in the donor reservoir ( $\mu\text{g}/\text{ml}$ ), and A = tissue area ( $\text{cm}^2$ ).

Bernards *et al.*<sup>1</sup> underestimate the exact value of the permeability coefficient by a factor of 6 by using the total concentration C of bupivacaine in the donor compartment (= sum of C1 + C2 in fig. 1). The actual "driving force" for diffusion of bupivacaine through the meninges (C1  $\approx$  0.166C) should be calculated according the Henderson-Hasselbalch equation and the pK<sub>a</sub> value measured by Strichartz *et al.*<sup>3</sup> at 37°C.

The conclusion of this study by Bernards *et al.*<sup>1</sup> is qualitatively correct; the impact of omitting the influence of ionization is nullified



**Fig. 1. Distribution and diffusion of bupivacaine between donor and receiver compartments. The concentrations of the ionized and unionized forms of bupivacaine (symbolized as a tertiary amine R<sub>3</sub>N) in donor and receiver compartments are depicted by C1, C2, and so on.**

because R- and S-bupivacaine, having the same pK<sub>a</sub>,<sup>4</sup> are compared. Furthermore, we independently obtained the same result using human meninges with (racemic) bupivacaine and a chiral high-pressure liquid chromatography method to measure the concurrent enantiomer concentrations individually.<sup>5</sup> However, it needs to be reiterated that other

relevant physicochemical properties, such as aqueous solubility, cannot be assumed to be equal for the enantiomers of racemic drugs separately and in the racemic admixture.<sup>4</sup>

The results of previous studies, comparing the permeability coefficients of different drug molecules with widely differing pK<sub>a</sub> values, and without correction for the unionized concentration, should be addressed cautiously.<sup>6,7</sup> Future studies should address this important aspect of diffusion.

**René J. Grouls, Ph.D.,\*** **Erik H. Korsten, M.D., Ph.D.**  
**Ludo J. Hellebrekers, D.V.M., Ph.D., Eric W. Ackerman, Pharm.D.,**  
**Laurence E. Mather, Ph.D.** \*Catharina Hospital, Eindhoven, The Netherlands. r.grouls@wxs.nl

## References

1. Bernards CM, Ulma GA, Kopacz DJ: The meningeal permeability of R- and S-bupivacaine are not different. *ANESTHESIOLOGY* 2000; 93: 896-7

*Anesthesiology* 2001; 95:1301

*In Reply:*—We appreciate the letter from Dr. Grouls *et al.* We agree with the authors but suggest that the issue is largely a semantic one. We should have referred to the reported permeability coefficient as the “apparent permeability coefficient” because it was calculated from the total drug concentration, not the unionized fraction. We chose to use total drug concentration for several reasons. First, total drug concentration is the clinically relevant drug quantity, and it is easy to measure accurately (as opposed to ionized fraction, which must be calculated based on pH, ionic strength, temperature, and so forth). Secondly, correcting for ionized fraction is based on the assumption that ionized solutes are impermeable across the relevant tissue. No tissue is completely impermeable to charged solutes, and we have shown that

*Anesthesiology* 2001; 95:1301

*To the Editor:*—In the December 2000 issue of *ANESTHESIOLOGY*, Benumof<sup>1</sup> describes the devastating results of four attempted interscalene nerve blocks (ISB) performed in patients during general anesthesia or heavy sedation. Dr. Benumof concludes that the neurologic injury these patients received was caused by the direct placement of a needle and injection of local anesthetic into the substance of the spinal cord. Three of these cases involved a 22-gauge, 2-in Braun Stimuplex needle, and the fourth case used a 1.5-in, 22-gauge needle that was “walked off” the transverse process of C6 in an attempt to locate the nerve trunks of the brachial plexus. An obvious common characteristic shared by all of these cases was that the patients were rendered incapable, either by general anesthesia or by profound sedation, of responding to the inappropriate placement of a needle and injection of local anesthetic.

While I would like to thank Dr. Benumof for bringing this previously unreported complication of interscalene brachial plexus blockade to our attention, this case report deserves further comment. First, if general anesthesia is not an absolute, but as Dr. Benumof states, a relative contraindication to performing an ISB, under what circumstances would it be appropriate to attempt this procedure in an anesthetized patient? Second, Dr. Benumof recommends that the needle used for an ISB be less than 1.5 in long, but he dissuades the reader from inserting a needle greater than 1.0 or 1.25 in long. I assume he meant that the needle should usually not be inserted more than 1.0–1.25 in into the patient. However, I would like to emphasize that

*Anesthesiology*, V 95, No 5, Nov 2001

2. Grouls R, Korsten E, Ackerman E, Hellebrekers L, Zundert van A, Breimer D: Diffusion of n-butyl-p-aminobenzoate (BAB), lidocaine and bupivacaine through the human dura-arachnoid mater in vitro. *Eur J Pharm Sciences* 2000; 12:125-31

3. Strichartz GR, Sanchez V, Arthur GR, Chafetz R, Martin D: Fundamental properties of local anesthetics, II: Measured octanol:buffer partition coefficients and pKa values of clinically used drugs. *Anesth Analg* 1990; 71:158-70

4. Friberger P, Åberg G: Some physicochemical properties of the racemates and the optically active isomers of two local anaesthetic compounds. *Acta Pharm Suecica* 1971; 8:361-4

5. Grouls RJE, Mather LE, Korsten HM, Gu X-Q: Diffusion of R- and S-bupivacaine through the human dura-arachnoid (abstract). *Br J Clin Pharmacol* 2000; 50:494-5

6. Bernards CM, Hill HF: Physical and chemical properties of drug molecules governing their diffusion through the spinal meninges. *ANESTHESIOLOGY* 1992; 77:750-6

7. McEllistrem RF, Bennington RG, Roth SH: In vitro determination of human dura mater permeability to opioids and local anaesthetics. *Can J Anaesth* 1993; 40:165-9

(Accepted for publication February 15, 2001.)

© 2001 American Society of Anesthesiologists, Inc. Lippincott Williams & Wilkins, Inc.

current will flow through the meninges if we place a potential across them. Admittedly, the magnitude of the current is not large, and small electrolytes (as opposed to larger charged drug molecules) may well carry the majority of the current, but we do not know that for sure. Consequently, we believe that using total drug concentration to calculate the permeability coefficient was appropriate and clinically relevant, but, to avoid confusion, we should have termed it “apparent permeability coefficient.”

**Christopher M. Bernards, M.D.,** University of Washington School of Medicine, Seattle, Washington. chrisb@u.washington.edu

(Accepted for publication February 15, 2001.)

© 2001 American Society of Anesthesiologists, Inc. Lippincott Williams & Wilkins, Inc.

## Catastrophic Complications of Interscalene Nerve Block

the length of the needle used for an ISB does not necessarily affect the inherent risk or safety of the procedure. If an individual can place a 1.5-in needle into the spinal cord in a patient with a weight of 93 kg and a height of 167 cm (case 3 of Benumof's report), the same could probably be done with a 1-in needle in a patient with a weight of 55 kg and a height of 167 cm. Likewise, an experienced and knowledgeable practitioner of regional anesthesia can safely place an ISB with a 2-in needle if need be.

Benumof's case report underscores the importance of a basic principle of regional anesthesia: that its safe and successful practice requires a sound fundamental knowledge of the relevant anatomy, physiology, and pharmacology, as well as the indications and contraindications of the procedure to be undertaken—knowledge gained through medical education, training, and experience. Such knowledge seems to have been lacking in those persons who attempted these nerve blocks with such catastrophic results.

**J. Lee White, M.D.,** University of Virginia, Charlottesville, Virginia. jlw9s@virginia.edu

## Reference

1. Benumof JL: Permanent loss of cervical spinal cord function associated with interscalene block performed under general anesthesia. *ANESTHESIOLOGY* 2000; 93:1541-4

(Accepted for publication April 18, 2001.)

Anesthesiology 2001; 95:1302

© 2001 American Society of Anesthesiologists, Inc. Lippincott Williams &amp; Wilkins, Inc.

## How to Prevent Catastrophic Complications When Performing Interscalene Blocks

*To the Editor:*—The cases presented by Dr. Jonathan L. Benumof<sup>1</sup> are invaluable contributions to our understanding of the risks associated with performing peripheral nerve blocks. However, it is important to acknowledge that these are malpractice cases, and that peripheral nerve blocks performed in appropriate conditions by properly trained and experienced practitioners are safe and effective in providing anesthesia and analgesia<sup>2</sup> and are cost effective.<sup>3</sup>

We strongly disagree with the statements, “Performing an interscalene block (ISB) during general anesthesia (GA) . . . is a common procedure” (introduction) and “GA can be considered as a relative contraindication for ISB” (discussion).<sup>1</sup> Of all the peripheral nerve blocks we perform, interscalene blocks in an adult should be performed awake. General anesthesia should be considered as an absolute rather than a relative contraindication. In our institution, we only perform interscalene blocks before or after surgery in awake patients (Ramsey score < 3).

In case 3, the patient was anesthetized because of “coughing, straining, and neck movement.”<sup>1</sup> We strongly believe that in this specific situation, general anesthesia is not the solution, but removing the needle and offering alternative postoperative pain therapy approaches should be considered the standard. Anyone performing peripheral nerve blocks needs to acknowledge that every patient is not necessarily a good candidate and that alternative therapies exist.

Because in three patients a nerve stimulator was used, if the needles were in the spinal cord, one should expect an intense motor response. Perhaps epidural or intrathecal injections leading to acute spine compression also deserve consideration in the differential diagnosis. This differential diagnosis is important because it suggests that magnetic resonance imaging performed immediately after the block might have provided insight and might have led to an early surgical decompression.

We also insist on using a 25-mm needle and introducing the needle in a posterior and caudal direction and agree that this technique minimizes the risk for the needle’s entering the intervertebral space. However, many anesthesiologists have performed thousands of interscalene blocks without similar catastrophic outcomes using a 50-mm needle. In our opinion, these four cases reinforce the importance of

proper setup, training, and experience. There is an increased demand for peripheral nerve blocks, but many resident training programs do not provide formal training in peripheral nerve blocks. Our residents spend a minimum of 1 month in a peripheral nerve block rotation and perform an average of 100–150 upper and lower extremity blocks. Many of our residents come back for a second month and even for a third month. In September 1999, we began a fellowship program. In addition, our residents are given educational materials, including a book and videos, and have access to dissection sessions. Similar programs exist in other institutions but are by far the exception, although they should be the rule.<sup>4</sup>

In conclusion, the cases presented by Dr. Benumof represent extreme complications of interscalene blocks. Residents and anesthesiologists performing these blocks should be aware of them. Prevention of these complications includes the proper selection of patients and the performance of blocks either before or after anesthesia in patients who are awake or mildly sedated.

**Jacques E. Chelly, M.D., Ph.D., M.B.A.,\* Jennifer Greger, M.D., Ralf Gebhard, M.D., Andrea Casati, M.D.** \*University of Texas Health Science Center-Houston, Houston, Texas. Jacques.E.Chelly@uth.tmc.edu

### References

1. Benumof JL: Permanent loss of cervical spinal cord function associated with interscalene block performed under general anesthesia. *ANESTHESIOLOGY* 2000; 93:1541–4
2. Auroy Y, Narchi P, Messiah A, Litt L, Rouvier B, Samii K: Serious complications related to regional anesthesia: Results of a prospective survey in France. *ANESTHESIOLOGY* 1997; 87:479–86
3. Pavlin DJ, Rapp SE, Polissar NL, Malmgren JA, Koerschgen M, Keyes H: Factors affecting discharge time in adult outpatients. *Anesth Analg* 1998; 87:816–26
4. Chelly JE, Hagberg CA, Gebhard R, Greger J, Khan A: Teaching peripheral nerve blocks to anesthesiology residents (abstract). *ANESTHESIOLOGY* 2000; 93:A1204

(Accepted for publication April 18, 2001.)

Anesthesiology 2001; 95:1302–3

© 2001 American Society of Anesthesiologists, Inc. Lippincott Williams &amp; Wilkins, Inc.

## Performing an Interscalene Block during General Anesthesia Must Be the Exception

*To the Editor:*—The four dramatic case reports reported by Benumof<sup>1</sup> in a recent issue of *ANESTHESIOLOGY* deserve comment because regional anesthesia techniques are becoming more frequently used. Indeed, interscalene block may result in better postoperative conditions as compared with general anesthesia.<sup>2</sup> A perineural catheter can also provide better postoperative pain control, fewer side effects, and greater patient satisfaction as compared with classic intravenous analgesia.<sup>3,4</sup>

We disagree with Benumof’s statement that “Performing an interscalene block (ISB) during general anesthesia . . . is a common procedure.”<sup>1</sup> In our experience, this practice must be the exception. Patients should be awake or lightly sedated when performing an ISB to increase the safety of this procedure. In addition, the precise ISB technique used in these cases is not clearly described. In case 3, we read, “by ‘walking’ the needle off the posterior aspect of the C6

transverse process . . .” For people regularly performing these nerve blocks, this approach is frightening. We surmise the Winnie approach has been used in the other patients, an approach that has already been associated with several complications, such as spinal or epidural anesthesia.<sup>5,6</sup> We believe this approach should be replaced by the modified lateral approach in which the needle is directed slightly medial and caudal in the direction of the plane of the interscalene groove. Moreover, the statement in case 1 that “right upper extremity . . . muscle twitches were obtained”<sup>1</sup> is too rough and imprecise to be accepted as a block description in modern regional anesthesia.

Regional techniques are not easy techniques to master and necessitate practice.<sup>7</sup> The lesson from these cases should not be that general anesthesia is a relative contraindication for ISB but that it should be a near absolute contraindication. The emphasis on the length of the

needle should be replaced by the need for anesthesiologists to be well-trained in that field to prevent these avoidable complications.

**Alan Borgeat, M.D.,\* Georgios Ekatodramis, M.D., Elisabeth Gaertner, M.D.** \*University Hospital of Zurich/Balgrist, Switzerland. aborgeat@balgrist.unizh.ch

## References

1. Benumof JL: Permanent loss of cervical spinal cord function associated with interscalene block performed under general anesthesia. *ANESTHESIOLOGY* 2000; 93:1541-4
2. Brown, AR, Weiss R, Greenberg, C, Flatow EL, Bigliani LU: Interscalene block for shoulder arthroscopy: Comparison with general anesthesia. *Arthroscopy* 1993; 9:295-300

3. Borgeat A, Schappi B, Biasca N, Gerber C: Patient-controlled analgesia after major shoulder surgery: Patient-controlled interscalene analgesia *versus* patient-controlled analgesia. *ANESTHESIOLOGY* 1997; 87:1343-47

4. Singelyn FJ, Seguy S, Gouverneur M: Interscalene brachial plexus analgesia after open shoulder surgery: Continuous versus patient-controlled infusion. *Anesth Analg* 1999; 89:1216-20

5. Tetzlaff JE, Yoon HJ, Dilger J, Brems J: Subdural anesthesia as a complication of an interscalene brachial plexus block. *Reg Anesth* 1994; 19:357-9

6. Passannante AN: Spinal anesthesia and permanent neurologic deficit after interscalene block. *Anesth Analg* 1996; 82:873-4

7. Konrad CH, Schupfer G, Wietlisbach M, Gerber H: Learning manual skills in anesthesiology: Is there a recommended number of cases for anesthetic procedures? *Anesth Analg* 1998; 96:635-9

(Accepted for publication April 18, 2001.)

Anesthesiology 2001; 95:1303

© 2001 American Society of Anesthesiologists, Inc. Lippincott Williams & Wilkins, Inc.

## Training Requirements for Peripheral Nerve Blocks

*To the Editor:*—The report by Benumof<sup>1</sup> about the permanent loss of cervical spinal cord function associated with interscalene blocks performed during general anesthesia fails to address a larger problem. The techniques that these anesthesiologists used, such as injection of local anesthetic after obtaining nerve stimulation at 0.80 mA or more and “walking off” the transverse process of C6 are unconventional and are not consistent with accepted techniques of interscalene brachial plexus blockade.<sup>2</sup> It is likely that a common factor in all four of the cases is a lack of expertise in the performance of interscalene block, not the use of general anesthesia, the needle size, or the direction and depth of insertion.

It has been suggested that many US residency training programs may be failing to prepare residents adequately for the practice of regional anesthesia.<sup>3,4,5</sup> Few residency training programs have structured rotations in regional anesthesia, and graduating anesthesiologists often perform only the simplest peripheral nerve block techniques, such as Bier and ankle blocks, to satisfy training requirements. Consequently, the majority of US anesthesiologists commonly use neuraxial anesthesia in their practice, but far fewer practice peripheral nerve blocks.<sup>4</sup> It is possible that a failure to differentiate peripheral nerve blocks from neuraxial anesthesia by traditionally labeling both as “regional anesthesia” has contributed to this lapse in training. For neuraxial anesthesia, the Program Requirements for Residency Training in Anesthesiology specifies 50 subarachnoid blocks and 50 epidural blocks as the minimum clinical experience that should be obtained by each graduating resident.\* In contrast, training requirements for peripheral nerve blocks are vague, currently consisting of any 40 peripheral nerve blocks.\*

The technology, techniques, equipment, and scope of practice of peripheral nerve blocks have become substantially more complex in

the past decade, while the consumer pressure in favor of peripheral nerve blocks has also significantly increased. Accordingly, many anesthesiologists feel compelled to introduce peripheral nerve blocks into their practice and may do so without adequate training in these techniques. Benumof's report affirms the importance of proper training in peripheral nerve blocks to preserve and enhance the value of regional anesthesia in today's practice. We believe that the time has come that the Residency Review Committee and the American Board of Anesthesiology reevaluate the training guidelines in light of the increasing trend for use of peripheral nerve blocks or, more specifically, recommend the training requirements for commonly used regional anesthesia techniques.

**Admir Hadzic, M.D., Ph.D.,† Jerry D. Vloka, M.D., Ph.D., Alan C. Santos, M.D., M.P.H., Alan Jay Schwartz, M.D., M.S.Ed., Kevin Sanborn, M.D., David J. Birnbach, M.D., Daniel M. Thys, M.D.** †St. Luke's-Roosevelt Hospital Center, New York, New York. ah149@columbia.edu

## References

1. Benumof JL: Permanent loss of cervical spinal cord function associated with interscalene block performed under general anesthesia. *ANESTHESIOLOGY* 2000;93:1541-4
2. Chelly EJ: *Peripheral Nerve Blocks: A Color Atlas*, 1st edition. Philadelphia, Lippincott Williams & Wilkins, 1999, pp 7-33
3. Kopacz DJ, Bridenbaugh LD: Are anesthesia residency programs failing regional anesthesia? The past, present, and future. *Reg Anesth* 1993; 18:84-7
4. Hadzic A, Vloka JD, Kuroda MM, Koorn R, Birnbach DJ: The practice of peripheral nerve blocks in the United States: A national survey. *Reg Anesth Pain Med* 1998; 23:241-6
5. Blumenthal D, Gokhale M, Campbell EG, Weissman JS: Preparedness for clinical practice. Reports of graduating residents at academic health centers. *JAMA* 2001; 286:1027-34

(Accepted for publication April 18, 2001.)

\*Accreditation Council for Graduate Medical Education: 1999-2000 Graduate Medical Education Directory. Chicago, American Medical Association, 1999. Available at: www.acgme.org

Anesthesiology 2001; 95:1303-4

© 2001 American Society of Anesthesiologists, Inc. Lippincott Williams & Wilkins, Inc.

## Attempted Interscalene Block Procedures

*To the Editor:*—I wish to thank Dr. Benumof for his interesting but tragic report of four patients in the December 2000 issue of *ANESTHESIOLOGY*.<sup>1</sup> However, I would like to object to his choice of title, “Permanent Loss of Cervical Spinal Cord Function Associated with Interscalene Block Performed under General Anesthesia.” The procedures performed were obviously not interscalene blocks but rather attempted blocks because the anesthetic solution was not placed in the interscalene sheath.

Winnie<sup>2</sup> states that the fascia of the anterior and middle scalene muscles “serves as a sheath of the plexus.” He further comments that the needle is to be advanced slowly and that “a very short distance under the skin the fascia is penetrated.”

I have performed more than 500 interscalene blocks, and most have been continuous blocks. The blocks were performed in awake and unmedicated patients. The plexus is extremely superficial and is the basis for the karate chop to the neck, thereby temporarily immobilizing

the upper arm. I have measured the skin to interscalene sheath distance in the average adult and found that it is 0.7–1.5 cm. In very obese patients (300–400 lb), the distance is no more than 2.5 cm. The use of a nerve stimulator may give a false feeling that one is within the sheath. An incomplete block, failed blocks, or increased risk of phrenic or recurrent laryngeal paralysis may result.<sup>2</sup> “Walking” the needle at the C6 transverse process, as has been described,<sup>2</sup> is not recommended because the needle depth would be greater than 1.5 cm in the average adult. Performing this block during general anesthesia is difficult because the tissues are relaxed, and feeling the “pop” into the sheath would be missed. Further, the elicitation of a paresthesia cannot be achieved. This paresthesia is normally described as a vague sensation in the shoulder, anterior chest wall, or down the arm and is easily and comfortably found. This is an extremely useful block and can give the patient a pain-free intraoperative and postoperative course.

Anesthesiology 2001; 95:1304

*In Reply:*—I thank Drs. White, Chelly *et al.*, Borgeat *et al.*, Hadzic *et al.*, and Bittar for their thoughtful comments. Drs. Chelly *et al.* and Borgeat *et al.* took exception to my statement that performing interscalene block during general anesthesia (ISB-GA) is a common procedure; their exception was based on their own practice and the practice at their own institutions. When I first learned of the four cases I reported, I informally surveyed many anesthesiologists in many locations to get a sense as to how common the ISB-GA procedure was. I was surprised to find that in many cities (including my own) and practice settings (private practice and teaching institutions, including my own department), the ISB-GA procedure was common and was the rule of practice rather than the exception. Furthermore, in several large cities and institutions, the local regional anesthesia expert told me that he or she was aware of one or more intracord injection complications in their community (but, as my report stated, no one had ever reported this complication before). Based on this survey experience, I am confident that as one broadens the sphere of inquiry, one will find that the ISB-GA procedure is common and geographically widespread.

Drs. White, Chelly *et al.*, and Bittar think that ISB-GA is absolutely, not relatively, contraindicated (as did one or two of the reviewers of my report). I struggled (and still do) with the exact strength of the wording “contraindicated” for ISB-GA for four reasons. First, standards of care are set in part by what other reasonably knowledgeable,

Attempting interscalene blocks during general anesthesia, as Dr. Benumof stated, is contraindicated and, if the anesthetic solution is not placed within the sheath, may lead to disaster.

**David A. Bittar, M.D.**, Anesthesia Services Medical Group Inc., San Diego, California. susandavidbittar@netscape.net

## References

1. Benumof JL: Permanent loss of cervical spinal cord function associated with interscalene block performed under general anesthesia. *ANESTHESIOLOGY* 2000; 93:1541–4
2. Winnie AP: Interscalene brachial plexus block. *Anesth Analg* 1970; 49: 455–66

(Accepted for publication April 18, 2001.)

© 2001 American Society of Anesthesiologists, Inc. Lippincott Williams & Wilkins, Inc.

prudent, and competent practitioners do in similar cases. If, as I found in my informal survey, many otherwise reasonably knowledgeable, prudent, and competent anesthesiologists are routinely performing ISB-GA, then how can ISB-GA be absolutely contraindicated? Are so many practitioners simply flat-out negligent? Second, it was not the primary intention of the report to set a standard of care, but rather to make the anesthesia community aware of the ISB-GA intracord injection complication and then let the practitioner come to his or her own standard of care conclusion. Third, some patients refuse awake ISB; are they then eliminated as candidates for ISB? Fourth, if one remains clearly cognizant of depth of insertion of the ISB needle, then the risk of intracord injection is minimized.

The depth of insertion issue brings me to the last comment that all the letters made, namely, that proper training, education, and technique (including depth of insertion) will avoid intracord injection. I suppose so, in a perfect world. In such a world, ISB-GA would not be contraindicated because proper training, education, and technique would prevent complications. However, the world is not perfect, so we are back to where we were before: should ISB-GA be relatively or absolutely contraindicated?

**Jonathan L. Benumof, M.D.**, University of California Medical Center, San Diego, California. jbenumof@ucsd.edu

(Accepted for publication April 18, 2001.)

Anesthesiology 2001; 95:1304–5

© 2001 American Society of Anesthesiologists, Inc. Lippincott Williams & Wilkins, Inc.

## Lighted Stylet Intubation in the Presence of Cricoid Pressure

*To the Editor:*—We would like to comment on the recently published study that investigated tracheal intubation using a Surch-lite (Aaron Medical, St. Petersburg, FL) lighted stylet in the presence of cricoid pressure (CP).<sup>1</sup>

The authors explored an interesting question: Does CP help or hinder lighted stylet intubation? The trial benefited from a well-defined protocol, comparable subject groups, standard technique, and, most importantly, a single intubator experienced in lighted stylet intubation. However, an important confounding factor was the intubator's relative inexperience using the lighted stylet in the presence of CP. Was he as good as he could be with this variation in technique? Ideally, Dr. Hodgson would have conducted the study after gaining experience and proficiency using the lighted stylet in this newer setting. Alternatively, he might have presented additional data and included a plot of serial intubation times with regular lighted stylet intubation *versus* those performed with CP. The authors allude to the problem in their

discussion: “. . . all four patients requiring two or more attempts for successful intubation with application of CP were among the first 15 patients to be enrolled in the study.”

Of most concern is the authors' opening statement, “The lightwand may be useful as an alternative for tracheal intubation during rapid-sequence induction of anesthesia in the presence of a full stomach.” We feel strongly that its use should not be advocated as a first choice or “alternative” intubation technique in this setting. Lighted stylet intubation is a blind technique that does not confer the same safety that visual assurance of tracheal intubation does in an emergency. However, it may facilitate rapid intubation when conventional techniques are impossible or have failed. Therefore, learning lighted stylet intubation with CP may be valuable.

In their discussion, the authors ponder reasons for the prolonged intubation times with CP. As we mentioned earlier, it may be secondary to difference in the intubator's experience with the two tech-

niques. The authors propose a more mechanical explanation: that there is an unopposed force from CP in lightwand intubation that is normally opposed by the laryngoscope blade in conventional approaches. This may be so with the technique used by Dr. Hodgson, but in other lighted stylet intubation techniques,<sup>2</sup> lifting force can be applied to the upper airway by lifting the mandible forward with the nondominant hand gripping the lateral jaw and molars, thereby elevating the epiglottis. Could this have made a difference in their findings? Finally, the authors did not comment on whether the hand applying CP obscured visual cues, and this could explain some delay in the CP group.

The investigators developed a technique using a Surch-lite bent to 90° with the head and neck in the “sniffing” position. In our experience, a more neutral head and neck position with the lightwand bent to a slightly obtuse (110°) angle gives more straightforward access to the larynx and easier “pushing off” of the tracheal tube. Where the internal stiffener can be withdrawn before “pushing off” (such as in the Trachlight [Laerdal, Armonk, NY]), the more acute hockey-stick for-

Anesthesiology 2001; 95:1305

*In Reply:*—I would like to thank Drs. Davis and Cook-Sather for their comments and would like to address some of the issues they have raised. Our study found that the technique of lighted stylet intubation in the presence of cricoid pressure differs sufficiently from the technique in which cricoid pressure is not applied to require a separate learning curve. As the intubator, I was as good with the technique as an experienced lighted stylet intubator would be when faced with an unexpected lighted stylet intubation in which cricoid pressure was being applied. When learning direct laryngoscopy, cricoid pressure is seldom applied purely for teaching purposes when not required clinically. The same may be true for lighted stylet intubation. The fact that a separate learning curve for lightwand intubation in the presence of cricoid pressure is required should be of value to practitioners of lighted stylet intubation because they should now be aware that the technique requires learning and practice for use in an emergency.

The times to successful intubation with and without cricoid pressure were compared in the study and were consistently longer in the cricoid pressure group, even after 30 patients and with the four patients requiring multiple attempts omitted (fig. 1).

The statement “The lightwand may be useful as an alternative for tracheal intubation during rapid-sequence induction of anesthesia in the presence of a full stomach” was made in the context of a requirement for general anesthesia in the presence of a full stomach and features suggestive of difficult direct laryngoscopy. The results of the study bear out the concerns of Davis and Cook-Sather, with 10% of patients requiring two attempts for successful intubation and a 3% failure rate after three attempts.

Regarding the technique of intubation, lifting force with the nondominant hand was applied (Material and Methods section: “The jaw was then lifted forward with the left hand of the intubating anesthesiologist”). The position of the hand was not described but was gripping the lateral jaw and molars as suggested by Davis and Cook-Sather. My fellow authors thought that the force that could be applied in this way was substantially less than that which can be applied by applying the tip of a Macintosh blade to the vallecula and using the handle of the laryngoscope as a lever. The visual cues for lighted stylet intubation

can be easily accommodated. Undoubtedly, individual experience and preferences are important determinants of successful lightwand intubation, but we wonder whether a repeat of the study with less acute angles or a Trachlight would improve intubating conditions in the presence of CP.

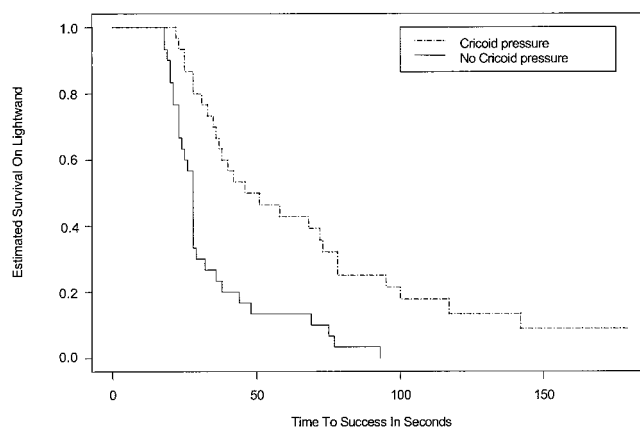
**Lionel Davis, F.R.C.A.,\* Scott D. Cook-Sather, M.D.**  
\*Royal London Hospital, London, United Kingdom.  
lionel.sarah@tinyworld.co.uk

## References

- Hodgson RE, Gopalan PD, Burrows RC, Zuma K: Effect of cricoid pressure on the success of endotracheal intubation with a lightwand. *ANESTHESIOLOGY* 2001; 94:259–62
- Davis L, Cook-Sather SD, Schreiner MS: Lighted stylet tracheal intubation: A review. *Anesth Analg* 2000; 90:745–56

(Accepted for publication July 6, 2001.)

© 2001 American Society of Anesthesiologists, Inc. Lippincott Williams & Wilkins, Inc.



**Fig. 1. Estimated survival time in lightwand intubation for 60 patients.**

were not hindered by the hand applying cricoid pressure because this involved the tips of the thumb and forefinger only.

The use of the Surch-lite bent to 90° was in accordance with published techniques<sup>1</sup> available during preparation for the study. Both Davis and Cook-Sather practice pediatric anesthesia, and the shallower 110° angle may be more appropriate in their patients than the adults in our study. However, a shallower angle and a removable stiffening stylet may prove useful and should be investigated.

**R. Eric Hodgson, M.B.,** University of Natal, Congella, South Africa.  
iti20178@mweb.co.za

## Reference

- Hung OR, Murphy M: Lightwands, lighted stylets and blind techniques of intubation. *Anesthesiol Clin North Am* 1995; 13: 477–89

(Accepted for publication July 6, 2001.)

Anesthesiology 2001; 95:1306

© 2001 American Society of Anesthesiologists, Inc. Lippincott Williams &amp; Wilkins, Inc.

## Patient "Uncontrolled" Analgesia

*To the Editor:*—We report a case of inadvertent drug administration resulting from use of a new stopcock-free intravenous system. The patient was a 40-yr-old man with end-stage renal disease scheduled for placement of an arteriovenous graft. An intravenous catheter was inserted and connected to a stopcock-free intravenous system manufactured by Budget Medical Products (San Clemente, CA). This system has ports with one-way valves that open easily when a syringe plunger is pressed.

The patient was premedicated with 2 mg midazolam and 50  $\mu$ g fentanyl and had an axillary block placed without complication. He was responsive throughout the block and was brought to the operating room for surgery. Approximately 5 min after incision, the patient was observed to be suddenly unresponsive and apneic. Mask ventilation

was instituted with ease, and it was noted that the fentanyl syringe now only contained 1 of the initial 5 ml. No one other than the patient had been near the intravenous line. It was suspected that the patient had somehow leaned on the intravenous line and inadvertently given himself a dose of fentanyl. After 10 min, spontaneous ventilation resumed, he awoke, and he was transferred to the postanesthesia care unit at the end of surgery without further problems.

We report this incident to highlight the risk of inadvertent drug administration with such intravenous systems. It seems that the best way to avoid this problem would be either to ensure that syringes do not remain connected to the system or for clinicians to return to a stopcock-based system.

**Janice M. Bitetti, M.D.,\* Marian L. Sherman, M.D.**  
\*George Washington University Medical Center, Washington, DC.  
bitettij@gwu.edu

(Accepted for publication March 29, 2001.)

Support was provided solely from institutional and/or departmental sources. Presented at George Washington University Medical Center Department of Anesthesiology and Critical Care Quality Assurance Grand Rounds, Washington, DC, November 9, 2000.

Anesthesiology 2001; 95:1306

© 2001 American Society of Anesthesiologists, Inc. Lippincott Williams &amp; Wilkins, Inc.

## Bowel and Bladder Dysfunction after Spinal Bupivacaine

*To the Editor:*—We report a case of bowel and bladder dysfunction after the intrathecal injection of hyperbaric bupivacaine. The patient was a 15-yr-old boy (weight, 60 kg; height, 180 cm) scheduled to undergo bilateral arthroscopy of the knees. He had no medical history and chose to be anesthetized by spinal anesthesia. The technique was performed using a 25-gauge Whitacre needle, with no complications or difficulties. Fifteen milligrams (3 ml) hyperbaric bupivacaine (Marcaine® Rachianesthésie; AstraZeneca, Rueil-Ma-Imaison, France) without epinephrine was injected at the L3–L4 level. Ten minutes after the spinal injection, sensory block was measured at T6; surgery was then undertaken without adverse events. Hemodynamic variables remained stable throughout the procedure. The motor block reversed 3 or 4 h later, and the patient experienced no pain, except for the pain induced by the surgical procedure. The patient was discharged to his home that evening.

The next morning, he reported bowel and bladder incontinence. He was unaware of the moment he had to defecate or urinate. Results of the neurologic examination were normal, with no motor or sensory losses. Magnetic resonance imaging was performed and ruled out compression of the sacral nerve roots or spinal canal abnormalities. The bowel dysfunction resolved that day, and the bladder dysfunction resolved in 2 weeks.

This case could be classified as a cauda equina syndrome of limited severity because sensory or motor impairments were absent. Transient neurologic dysfunctions may occur after bupivacaine spinal anesthesia.<sup>1–3</sup> In the aforementioned reports, as well in the current case, the cause of injury could not be found and therefore is likely to be related to anesthetic neurotoxicity.

In conclusion, this is one of the few reports of such a serious complication after "one-shot" spinal anesthesia in a young and healthy patient, with a dose of bupivacaine that is widely used in current clinical practice.

**Chahé Mardirosoff, M.D.,\* Lionel Dumont, M.D.** \*Polyclinique de Savoie, Annemasse, France. chahe@yahoo.com

### References

1. Auroy Y, Narchi P, Messiah A, Litt L, Rouvier B, Samii K: Serious complications related to regional anesthesia: results of a prospective survey in France. *ANESTHESIOLOGY* 1997; 87:479–86
2. Pley H, Spigset O: Peripheral neurologic deficits in relation to subarachnoid or epidural administration of local anesthetics for surgery: A survey of 21 cases. *Acta Anaesthesiol Scand* 1997; 41:453–60
3. Aromaa U, Lahdensuu M, Cozantitis DA: Severe complications associated with epidural and spinal anaesthetics in Finland 1987–1993: A study based on patient insurance claims. *Acta Anaesthesiol Scand* 1997; 41:445–52

(Accepted for publication April 16, 2001.)

Support was provided solely from institutional and/or departmental sources.

## Epidural Hematoma after Epidural Steroid Injection: A Possible Association with Use of Pentosan Polysulfate Sodium

*To the Editor:*—There have been several cases of epidural hematoma after administrations of low-molecular-weight heparin, enoxaparin. We describe a case of epidural hematoma in a patient taking pentosan polysulfate sodium.

A 63-yr-old woman was referred to the pain clinic after reporting chronic lower back pain. The magnetic resonance films showed severe degenerative disc disease, spinal stenosis from T11 to L4, and bilateral facet hypertrophy at multiple levels. Her medical history was significant for interstitial cystitis, and she was taking pentosan polysulfate sodium (Elmiron; Baker Norton Pharmaceuticals, Inc., Miami, FL). She was also taking 300 mg gabapentin (Neurontin; Parke-Davis, Morris Plains, NJ) three times a day and 25 mg amitriptyline (Elavil; Zeneca Pharmaceuticals, Wilmington, DE) orally at night. Lumbar epidural steroid injection, without stopping her current medications, was planned and was performed under fluoroscopic guidance uneventfully. Two weeks later, because there was no improvement in the pain, a second epidural steroid injection was performed, along with bilateral L3-L4, L4-L5, and L5-S1 facet steroid injections under fluoroscopic guidance. Approximately 8 h after the procedure, the patient reported severe lower back pain, and physical examination revealed lower back tenderness with decreased range of motion at the lumbosacral spine, with no sensory or motor deficit. The magnetic resonance scans revealed an epidural collection of blood from T11 to L3. It was initially elected to observe her, but 12 h later, numbness developed in her right foot, and she underwent immediate laminectomy from T11 to L2, with uneventful evacuation of the epidural blood clot. No other abnormalities were detected. Postoperatively, there was no neurologic deficit, and the patient left for home 3 days later.

In this patient, there was no history of bleeding disorder, and she was not taking any conventional anticoagulant medication. She was taking pentosan polysulfate for treatment of interstitial cystitis. Pen-

tosan polysulfate is a semi-synthetic compound similar to low-molecular-weight heparin with a weak anticoagulant property. The oral bioavailability of the drug is minimal.<sup>1</sup> Pentosan is shown to be efficacious in the treatment of pain, the urgency, and the frequency associated with interstitial cystitis.<sup>2</sup> Although the exact mechanism of action for pentosan in interstitial cystitis is not known, it is thought to act as a buffer to control cell permeability, preventing irritating solutions in the urine from reaching cells. The elimination half-life of the drug is approximately 4–6 h, and the liver and spleen are the primary sites for metabolism. Pentosan can decrease factor V concentration, but serious bleeding complications associated with its use are rare.<sup>3</sup>

We cannot be certain that this patient's epidural hematoma was related to pentosan; it might have been a direct consequence of multiple needle punctures. However, an extensive epidural hematoma that leads to neurologic symptoms, as seen in this patient, is unlikely to arise from needle trauma alone. To the best of our knowledge, there are no cases of epidural hematoma in association with pentosan reported in the medical literature, and this is probably the first case that suggests an association with pentosan use.

**Meraj N. Siddiqui, M.D.,\* J. Sue Ranasinghe, M.D., Shazia Siddiqui, M.D.** \*Jackson Memorial Hospital—University of Miami, Miami, Florida. msiddiqui66@hotmail.com

### References

1. Faaiz RA, Srivastava N, van Griensven JM, Schoemaker RC, Kluff C, Burggraaf J, Cohen AF: The oral bioavailability of pentosan polysulphate sodium in healthy volunteers. *Eur J Clin Pharmacol* 1999; 54:929–35
2. Hwang P, Auclair B, Beechinor D, Diment M, Einarson TR: Efficacy of pentosan polysulfate in the treatment of interstitial cystitis: A meta-analysis. *Urology* 1997; 50:39–43
3. De Prost D, Guerot C, Karsenty F: Pentosane polysulfate: The effect on hemostasis of a continuous 3-day infusion. *Clin Pharmacol Ther* 1985; 38:171–5

(Accepted for publication July 5, 2001.)

Support was provided solely from institutional and/or departmental sources.