

Does Acute Normovolemic Hemodilution Work in Cardiac Surgery?

To the Editor:—In a recent article by Höhn *et al.*¹, it was concluded that acute normovolemic hemodilution (ANH) in addition to aprotinin was not beneficial in preventing allogeneic blood transfusions compared to aprotinin alone in cardiac surgery. In this randomized, controlled trial, the patients were hemodiluted to a hematocrit of 28% pre-cardiopulmonary bypass (CPB). The transfusion threshold was set at 17% during CPB and at 25% for post-CPB. The total fluid replacement was in excess relative to the amount of ANH (autologous blood) removed (6.4 ± 2.1 l of crystalloid, 2.0 ± 0.7 l of colloid).² This led to excessive hemodilution, reducing the hematocrit below the transfusion threshold in the ANH group. Indeed, 50% of the patients in the ANH group required either all (33%) or a portion (22%) of the autologous blood to be transfused during CPB, thus negating its positive effects on erythrocytes and coagulation protection. Consequently, allogeneic erythrocyte transfusion rates and the indirect clinical markers for surgical bleeding (cell saver and 24-h chest tube drainage) were not different between the two groups. One of the goals of ANH is to protect the autologous blood from the negative effects of CPB and to return it after heparin neutralization. Additional hemodilution occurs with the onset of CPB; therefore, hemofiltration or ultrafiltration and/or diuresis should have been employed to remove excess fluid. Alternatively, ANH can be performed just prior to the onset of CPB (by diverting heparinized blood into a storage bag), thus preventing excessive dilutional anemia.³

The criteria for exclusion from this study were left main disease, severe aortic stenosis, recent myocardial infarction, unstable angina, ejection fraction below 30%, severe carotid stenosis, combined coronary artery bypass grafting and valve cases, respiratory insufficiency, renal insufficiency, and anemia (hemoglobin < 12 g/dl). This exclusion process resulted in the selection of a group of patients that we know are at low risk for allogeneic transfusions. Our data (shown below) and those of other investigators demonstrate that patients presenting with adequate hemoglobin levels (average starting hematocrit of 43.3%, body surface area of 1.86) rarely require allogeneic blood.^{4,5}

At our institution, the cardiac surgery program utilizes a multidisciplinary approach to blood conservation. In over 300 cardiac surgery cases (coronary artery bypass grafting, valves, and combined proce-

dures), we remove on average 1280 ml of ANH blood per case (based on a formula to reach a target hematocrit on bypass of 20%).⁶ The average amount of fluid used for replacement was 1680 ml of crystalloid and 591 ml of colloid (Hextend®, Abbott Laboratories, North Chicago, IL). Hemofiltration or ultrafiltration and/or induced diuresis is frequently utilized on CPB to remove excess fluids and to reduce the dilutional effect from the CPB prime. The starting hematocrit averages 39%. We use ϵ -aminocaproic acid for low-risk cases and reserve aprotinin (Trasylol®, Bayer, West Haven, CT) for high-risk cases. The total amount of cell saver returned is approximately 200 ml, and 24-h chest tube drainage is 428 ml. Allogeneic transfusion rates for packed erythrocytes, fresh frozen plasma, and cryoprecipitate are 11%, 3%, and less than 1%, respectively.

David M. Moskowitz, M.D.,* Seth I. Perelman, M.D., Aryeh Shander, M.D., James J. Klein, M.D., *Englewood Hospital and Medical Center, Englewood, New Jersey. david.moskowitz@ehmc.com

References

1. Hohn L, Schweizer A, Licker M, Morel DR: Absence of beneficial effect of acute normovolemic hemodilution combined with aprotinin on allogeneic blood transfusion requirements in cardiac surgery. *ANESTHESIOLOGY* 2002; 96:276-82
2. Weiskopf RB: Mathematical analysis of isovolemic hemodilution indicates that it can decrease the need for allogeneic blood transfusion. *Transfusion* 1995; 35:37-41
3. Petry AF, Jost J, Sievers H: Reduction of homologous blood requirements by blood-pooling at the onset of cardiopulmonary bypass. *J Thorac Cardiovasc Surg* 1994; 107:1210-4
4. Rosengart TK, Helm RE, DeBois WJ, Garcia N, Krieger KH, Isom OW: Open heart operations without transfusion using a multimodality blood conservation strategy in 50 Jehovah's Witness patients: Implications for a "bloodless" surgical technique. *J Am Coll Surg* 1997; 184:618-29
5. Ovrum E, Holen EA, Abdelnoor M, Oystese R: Conventional blood conservation techniques in 500 consecutive coronary artery bypass operations. *Ann Thorac Surg* 1991; 52:500-5
6. Helm RE, Klemperer JD, Rosengart TK, Gold JP, Peterson P, DeBois W, Altorki NK, Lang S, Thomas S, Isom OW, Krieger KH: Intraoperative autologous blood donation preserves red cell mass but does not decrease postoperative bleeding. *Ann Thorac Surg* 1996; 62:1431-41

(Accepted for publication June 20, 2002.)

In Reply:—We appreciate the interest of Moskowitz *et al.* regarding our article.¹ They hypothesize that too restrictive inclusion criteria and excessive fluid replacement in the acute normovolemic hemodilution (ANH) group could explain the absence of beneficial effects of ANH.

First, for obvious ethical reasons, we selected patients to undergo preoperative ANH based on the recommendations of the British Committee for Standards in Blood Transfusion, which take into account the potential risks and benefits of blood salvage techniques. Therefore, due to the risk of myocardial ischemia, stroke, or heart failure, we did not perform ANH in patients with severe coronary artery disease (recent myocardial infarction, unstable angina, left main coronary stenosis), severe aortic stenosis, poor left ventricular function, carotid stenosis, and/or preoperative anemia. According to these stringent exclusion criteria, we included only 57% of all consecutive patients undergoing elective coronary revascularization or valvular surgery. Nevertheless, a high risk of bleeding was considered in more than 50% of these surgical candidates (preoperative anticoagulant and/or aspirin therapy,

repeat or combined operation) in whom the blood-sparing benefits of ANH could be anticipated.

Second, perioperative fluid hydration was similar in both groups, except for compensation of the removed blood by colloids in the ANH group: the volumes of infused crystalloids ($94.6 \text{ ml} \cdot \text{kg}^{-1} \cdot 24 \text{ h}^{-1}$ and $88.8 \text{ ml} \cdot \text{kg}^{-1} \cdot 24 \text{ h}^{-1}$ in the control and ANH groups, respectively) and colloids ($16.5 \text{ ml} \cdot \text{kg}^{-1} \cdot 24 \text{ h}^{-1}$ and $26.2 \text{ ml} \cdot \text{kg}^{-1} \cdot 24 \text{ h}^{-1}$ in the control and ANH groups, respectively) were in the range of the values commonly reported² and included any solution administered intravenously and through the cardiopulmonary bypass (*e.g.*, cardioplegia, priming). To achieve similar cardiac preload conditions, larger than expected volume of colloids were given in the ANH group (hypervolemic compensation), which resulted in ANH-induced vasodilatation and reduced blood viscosity.³ Since ANH is known to be associated with poor tolerance to acute blood loss and impaired adrenergic response,^{4,5} we closely guided fluid administration using transesophageal echocardiography and central venous pressure monitoring in order to avoid hypovolemia and to detect myocardial ischemia.

Finally, as suggested by Dr. Moskowitz and others,⁶ we agree that the implementation of a standardized, multidisciplinary approach, including definition of transfusion criteria, administration of antifibrinolytic drugs, use of cell saver devices, and external heating, is most helpful to reduce transfusion of allogenic blood products in patients undergoing cardiac surgery. However, evidence supporting the addition of ANH as a blood-sparing technique is still lacking, although a consensus is based on data from observational studies and prospective, unblinded, randomized trials.⁷

Marc J. Licker, M.D., Laurent Hohn, M.D., Alexandre Schweizer, M.D., Denis R. Morel, M.D.,* University Hospital of Geneva, Switzerland. denis.morel@hcuge.ch

References

1. Hohn L, Schweizer A, Licker M, Morel DR: Absence of beneficial effect of acute normovolemic hemodilution combined with aprotinin on allogeneic blood transfusion requirements in cardiac surgery. *ANESTHESIOLOGY* 2002; 96:276-82

2. von Spiegel T, Giannaris S, Wietasch GJ, Schroeder S, Buhre W, Schorn B, Hoefl A: Effects of dexamethasone on intravascular and extravascular fluid balance in patients undergoing coronary bypass surgery with cardiopulmonary bypass. *ANESTHESIOLOGY* 2002; 96:827-34

3. Doss DN, Estafanous FG, Ferrario CM, Brum JM, Murray PA: Mechanism of systemic vasodilation during normovolemic hemodilution. *Anesth Analg* 1995; 81:30-4

4. Shinoda T, Mekhail NA, Estafanous FG, Smith C, Khairallah PA: Hemodynamic responses to dobutamine during acute normovolemic hemodilution. *J Cardiothorac Vasc Anesth* 1994; 8:545-51

5. Schou H, Kongstad L, Perez de Sa V, Werner O, Larsson A: Uncompensated blood loss is not tolerated during acute normovolemic hemodilution in anesthetized pigs. *Anesth Analg* 1998; 87:786-94

6. Van der Linden P, De Hert S, Daper A, Trenchant A, Jacobs D, De Boelpepe C, Kimbimbi P, Defrance P, Simoons G: A standardized multidisciplinary approach reduces the use of allogeneic blood products in patients undergoing cardiac surgery. *Can J Anaesth* 2001; 48:894-901

7. Bryson GL, Laupacis A, Wells GA: Does acute normovolemic hemodilution reduce perioperative allogeneic transfusion? A meta-analysis. *The International Study of Perioperative Transfusion. Anesth Analg* 1998; 86:9-15

(Accepted for publication June 20, 2002.)

Anesthesiology 2002; 97:1323

© 2002 American Society of Anesthesiologists, Inc. Lippincott Williams & Wilkins, Inc.

Hepatic Failure after Cardiopulmonary Bypass Is Unlikely to Be Isoflurane Hepatitis

To the Editor:—In the article by Njoku *et al.*¹ in the March 2002 issue of *ANESTHESIOLOGY*, they describe a patient who developed nonfatal hepatic failure 24–48 h after coronary artery surgery on cardiopulmonary bypass. The authors suggest, “that the hepatitis may have been caused by isoflurane.”

The patient was a 66-yr-old man with arteriopathy who had non-insulin-dependent (type 11) diabetes mellitus, chronic obstructive pulmonary disease, hypertension, coronary artery disease, and carotid artery disease. Two months prior to his coronary artery surgery, the patient had been anesthetized with isoflurane for a carotid endarterectomy.

During his operation, but prior to the establishment of cardiopulmonary bypass, the patient received norepinephrine and nitroglycerin to support his circulation and hemodynamic performance. His bypass time was 110 min, and his aortic cross-clamp time was 89 min.

The authors of this case report state, “we provide clinical, histologic, and immunohistochemical evidence supporting a possible role of trifluoroacetyl-modified protein (TFAMPs) in hepatitis associated with isoflurane.” I believe that the patient’s postoperative hepatic failure was much more likely to be caused by an operative hepatic perfusion problem than from any event initiated by isoflurane.

The National Halothane Study² investigated the administration of 254,896 halothane anesthetics. There were 14,100 patients who received halothane on two or more occasions. In this study, it was calculated that the fatality rate following multiple exposure to halothane within a 6-week period was 1 in 3,525. The incidence of hepatic failure after a second isoflurane anesthetic within 2 months is unknown, although it is universally agreed that the incidence of hepatic failure after isoflurane anesthesia is much less than the incidence of hepatic failure after halothane anesthesia. The incidence of hepatic failure after two isoflurane anesthetics would be much less than 1 in 3,525. This should be compared with the incidence of hepatic failure following cardiopulmonary bypass, from low regional blood flow, of 1 in 1,500.³

The biopsy findings presented in the case report are equally compatible with hepatic failure that has been caused by hepatic artery hypotension, hepatic or portal vein hypertension, and toxic or immu-

nologic injury to the hepatocyte. It is generally agreed that anesthetic agent hepatitis cannot be confidently diagnosed from an examination of a patient’s hepatic histopathology.

It would seem that the authors’ claim that the patient’s postoperative hepatic failure was due to isoflurane hepatitis rests heavily on the immunohistologic studies. These studies show that the trifluoroacetyl moiety was demonstrated in the mitochondria, the endoplasmic reticulum, the nuclear membrane, and the nucleus of the hepatocyte. The presence of the trifluoroacetyl moiety at these sites does not prove that the trifluoroacetyl moiety induced any injury in the hepatocyte. In every patient anesthetized with isoflurane, a small amount of the absorbed isoflurane is metabolized in the liver to trifluoroacetic acid, which is then excreted in the urine. During the metabolism of isoflurane to trifluoroacetic acid in the liver, intermediate metabolites are produced, and it would seem likely that the hepatic metabolites of isoflurane that have been identified by the authors are of no pathologic significance.

On the balance of probability, it is 100 times more likely that this patient’s hepatic failure was related to some intraoperative event rather than to isoflurane hepatitis. The connection between the hepatic failure and the isoflurane administered during this patient’s anesthesia is merely coincidental.

Harry J. Wark, M.D., M.B., B.S., F.R.C.A., Children’s Hospital Westmead, Sydney, Australia. awark@bigpond.net.au

References

1. Njoku DB, Shrestha S, Soloway R, Duray PR, Tsokos M, Abu-Asab MS, Pohl LR, West AB: Subcellular localization of trifluoroacetyl liver proteins in association with hepatitis following isoflurane. *ANESTHESIOLOGY* 2002; 96:757-61

2. Bunker JP, Mosteller F, Vandam LD: National Halothane Study: A Study of the Possible Association between Halothane Anesthesia and Post-operative Hepatic Necrosis. Washington, DC, US Government Printing Office, 1969.

3. Yilmaz AT, Arslan M, Demirkilic U, Ozal E, Kuralay E, Bingol H, Oz BS, Tatar H, Ozturk OY: Gastrointestinal complications after cardiac surgery. *Eur J Cardiothorac Surg* 1996; 10:763-7

(Accepted for publication July 25, 2002.)

Anesthesiology 2002; 97:1324

© 2002 American Society of Anesthesiologists, Inc. Lippincott Williams & Wilkins, Inc.

In Reply:—In Dr. Wark's letter, he states, "hepatic failure after cardiopulmonary bypass is unlikely to be isoflurane hepatitis." In response, I will borrow an Asian proverb: "A journey of a thousand miles must begin with a single step."

Dr. Wark introduces alternative views of a classic argument. We both agree that hepatotoxicity can occur following halothane administration. However, we disagree about hepatotoxicity when other halogenated volatile anesthetics are considered. Nonetheless, hepatotoxicity following halogenated volatile anesthetics, including isoflurane, is believed to be idiosyncratic,¹ and immune-mediated processes are believed to have a role in this injury, similar to other forms of idiosyncratic drug-induced hepatotoxicity.² There are several reports of immune responses and hepatotoxicity following isoflurane administration.¹ More importantly, in this case report, isoflurane was implicated after critically examining other possible causes of hepatotoxicity and was not based on histologic findings alone.

This case report takes forward steps in the journey of a thousand miles to the discovery of the etiologies of drug-induced hepatotoxicity. The first step was also taken by those before us. We demonstrated liver injury following isoflurane administration. Norepinephrine and nitroglycerin were administered, but hypotension or other evidence of ischemia was not demonstrated. The article from 1996 referenced by Dr. Wark clearly states the risk factors for gastrointestinal complications after cardiopulmonary bypass: advanced age, combined coronary artery bypass grafting–valve operation, postoperative low cardiac output, prolonged ventilation time, reexploration of the chest, sternal infection, and a history of peptic ulcer. In our report, the patient was 66 yr old, underwent a three-vessel coronary artery bypass graft, and maintained mean arterial pressures ≥ 70 mmHg for > 48 h intraoperatively and postoperatively during the initial demonstration of increased aspartate aminotransferase. Therefore, if Dr. Wark's probability was correct, the only risk factor was age.

By showing that the patient had several risk factors for volatile anesthetic-induced liver injury, additional steps were taken. The patient had received two anesthetics in 3 months; developed a relapsing fever postoperatively, which could suggest the presence of an immune-mediated process; and also developed significant increases in serum transaminases. The immunohistochemical evidence was supportive since the trifluoroacetyl-modified proteins were detected in centrilobular areas, suggesting drug-induced liver injury, and were associated with cytoplasmic organelles, suggesting specificity. Surprisingly, the trifluoroacetyl-modified proteins were detected after 72 h at concentrations previously not seen with isoflurane. Surely, the increased amount of trifluoroacetyl-modified proteins may have been caused by reduced hepatic clearance from global hepatic dysfunction induced by other causes. However, if this was the case, anesthetic metabolism should have been impaired as well.

Our gastroenterology colleagues completed another step in the journey by documenting identical histologic evidence of hepatotoxicity in a patient 5 days after isoflurane exposure for a different surgical procedure.³ We would like to thank Dr. Wark for his comments. We will only move forward by having these kinds of discussions.

Dolores B. Njoku, M.D., Johns Hopkins Medical Institutions, Baltimore, Maryland. dnjoku@jhmi.edu

References

1. Njoku DB, Shrestha S, Soloway R, Duray PR, Tsokos M, Abu-Asab M, Pohl LR, West AB: Subcellular localization of trifluoroacetyl liver proteins in association with hepatitis following isoflurane. *ANESTHESIOLOGY* 2002; 96:757–61
2. Van Pelt FN, Straub P, Manns MP: Molecular basis of drug-induced immunological liver injury. *Semin Liver Dis* 1995; 15:283–300
3. Yilmaz AT, Arslan M, Demirkilic U, Ozal E, Kuralay E, Bingol H, Oz BS, Tatar H, Ozturk OY: Gastrointestinal complications after cardiac surgery. *Eur J Cardiothorac Surg* 1996; 10:763–7

(Accepted for publication July 25, 2002.)

Anesthesiology 2002; 97:1324–5

© 2002 American Society of Anesthesiologists, Inc. Lippincott Williams & Wilkins, Inc.

Oral to Nasal Endotracheal Tube Exchange in a Difficult Airway: A Novel Method

To the Editor:—There is a significant risk of losing a proven difficult airway during nasal to orotracheal tube exchange.¹ Various methods are described to achieve such conversions,^{1–5} but they are associated with technical disadvantages intrinsic to the method, lack of an optimal aid, procedural complications, and the stage at which the need for conversion arises.^{3,6}

We successfully converted an oral endotracheal tube (ETT) to a nasal ETT in an 11-yr-old girl presenting for reconstruction of a postmandibulectomy defect secondary to osteogenic carcinoma. Airway assessment revealed agnathia, bucked incisors, a large tongue occupying the oral cavity, postradiotherapy contracture and scarring of the anterior neck, and a postracheostomy scar. Neck mobility was adequate, and the nares were patent. The lateral view radiograph of the head and neck showed a large tongue base, an anteriorly placed larynx, and a noncompressed air column.

In view of the aforementioned findings, a flexible fiberoptic bronchoscope (FFB)–guided nasotracheal intubation was planned under sedation. Premedication included 150 mg ranitidine orally and intramuscular glycopyrrolate 1 h prior to the procedure. Informed consent was obtained from the parents after explaining the procedure. The

child was moved to the operating room, and routine monitoring was applied. The nasopharynx was anesthetized with 10% lidocaine spray. Propofol, 1 mg/kg, was administered, and the FFB (FB-10X; Pentax, Tokyo, Japan) was introduced *via* the right naris and advanced further while the child breathed 100% oxygen *via* a nasal cannula placed in the left naris. The fibroscope repeatedly met the large tongue base, obstructing the view. Oral fibroscopy also failed to negotiate the base of the tongue on multiple attempts. By this time, the child had desaturated to an oxygen saturation of 90%. Flexible fiberoptic bronchoscopy was abandoned. Direct laryngoscopy (Miller blade #2) showed a Cormack and Lehane⁷ grade III cords view. A 5.5-mm uncuffed ETT was blindly placed into the trachea with the help of a stylet. One hundred percent oxygen was given, and saturation improved. As per the requirement of the procedure, oral to nasotracheal tube conversion was then performed. The FFB was advanced *via* the right naris and retrieved orally. The proximal end of the existent oral ETT holding the connector was cut. The fibroscope was passed through the oral tube to just above the carina. The tube-FFB assembly was grasped with fingers inside the oral cavity, and the tip of the fibroscope was anteriorly flexed to prevent dislodgment. The fibroscope and the ETT were gradually withdrawn retrogradely through the nasal passage and out of the naris. The FFB was removed, bilateral air entry was reconfirmed,

Support was provided solely from institutional and departmental sources.

and the ETT was secured. The conversion took 80 s and was atraumatic and without any desaturation. Thereafter, anesthesia was maintained with 1–2% halothane and 66% nitrous oxide in oxygen.

The FFB may be a less than ideal device to gain airway control in certain difficult airway situations.⁸ Orally or nasally guided flexible fiberoptic bronchoscopy may fail to locate the glottis adequately in conditions in which the airway anatomy is distorted.^{5,9,10} Partial and complete airway obstruction add to the difficulty of fibroscopy, and certain maneuvers^{11,12} and intubation¹³ have proven effective in opening up the airway.

Our patient was a child with major airway abnormalities. This resulted in the following problems: (1) the maneuvers designed to aid oral and nasal flexible fiberoptic bronchoscopy were inapplicable, (2) we could not have kept the child awake before airway control, and (3) nasotracheal intubation was necessary. The former two presumably led to the failure of our FFB-aided intubation attempts. The last problem posed a significant challenge. We were able to convert the existing oral ETT to a nasotracheal tube with the help of the FFB, but the limitations of this method can be manifold, such as breakage of optical fibers, trauma, failure, and/or inadvertent extubation. An uncuffed polyvinyl chloride ETT is flexible enough to allow bending without transmitting tension to the FFB. The absence of jaw and tongue retraction led to minimal oral space in our patient, which significantly decreased the arc of negotiation of the FFB-ETT unit and consequently prevented damage to the optical fibers. Moreover, the possibility of accidental extubation was lessened, as the tube and the FFB were firmly grasped, the tip of the fiberscope was anteriorly flexed, and the pull of the FFB through nose was gentle. FFBs have been utilized previously to effect safer conversion of a nasal tube to an oral tube.^{5,14} Ours is probably the first case in which an oral to nasal ETT conversion was carried out with the help of a FFB. This case not only reiterates the few significant limitations of the FFB while gaining a difficult airway, but it also shows that deft handling of this delicate equipment may improve outcome.

Amitabh Dutta, M.D., Pramila Chari, M.D., M.N.A.M.S., F.A.M.S.,* Ram A. Mohan, M.D., Yogesh Manhas, M.B.B.S., *Postgraduate Institute of Medical Education and Research, Chandigarh, India. pchari@glide.net.in

References

1. Gabriel DM, Azocar RJ: A novel technique for conversion of nasotracheal tube to orotracheal. *ANESTHESIOLOGY* 2000; 93:911
2. Cooper RM: Conversion of a nasal to an orotracheal intubation using an endotracheal tube exchange. *ANESTHESIOLOGY* 1997; 87:717–8
3. Novella J: Intraoperative nasotracheal to orotracheal tube change in a patient with Klippel-Feil syndrome. *Anaesth Intensive Care* 1995; 23:402–4
4. Hartmannsgruber MW, Rosenbaum SH: Safer endotracheal tube exchange technique (letter). *ANESTHESIOLOGY* 1998; 88:1683
5. Tapnio RU, Viegas OJ: An alternative method of conversion of a nasal to an orotracheal intubation (letter). *ANESTHESIOLOGY* 1998; 88:1683–4
6. Seidan AM: Sinusitis in the critical care patient. *New Horiz* 1993; 1:261–70
7. Cormack RS, Lehane J: Difficult tracheal intubation in obstetrics. *Anaesthesia* 1984; 39:1105–11
8. Mason RA: The obstructed airway in head and neck surgery. *Anaesthesia* 1999; 54:625–8
9. Kanaya N, Nakayama M, Seki S, Kawana S, Watanabe H, Namiki A: Two-person technique for fiberscope-aided tracheal intubation in a patient with long and narrow retropharyngeal airspace. *Anesth Analg* 2001; 92:1611–3
10. Podder S, Dutta A, Chari P: Retropharyngeal extension of goiter in a morbidly obese patient leading to a difficult airway. *Anaesthesia* 2000; 55:1219–21
11. Durga VK, Millns JP, Smith JE: Maneuvers used to clear the airway during fiberoptic intubation. *Br J Anaesth* 2001; 87:201–11
12. Ovassapian A: *Fiberoptic Endoscopy and the Difficult Airway*, 2nd edition. Philadelphia, Lippincott-Raven, 1996, pp 71–103
13. Berman RA: A method for blind intubation of the trachea or esophagus. *Anesth Analg* 1977; 66:866–7
14. Rosenbaum SH, Rosenbaum LM, Cole RP, Askanazi J, Hyman AI: Use of the flexible fiberoptic bronchoscope to change endotracheal tubes in critically ill patients. *ANESTHESIOLOGY* 1981; 54:169–70

(Accepted for publication June 11, 2002.)

Anesthesiology 2002; 97:1325

© 2002 American Society of Anesthesiologists, Inc. Lippincott Williams & Wilkins, Inc.

Use of the Arndt Wire-guided Endobronchial Blocker

To the Editor:—The Arndt fiberoptically directable, wire-guided endobronchial blocker (William Cook Europe A/S, Bjaeverskor, Denmark) is a useful tool to achieve one-lung ventilation with an endotracheal tube in a variety of clinical settings.¹ The endobronchial blocker is placed coaxially through a conventional endotracheal tube using a pediatric bronchoscope and a special bronchoscopy port. The special bronchoscopy port offers multiple access ports, allowing simultaneous introduction of the bronchoscope and the endobronchial blocker while maintaining ventilation of the lungs. The endobronchial port (wire-guided endobronchial blocker port), which is oriented at 30° to the bronchoscopy port, has a Tuohy-Borst-type valve that locks the blocker in place and maintains an airtight seal. The elliptical balloon of the blocker must be deflated and the wire-guided endobronchial blocker port unthreaded before removing the endobronchial blocker.

After successfully using the wire-guided endobronchial blocker system for one-lung ventilation, we encountered resistance at the level of the Tuohy-Borst valve on attempting to remove the deflated blocker. After ensuring that the valve was fully open, the blocker was pulled out, but the balloon was sheared from the catheter. The special bronchoscopy port was quickly disconnected from the endotracheal tube, and the sheared balloon was recovered in one piece (fig. 1).

Based on our experience, we suggest removing the valve cap before removing the endobronchial blocker.

Mahesh R. Prabhu, M.B.B.S., F.R.C.A.,* Jonathan H. Smith, M.B.Ch.B., M.R.C.P., F.R.C.A., *Freeman Hospital, Newcastle upon Tyne, United Kingdom. prabhum@doctors.org.uk

Reference

1. Arndt GA, Kranner PW, Rusy DA, Love R: Single-lung ventilation in a critically ill patient using a fiberoptically directed wire-guided endobronchial blocker. *ANESTHESIOLOGY* 1999; 90:1484–6

(Accepted for publication June 26, 2002.)

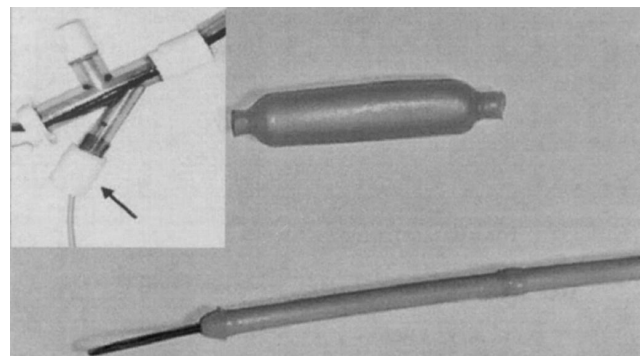


Fig. 1. Sheared balloon of the Arndt endobronchial blocker. Insert shows the endobronchial blocker passing through the Tuohy-Borst valve (arrow) of the special bronchoscopy port.

Support was provided solely from institutional and/or departmental sources.

Use of a *LMA*TM and a Sequential Technique for Unanticipated Difficult Intubations

To the Editor:—For difficult airway management in pediatric patients, a technique using a laryngeal mask airway (*LMA*TM; Laryngeal Mask Company, Nicosia, Cyprus), a fiberoptic bronchoscope (FOB), wire insertion, and an endotracheal exchange catheter has been described.^{1,2} We have employed a similar technique in adults when dealing with an unanticipated difficult airway after induction of anesthesia. In an anesthetized patient, the technique is as follows: insertion of an appropriate-sized *LMA*TM and ventilation of the patient; passage of a FOB through a collapsible elbow connector, through the *LMA*TM, and into the trachea; passage of a guide wire (0.081-cm diameter, 145-cm length; Cook Urological, Spencer, IN) through the FOB suction port and into the trachea; withdrawal of the FOB, leaving the wire in place; passage of an endotracheal tube exchange catheter (Cook Critical Care, Bloomington, IN) over the wire and into the trachea; withdrawal of the *LMA*TM; and insertion of a standard endotracheal tube over the exchange catheter. Direct laryngoscopy is useful at this point to guide the endotracheal tube through the mouth and under the epiglottis. Assuming that ventilation with a *LMA*TM is successful, this technique allows almost continuous control of the airway with manual or mechanical ventilation except during the last step; an unhurried sequential approach allowing deliberate use of the FOB; minimal trauma, as the devices employed are designed for soft tissue use; and final intubation with a conventional endotracheal tube of adequate

Support was provided solely from institutional and/or departmental sources.

size. Of note, we have observed that a standard *LMA*TM works best rather than an intubating type.

Larger endotracheal tubes (sizes ≥ 7.0) may be difficult to insert directly through a *LMA*TM over a FOB, and the endotracheal tubes used with intubating airways have a higher pressure cuff than standard tubes. This is of greater importance when postoperative ventilation is anticipated. Smaller endotracheal tubes placed over a FOB and through a *LMA*TM may secure an airway but may result in problems with weaning or may be generally unsuitable for prolonged ventilation, especially in large patients.

We have used this technique successfully many times during the last 3 yr, and it is now our initial approach to the unanticipated difficult airway in patients undergoing cardiovascular surgery.

John R. Cooper, Jr., M.D., Texas Heart Institute, Houston, Texas.
jcooper@heart.thi.tmc.edu

References

1. Hasan MA, Black AE: A new technique for fibreoptic intubation in children. *Anaesthesia* 1994; 49:1031-3
2. Walker RW, Allen DL, Rothera MR: A fibreoptic intubation technique for children with mucopolysaccharidoses using the laryngeal mask airway. *Paediatr Anaesth* 1997; 7:421-6

(Accepted for publication July 24, 2002.)