

## Persistent Phrenic Nerve Paralysis following Interscalene Brachial Plexus Block

Sébastien Robaux, M.D.,\* Hervé Bouaziz, M.D., Ph.D.,† Nicolas Boisseau, M.D.,‡ Marc Raucoules-Aimé, M.D.,§ Marie-Claire Laxenaire, M.D.,|| the S.O.S. Regional Hot Line Service#

WE report a case of permanent phrenic nerve paralysis with hemidiaphragmatic palsy after interscalene brachial plexus block.

### Case Report

A 60-yr-old man, 160 cm tall, weighing 75 kg, with American Society of Anesthesiologists physical status class II, was admitted for elective right shoulder surgery. His medical history was unremarkable except for recent mild diabetes with no related neuropathy, controlled by diet and glimepiride. Physical examination results were unremarkable, and the results of laboratory studies were all within normal limits, including preoperative glycemia and chest x-ray. He agreed to undergo a combination of regional and general anesthesia.

Hydroxyzine, 100 mg, was administered 2 h preoperatively. After application of routine monitors, intravenous access was secured. He was positioned supine with the head turned to the contralateral side, and the right side of the neck was prepared as a sterile field. The elbow was flexed, with the forearm lying on the patient's abdomen. Thereafter, interscalene brachial plexus block was performed as described by Winnie but using a nerve stimulator to ascertain that the needle's tip was in the brachial plexus. The plexus was located with a nerve stimulator (Stimuplex HNS 11; B/Braun, Melsungen, Germany) and an insulated needle, 25 mm long with a short 30° bevel (Stimuplex, B/Braun). Three attempts at needle insertion were required to achieve an appropriate motor response: the brachial plexus was first located using a high current intensity (2 mA; 0.1 ms and 1 Hz), and then it was decreased to 0.5 mA to refine the approach. After obtaining a motor response of the deltoid muscle, a mixture of 30 ml ropivacaine, 0.75%, and 75 µg clonidine was injected. No blood could be aspirated, and the patient reported neither pain nor paresthesia during the procedure, although phrenic nerve stimulation was transiently observed.

After 20 min, profound surgical anesthesia was established on C5-C7 dermatomes. Then, general anesthesia was induced with 2 mg midazolam, 100 µg fentanyl, 200 mg propofol, and 30 mg atracurium to facilitate tracheal intubation. General anesthesia was maintained with 1-2% sevoflurane and 50% nitrous oxide, and the patient underwent a right rotator cuff repair *via* a deltopectoral approach. He was placed in a "beach chair" position with his head turned the opposite

direction. Vital signs and standard parameters remained stable throughout the 2-h procedure.

At the end of surgery, the trachea was extubated, and the patient was observed for 1 h in the postanesthesia care unit. He did not report any pain. Vital signs and postoperative glycemia were normal. The interscalene brachial plexus blockade was still effective. Postoperative analgesia consisted of regular administration of a combination of propacetamol and nefopam intravenously. The patient was discharged to the ward. Postoperative follow-up was unremarkable.

Ten days later, the patient was readmitted to the hospital because of increasing shortness of breath. A chest roentgenogram revealed marked elevation of the right hemidiaphragm when compared with the preoperative chest film. No signs of infection or other disorders were shown on the film. This pattern was suggestive of acquired phrenic nerve palsy.

Because the moderate difficulty in breathing persisted despite physiotherapy, a complete checkup was made 3 months after the block. A new chest x-ray confirmed that the elevation of the right hemidiaphragm was unchanged and revealed atelectasis limited to the lower part of the right lung field, probably related to the right ventilatory deficit. No movement of the hemidiaphragm was observed during fluoroscopy, and paradoxical motion was shown by sniffing maneuver. Pulmonary function tests showed mild restrictive lung disease: vital capacity, forced expiratory volume in 1 s, forced vital capacity, and total lung capacity were respectively reduced to 89, 79, 88, and 76% of predicted values. By contrast, peak expiratory flow rate, arterial oxygen tension (Pao<sub>2</sub>), and arterial carbon dioxide tension (Paco<sub>2</sub>) were in the normal range. Computed tomography and nuclear magnetic resonance scans of the neck and thorax were also normal.

A definitive diagnosis of phrenic nerve dysfunction as the cause of hemidiaphragm paralysis was obtained by electromyography using phrenic nerve stimulation in the neck and the measurements of phrenic nerve latencies and conduction velocities. Stimulating electrodes were placed over the phrenic nerve in the supraclavicular fossa. The compound action potential of the hemidiaphragm was recorded using surface electrodes placed on the anterolateral aspect of the chest in the seventh intercostal space in the anterior axillary line. Results showed the absence of a right phrenic nerve compound action potential, whereas the left phrenic nerve conduction velocity was normal, suggesting that the right phrenic nerve was completely interrupted or significantly demyelinated. Although this examination failed to identify the mechanism or the precise location of the lesion, it was useful in confirming the lack of electromyographic pattern of diffuse neuropathy. One year after surgery, the patient still reported exertional dyspnea with no functional improvement.

### Discussion

In 1985, Bashein *et al.*<sup>1</sup> reported a case of permanent hemidiaphragmatic paralysis after interscalene block performed using a paresthesia technique as described by Winnie. These authors suggested that phrenic nerve paralysis was related to a direct needle trauma. In the current situation, we describe right phrenic nerve paralysis after interscalene brachial plexus block despite the use of a nerve stimulator and B-bevel needle.

\* Resident in Anesthesiology, † Staff Anesthesiologist, ‡ Professor of Anesthesiology, Department of Anesthesiology and Critical Care, Central University Hospital. ‡ Assistant Professor, § Professor of Anesthesiology, Department of Anesthesiology and Critical Care, L'Archet II University Hospital. # Members of the S.O.S. Regional Anesthesia Hot Line Service are listed in the Appendix.

Received from the Department of Anesthesiology and Critical Care, Central University Hospital, Nancy, France; the Department of Anesthesiology and Critical Care, L'Archet II University Hospital, Nice, France; and the S.O.S. Regional Anesthesia Hot Line Service, Department of Anesthesiology, Bicetre Hospital, Paris, France. Submitted for publication February 28, 2001. Accepted for publication July 5, 2001. Supported by the Mise Au Point Anesthésie-Réanimation Association, Department of Anesthesiology and Intensive Care, Bicetre Hospital, Paris, France.

Address reprint requests to Dr. Bouaziz: Département d'Anesthésie-Réanimation Chirurgicale, Hôpital Central, 29, avenue du M<sup>l</sup> de Lattre de Tassigny, 54 035 Nancy cedex, France. Address electronic mail to: h.bouaziz@chu-nancy.fr. Individual article reprints may be purchased through the Journal Web site, www.anesthesiology.org.

The 100% incidence of ipsilateral hemidiaphragmatic paresis reported in patients undergoing interscalene brachial plexus block has been related to the spread of the local anesthetic solution either on C3–C5 roots or through the scalene anterior fascia.<sup>2</sup> This is not prevented by digital pressure and occurs with a variety of local anesthetics and doses. The main mechanism of this hemidiaphragmatic paresis is transient phrenic nerve block. This hypothesis is supported by the time profile of the paralysis, which is usually correlated with the pharmacologic properties of the local anesthetics used. However, this hemidiaphragmatic paresis is not usually associated with adverse clinical symptoms in healthy patients.

The mechanism of phrenic nerve paralysis in the current case may be caused by ischemic, mechanical, or chemical factors, which may occur either alone or in combination. The neural toxicity of ropivacaine has been studied after intraneural injection.<sup>3</sup> Results showed that ropivacaine seems to be devoid of toxicity. Moreover, considering the small diameter of a phrenic nerve (1.5 mm), an intraneural injection seems unlikely. However, needle trauma may easily explain the phrenic nerve injury observed in the current case and in the report of Bashein *et al.*<sup>1</sup> Indeed, such trauma has already been observed in patients undergoing central venous catheterization.<sup>4–6</sup> Etiologies usually reported in the literature are needle trauma or compression resulting from hematoma.<sup>7</sup> Functional respiratory recovery seems to be less after trauma than after hematoma.

Other causes of hemidiaphragmatic paralysis were considered. These etiologies were not compatible with the clinical course, the lack of electromyographic evidence of diffuse neuropathy, and the normal postoperative computed tomographic scan of the chest. In the current case, the surgical procedure is unlikely to explain the phrenic nerve paralysis. Moreover, even though the patient's head was rotated during surgery, this posture is unlikely to explain diaphragmatic paralysis. Indeed, such stretch mechanisms have been reported to be associated with cervical nerves roots injuries, but they were induced by severe trauma<sup>8</sup> or cervical chiropractic manipulation<sup>9</sup> and often lead to transient phrenic nerve palsy only. Conversely, the chronology of the events is in favor of a complication related to the interscalene block, and the symptoms can be attributed to a severe phrenic neuropathy, such as axonotmesis or neurotmesis. Moreover, taking into account both the distance between the diaphragm and the site of nerve injury, the lesion can be considered to be permanent beyond 12 months after the initial injury, according to the usual speed of regeneration (1 mm/day). Such a long follow-up study has been performed only in the case published by Bashein *et al.*<sup>1</sup> and in the current one.

This report stresses that the use of a nerve stimulator or a B-bevel needle does not guarantee that complica-

tions will not occur. Preliminary data from France also suggest that nerve complications can occur despite the use of a nerve stimulator, even with an apparently uneventful block (in 4 of 9 patients with neurologic complications reported, no risk factor could be identified [S.O.S. Regional Anesthesia Hot Line, Paris, France, unpublished data, obtained August 1998–May 1999]). It is noteworthy that the patient was installed with his forearm resting on his abdomen. With the forearm positioned that way, an ipsilateral diaphragmatic contraction may have been misinterpreted as an elbow contraction. Therefore, we recommend that patients be placed supine, with their arms by their sides. The sudden occurrence of diaphragmatic contractions should alert and indicate that the needle should be gently moved posteriorly.

It is interesting to note that the majority of patients with phrenic nerve paralysis reported in the literature did not report during the procedure paresthesia or shoulder pain that lead to nerve injury.<sup>4–6</sup> Nevertheless, because referred pain from phrenic nerve irritation is mainly located in the shoulder, it is conceivable for a patient to report right shoulder pain while the needle tip comes in contact with the phrenic nerve. This has been reported during central venous catheterization.<sup>10</sup> Therefore, subjective paresthesia to the shoulder during interscalene block could also be misinterpreted as an appropriate location of the needle tip, which is actually anterior to the plexus.

## References

1. Bashein G, Robertson HT, Kennedy WF: Persistent phrenic nerve paresis following interscalene brachial plexus block. *ANESTHESIOLOGY* 1985; 63:102–4
2. Urney WF, Talts KH, Sharrock NE: One hundred percent incidence of hemidiaphragmatic paresis associated with interscalene brachial plexus anesthesia as diagnosed by ultrasonography. *Anesth Analg* 1991; 72:498–503
3. Bouazziz H, Lan GB, Grignon Y, Leblanc AL, Merle M, Laxenaire MC: Effect of ropivacaine injected into peripheral nerve in rats using the sciatic functional index (abstract). *Eur J Anaesthesiol* 2000; 17:115:A:375
4. Drachler DH, Koepke GH, Weg JG: Phrenic nerve injury from subclavian vein catheterization: Diagnosis by electromyography. *JAMA* 1976; 236:2880–1
5. Vest JV, Pereira M, Senior RM: Phrenic nerve injury associated with venipuncture of the internal jugular vein. *Chest* 1980; 78:777–9
6. Armengaud MH, Trevoix-Paul J, Boucherie JC, Cousin MT: Diaphragmatic paralysis after puncture of the internal jugular vein. *Ann Fr Anesth Reanim* 1991; 10:77–80
7. Deperriaz B, Essinger A, Morin D, Goy JJ, Buchser E: Isolated phrenic nerve injury after apparently atraumatic puncture of the internal jugular vein. *Intensive Care Med* 1989; 15:132–4
8. Park GR, Young GB: Demonstration of phrenic nerve paralysis and its subsequent recovery by ultrasound. *Intensive Care Med* 1981; 7:145–6
9. Heffner JE: Diaphragmatic paralysis following chiropractic manipulation of the cervical spine. *Arch Intern Med* 1985; 145:562–4
10. Stock MC, Downs JB: Transient phrenic nerve blockade during internal jugular vein cannulation using the anterolateral approach. *ANESTHESIOLOGY* 1982; 57:230–3

## Appendix: The S.O.S. Regional Anesthesia Hot Line Service

Yves Auroy, M.D., Laurent Bargues, M.D. (Staff Anesthesiologists, Département d'Anesthésie, Hôpital D'instruction des Armées, Percy, Clamart, France); Dan Benhamou, M.D. (Professor and Chairman, Département d'Anesthésie et de Réanimation, Hôpital de Bicêtre, Univer-

sité Paris Sud, France); Hervé Bouaziz, M.D., Ph.D. (Staff Anesthesiologist, Département d'Anesthésie et de Réanimation, Hôpital Central, Nancy, France); Claude Ecoffey, M.D. (Professor and Chairman, Département d'Anesthésie et de Réanimation 2, Hôpital Ponchaillou, Univer-

sité de Rennes, France); Frédéric J. Mercier, M.D. (Staff Anesthesiologist, Département d'Anesthésie, Hôpital Bécélère, Clamart, France); Kamran Samii, M.D. (Professor and Chairman, Coordination d'Anesthésie et de Réanimation, Université de Toulouse, France).

Anesthesiology 2001; 95:1521-3

© 2001 American Society of Anesthesiologists, Inc. Lippincott Williams & Wilkins, Inc.

## Continuous Posterior Lumbar Plexus Block for Acute Postoperative Pain Control in Young Children

Didier Sciard, M.D.,\* Maria Matuszczak, M.D.,\* Ralf Gebhard, M.D.,† Jennifer Greger, M.D.,‡  
Tameen Al-Samsam, M.D.,§ Jacques E. Chelly, M.D., Ph.D., M.B.A.||

IT is well-established that postoperative pain is frequently poorly managed in children and that they receive relatively less analgesic than adults. Side effects associated with the use of opioids<sup>1</sup> often limit their administration. Although neuroaxial continuous block techniques represent an interesting alternative, their associated side effects (urinary retention, hypotension, intrathecal infection, post-dural puncture headache, and the poor tolerance of a lasting bilateral sensory and motor block in children) limit these continuous techniques.<sup>2</sup> Although it was shown that complications of central blockade are rare,<sup>3,4</sup> bilateral blockade is unnecessary for a unilateral operation. We present two cases of the use of continuous lumbar plexus block as a main postoperative orthopedic analgesia in young children.

### Case Reports

#### Case 1

A 4-yr-old, 20-kg boy was admitted at the Memorial-Hermann Children Hospital (Houston, Texas) after an automobile-pedestrian accident. At the time of arrival, he was diagnosed with a skull fracture, a scalp avulsion, and a right femur fracture. The femur fracture consisted of a proximal transverse subtrochanteric fracture and was placed on traction. The open reduction and fixation of the femur was performed 7 days later during general anesthesia. At the end of surgery, the child

was placed in a left lateral position for the placement of a posterior lumbar plexus catheter during general anesthesia (See video on the ANESTHESIOLOGY Web site).

First, a vertical line was drawn at the level of the highest point of the right iliac crest. Second, a horizontal line parallel to the spine process line was drawn at the level of the right posterior iliac spine. The site of the introduction of the needle was defined as the intersection between these two lines. An insulated 18-gauge, 50-mm introducer Sprotte needle (Pajunk, Albany, NY) was connected to a nerve stimulator (Stimuplex HNS 11; B-Braun Medical, Bethlehem, PA) set up to deliver a current of 1.5 mA, two times per second (2 Hz), with an impulse duration of 0.1 ms with the neutral electrode placed on the opposite leg.

The needle was introduced perpendicular through the skin in search of the transverse process of L5 and then oriented slightly cranially. At a depth of 3 cm, a quadriceps contraction was elicited, indicating the stimulation of the lumbar plexus. The intensity of the current was progressively decreased, and the position of the needle was adjusted to maintain the same motor response with a current of 0.5 mA. After negative aspiration for blood, a test dose of 2 ml of a 0.2% ropivacaine-1.5% mepivacaine (vol/vol) mixture was slowly injected and followed by 12 ml of the same mixture for a total volume of 14 ml. This was followed by the placement of a 20-gauge Stimulong plexus catheter (Pajunk) introduced about 1 cm beyond the tip of the introducer needle (4 cm at the skin). The catheter was secured in place with steri-strip (3M Health Care, St. Paul, MN) and covered with a tegaderm (3M Health Care, St. Paul, MN). The child was placed in a supine position, was awakened, underwent extubation, and was transferred to the postoperative acute care unit. The absence of epidural spread was assessed by hemodynamic stability after the performance of the blocks and by the presence of an adequate reaction to pin prick of the opposite leg after emergence. Standard anesthesia care monitoring was used during the procedure and recovery. In the postoperative acute care unit, a continuous infusion pump (Baxter AP II; Baxter Healthcare, Deerfield, IL) was connected to the lumbar plexus catheter and set up to deliver a continuous infusion of 0.2% ropivacaine at a rate of 4 ml/h. The acute orthopedic pain management team took care of the child until discharge from the hospital.

Postoperatively, the child did not request morphine. He slept the full night after his surgery, for the first time since he arrived in our facility. He received a total of only 450 mg acetaminophen on the first postoperative day, and 5 ml acetaminophen plus codeine elixir on one and two occasions on the first and second postoperative days, respectively. No side effects or complications were observed. The nurses and parents were satisfied with the child's postoperative pain management.

Additional material related to this article can be found on the ANESTHESIOLOGY Web site. Go to the following address, click on Enhancements Index, and then scroll down to find the appropriate article and link. <http://www.anesthesiology.org>

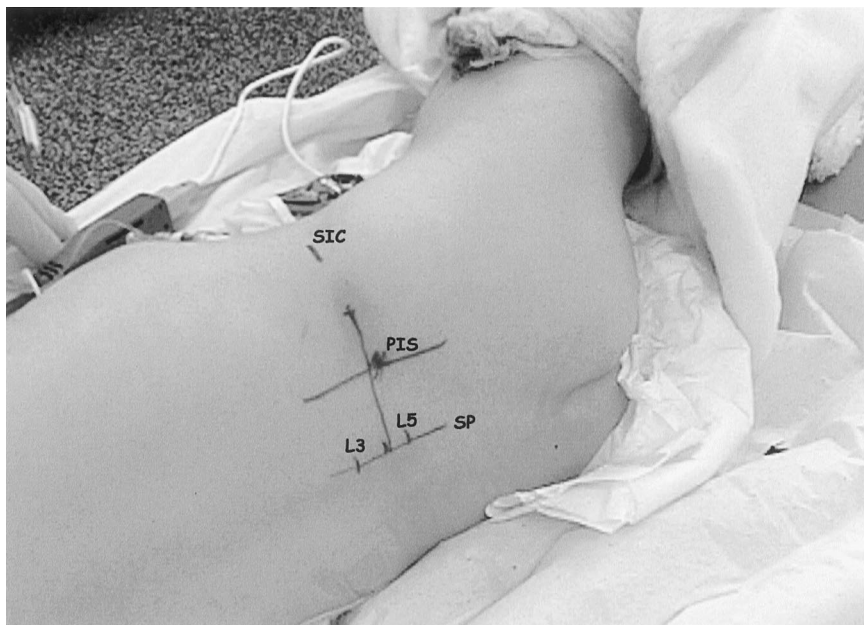
\* Visiting Associate Professor of Anesthesiology, † Assistant Professor of Anesthesiology and Director of Same Day Surgery Clinic, ‡ Assistant Professor, Assistant Director of Residency Training, and Assistant Director of Orthopaedic Anesthesia and Orthopaedic Acute Pain Service, § Regional Anesthesia Fellow, || Professor, Director of Regional Anesthesia, and Director of Orthopaedic Anesthesia and Orthopaedic Acute Pain Service, Department of Anesthesiology, The University of Texas Medical School at Houston, Houston, Texas.

Received from the Memorial Hermann Hospital, Houston, Texas. Submitted for publication March 16, 2001. Accepted for publication July 19, 2001. Supported by the Department of Anesthesiology, The University of Texas Medical School-Houston, Houston, Texas.

Address reprint requests to Dr. Chelly: The University of Texas, Health Science Center at Houston, Department of Anesthesiology, 6431 Fannin, MSB 5.020, Houston, Texas 77030-1503. Address electronic mail to: Jacques.E.Chelly@uth.tmc.edu. Individual article reprints may be purchased through the Journal Web site, [www.anesthesiology.org](http://www.anesthesiology.org).

#### Case 2

A 16-month-old, 12-kg boy was involved in a lawnmower accident. He was admitted at the Memorial-Hermann Children Hospital. At the time of arrival, the child had a partial left great toe amputation, a right



**Fig. 1.** Landmarks for the placement of lumbar plexus catheter in a 16-month-old, 12-kg child. SIC = superior iliac crest; PIS = posterior iliac spine; SP = spinous processes.

femur fracture associated with a severe injury of the knee, and multiple lacerations to his right thigh. After proper consent was received, he underwent irrigation and drainage and a free vascularized tissue transfer of the right leg. This was followed by irrigation and drainage of the left foot on the next day and by an open reduction of the right femur and knee during general anesthesia. A continuous posterior lumbar plexus block was performed after induction of general anesthesia and positioning of the child in the left lateral position (fig. 1).

The landmarks and technique used as well as the follow-up of this patient were the same as those described in the first case, except that (1) an insulated 18-gauge, 25-mm Sprotte needle was used; (2) the lumbar plexus was found at a depth of 25 mm; (3) a test dose of 2 ml was used, followed by the injection of 6 ml of the same mixture for a total volume of 8 ml; (4) the 20-gauge Stimulong plexus catheter was introduced 3.5 cm at the skin; and (5) 0.2% ropivacaine was infused at a rate of 2 ml/h. Also in this case, the child did not require morphine postoperatively. The child only received acetaminophen on one and two occasions on the first and second postoperative days, respectively.

## Discussion

Continuous femoral infusions have been proven to provide effective postoperative pain control in children.<sup>5,6</sup> To our knowledge, these cases represent the first report of continuous posterior lumbar infusions for postoperative pain management in orthopedics in young children. The approach used was similar to the one described by Dalens *et al.*<sup>7</sup> in children according to the original landmarks described by Winnie<sup>8</sup> in adults. Dalens *et al.*<sup>9</sup> also evaluated the approach of the lumbar plexus block described by Chayen *et al.*<sup>10</sup> and reported that this approach was associated with an epidural spread in 90% of the cases and was therefore less suitable for unilateral lumbar plexus block.

The depths at which the lumbar plexus was found were approximately 2.5 and 3.0 cm for our 17-month-old and 4-yr-old patients, respectively. These findings are within the limits described by Dalens *et al.*,<sup>7</sup> who estab-

lished a relation between the depth of the lumbar plexus and the age and the weight of the child (2–2.5 cm for a 1-yr-old infant to 6.0 cm for a 16-yr-old adolescent). Because the depth at which the lumbar plexus is found depends on age, it is clear that the introduction of a needle beyond the recommended depth increases the risk of intraabdominal organ damage. It is critical to recognize that in infants and children, the placement of catheters allowing continuous perineural infusions of local anesthetics requires appropriate expertise and understanding of infant anatomy and, especially for this approach, should be performed by experts in pediatric peripheral nerve blocks.

In adults, the posterior approach to the lumbar plexus is recognized to provide a complete block of the femoral, lateral cutaneous femoral, and obturator nerves. In contrast, the anterior approach to the lumbar plexus (three-in-one block) often misses the lateral cutaneous femoral nerve, the obturator nerve, or both. Although it seems that the anterior approach is preferred for pain management of femoral fracture in infants and children,<sup>5,6</sup> the posterior approach was chosen as the technique that most likely would also block the lateral cutaneous femoral and obturator nerves. This was necessary to cover the lateral surgical approach in the first case and the associated lateral laceration and the medial lesion of the knee in the second case. Despite the obvious inability to evaluate the extent of a sensory block in young children, the absence of postoperative requirement for morphine in view of the types of surgeries and expected postoperative pain suggests that indeed our choice produced an appropriate sensory block of the femoral, obturator, and lateral femoral cutaneous nerves.

The use of a continuous infusion technique in infants and children raises questions about the choice, concen-

tration, and rate of infusion of local anesthetics. We chose 0.2% ropivacaine rather than lidocaine or bupivacaine. Like other local anesthetics, the use of ropivacaine is not approved in infants. Nevertheless, local anesthetics are used for neuroaxial continuous blocks, including epidural and caudal blocks.<sup>11,12</sup> In this respect, 0.2% ropivacaine has been demonstrated to be safe and effective for epidural continuous infusions at rates similar to those we chose in this infant.<sup>11</sup> At these rates, 0.2% ropivacaine has been proven to produce plasma concentrations below those considered toxic in adults. Additional studies investigating the plasma concentrations generated by these dosages are required to confirm the safety of this agent. However, the determination of the local plasma concentration of anesthesia in the absence of a relation between plasma concentrations and clinical symptoms of toxicity is of limited value in the infant. It is well-established that the permeability of the brain barrier as well as the sensitivity of the brain and heart varies with age.

These two case reports represent successful postoperative management of orthopedic pain in children using continuous posterior lumbar plexus infusion. This approach is most likely to provide a complete block of the lumbar plexus and consequently minimizes the need for additional opioids during the postoperative period. How-

ever, it is important to recognize that lumbar plexus block in infants and children should only be performed by trained anesthesiologists.

## References

1. Lloyd-Thomas AR: Pain management in pediatric patients. *Br J Anaesth* 1990; 64:85-104
2. Wood C, Goresky G, Klassen K, Kuwahara B, Neil G: Complications of continuous epidural infusions for postoperative analgesia in children. *Can J Anaesth* 1994; 41:613-20
3. Giaufre E, Dalens B, Gombert A: Epidemiology and morbidity of regional anesthesia in children: A one-year prospective survey of the French-language Society of Pediatric Anesthesiologists. *Anesth Analg* 1996; 83:904-12
4. Flandin-Blety C, Barrier G: Accidents following extradural analgesia in children: The results of a retrospective study. *Paediatr Anaesth* 1995; 5:41-6
5. Johnson CM: Continuous femoral nerve blockade for analgesia in children with femoral fractures. *Anaesth Intensive Care* 1994; 22:281-3
6. Tobias JD: Continuous femoral nerve block to provide analgesia following femur fracture in a paediatric ICU population. *Anaesth Intensive Care* 1994; 22:616-8
7. Dalens B: Chapter 13, Lumbar plexus block, *Regional Anesthesia in Infants, Children and Adolescents*, 2nd edition. Edited by Dalens B. Baltimore, Williams & Wilkins, 1995, pp 313-40
8. Winnie AP, Ramamurthy S, Durrani Z, Radonjic R: Plexus for lower extremity surgery: New answers to old problems. *Anesthesiol Rev* 1974; 1:11-6
9. Dalens B, Tanguy A, Vannerville G: Lumbar plexus block in children: Comparison of two procedures in 50 patients. *Anesth Analg* 1988; 67:750-8
10. Chayen D, Nathan H, Chayen M: The psoas compartment block. *ANESTHESIOLOGY* 1976; 45:95-9
11. Moriarty A: Postoperative extradural infusion in children: Preliminary data from a comparison of bupivacaine/diamorphine with plain ropivacaine. *Paediatr Anaesth* 1999; 9:423-7
12. Ivani G, Lampugnani E, De Negri P, Lonnqvist PA, Broadman L: Ropivacaine vs bupivacaine in major surgery in infant. *Can J Anaesth* 1999; 46:467-9

Anesthesiology 2001; 95:1523-4

© 2001 American Society of Anesthesiologists, Inc. Lippincott Williams & Wilkins, Inc.

## Hepatocellular Injury following the Administration of Propofol

Kapil Anand, M.D.,\* Michael A. Ramsay, M.D.,† Jeffrey S. Crippin, M.D.‡

DRUG-INDUCED liver injury may occur in the postoperative period and has been reported as a result of exposure to several anesthetic agents. Although inhalational agents are often suspected, many drugs administered in the perioperative period can cause liver injury. The injury may be dose related, as with acetaminophen, or may be idiosyncratic, such as isoniazid. The parent molecule or a toxic metabolic intermediary may act as the hepatotoxin. The histologic injury can be diffuse with cholestasis, inflammation, and necrosis. Hepatocellular injury in the immediate postoperative period may be the result of a direct hepatotoxin or hepatic oxygen deple-

tion caused by alterations in the splanchnic and hepatic circulation when surgical manipulations occur near these blood vessels, with a potential confounding effect of the anesthetic agent.<sup>1</sup> This report examines the causation of toxic hepatitis after administration of propofol as a sole general anesthetic agent for a minor surgical procedure.

### Case Report

A 17-yr-old, 56.8-kg girl presented for outpatient left femoral hernia repair. She had a history of bronchial asthma that was being treated with salmeterol xinafoate inhalation aerosol, fluticasone propionate inhalational aerosol, zafirlukast tablets, and cetirizine hydrochloride tablets. Three years before this admission, she had undergone Nissen fundoplication as a treatment for gastric reflux. She had a history of an episode of hepatitis A as an infant, which had resolved. Liver biochemistries performed 6 months before this admission were within normal range. Previous general anesthetics, including sodium methohexital, had been associated with severe postoperative nausea and vomiting. The patient was a high school student who denied tobacco, ethanol, or intravenous drug abuse. The patient had a history of multiple drug allergies, including codeine, morphine, meperidine, fentanyl, ketorolac, penicillin, lorazepam, and midazolam. The allergy symptoms reported were nausea and vomiting after administration of the analgesics,

\* Resident in Anesthesiology, Department of Anesthesiology and Pain Management, University of Texas Southwestern Medical School, Dallas, Texas. † Chief of Anesthesiology and Pain Management, Department of Anesthesiology and Pain Management, Baylor University Medical Center, Dallas, Texas. ‡ Associate Professor of Medicine, Department of Internal Medicine, Medical Director, Liver Transplantation, Washington University School of Medicine, St. Louis, Missouri.

Received from Baylor University Medical Center, Dallas, Texas. Submitted for publication April 10, 2001. Accepted for publication July 19, 2001. Support was provided solely from institutional and/or departmental sources.

Address reprint requests to Dr. Ramsay: Baylor University Medical Center, 3500 Gaston Avenue, Dallas, Texas 75246. Address electronic mail to: docram@baylordallas.edu. Individual article reprints may be purchased through the Journal Web site, www.anesthesiology.org.

a skin rash after penicillin administration, and bronchospasm after lorazepam or midazolam administration. She had no known hepatotoxic reactions to any medications. At the time of physical examination, she appeared healthy and without abnormalities other than a left femoral hernia. Her serum human chorionic gonadotropin test results were negative.

The hernia repair was performed during intravenous anesthesia using propofol (with disodium edetate) as the sole anesthetic agent. The propofol emulsion was infused at a mean dose of  $150 \mu\text{g} \cdot \text{kg}^{-1} \cdot \text{min}^{-1}$  for a total dose of 682 mg. Oxygen supplementation was administered, and the oxygen saturation was maintained at 100%. Bupivacaine, 0.5% (75 mg total), was infiltrated into the surgical wound. The procedure lasted 1 h 20 min, and the patient was hemodynamically stable throughout this period. There were no apparent surgical or anesthetic complications. The patient was in satisfactory condition throughout her stay and was discharged to her home after a routine stay in the postanesthesia care unit.

After discharge from the hospital, the patient developed severe nausea and vomiting. She was readmitted to the hospital the day after surgery because of persistent nausea, vomiting, retching, and dehydration. She denied acute abdominal pain, fever, or chills. She had not taken any medication except promethazine, in an attempt to control her nausea. The results of her physical examination were unremarkable, except for the presence of a tachycardia and diffuse abdominal discomfort considered to be secondary to retching.

At the time of readmission to the hospital, laboratory analysis revealed a serum aspartate aminotransferase concentration of 241 U/l (normal range, 5–50 U/l) and a serum alanine aminotransferase concentration of 174 U/l (normal range, 5–40 U/l). Total serum bilirubin, serum alkaline phosphatase, and serum  $\gamma$ -glutamyl transferase values were normal. A urine examination yielded normal results. The diagnosis of acute hepatitis of unknown etiology was made, and hepatology consultation was obtained. She received intravenous rehydration while undergoing a complete diagnostic assessment. The serum aspartate aminotransferase and alanine aminotransferase concentrations increased to 1,423 and 1,567 U/L, respectively, during the next 36 h, and a prothrombin time of 14.9 s (normal range, < 12 s) was reported. On postoperative day 3, the serum aspartate aminotransferase and alanine aminotransferase concentrations were noted to have stabilized at 997 and 1,298 U/l, respectively. A repeat analysis of liver biochemistries 10 days later revealed a serum aspartate aminotransferase concentration of 20 U/l and a serum alanine aminotransferase concentration of 62 U/l. The laboratory evaluation did not reveal a viral etiology. The viral screen included hepatitis A, B, and C, cytomegalovirus, and Epstein-Barr virus. Antinuclear antibody and smooth muscle antibody titers were not increased. The ceruloplasmin concentration was also normal. Abdominal ultrasound examination did not reveal the presence of gallstones and was otherwise unremarkable.

## Discussion

The etiology of this girl's acute postoperative hepatitis seems to be drug induced; common viral etiologies have been excluded. The presentation of severe nausea and vomiting and the speed of onset are somewhat unusual for a drug-induced hepatic injury, but no other cause could be identified, despite extensive evaluation. The symptoms of recurrent nausea and vomiting after anesthesia, together with the multiple drug allergies, caused acute porphyria to be considered in the differential diagnosis. Porphyria may be associated with hepatitis, but this is usually a chronic presentation, not an acute hep-

atitis with rapid resolution as reported in this patient. The urinary examination did not reveal the presence of porphyrins or porphobilinogen, again making acute porphyria an unlikely diagnosis.<sup>2</sup>

This pattern of acute liver injury seemed most likely to be caused by a severe ischemic event or a drug-induced toxic injury. Because there was no evidence for a hemodynamic or hypoxic event, we conclude there was a causal relation between the administration of propofol and the hepatocellular injury. This agent has never been reported to cause acute liver injury after a brief exposure, although it has been associated with the development of acute pancreatitis.<sup>3,4</sup>

The association between the administration of propofol and the development of hepatocellular injury has been reported after a long-term infusion. This has been documented by the measurement of plasma concentrations of glutathione S-transferase that are increased in the presence of hepatocellular damage and the leakage of cytosolic enzymes into the extracellular space.<sup>5–7</sup> Other adverse reports of liver damage associated with propofol have again followed long-term infusions and also have been associated with the presence of lactic acidemia, bradyarrhythmias, and rhabdomyolysis.<sup>8</sup>

Unfortunately, a liver biopsy was not performed to further assess the amount of liver injury. However, with her spontaneous improvement, it was difficult to justify a biopsy from the standpoint of practicality. Furthermore, the patient has not been rechallenged with propofol to confirm a hepatotoxic reaction. We have recommended that she list propofol as a drug allergy in order to prevent future exposures.

This case report suggests hepatotoxicity following a brief exposure to propofol. Abnormal liver biochemistries detected after the use of this agent were assessed carefully and thoroughly, and propofol-induced hepatotoxicity has to be considered in the differential diagnosis.

## References

1. Gelman S: General anesthesia and hepatic circulation. *Can J Physiol Pharmacol* 1987; 65:1762–79
2. Gross U, Hoffman GF, Doss MO: Erythropoietic and hepatic porphyrias. *J Inher Metab Dis* 2000; 23:641–61
3. Leisure GS, O'Flaherty J, Green L, Jones DR: Propofol and postoperative pancreatitis. *ANESTHESIOLOGY* 1996; 84:224–7
4. Bird H, Brim V: Propofol and postoperative pancreatitis. *Anaesthesia* 2000; 55:506–7
5. Tianen P, Lindgren L, Rosenberg PH: Disturbance of hepatocellular integrity associated with propofol anesthesia in surgical patients. *Acta Anaesthesiol Scand* 1995; 39:840–4
6. Motsch J, Schmidt H, Bach A, Bottinger BW, Bohrer H: Long-term sedation with propofol and green discoloration of the liver. *Eur J Anaesth* 1994; 11:499–502
7. Granados Llamas LM, Navas Rivera E, Marengo de la Fuente ML, Balanza Ortiz R, Suarez Collazos F, Puente Egidio JJ: Mobilization of alpha-glutathione S-transferase in the anesthetized patient. *Rev Esp Anestesiol Reanim* 1999; 46:350–3
8. Cray SH, Robinson BH, Cox PN: Lactic acidemia and bradyarrhythmia in a child sedated with propofol. *Crit Care Med* 1998; 26:2087–92

## Two Cases of Fatal Thrombosis after Aminocaproic Acid Therapy and Deep Hypothermic Circulatory Arrest

Michael P. Fanashawe, F.A.N.Z.A.,\* Linda Shore-Lesserson, M.D.,† David L. Reich, M.D.‡

POSTOPERATIVE bleeding after cardiopulmonary bypass using deep hypothermic circulatory arrest (DHCA) is a significant cause of morbidity and mortality. The pathogenesis of this hemorrhagic tendency is complex and multifactorial, resulting from hypothermia, consumption of clotting factors, platelet destruction, platelet dysfunction, hyperfibrinolysis, and surgical factors. The use of antifibrinolytic agents, such as aprotinin,  $\epsilon$ -aminocaproic acid (EACA), and tranexamic acid, have been demonstrated to reduce postoperative blood loss and transfusion requirements in cardiac surgery.<sup>1-7</sup> The benefits of antifibrinolytic use in DHCA are less well-established because of anecdotal and retrospective reports of renal dysfunction and thrombosis.<sup>8-14</sup> We present two cases in which patients treated intraoperatively with EACA during aortic replacement surgery presented with massive, fatal aortic thrombosis.

### Case Reports

#### Case 1

A 70-yr-old man with previous aortic valve replacement presented several months postoperatively with bacterial endocarditis and an aortic root abscess. He was scheduled for an aortic root replacement (Bentall) procedure using cardiopulmonary bypass (CPB) and DHCA. At the time of surgery, his vital signs were normal; his coagulation, hematology, and biochemical profiles were normal; and he was taking the following medications: spironolactone, furosemide, digoxin, metoprolol, oxacillin, and verapamil. General anesthesia was induced and maintained with midazolam, sufentanil, pancuronium, and isoflurane. Cefazolin (1,000 mg) and vancomycin (1,000 mg) were also administered. Monitoring included standard anesthesia monitoring plus a radial arterial line, a pulmonary artery catheter, jugular bulb saturation monitoring, and transesophageal echocardiography. EACA (150 mg/kg) was administered as a loading dose soon after induction, and a maintenance infusion of  $15 \text{ mg} \cdot \text{kg}^{-1} \cdot \text{h}^{-1}$  was continued until after protamine administration.

The patient's intraoperative course was uneventful. Activated clotting time (ACT) was maintained at more than 500 s with bovine lung heparin using an initial dose of 300 U/kg and ACT testing every 30 min thereafter. The Bentall procedure was performed with a mechanical prosthetic aortic valve and composite graft. The aortic root graft was a

Hemashield® (Boston Scientific, Oakland, NJ) graft, and the coronary arteries were reimplanted successfully. CPB time was 311 min, DHCA was 25 min, and the patient initially separated successfully from CPB with  $5 \mu\text{g} \cdot \text{kg}^{-1} \cdot \text{min}^{-1}$  dopamine for inotropic support. Protamine sulphate (7 mg/kg) was administered over 15 min to neutralize a total heparin dose of 700 U/kg. After 5 min of protamine administration, the mean arterial blood pressure decreased to 40 mmHg, and protamine administration was stopped to evaluate the etiology of the severe hypotension. Transesophageal echocardiography revealed a large thrombus, which occupied the entire lumen of the ascending aorta, the aortic arch, and the descending aorta. This thrombus and fibrous material was also visualized in the left atrium and ventricle (fig. 1). The patient rapidly progressed to cardiac arrest, CPR was commenced, heparin was readministered, and a futile attempt to reinstitute CPB was made. Resuscitative efforts were unsuccessful.

At the time of death, blood sampling was performed to evaluate for the possibility of a previously undiagnosed hypercoagulable state. The patient was negative for anticardiolipin antibodies, anti-thrombin III deficiency, and protein C or S deficiency. Laboratory analysis revealed that the patient had a heterozygous mutation of Factor V, FV:R506Q, also known as Factor V Leiden.

#### Case 2

A 76-yr-old woman presented for repair of an ascending aortic aneurysm. At the time of surgery, her vital signs were normal; her coagulation, hematology, and biochemical profiles were normal; and she was taking the following medications: hydroxyzine, furosemide, benazepril hydrochloride, and metoprolol. General anesthesia was induced and maintained with etomidate, midazolam, sufentanil, pancuronium, and isoflurane. Cefazolin (1,000 mg) and vancomycin (1,000 mg) were also administered. Monitoring included standard anesthesia monitoring plus a radial arterial line, a pulmonary artery catheter, jugular bulb saturation monitoring, and transesophageal echocardiography. EACA (150 mg/kg) was administered as a loading dose soon after induction, and a maintenance infusion of  $15 \text{ mg} \cdot \text{kg}^{-1} \cdot \text{h}^{-1}$  was continued until after protamine administration. Her intraoperative course was uneventful. ACT was maintained at greater than 500 s with bovine lung heparin using an initial dose of 300 U/kg and ACT testing every 30 min thereafter. The aortic arch graft was a Hemashield® graft. CPB time was 233 min, DHCA was 46 min, and the patient initially separated successfully from bypass using  $5 \mu\text{g} \cdot \text{kg}^{-1} \cdot \text{min}^{-1}$  dopamine.

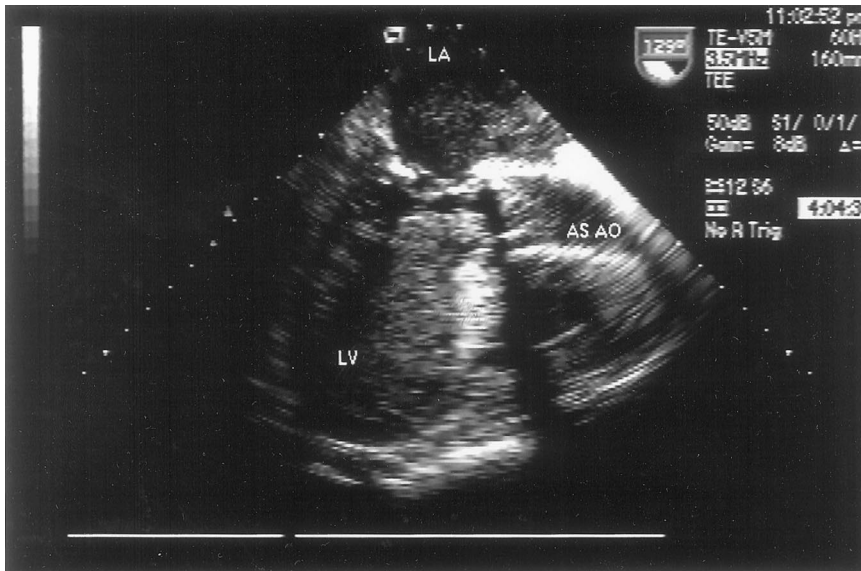
After separation from CPB, 5 mg/kg protamine sulphate was administered by slow infusion to neutralize a total heparin dose of 500 U/kg. Five units pooled platelet concentrates were administered without incident to treat microvascular bleeding. Forty-one minutes after successful separation from CPB, during transfusion of 1 unit fresh frozen plasma, the patient became profoundly hypotensive. Fresh frozen plasma transfusion was discontinued, and the patient's hemodynamics initially responded to commencement of epinephrine and norepinephrine infusions. A dose of steroids was administered in case anaphylaxis to fresh frozen plasma had caused the hypotension. Transesophageal echocardiography revealed large thrombi in the right atrium, the main pulmonary artery, and the entire lumen of the descending aorta. The patient did not respond to further resuscitative efforts.

Postmortem analysis showed that the patient had normal alleles for Factor V Leiden by prothrombin assay. There was insufficient sera for

\* Fellow in Anesthesiology, † Assistant Professor of Anesthesiology, ‡ Professor of Anesthesiology.

Received from the Department of Anesthesiology, Mt. Sinai Medical Center, New York, New York. Submitted for publication March 23, 2001. Accepted for publication July 27, 2001. Supported by the Department of Anesthesiology, Mt. Sinai Medical Center.

Address reprint requests to Dr. Shore-Lesserson: Department of Anesthesiology, Mt. Sinai Medical Center, One Gustave L. Levy Place, New York, New York 10029. Address electronic mail to: linda.shore@mssm.edu. Individual article reprints may be purchased through the Journal Web site, www.anesthesiology.org.



**Fig. 1.** Transesophageal echocardiographic image of the left atrium (LA), left ventricle (LV), and ascending aorta (AS AO), showing a large thrombus extending across the mitral valve and aortic valve and completely occluding flow.

further testing for other causes of previously undiagnosed hypercoagulable states.

## Discussion

Blood loss minimization in patients undergoing CPB with DHCA has been attempted with the use of either the lysine analog antifibrinolytic agents (EACA and tranexamic acid) or the nonspecific serine protease inhibitor, aprotinin. The literature suggests that these agents are effective in reducing blood loss after CPB. However, their safety and efficacy in DHCA are controversial because some reports suggest that thrombotic events and renal dysfunction are potential risks that outweigh any benefits.<sup>9-12,14-18</sup> The risks of thrombosis in DHCA have prompted some clinicians to stop using aprotinin in these patients. Others recommend using aprotinin after deep hypothermia and circulatory arrest have been completed.<sup>13</sup> Specifically, aprotinin has been reported to be associated with renal glomerular thrombi<sup>14</sup> and other thrombi<sup>19</sup> in CPB both with and without DHCA. Careful analysis of these events has more accurately attributed them to inadequate heparinization, inappropriate aprotinin dosing regimens, or flawed study methodology.<sup>10-12,14,17,19,20</sup> There are fewer reports of catastrophic thrombotic events using EACA or tranexamic acid, but it is unclear whether these events are truly less frequent or underreported.<sup>21</sup> One case report describes massive thrombosis after a hypovolemic cardiac arrest in a patient treated with EACA while undergoing CPB.<sup>22</sup> Another report of fatal aortic thrombosis occurred in a neonate treated with EACA during extracorporeal life support.<sup>23</sup> Data regarding the use of the lysine analogs EACA or tranexamic acid given during DHCA are even more scarce and inconclusive about safety outcomes.<sup>9</sup>

ε-Aminocaproic acid is a lysine analog that inhibits fibrinolysis by attaching to lysine binding sites on plas-

minogen and plasmin, thereby inhibiting their activities. In secondary fibrinolysis states, such as that which occurs during CPB, EACA may potentially precipitate a prothrombotic state with unopposed coagulation.<sup>24,25</sup>

The two cases that we present suggest that certain patients may be prone to thrombosis when given lysine analog antifibrinolytic agents during DHCA. In both of our patients, Hemoshield<sup>®</sup> aortic grafts were used. These grafts are collagen-impregnated and have hemostatic properties but have not been associated with acute aortic intravascular thrombosis.<sup>26,27</sup> Though we did monitor ACT to assure adequate anticoagulation during CPB, we did not measure or maintain a specific heparin concentration. It is possible that a combination of disseminated intravascular coagulation after hypothermic CPB, the use of an antifibrinolytic agent, low heparin concentrations, and the presence of hemostatic graft material combined to produce the hypercoagulable state that led to the fatal thrombotic events in these two patients. In the first patient, the presence of a heterozygous mutation associated with hypercoagulability (Factor V Leiden) was almost certainly contributory.

Factor V Leiden is reported to occur in 3-5% of the population and is associated with hypercoagulable states. This abnormality produces a resistance to activated protein C, which is involved in anticoagulation and thrombolysis. The use of an antifibrinolytic agent in the presence of abnormal thrombolysis could be expected possibly to enhance the likelihood of thrombosis.

Both patients received a standard 300-U/kg dose of heparin and had ACT monitoring every 30 min. Although the ACT was maintained at more than 500 s, in profound hypothermia, ACT correlates poorly with plasma heparin concentrations.<sup>28,29</sup> This is our standard method of heparin management in a referral center in which we perform hundreds of DHCA operations per year. How-



ever, it is possible that low heparin concentrations were present in each patient and that the development of a subclinical disseminated intravascular coagulation contributed to the postprotamine fatal thrombotic events.<sup>28,29</sup> The optimal ACT and heparin management protocol in the presence of antifibrinolytic therapy and DHCA remains unknown.

In summary, we have presented two cases of fatal thrombosis after EACA administration and DHCA. Previously, such cases had only been described with aprotinin usage. These cases provide a warning that the lysine analogs may also cause unopposed coagulation by virtue of their antifibrinolytic properties, especially in patients who have a second risk factor for thrombosis. Screening for subclinical procoagulant states, such as Factor V Leiden abnormality, is costly but may be considered in patients undergoing DHCA in which the use of antifibrinolytics is planned. The optimal heparin dosage and maintenance in this patient group also need to be further investigated. The benefits of reduced blood loss need to be carefully weighed against the risks of intravascular thrombosis when selecting an anesthetic and surgical plan for aortic surgery using deep hypothermic circulatory arrest.

## References

- Munoz JJ, Birkmeyer NJ, Birkmeyer JD, O'Connor GT, Dacey LJ: Is epsilon-aminocaproic acid as effective as aprotinin in reducing bleeding with cardiac surgery? A meta-analysis. *Circulation* 1999; 99:81-9
- Laupacis A, Fergusson D: Drugs to minimize perioperative blood loss in cardiac surgery: Meta-analyses using perioperative blood transfusion as the outcome. The International Study of Peri-operative Transfusion (ISPOT) Investigators. *Anesth Analg* 1997; 85:1258-67
- Bennett-Guerrero E, Sorohan JG, Gurevich ML, Kazanjian PE, Levy RR, Barbera AV, White WD, Slaughter TF, Sladen RN, Smith PK, Newman MF: Cost-benefit and efficacy of aprotinin compared with epsilon-aminocaproic acid in patients having repeated cardiac operations: A randomized, blinded clinical trial. *ANESTHESIOLOGY* 1997; 87:1373-80
- Shore-Lesserson L, Reich DL, Silvay G, Griep RB: Hemostasis in aortic and cardiothoracic surgery. *J Card Surg* 1997; 12:232-7
- Landyore RW, Murphy JT, Lummis H, Carter C: The use of low-dose aprotinin, epsilon-aminocaproic acid or tranexamic acid for prevention of mediastinal bleeding in patients receiving aspirin before coronary artery bypass operations (letter). *Eur J Cardiothorac Surg* 1997; 11:798-800
- Shore-Lesserson L, Reich DL, Vela-Cantos F, Ammar T, Ergin MA: Tranexamic acid reduces transfusions and mediastinal drainage in repeat cardiac surgery. *Anesth Analg* 1996; 83:18-26
- Horrow JC, Hlavacek J, Strong MD, Collier W, Brodsky I, Goldman SM, Goel IP: Prophylactic tranexamic acid decreases bleeding after cardiac operations. *J Thorac Cardiovasc Surg* 1990; 99:70-4
- Blauhut B, Gross C, Neccek S, Doran JE, Spath P, Lundsgaard-Hansen P: Effects of high-dose aprotinin on blood loss, platelet function, fibrinolysis, complement, and renal function after cardiopulmonary bypass. *J Thorac Cardiovasc Surg* 1991; 101:958-67
- Eaton MP, Deeb GM: Aprotinin versus epsilon-aminocaproic acid for aortic surgery using deep hypothermic circulatory arrest. *J Cardiothorac Vasc Anesth* 1998; 12:548-52
- Ehrlich M, Grabenwoger M, Cartes-Zumelzu F, Luckner D, Kovarik J, Laufer G, Kocher A, Konetschny R, Wolner E, Havel M: Operations on the thoracic aorta and hypothermic circulatory arrest: Is aprotinin safe? *J Thorac Cardiovasc Surg* 1998; 115:220-5
- Goldstein DJ, DeRosa CM, Mongero LB, Weinberg AD, Michler RE, Rose EA, Oz MC, Smith CR: Safety and efficacy of aprotinin under conditions of deep hypothermia and circulatory arrest. *J Thorac Cardiovasc Surg* 1995; 110:1615-21, 1621-2
- Parolari A, Antona C, Alamanni F, Spirito R, Naliato M, Gerometta P, Arena V, Biglioli P: Aprotinin and deep hypothermic circulatory arrest: there are no benefits even when appropriate amounts of heparin are given. *Eur J Cardiothorac Surg* 1997; 11:149-56
- Rooney SJ, Pagano D, Bognolo G, Wong C, Bonser RS: Aprotinin in aortic surgery requiring profound hypothermia and circulatory arrest. *Eur J Cardiothorac Surg* 1997; 11:373-8
- Sundt TM III, Kouchoukos NT, Saffitz JE, Murphy SF, Wareing TH, Stahl DJ: Renal dysfunction and intravascular coagulation with aprotinin and hypothermic circulatory arrest. *Ann Thorac Surg* 1993; 55:1418-24
- Heindel SMM, Freid E, Valley R, White G, Norfleet E: Fatal thrombosis associated with a hemi-fontan procedure, heparin-protamine reversal, and aprotinin. *ANESTHESIOLOGY* 2001; 94:369-71
- Westaby S, Katsumata T: Aprotinin and vein graft occlusion—the controversy continues (editorial). *J Thorac Cardiovasc Surg* 1998; 116:731-3
- Okita Y, Takamoto S, Ando M, Morota T, Yamaki F, Kawashima Y: Is use of aprotinin safe with deep hypothermic circulatory arrest in aortic surgery? Investigations on blood coagulation. *Circulation* 1996; 94:II177-81
- Okita Y, Takamoto S, Ando M, Morota T, Yamaki F, Matsukawa R, Kawashima Y: Coagulation and fibrinolysis system in aortic surgery under deep hypothermic circulatory arrest with aprotinin: The importance of adequate heparinization. *Circulation* 1997; 96:II-376-81
- Cosgrove DM III, Heric B, Lytle BW, Taylor PC, Novoa R, Golding LA, Stewart RW, McCarthy PM, Loop FD: Aprotinin therapy for reoperative myocardial revascularization: A placebo-controlled study. *Ann Thorac Surg* 1992; 54:1031-6, 1036-8
- Gitter R, Alivizatos P, Capehart J, Ramsay M, Jett GK: Aprotinin and aortic cannula thrombosis. *J Thorac Cardiovasc Surg* 1996; 112:537-8
- Moser KM, Cantor JP, Olman M, Villespin I, Graif JL, Konopka R, Marsh JJ, Pedersen C: Chronic pulmonary thromboembolism in dogs treated with tranexamic acid. *Circulation* 1991; 83:1371-9
- Royston D: A case for aprotinin in patients having deep hypothermic circulatory arrest. *J Card Surg* 1997; 12:214-20, 220-1
- Hocker JR, Saving KL: Fatal aortic thrombosis in a neonate during infusion of epsilon-aminocaproic acid. *J Pediatr Surg* 1995; 30:1490-2
- Saffitz JE, Stahl DJ, Sundt TM, Wareing TH, Kouchoukos NT: Disseminated intravascular coagulation after administration of aprotinin in combination with deep hypothermic circulatory arrest. *Am J Cardiol* 1993; 72:1080-2
- Royston D: Blood-sparing drugs: Aprotinin, tranexamic acid, and epsilon-aminocaproic acid. *Int Anesthesiol Clin* 1995; 33:155-79
- Mohamed MS MM, Kakkar VV: Thrombogenicity of heparin and non-heparin bound arterial prostheses: An in vitro evaluation. *J R Coll Surg Edinb* 1998; 43:155-7
- Hirt S DD, Siclari R, Rohde R, Haverich A: Collagen presealed or uncoated aortic bifurcation Dacron prosthesis: A 5 year clinical follow-up study. *Thorac Cardiovasc Surg* 1991; 39:365-70
- Shirota K, Watanabe T, Takagi Y, Ohara Y, Usui A, Yasuura K: Maintenance of blood heparin concentration rather than activated clotting time better preserves coagulation system in hypothermic cardiopulmonary bypass. *Artif Organs* 2000; 24:49-56
- Despotis GJ, Joist JH: Anticoagulation and anticoagulation reversal with cardiac surgery involving cardiopulmonary bypass: An update. *J Cardiothorac Vasc Anesth* 1999; 13:18-29

## A Novel Method of One-lung Isolation Using a Double Endobronchial Blocker Technique

David Amar, M.D.,\* Dawn P. Desiderio, M.D.,† Manjit S. Bains, M.D.,‡ Roger S. Wilson, M.D.§

THE use of endobronchial blockers to provide one-lung isolation during anesthesia for thoracic surgery has been previously described.<sup>1</sup> Based on clinical experience, the primary disadvantage of this technique is the potential for the endobronchial blocker to become dislodged and obstruct the trachea.<sup>2</sup> This is especially true when the blocker is placed in the right mainstem bronchus. We present our experience with a double endobronchial blocker (DEB) technique that effectively deals with this problem.

### Case Report

A 69-yr-old man weighing 92 kg with carcinoma of the esophagus was scheduled to undergo flexible esophagoscopy and bronchoscopy, followed by an Ivor-Lewis esophagectomy through laparotomy and right thoracotomy incisions. It is our practice to provide early postoperative ventilatory support for such patients. Therefore, use of a double-lumen endotracheal tube (DLT) would require that we exchange the DLT with a single-lumen tube again at the end of surgery. This procedure involves a risk, albeit small, of aspiration. Therefore, a decision was made to use an endobronchial blocker placed externally to the single lumen endotracheal tube to avoid further airway manipulation before and after the operation.

Anesthesia was induced using sodium thiopental, fentanyl, and succinylcholine and maintained with isoflurane in oxygen, fentanyl, and pancuronium. The patient's trachea was intubated with an 8/14-French Fogarty Occlusion Catheter (Baxter Healthcare Co., Irvine, CA) and then with an 8.0-mm-ID standard endotracheal tube. After bronchoscopy and esophagoscopy, the surgeon decided to enter the thorax before entering the abdomen because the trachea seemed to be compressed by the esophageal carcinoma, possibly rendering the patient unresectable. This approach would spare the need for the abdominal incision. With the aid of a 4.1-mm-OD fiberscope (Olympus LF-GP; Olympus Optical Co., Ltd., Tokyo, Japan) the Fogarty catheter was

positioned in the right mainstem bronchus and later inflated under direct vision with 5 ml air at the start of the right thoracotomy. When the lung was visualized through the surgical incision, it was obvious that there was unsatisfactory one-lung isolation with full lung expansion. Multiple attempts to position the endobronchial blocker in the right mainstem bronchus to occlude the right upper lobe orifice were unsuccessful. It was then decided to advance the endobronchial blocker into the bronchus intermedius and inflate the balloon with 4 ml air. A Cook airway adapter (Cook Critical Care, Bloomington, IN) was used to introduce a second 8/14-French Fogarty catheter through the endotracheal tube and position it in the orifice of the right upper bronchus without difficulty and inflate the balloon with 3 ml air (figs. 1A, 1B, and 2A). One-lung isolation was accomplished, and surgery proceeded without further interruption. Unfortunately, the carcinoma was contiguous with the aorta, and further attempts to resect were abandoned. The remainder of the patient's anesthetic procedure and recovery were uneventful.

### Additional Experience

After the initial experience with this patient, we have used the DEB technique in eight patients undergoing esophageal or pulmonary resection. Lung isolation was accomplished without difficulty in all patients. We subsequently modified our approach in six other patients undergoing thoracic surgery. We tested the feasibility of inserting both endobronchial blockers through an 8.0- or 9.0-mm-ID single-lumen standard endotracheal tube, as shown in figure 2B. One of these patients required an awake fiberoptic intubation for a history of difficult intubation. We measured airway peak and plateau pressures in this patient whose trachea was intubated with an 8.0-mm-ID standard endotracheal tube: 24 and 15 cm H<sub>2</sub>O at baseline, 30 and 18 cm H<sub>2</sub>O with both endobronchial blockers in place, and 42 and 22 cm H<sub>2</sub>O with both blockers and a 4.1-mm-OD Olympus LF-GP fiberscope placed intraluminally, respectively. None of the patients had difficult ventilation or oxygenation due to the presence of both endobronchial blockers.

### Discussion

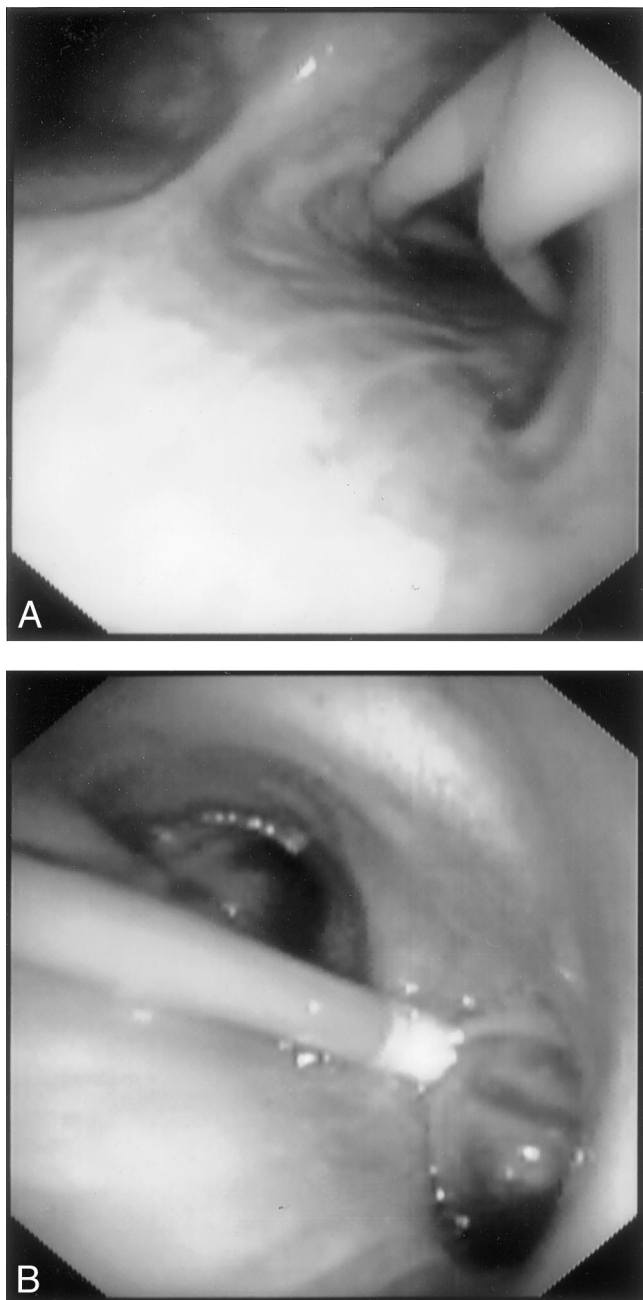
We have presented the DEB technique as an alternative method to the DLT to provide one-lung isolation. Our initial goal was to minimize the potential risk for aspiration and airway trauma at the conclusion of esophageal surgery. The patient presented in this report seemed to have a short right mainstem bronchus, a condition that may be found in approximately 10% of the population.<sup>3</sup> In addition, 0.4-2% of patients have a right upper lobe orifice arising at or above the level of the

Additional material related to this article can be found on the ANESTHESIOLOGY Web site. Go to the following address, click on Enhancements Index, and then scroll down to find the appropriate article and link. <http://www.anesthesiology.org>

\* Associate Professor of Anesthesiology, † Associate Professor of Clinical Anesthesiology, § Professor and Chairman of Anesthesiology, Departments of Anesthesiology and Critical Care, ‡ Professor of Clinical Surgery, Department of Surgery.

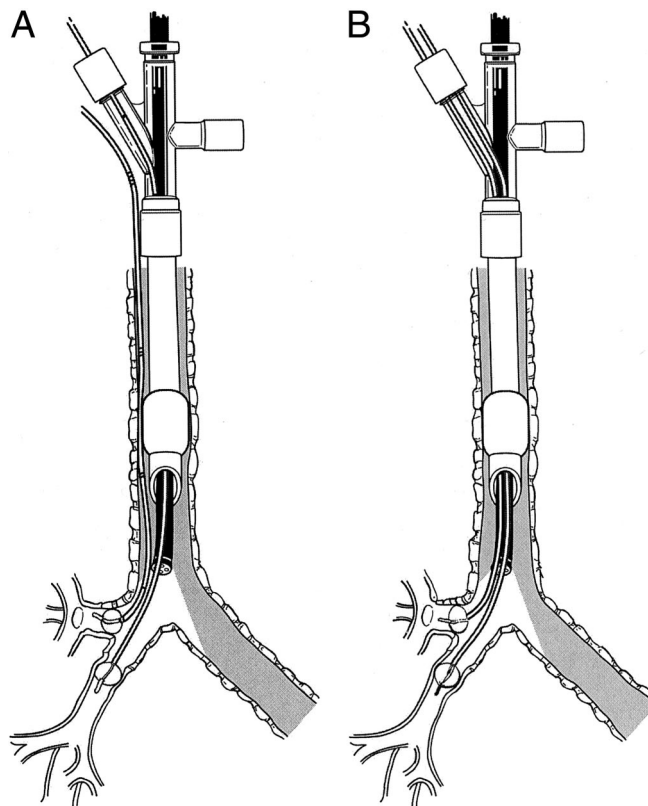
Received from the Departments of Anesthesiology and Critical Care Medicine and Surgery, Memorial Sloan-Kettering Cancer Center and Weill Medical College of Cornell University, New York, New York. Submitted for publication April 18, 2001. Accepted for publication July 27, 2001. Support was provided solely from institutional and/or departmental sources.

Address reprint requests to Dr. Amar: Memorial Sloan-Kettering Cancer Center, 1275 York Avenue, M304, New York, New York 10021. Address electronic mail to: [amard@mskcc.org](mailto:amard@mskcc.org). Individual article reprints may be purchased through the Journal Web site, [www.anesthesiology.org](http://www.anesthesiology.org).



**Fig. 1.** Fiberoptic views of the double endobronchial blockers from above the carina (A) and right mainstem bronchus (B). (These figures appear in color in the Web Enhancement.)

carina. Both of these anatomic variations can account for failure of a single endobronchial blocker technique to provide complete one-lung isolation. Other examples of extensive operations in which one-lung isolation is routinely used with a DLT and commonly require a period of postoperative mechanical ventilation with a single-lumen endotracheal tube include major pulmonary resection, thoracoabdominal aortic reconstruction, and extensive thoracolumbar spine fusion. We subsequently extended our experience with the DEB technique and found that it provided satisfactory one-lung isolation in



**Fig. 2.** Schematic of the double endobronchial blocker technique. (A) One blocker is external to a standard endotracheal tube, and the second blocker and fiberscope together are intraluminal. (B) Both blockers and the fiberscope are positioned within the endotracheal tube.

patients undergoing minimally invasive or major thoracic surgery. DLTs are frequently used to provide one-lung isolation during cardiothoracic and other surgery. However, there are situations in which the anesthesiologist may elect to place a DLT and, even with much expertise, may be forced to abandon its use in cases when it is difficult or impossible to do so because of unanticipated anatomical constraints.<sup>4,5</sup> Also, patients requiring an awake fiberoptic intubation for a known difficult airway present a challenge for DLT placement. Use of the DEB technique in these clinical situations offers the advantage of instrumenting the airway with a smaller endotracheal tube and, if required, avoiding the need to replace the DLT at the end of surgery for any reason.

The use of selective lobar blockade in adults has been reported to improve arterial oxygenation during one-lung ventilation in some patients undergoing thoracic surgery.<sup>6</sup> Our DEB technique could also be considered for selective lobar blockade in adults who have marginal pulmonary function reserve in which complete isolation of the left or right lung would cause hypoxemia or in situations in which the surgeon does not need more than selective lobar blockade to accomplish the desired operation. In fact, using the DEB technique for video-

assisted thoracoscopy to biopsy a right lower lobe mass, we placed the distal endobronchial blocker in the bronchus intermedius and inflated its cuff while the second endobronchial blocker placed in the orifice of the right upper bronchus was not inflated but provided reduced ventilation to that lobe so that surgical conditions were satisfactory. Recently, Takahashi *et al.*<sup>7</sup> reported their experience of selective lobar endobronchial blockade in children undergoing thoracic surgery. Whether the DEB technique may be used safely in children or small adults requires further study. We speculate that this will depend on the size of the trachea, the size of the endotracheal tube, and whether one can insert an appropriately sized endobronchial blocker through the endotracheal tube and another externally to it or both endobronchial blockers externally to the endotracheal tube.

Factors that might limit use of the DEB method are operator inexperience with the use of fiberoptic bronchoscopy and lack of knowledge of airway anatomy. Also, it is anticipated that there will be a learning curve to achieve perfect results, which may translate into increased operating room time utilization. However, this increase in operating room time usage will be offset by avoiding the need to replace a DLT at the conclusion of surgery or by struggling to insert a DLT in difficult clinical situations. Similarly, the cost of two Fogarty catheters are greater than one DLT by approximately \$50, and this should be weighed against the benefits of avoiding repeated airway instrumentation and risk for trauma, aspiration, or both. Common clinical practice standards at one's own institution in conjunction with cost considerations and having the surgeon participate in discussions about which method of one-lung isolation to use are intuitive to achieve satisfactory results and to solve potential intraoperative problems related to this technique. In addition to known methods to treat severe hypoxemia during one-lung ventilation, such as positive end-expiratory pressure to the ventilated lung, intermittent ventilation of the collapsed lung, or both, the DEB

technique offers the option to selectively inflate the nonoperative segment of the lung to hopefully improve oxygenation without compromising the operation. Our experience using this technique in 15 patients should not be interpreted as an efficacy trial but as a stimulus for further evaluation of its applicability and safety.

The Fogarty catheters used in this report lack suction ports and thus the ability to insufflate oxygen or to provide jet ventilation. Alternative endobronchial blockers with suction ports include the wire-guided Arndt blocker (Cook Critical Care) and the Univent tube (Vitaed Medical Products, Lewiston, NY). In contrast to the DEB technique, both of these alternatives have the same problem of dislodgement when used on the right side.<sup>2</sup> In addition, if a patient requires extended mechanical ventilation postoperatively, the Univent tube may need to be exchanged for a standard endotracheal tube.

In conclusion, we present a novel method for one-lung isolation using a DEB technique. This method could be considered for patients undergoing major surgery or for minimally invasive procedures. We believe that the DEB method may lead to fewer airway interventions and reduce the potential for injury.

## References

1. Ginsberg RJ: New technique for one-lung anesthesia using an endobronchial blocker. *J Thorac Cardiovasc Surg* 1981; 82:542-6
2. Wilson RS: Endotracheal intubation, *Thoracic Anesthesia*, 2nd edition. Edited by Kaplan JA. New York, Churchill Livingstone, 1991, pp 371-88
3. Atwell SW: Major anomalies of the tracheobronchial tree. *Chest* 1967; 52:611-5
4. Benumoff JL, Partridge BL, Salvaterra C, Keating J: Margin of safety in positioning modern double-lumen endotracheal tubes. *ANESTHESIOLOGY* 1987; 67: 729-38
5. Capdeville M, Hall D, Koch CG: Practical use of a bronchial blocker in combination with a double-lumen endotracheal tube. *Anesth Analg* 1998; 87: 1239-41
6. Campos JH: Effects on oxygenation during selective lobar versus total lung collapse with or without continuous positive airway pressure. *Anesth Analg* 1997; 85:583-6.
7. Takahashi M, Yamada M, Izumi H, Kato M, Yamamuro M, Hashimoto Y: Selective lobar-bronchial blocking for pediatric video-assisted thoracic surgery. *ANESTHESIOLOGY* 2001; 94:170-2