

Immunohistochemical Expression of Cortactin and Focal Adhesion Kinase Predicts Recurrence Risk and Laryngeal Cancer Risk Beyond Histologic Grading



M. Ángeles Villaronga¹, Francisco Hermida-Prado¹, Rocío Granda-Díaz¹, Sofía T. Menéndez¹, Saúl Álvarez-Teijeiro¹, Miquel Quer², Isabel Vilaseca³, Eva Allonca¹, Marta Garzón-Arango¹, Victoria Sanz-Moreno⁴, Aurora Astudillo⁵, Juan P. Rodrigo¹, and Juana M. García-Pedrero¹

Abstract

Background: Cortactin (*CTTN*) and the focal adhesion kinase (*FAK*) are two major candidate genes to, respectively, drive 11q13- and 8q24-associated aggressive behavior in various cancers. Recent evidence uncovered their clinical relevance in early stages of tumorigenesis as promising biomarkers for cancer risk assessment.

Methods: Using a multicenter validation study, *CTTN* and *FAK* expression was evaluated by immunohistochemistry (IHC) in a cohort of 109 patients with laryngeal precancerous lesions, and correlated with clinicopathologic parameters and laryngeal cancer risk. The pathophysiologic role of *CTTN* and *FAK* was further investigated using functional studies in cellular models.

Results: Positive *CTTN* and *FAK* expression (scores 2 and 3) was detected in 49 (41%) and 35 (32%) laryngeal dysplasias, respectively. Univariate Cox analysis showed that *CTTN* and *FAK* expression but not histologic grading was significantly associated with both recurrence risk and laryngeal cancer risk. Patients

carrying strong *CTTN*- or *FAK*-expressing lesions (score 3) experienced the highest laryngeal cancer incidence (log-rank $P < 0.001$). In multivariate stepwise analysis, *FAK* expression [HR = 13.91; 95% CI, 4.82–40.15; $P < 0.001$] and alcohol consumption (HR = 2.22; 95% confidence interval, 1.17–4.20; $P = 0.014$) were significant independent predictors of laryngeal cancer development. Targeting *FAK* by either RNAi or pharmacologic inhibitors effectively blocked cell growth, colony formation, and invasion into 3D collagen matrices.

Conclusions: *CTTN* and *FAK* emerge as powerful predictors of laryngeal cancer risk and recurrence risk beyond histologic grading.

Impact: Our work supports the applicability of IHC *CTTN* and *FAK* as complementary markers for risk stratification in patients with laryngeal precancerous lesions. *Cancer Epidemiol Biomarkers Prev*; 27(7); 805–13. ©2018 AACR.

Introduction

Head and neck squamous cell carcinoma (HNSCC) is the sixth most common cancer worldwide (1). Despite the latest advances using combined modality therapies (surgery and radio/chemo-

therapy), the survival rates have not improved significantly over the last years (2). HNSCC is a very complex and heterogeneous disease involving multiple genetic alterations and highly variable biological behavior and disease outcome (3, 4). This highlights the urgent need of novel methods to enable more accurate and effective cancer detection, prognostication, and also the development of personalized therapeutic strategies.

Amplification of the chromosomal regions 8q23-24 and 11q13 are two of the most recurrent genetic alterations in HNSCC, which have been associated with recurrent and metastatic disease, and poor disease outcome (5). The genes *FAK/PTK2* and *CTTN* (formerly *EMS1*) that encode the focal adhesion kinase (*FAK*) and the actin-binding protein cortactin (*CTTN*) have emerged as the major candidate genes to, respectively, drive 8q24- and 11q13-associated aggressive behavior and tumor spreading (5).

We and others have consistently demonstrated the association of both *CTTN* gene amplification and protein overexpression in tumor progression, found to correlate significantly with poor prognosis and reduced survival in HNSCC patients (6–8), and other carcinomas (9–11). *FAK* overexpression has also been linked to increased invasive and metastatic potential in various cancers (12–15).

This prompted us to investigate the role of *CTTN* and *FAK* in early stages of HNSCC tumorigenesis and their contribution to tumor initiation and acquisition of an invasive phenotype. Our

¹Department of Otolaryngology, Hospital Universitario Central de Asturias and Instituto Universitario de Oncología del Principado de Asturias, University of Oviedo, CIBERONC, Oviedo, Spain. ²Department of Otolaryngology, Hospital Santa Creu i Sant Pau, Barcelona, Spain. ³Department of Otolaryngology, Hospital Clínic, Barcelona, Spain. ⁴Tumour Plasticity Laboratory, Randall Division of Cell and Molecular Biophysics, Guy's Campus, King's College London, London, United Kingdom. ⁵Department of Pathology, Hospital Universitario Central de Asturias, Oviedo, Spain.

Note: Supplementary data for this article are available at Cancer Epidemiology, Biomarkers & Prevention Online (<http://cebp.aacrjournals.org/>).

M. Ángeles Villaronga and Francisco Hermida-Prado contributed equally to this article.

Corresponding Authors: Juana María García-Pedrero, Hospital Universitario Central de Asturias, Av de Roma, Oviedo, Asturias 33011, Spain. Phone: 0034-985107937; E-mail: juanagp.finba@gmail.com; Juan Pablo Rodrigo, E-mail: juanpablo.rodrigo@sespa.es; and M. Ángeles Villaronga, E-mail: angelesvillaronga@gmail.com

doi: 10.1158/1055-9965.EPI-17-1082

©2018 American Association for Cancer Research.

findings uncovered the clinical and biological relevance of CTTN and FAK in HNSCC tumorigenesis and, more importantly, their potential utility as biomarkers for cancer risk assessment (16, 17).

Using a multicenter validation study, we herein demonstrate that immunohistochemistry (IHC) determination of CTTN and FAK robustly predicts recurrence risk and laryngeal cancer risk beyond histologic grading, therefore, recommending their clinical application as complementary markers for risk stratification. Functional analysis in HNSCC-derived cell lines further contributed to delineate the pathobiological role of CTTN and FAK. Our results provide strong evidence supporting the involvement of FAK in laryngeal tumorigenesis and malignant transformation. Effective inhibition of cell growth, colony formation, and 3D invasion unveils that pharmacologic targeting of FAK could constitute a promising therapeutic strategy for HNSCC prevention and treatment.

Materials and Methods

Patients and tissue specimens

Surgical tissue specimens from patients who were diagnosed of laryngeal dysplasia between 2004 and 2010 were retrospectively collected in accordance to approved institutional review board guidelines. Patients must meet the following criteria to be included in the study: (i) pathologic diagnosis of laryngeal dysplasia; (ii) with lesions of the vocal folds; (iii) no previous history of head and neck cancer; (iv) complete excisional biopsy of the lesion; (v) a minimum follow-up of 5 years (or until progression to malignancy occurred); and (vi) patients with diagnosis of laryngeal dysplasia who developed cancer within the next 6 months were excluded from the study. A total of 109 patients who met these criteria were included in this study. This series included patients treated at the Hospital Universitario Central de Asturias (Oviedo, Spain; $n = 23$) and two other collaborating institutions in Barcelona, Spain, the Hospital de la Santa Creu i Sant Pau ($n = 46$) and the Hospital Clínic ($n = 40$). There was no overlap with the patients enrolled in our previous study (16). All experimental procedures were conducted in accordance to the Declaration of Helsinki and approved by Institutional Ethics Committees of the Hospital Universitario Central de Asturias (Asturias, Spain), Hospital Sant Pau and Hospital Clínic (Barcelona, Spain), and by the Regional CEIC from Principado de Asturias (date of approval 18th of July 2013; approval number: 81/2013) for the project PI13/00259. Informed consent was obtained from all patients. All the patients were treated with macroscopically complete excisional biopsy of the lesion, either with CO₂ laser or with cold instruments. Microscopically surgical margins were not assessed. No other treatments were administered. Patients were followed up every 2 months in the first 6 months after completing the treatment, every 3 months until the second year, and every 6 months thereafter.

Representative tissue sections from the original biopsy material were obtained from archival, paraffin embedded blocks, and the histologic diagnosis, and epithelial dysplasia grade was confirmed in all the cases by an experienced pathologist (A. Astudillo). The sections selected for study also contained normal epithelia as internal controls. The premalignant lesions were classified into the categories of low-grade and high-grade dysplasia following the WHO classification (4th edition; ref. 18).

IHC

The formalin-fixed paraffin-embedded tissues were cut into 3- μ m sections and dried on Flex IHC microscope slides (Dako).

The sections were deparaffinized with standard xylene and hydrated through graded alcohols into water. Antigen retrieval was performed using Envision Flex Target Retrieval solution, high pH (Dako). Staining was done at room temperature on an automatic staining workstation (Dako Autostainer Plus) with mouse anti-cortactin mAb Clone 30 (BD Biosciences Pharmingen) at 1:200 dilution or mouse anti-FAK mAb Clone 4.47 (Upstate Biotechnology) at 1:250 dilution using the Dako EnVision Flex + Visualization System (Dako Autostainer). Counterstaining with hematoxylin was the final step.

Because CTTN and FAK staining showed a homogeneous distribution, a semiquantitative scoring system based on staining intensity was applied, as reported previously (16). Immunostaining of the dysplastic areas was scored blinded to clinical data by two independent observers as negative (absence of expression, 0), weak (staining similar to that observed in normal epithelium, 1), moderate (intermediate staining, 2), and strong protein expression (intense and homogeneous staining, 3), with a high level of inter-observer concordance (> 95%).

HNSCC-derived cell lines and cell culture conditions

FaDu cells originated from an undifferentiated hypopharyngeal carcinoma were purchased from the ATCC (ATCC HTB-43). The HNSCC cell line SCC42B derived from a primary laryngeal carcinoma (T4N3M0) was initiated and kindly provided by Dr. R. Grenman in 2003 (Department of Otolaryngology, University Central Hospital, Turku, Finland; ref. 19). Cell line authentication was performed by DNA (STR) profiling at the SCT Core Facilities (University of Oviedo, Asturias, Spain) in 2016. All the cell lines used in this study have been passaged and kept fewer than 4 months after reauthentication or thawing. All cell lines were tested periodically for mycoplasma contamination by PCR to specifically amplify a conserved region of the mycoplasma 16S rRNA gene (Biotools Detection Kit).

Cells were grown in DMEM supplemented with 10% FBS, 100 U/mL penicillin, 200 mg/mL streptomycin, 2 mmol/L L-glutamine, 20 mmol/L HEPES (pH 7.3), and 100 mmol/L non-essential amino acids.

Transfection with siRNAs

siRNA duplexes were purchased from Thermo Scientific Dharmacon. Human ON-TARGETplus SMARTpools were used to knockdown specifically CTTN and FAK expression, and siGENOME RISC-Free Control was used as a negative control siRNA.

HNSCC cells were plated into 6-well plates in antibiotic-free medium at a density of 60,000 cells/well. The next day, cells were transfected with pooled siRNAs duplexes using Lipofectamine 2000 (Invitrogen) according to manufacturers' protocol.

Western blotting

Cells were lysed in Laemmli sample buffer and sonicated for 15 seconds before centrifugation. Samples were resolved by SDS-PAGE and transferred subsequently to nitrocellulose membranes (Amersham Protran, GE Healthcare).

The membranes were blocked for 1 hour with Odyssey blocking buffer and incubated overnight with the following specific primary antibodies at 1:1,000 dilution – cortactin (Clone 30) from BD Transduction, FAK (Clone 4.47) from Upstate Biotechnology, phospho-FAK pTyr397 (44-624G) from Invitrogen, or GAPDH (MAB374; at 1:10,000 dilution) from Millipore. The Alexa Fluor secondary antibodies IRDye 800CW Goat anti-Rabbit IgG (H+L)

and IRDye 680 RD Goat anti-Mouse IgG (H+L) were used for detection. Membranes were scanned with the Odyssey Fc Dual-Mode Imaging System (LI-COR Biosciences) using the red (700 nm) and green (800 nm) channels.

Soft agar colony formation assay

Colony formation assay was carried out using the CytoSelect 96-Well Cell Transformation Assay Kit (Cell Biolabs Inc). Briefly, 50 μ L of base agar matrix was added in the bottom of each well of a 96-well plate. When the agar was solid, 75 μ L of cell suspension/soft agar matrix containing 2,000 cells was layered on top followed by 50 μ L of 2 \times complete medium after matrix solidification. After 7 days, the agar matrix was solubilized and the relative growth of colonies was determined in quadruplicates using a tetrazolium-based MTS test (CellTiter 96 AQueous One Solution Cell Proliferation Assay from Promega) reading the absorbance at 490 nm in a Synergy HT plate reader (BioTek).

Cell growth analysis

HNSCC cells were plated into 96-well plate at a density of 2,000 cells/well, treated with the vehicle (DMSO) or different doses of PF-573228, PF-562271, and VS-6063 (also known as defactinib or PF-04554878) from Selleck Chemicals. Cell proliferation was measured at 72 hours. For siRNA assays, cells were seeded 72 hours posttransfection and cell viability measured after 96 hours.

Quantification of cell number was determined in quadruplicates using a tetrazolium-based MTS test (CellTiter 96 AQueous One Solution Cell Proliferation Assay from Promega) and reading absorbance at 490 nm with the use of a Synergy HT plate reader (BioTek). The proliferation rate for each experimental condition was quantified by dividing the absorbance data at the endpoint between the absorbance data at the initial point, and these data were normalized to either vehicle-treated or siControl-transfected cells.

Three-dimensional spheroid invasion assays

Cells were suspended in DMEM medium plus 5% methyl cellulose (Sigma) at 80,000 cells/mL. Cell spheroids were subsequently formed by serial pipetting of 25 μ L into a nonadhesive petri dish (2,000 cells/spheroid) and incubated in an inverted position for 18 hours. Next day, each cell spheroid was transferred to an individual well of 96-well plate and embedded into a volume of 110 μ L of 2.3 mg/mL bovine collagen type I matrix

(PureCol) from Advanced Biomatrix, and filled with 100 μ L of complete media. Collective cell invasion was monitored using a Zeiss Cell Observer Live Imaging microscope coupled with a CO₂ and temperature maintenance system. Time-lapse images were acquired every 15 minutes during 24 hours using a Zeiss AxioCam MRc camera. The area of each individual spheroid was measured using Image J analysis program. The invasive area was determined by calculating the difference between the final area (at each represented time) and the initial area ($t = 0$ hour), and data were normalized to the control (untreated) cells.

Statistical analysis

χ^2 and Fisher exact tests were used for comparison between categorical variables. For time-to-event analysis, Kaplan–Meier curves were plotted. Differences between survival times were analyzed by the log-rank method. Cox proportional hazards models were utilized for univariate analysis. The hazard ratios (HRs) with 95% confidence intervals (CIs) and *P* values were reported. The predictive potential of the studied variables was evaluated by performing ROC curves analysis, and the discriminative efficacy of the individual variable was calculated by the area under the ROC curve (AUC). For quantitative variables, means were compared using Student *t* test. All tests were two-sided. *P* values of ≤ 0.05 were considered statistically significant.

Results

Patient characteristics

A total of 109 patients who met the above-described inclusion criteria were enrolled in the multicenter validation study. All but 9 patients were men, with a mean age of 62 years (range 30–87 years). All but 11 patients were smokers, and 54 (50%) were also habitual alcohol drinkers. The mean tobacco consumption was 46 pack-year (range 3–150), 55 (51%) moderate (1–50 pack-year), and 42 (39%) heavy (> 50 pack-year) smokers. After the diagnosis, all the patients who were active smokers received smoking cessation advice; however, 30 (28%) of them continued smoking. The histologic diagnosis and epithelial dysplasia grade was verified in all the cases by the same pathologist at our institution (A. Astudillo), and after review the premalignant lesions were classified as low-grade dysplasia (27 cases, 25%) and high-grade dysplasia (82 cases, 75%).

During the follow-up period, 28 (26%) cases suffered a premalignancy recurrence and 16 (15%) of 109 patients developed an invasive carcinoma at the biopsy site (i.e., same vocal cord).

Table 1. Evolution of the premalignant lesions in relation to histopathologic diagnosis and CTTN and FAK protein expression

Characteristic	Total no. (%)	Premalignancy recurrence		Progression to carcinoma	
		Cases (%)	<i>P</i> ^a	Cases (%)	<i>P</i> ^a
Histopathologic diagnosis					
Low-grade dysplasia	27 (25)	7 (25)	1.000	4 (15)	1.000
High-grade dysplasia	82 (75)	21 (26)		12 (15)	
CTTN protein expression					
Negative to moderate (score 0–2)	95 (87)	20 (21)	0.008	9 (9)	0.001
Strong (score 3)	14 (33)	8 (57)		7 (50)	
FAK protein expression					
Negative to moderate (score 0–2)	99 (73)	20 (20)	<0.001	9 (9)	<0.001
Strong (score 3)	10 (27)	8 (80)		7 (70)	
CTTN and/or FAK expression					
Negative to moderate (score 0–2)	91 (83)	17 (19)	0.001	7 (8)	<0.001
Strong (score 3)	18 (17)	11 (61)		9 (50)	

^aFisher exact test.

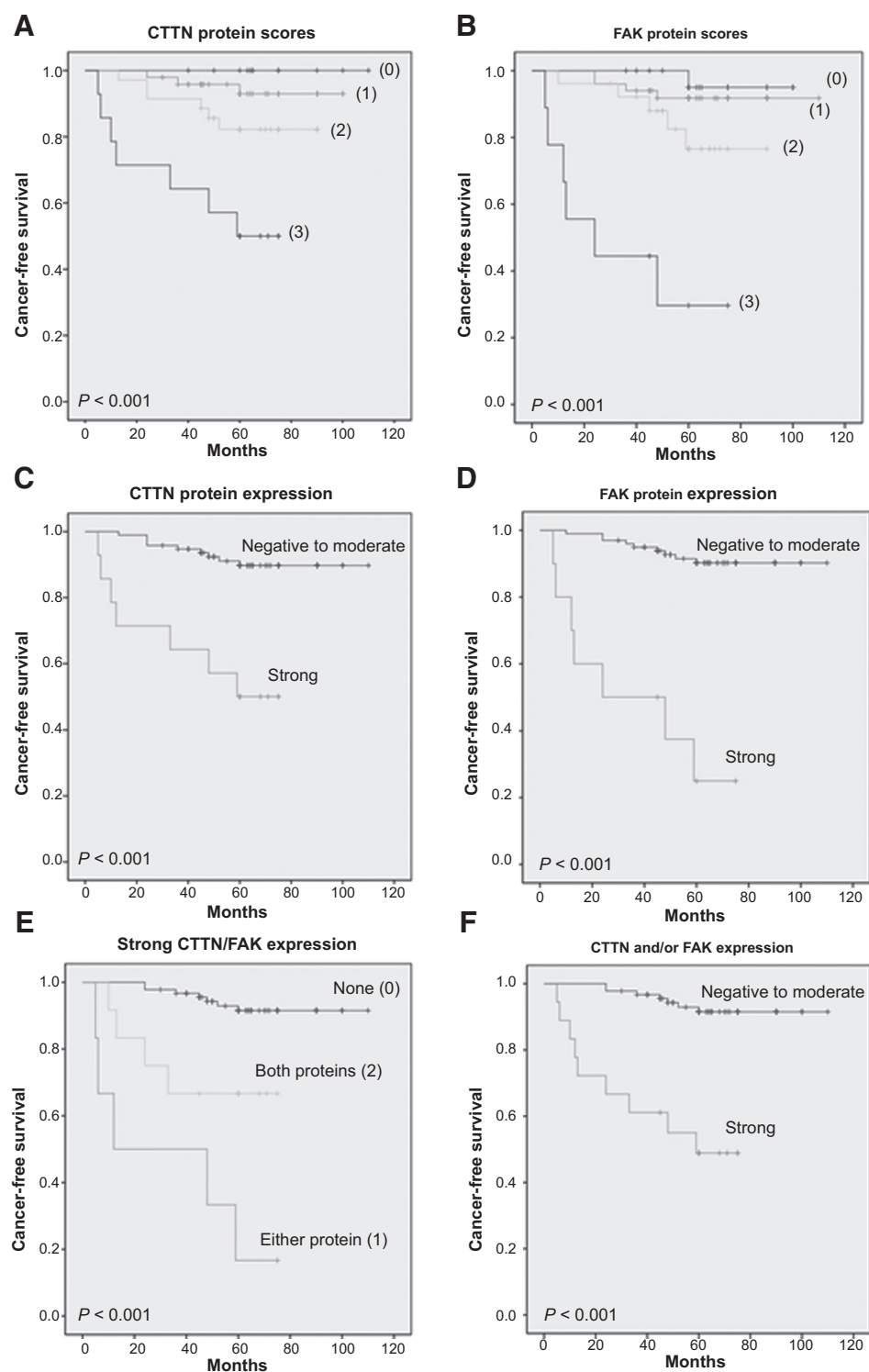


Figure 1. Kaplan-Meier cancer-free survival curves in patients with laryngeal dysplasias categorized by CTTN (A) and FAK (B) protein scores. CTTN (C) and FAK (D) protein expression dichotomized as score 3 (strong) versus scores 0-2 (negative to moderate). E, CTTN and FAK expression grouped as strong expression of either one protein (1), both proteins (2), or none (0). F, CTTN and/or FAK protein expression dichotomized as strong expression versus negative to moderate expression. *P* values were estimated using the log-rank test.

None of these patients developed laryngeal carcinomas away from the biopsy site. The mean time to cancer diagnosis in the cases that progressed was 31 months (range 10–60 months). No significant differences attributable to age were observed ($P = 1.0$) between the group of patients who developed cancer (mean, 63 years) and those who did not (mean, 62 years). The mean tobacco

consumption for patients who developed an invasive carcinoma was 66 pack-year, compared with 43 pack-year for those who did not develop cancer ($P = 0.09$). No significant differences in laryngeal cancer risk were observed ($P = 1.0$) between the subgroup of patients who continued smoking (13%, 4 of 30 cases) and those who ceased smoking (16%, 12 of 77 cases).

Table 2. Univariate Cox proportional hazards model to estimate laryngeal cancer risk

Characteristic	P	HR (95% CI)
Age (above vs. below the mean)	0.89	1.072 (0.402–2.857)
Smoking (above vs. below the mean)	0.062	2.785 (0.952–8.149)
Drinking (yes vs. no)	0.040	1.814 (1.026–3.205)
Histology (high-grade vs. low-grade dysplasia)	0.989	0.992 (0.320–3.077)
CTTN expression (score 3 vs. 0–2)	<0.001	6.810 (2.533–18.308)
FAK expression (score 3 vs. 0–2)	<0.001	13.296 (4.891–36.142)
CTTN and/or FAK (0 vs. 1 or 2)	<0.001	8.864 (3.293–23.859)

Table 3. Multivariate Cox proportional hazards model to estimate laryngeal cancer risk

Characteristic	P	HR (95% CI)
Histology (high-grade)	0.22	0.44 (0.12–1.63)
Tobacco (above the mean)	0.46	1.62 (0.41–5.79)
Alcohol (yes)	0.014	2.22 (1.17–4.20)
CTTN expression (strong)	0.37	2.02 (0.44–9.30)
FAK expression (strong)	<0.001	13.91 (4.82–40.15)

Multicenter validation of CTTN and FAK as cancer risk markers

IHC analysis of CTTN and FAK protein expression was carried out in a cohort of 109 patients with laryngeal dysplasia diagnosed at three different institutions in Spain: the Hospital Universitario Central de Asturias, the Hospital de la Santa Creu i Sant Pau in Barcelona, and the Hospital Clínic in Barcelona.

According to our previous data (16), normal epithelia showed weak CTTN staining in the most differentiated layers and weak positive FAK expression restricted to the basal cell layer, whereas the expression of both proteins was negligible in stromal cells. Forty-nine (41%) and 35 (32%) of the 109 laryngeal lesions, respectively, displayed increased CTTN and FAK expression (scored as 2 and 3) in the dysplastic areas, compared with the corresponding normal epithelia. Strong CTTN and FAK expression (score 3) was, respectively, detected in 14 (33%) and 10 (27%) laryngeal dysplasias (Supplementary Fig. S1). CTTN and FAK immunostaining preferentially yielded a cytoplasmic pattern, although some cases also exhibited protein enrichment at the cell periphery.

The expression status was analyzed in relation to the histopathologic classification of the laryngeal lesions. We found that

CTTN and FAK protein expression did not significantly correlate with the grade of dysplasia (Supplementary Table S1).

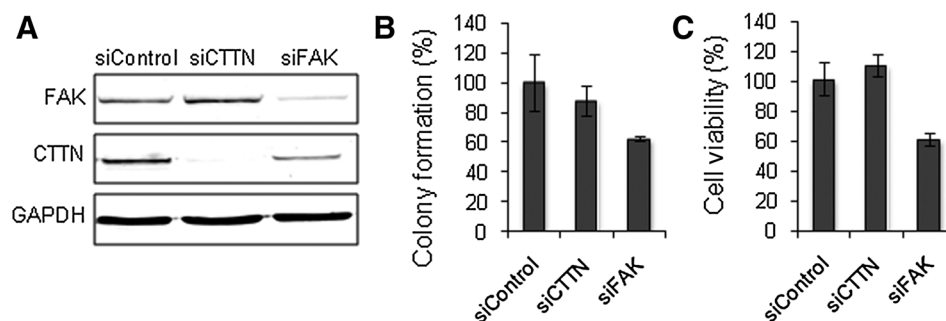
There was no statistically significant correlation between the histopathologic grade and the risk of progression to laryngeal cancer in this cohort ($P = 1.000$; Table 1).

In marked contrast, increasing CTTN and FAK protein scores (from 0 to 3) significantly correlated with an increased laryngeal cancer risk (log-rank $P < 0.001$; Fig. 1A and B). Consistent to our previous observations (16), strong CTTN and FAK expression (score 3) showed the highest risk of progression and was therefore used as a cut-off point in our subsequent analyses ($P = 0.016$ and $P < 0.001$, respectively). Thus, patients carrying strong CTTN-expressing lesions and strong FAK-expressing lesions experienced a significantly higher laryngeal cancer incidence than those with weak to moderate expression (log-rank $P < 0.001$; Fig. 1C and D). Quite remarkably, 5 years after the patients were diagnosed, 7 (70%) of the 10 patients with strong FAK expression developed laryngeal cancer whereas only 9 (9%) of the 99 patients with weak to moderate expression of these two proteins progressed to invasive carcinoma ($P < 0.001$; Table 1).

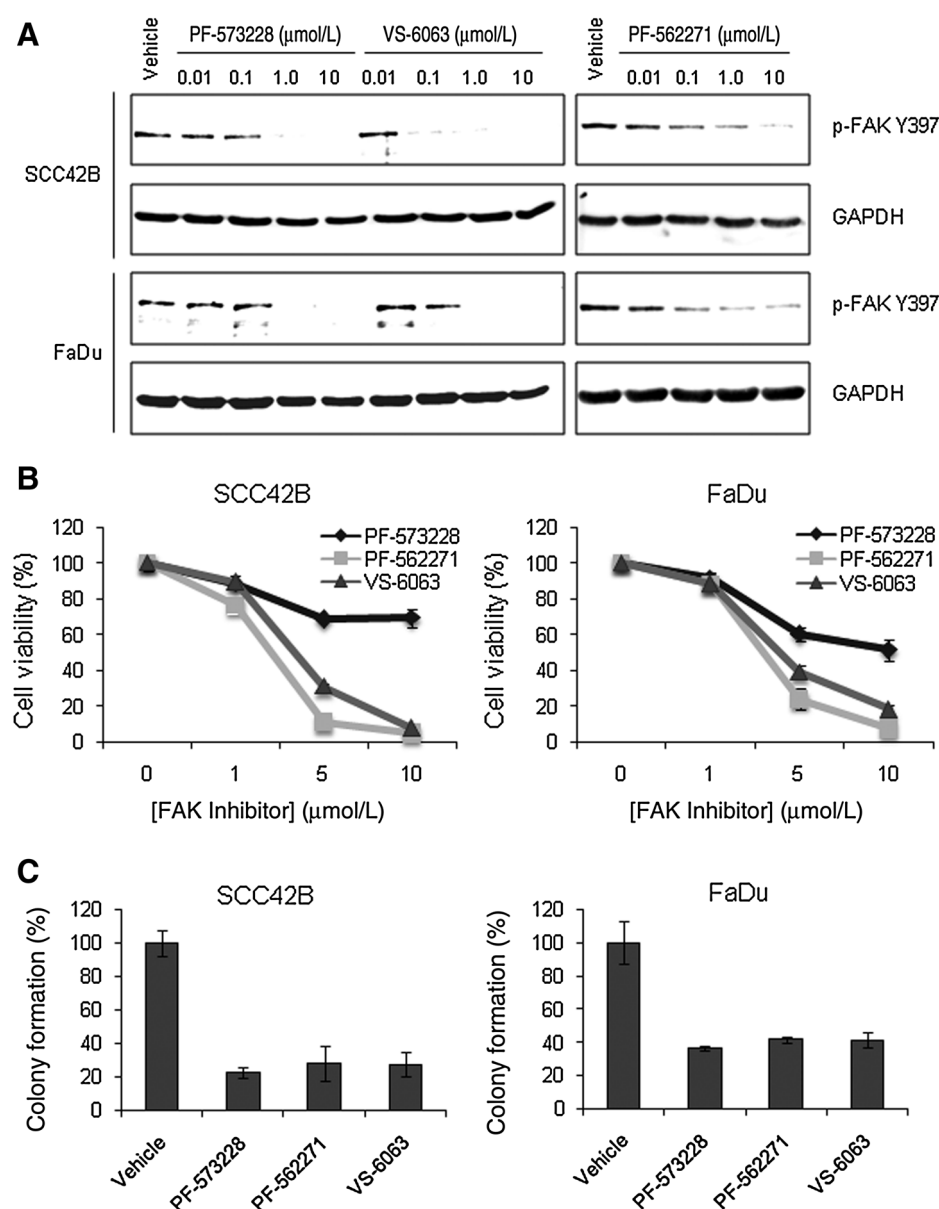
Simultaneous analysis of CTTN and FAK as predictive markers showed that lesions with strong expression of either one (group 1) or both proteins (group 2) reflected a significantly higher cancer risk than those with weak to moderate expression of both proteins (group 0) (log-rank $P = 0.003$, group 2 vs. 0; $P < 0.001$, group 1 vs. 0; Fig. 1E); however, strong expression of both proteins together did not correspond to a higher cancer risk compared with a single protein (log-rank $P = 0.045$, group 2 vs. 1; Fig. 1E). Consequently, strong expression of CTTN and/or FAK showed a robust association with laryngeal cancer risk (log-rank $P < 0.001$; Fig. 1F).

Univariate Cox analysis showed that CTTN expression and FAK expression but not histologic grading were significantly associated with laryngeal cancer risk (Table 2). In addition, alcohol consumption significantly correlated with laryngeal cancer risk, and tobacco showed a nearly significant correlation (Table 2).

In multivariate stepwise analysis including tobacco (above the mean of pack-year vs. below the mean) and alcohol (yes vs. no) consumption, histology (low-grade vs. high-grade dysplasia), CTTN and FAK expression, only FAK expression (HR = 13.91, 95% CI 4.82–40.15; $P < 0.001$) and alcohol consumption (HR = 2.22, 95% CI 1.17–4.20; $P = 0.014$) were significant independent predictors of laryngeal cancer development (Table 3).

**Figure 2.**

Effect of CTTN and FAK knockdown on cell transformation and growth. **A**, FaDu cells were transfected with either CTTN or FAK siRNAs, or siControl (as indicated), and protein expression levels analyzed by Western blot analysis 72 hours after transfection. **B** and **C**, Soft agar colony formation assay was performed for 7 days (**B**), and tetrazolium-based MTS proliferation assay for 96 hours in FaDu cells transfected with the indicated siRNAs (**C**). Data were normalized to the absorbance at day 0 (72 hours after transfection) and relative to siControl-transfected cells. All data were expressed as the mean \pm SD of at least two independent experiments performed in quadruplicate.

**Figure 3.**

Effect of FAK inhibitors on cell transformation and growth in HNSCC-derived cell lines. **A**, Western blot analysis of phosphorylated FAK Y397 levels in SCC42B and FaDu cells treated with increasing concentrations of the FAK inhibitors PF-573228, PF-562271, and VS-6063 for 1 hour. GAPDH levels were used as loading control. **B**, SCC42B and FaDu cells were treated for 72 hours with the indicated concentrations of FAK inhibitors and cell viability measured by tetrazolium-based MTS assay. **C**, Colony formation in soft agar was measured at 7 days in SCC42B and FaDu cells treated with FAK inhibitors (1 μmol/L), and cell number quantified by MTS. Data were normalized to the absorbance at day 0 and relative to control (vehicle-treated) cells. All data were expressed as the mean ± SD of at least two independent experiments performed in quadruplicate.

The clinical relevance of age, tobacco and alcohol consumption, histologic classification, CTTN expression, FAK expression, and the combined CTTN/FAK expression to predict laryngeal cancer risk and recurrence risk was estimated by ROC curves. The results of the area under the curve (AUC) clearly indicate that the combination of CTTN and FAK expression has the highest predictive value for both laryngeal cancer development and recurrence (Supplementary Table S2).

Impact of CTTN and FAK inhibition on colony formation and cell growth in HNSCC-derived cell lines

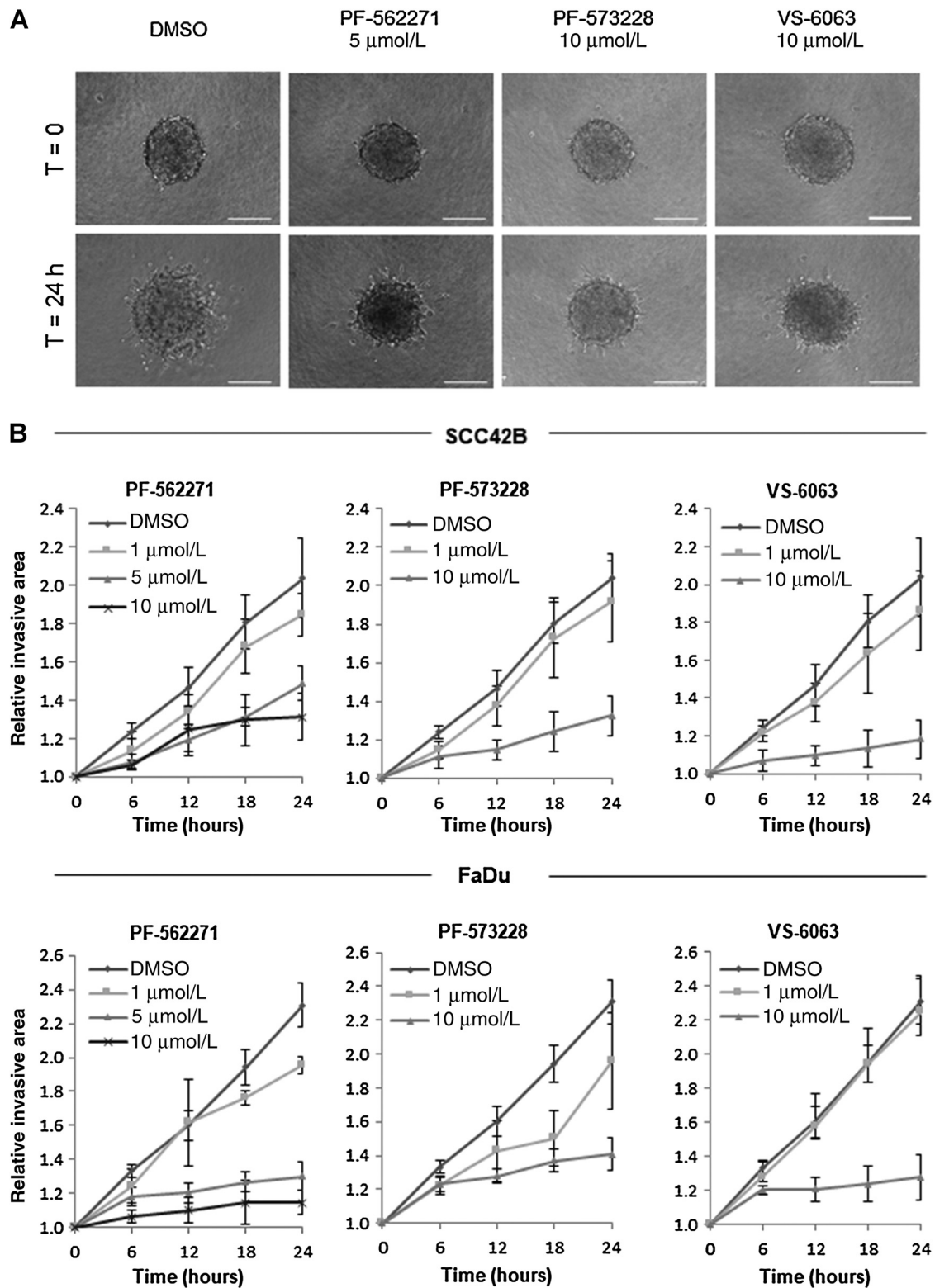
To investigate the pathophysiologic role of CTTN and/or FAK and their possible contribution to malignant transformation, transfections with specific siRNA pools were carried out in HNSCC-derived cells. Soft agar colony formation was used to monitor anchorage-independent growth, which is one of the hallmarks of cell transformation. Transfection with siCTTN and

siFAK in FaDu cells specifically and efficiently inhibited endogenous expression of CTTN and FAK (Fig. 2A) compared with siControl-transfected cells. We found that FAK depletion in FaDu cells reduced both colony formation (Fig. 2B) and cell growth (Fig. 2C).

Pharmacologic blockade of FAK effectively prevents colony formation, cell growth, and invasion in HNSCC cell lines

We next evaluated the effect of targeting FAK using different small-molecule inhibitors available (PF-573228, PF-562271, and VS-6063). All three FAK inhibitors efficiently reduced the phosphorylation levels of FAK at tyrosine 397 (pY397) in a dose-dependent manner in both FaDu and SCC42B cells (Fig. 3A).

In addition, the effect on cell viability was assessed using MTS assay in both HNSCC-derived cell lines. Although, the three compounds significantly diminished cell growth in a dose-dependent manner in FaDu and SCC42B cells, PF-562271 and VS-6063

**Figure 4.**

Effect of FAK inhibitors on the invasive potential of HNSCC-derived cell lines. **A**, Representative images from the 3D invasion assays of SCC42B spheroids embedded into a collagen matrix at initial ($t = 0$ hour) and final time ($t = 24$ hours) for the different treatments. Scale bars = 200 μm . **B**, Analysis of the invasive properties of SCC42B and FaDu cells treated for 24 hours with the indicated concentrations of the FAK inhibitors. Graphs represent the quantification of the invasive area at the indicated times. The invasive area was determined by calculating the difference between the final area and the initial area using ImageJ analysis program. Data were normalized to vehicle-treated cells and expressed as the mean \pm SD of at least two independent experiments performed in quadruplicate.

showed a more robust inhibitory effect than PF-573228 (Fig. 3B). Nevertheless, all three FAK inhibitors were highly effective blocking colony formation in both HNSCC cell lines (Fig. 3C), thus confirming the relevant role of FAK in HNSCC tumorigenesis.

Similarly, all FAK inhibitors consistently diminished the invasive potential of both SCC42B and FaDu cells in a dose-dependent manner (Fig. 4A and B; Supplementary Videos S1–S4).

Discussion

Advances in deep sequencing have uncovered the great complexity and heterogeneity of the HNSCC oncogenome (20, 21). Despite the high diversity of genetic alterations underlying each individual tumor, most molecular alterations converge into few major driver pathways (22). It has been reported that over 80% of patients harbor alterations in actionable genes (23), thus representing an excellent opportunity to develop more personalized therapeutic strategies. Nevertheless, the identification of clinically and biologically relevant features in HNSCC development and progression is fundamental to define the central nodes that may be exploited therapeutically.

CTTN and FAK have emerged as major candidates to, respectively, drive 11q13- and 8q24-associated aggressive behavior and tumor spreading in various cancers, including HNSCC. We and others have contributed to demonstrate extensively the impact of CTTN and FAK on the prognosis of HNSCC patients and their implication in disease progression and dissemination (6–8, 13–15). However, very few studies have investigated, to date, the role of CTTN and FAK in early stages of HNSCC tumorigenesis and malignant transformation. We provided the first evidence demonstrating the early occurrence of CTTN and FAK expression and gene amplification in patients with laryngeal and oral premalignant lesions (16, 17), and more importantly, uncovered their potential utility as biomarkers for cancer risk assessment. Nevertheless, these promising observations require further confirmation in large independent cohorts.

To this purpose, we performed a multicenter validation using a cohort of 109 patients with laryngeal precancerous lesions. Consistent with our previous data (16, 17), CTTN and FAK were both found to be frequently abnormally expressed in the early stages of laryngeal tumorigenesis, and that patients carrying strong CTTN- or FAK-expressing dysplastic lesions exhibit a significantly higher cancer incidence. Our *in vitro* functional analyses further contributed to delineate the pathobiological role of CTTN and FAK. Results consistently showed that targeting FAK by either RNAi or pharmacologic inhibitors effectively blocked cell growth, *in vitro* transformation and 3D invasion.

In the light of all these data, CTTN and more strongly FAK seem to be clinically and biologically relevant features that contribute to laryngeal cancer development and although the expression of both proteins does not seem to confer an additional advantage to tumor formation, the combination of CTTN and FAK evaluation was statistically significantly superior in terms of predictive value and also sensitivity therefore recommending their use as complementary markers.

It is also worth mentioning that CTTN and FAK showed robust associations with laryngeal cancer risk and superior predictive power than the histologic grading. Quite remarkably, histology even using the new WHO classification did not show a significant role in assessing laryngeal cancer risk in this cohort nor previous cohorts studied (16, 17). In marked contrast, expression of FAK

alone or CTTN and/or FAK were independent predictors in multivariate analysis in two independent cohorts of laryngeal precancerous lesions. Similar findings have been obtained in patients diagnosed with oral leukoplakias (17), thus extending extraordinarily the clinical applicability of these molecular markers to these highly common oral lesions. FAK expression has also been described as a marker for malignant transformation in CIS lesions of the cervix and breast (24). These data highlight the limited value of histopathologic classification in predicting outcome, despite the new WHO grading criteria recently established, while strongly and consistently suggest that CTTN and FAK protein evaluation may provide additional predictive power beyond histologic features.

Histopathologic diagnosis of squamous intraepithelial lesions remains the current gold standard in clinical practice for cancer risk assessment and decision-making (25). Although high-grade lesions are thought to be at a higher cancer risk, some cancers develop from low-grade dysplasias. Histologic grading is also affected by inter- and intra-observer variability. Additional objective and reliable markers are therefore needed to identify more accurately high-risk lesions beyond current clinical and histopathologic criteria (26), which will subsequently help the clinicians to choose the most adequate therapeutic option. As IHC analysis of CTTN and FAK is relatively simple and easy to interpret, it seems reasonable to recommend this molecular test to be included as complementary markers for cancer risk assessment and decision-making.

Together, these data strongly support the clinical relevance of CTTN and FAK expression in laryngeal tumorigenesis and their application as biomarkers for cancer risk assessment. Furthermore, our results suggest pharmacologic FAK targeting with currently available inhibitors to be tested for HNSCC treatment. Laryngeal cancer treatment may have severe functional consequences and a major impact on patients' quality of life. Hence, novel cancer risk markers and/or molecular-targeted therapies will undoubtedly contribute to improve local control, overall survival, reduction of morbidity, and preservation of organ function.

Disclosure of Potential Conflicts of Interest

No potential conflicts of interest were disclosed.

Authors' Contributions

Conception and design: M.Á. Villaronga, F. Hermida-Prado, J.P. Rodrigo, J.M. García-Pedrero

Development of methodology: M.Á. Villaronga, F. Hermida-Prado, R. Granda-Díaz, S.T. Menéndez, E. Allonca, M. Garzón-Arango, J.P. Rodrigo

Acquisition of data (provided animals, acquired and managed patients, provided facilities, etc.): S. Álvarez-Teijeiro, M. Quer, I. Vilaseca, A. Astudillo, J.P. Rodrigo

Analysis and interpretation of data (e.g., statistical analysis, biostatistics, computational analysis): M.Á. Villaronga, F. Hermida-Prado, R. Granda-Díaz, S.T. Menéndez, S. Álvarez-Teijeiro, M. Quer, E. Allonca, M. Garzón-Arango, J.P. Rodrigo, J.M. García-Pedrero

Writing, review, and/or revision of the manuscript: F. Hermida-Prado, R. Granda-Díaz, M. Quer, I. Vilaseca, E. Allonca, M. Garzón-Arango, V. Sanz-Moreno, J.P. Rodrigo, J.M. García-Pedrero

Study supervision: J.P. Rodrigo, J.M. García-Pedrero

Acknowledgments

This study was supported by grants from the Plan Nacional de I+D+I 2013-2016 ISCIII (CP13/00013 and PI13/00259, to J.M. García-Pedrero), RD12/0036/0015 of Red Temática de Investigación Cooperativa en Cáncer (RTICC), PI16/00280 and CIBERONC Spain (CB16/12/00390, to J.P. Rodrigo),

Fundación Merck Salud (17-CC-008), the FEDER Funding Program from the European Union, and Cancer Research UK (C33043/A12065 and C33043/A24478, to V. Sanz-Moreno). M.Á. Villaronga and S. Álvarez-Teijeiro were recipients of fellowships from ISCIII (CD13/00157 and FI12/00415, respectively). S.T. Menéndez was the recipient of a fellowship from Fundación Bancaria Caja de Ahorros de Asturias-IUOPA, and F. Hermida-Prado recipient of a fellowship from Gobierno del Principado de Asturias PCTI-Asturias (GRUPIN14-003).

We would like to acknowledge the technical assistance and samples kindly provided by the Principado de Asturias BioBank (PT13/0010/0046), financed jointly by Servicio de Salud del Principado de Asturias, Instituto de Salud Carlos III and Fundación Bancaria Cajastur and integrated in the Spanish National

Biobanks Network, IIB Sant Pau-Fundació Puigvert Biobank and the Biobanc-Hospital Clínic-IDIBAPS. We also thank Pablo Martínez-Cambler (Oficina de Investigación Biosanitaria, OIB) for his assistance with statistical analyses, as well as Teresa Ortega Montoliu and the OIB staff for the administrative support.

The costs of publication of this article were defrayed in part by the payment of page charges. This article must therefore be hereby marked *advertisement* in accordance with 18 U.S.C. Section 1734 solely to indicate this fact.

Received November 21, 2017; revised January 2, 2018; accepted April 9, 2018; published first April 13, 2018.

References

- Haddad RI, Shin DM. Recent advances in head and neck cancer. *N Engl J Med* 2008;359:1143–54.
- Forastiere A, Koch W, Trotti A, Sidransky D. Head-and-neck cancer. *N Engl J Med* 2001;345:1890–900.
- Leemans CR, Braakhuis BJ, Brakenhoff RH. The molecular biology of head and neck cancer. *Nat Rev Cancer* 2011;11:9–22.
- Pickering CR, Zhang J, Yoo SY, Bengtsson L, Moorthy S, Neskey DM, et al. Integrative genomic characterization of oral squamous cell carcinoma identifies frequent somatic drivers. *Cancer Discov* 2013;3:770–81.
- Kelley LC, Shahab S, Weed SA. Actin cytoskeletal mediators of motility and invasion amplified and overexpressed in head and neck cancer. *Clin Exp Metastasis* 2008;25:289–304.
- Rodrigo JP, García-Carracedo D, García LA, Menéndez S, Allonca E, González MV, et al. Distinctive clinicopathological associations of amplification of the cortactin gene at 11q13 in head and neck squamous cell carcinomas. *J Pathol* 2009;217:516–23.
- Rodrigo JP, García LA, Ramos S, Lazo PS, Suárez C. EMS1 gene amplification correlates with poor prognosis in squamous cell carcinomas of the head and neck. *Clin Cancer Res* 2000;6:3177–82.
- Gibus JH, Mastik MF, Menkema L, de Bock GH, Kluijn PM, Schuurings E, et al. Cortactin expression predicts poor survival in laryngeal carcinoma. *Br J Cancer* 2008;98:950–5.
- Luo ML, Shen XM, Zhang Y, Wei F, Xu X, Cai Y, et al. Amplification and overexpression of CTTN (EMS1) contribute to the metastasis of esophageal squamous cell carcinoma by promoting cell migration and anoikis resistance. *Cancer Res* 2006;66:11690–9.
- Hui R, Ball JR, Macmillan RD, Kenny FS, Prall OW, Campbell DH, et al. EMS1 gene expression in primary breast cancer: relationship to cyclin D1 and oestrogen receptor expression and patient survival. *Oncogene* 1998;17:1053–9.
- Yuan BZ, Zhou X, Zimonjic DB, Durkin ME, Popescu NC. Amplification and overexpression of the EMS1 oncogene, a possible prognostic marker, in human hepatocellular carcinoma. *J Mol Diagn* 2003;5:48–53.
- Gabarra-Niecko V, Schaller MD, Dunty JM. FAK regulates biological processes important for the pathogenesis of cancer. *Cancer Metastasis Rev* 2003;22:359–74.
- Canel M, Secades P, Rodrigo JP, Cabanillas R, Herrero A, Suarez C, et al. Overexpression of focal adhesion kinase in head and neck squamous cell carcinoma is independent of fak gene copy number. *Clin Cancer Res* 2006;12:3272–9.
- McLean GW, Carragher NO, Avizienyte E, Evans J, Brunton VG, Frame MC. The role of focal-adhesion kinase in cancer – a new therapeutic opportunity. *Nat Rev Cancer* 2005;5:505–15.
- Canel M, Secades P, Garzón-Arango M, Allonca E, Suarez C, Serrels A, et al. Involvement of focal adhesion kinase in cellular invasion of head and neck squamous cell carcinomas via regulation of MMP-2 expression. *Br J Cancer* 2008;98:1274–84.
- Rodrigo JP, Álvarez-Alija G, Menéndez ST, Mancebo G, Allonca E, García-Carracedo D, et al. Cortactin and focal adhesion kinase as predictors of cancer risk in patients with laryngeal premalignancy. *Cancer Prev Res* 2011;4:1333–41.
- de Vicente JC, Rodrigo JP, Rodríguez-Santamarta T, Lequerica-Fernández P, Allonca E, García-Pedrero JM. Cortactin and focal adhesion kinase as predictors of cancer risk in patients with premalignant oral epithelial lesions. *Oral Oncol* 2012;48:641–6.
- El-Naggar AK, Chan JKC, Grandis JR, Takata T, Slootweg PJ. WHO classification of head and neck tumours. WHO/IARC classification of tumours. 4th ed. Lyon, France: IARC; 2017.
- Lansford CD, Grenman R, Bier H, Somers KD, Kim S-Y, Whiteside TL. Head and neck cancers. In: Masters JRW, Plasson B, editors. *Human cell culture*. Dordrecht, the Netherlands: Kluwer Academic Press; 1999. p. 185–255.
- Stransky N, Egloff AM, Tward AD, Kostic AD, Cibulskis K, Sivachenko A, et al. The mutational landscape of head and neck squamous cell carcinoma. *Science* 2011;333:1157–60.
- Hedberg ML, Goh G, Chiosea SI, Bauman JE, Freilino ML, Zeng Y, et al. Genetic landscape of metastatic and recurrent head and neck squamous cell carcinoma. *J Clin Invest* 2016;126:169–80.
- Pickering CR, Zhang J, Yoo SY, Bengtsson L, Moorthy S, Neskey DM, et al. Integrative genomic characterization of oral squamous cell carcinoma identifies frequent somatic drivers. *Cancer Discov* 2013;3:770–81.
- Martin D, Abba MC, Molinolo AA, Vitale-Cross L, Wang Z, Zaida M, et al. The head and neck cancer cell oncogenome: a platform for the development of precision molecular therapies. *Oncotarget* 2014;5:8906–23.
- Oktay MH, Oktay K, Hamele-Bena D, Buyuk A, Koss LG. Focal adhesion kinase as a marker of malignant phenotype in breast and cervical carcinomas. *Hum Pathol* 2003;34:240–5.
- Gale N, Michaels L, Luzar B, Poljak M, Zidar N, Fischinger J, et al. Current review on squamous intraepithelial lesions of the larynx. *Histopathology* 2009;54:639–56.
- Nankivell P, Weller M, McConkey C, Paleri V, Mehanna H. Biomarkers in laryngeal dysplasia: a systematic review. *Head Neck* 2011;33:1170–6.