

Cytogenetic Features Of Juvenile Chronic Myelogenous Leukemia

By Garrett M. Brodeur, Lois W. Dow, and Dorothy L. Williams

Consistent chromosomal abnormalities have been described in several leukemic disorders, but relatively little is known about the cytogenetic features of juvenile chronic myelogenous leukemia (JCML). We report the serial cytogenetic findings over a 2-yr period for a patient with JCML. A large subtelocentric marker chromosome was noted in all metaphases throughout the course of his disease and provided evidence for a clonal etiology of JCML in this patient. Banding analysis identified this marker as a chromosome 8, to which most of the long arm of a chromosome 2 had been translocated. An abnormal chromosome 1 was also noted. The probable stem cell karyotype was 46,XY,t(2;8)(q21;q24),

del(1)(p33-pter), dup(1)(p21-p32). Two subclones evolved from the stem line population at different times during the course of the disease. We reviewed the cytogenetic findings for 16 other patients with JCML at this institution and for 68 patients reported elsewhere. Over 80% of these patients had normal karyotypes as determined by conventional techniques, and no consistent cytogenetic abnormalities were noted among those with an abnormal karyotype. JCML may be a heterogeneous disorder, with some patients clearly showing evidence of malignant clonal proliferation. A few of the patients with normal karyotypes may have transient or sustained failure of bone marrow maturation.

CHRONIC MYELOGENOUS LEUKEMIA (CML) represents about 5% of the leukemias in children and adolescents.¹⁻³ It has been subclassified into a juvenile type (JCML) and an adult type (ACML) on the basis of different clinical, hematologic, and cytogenetic features.^{3,4} Leukocytes from the blood and bone marrow of patients with JCML form predominantly monocytic colonies in vitro, whereas leukocytes from patients with ACML form mainly myelocytic colonies.^{5,6} The Philadelphia (Ph¹) chromosome is present in about 90% of cases of ACML, and distinct patterns of chromosomal evolution precede or coincide with the development of blast crisis in most cases.⁷ Relatively little is known about the cytogenetics of JCML because of its infrequency. The Ph¹ chromosome is always absent, and although aneuploidy is reported, no consistent abnormalities have been found.^{1,2} We report a patient with JCML who had a cytogenetic abnormality in his marrow cells. Serial cytogenetic studies of this patient provided evidence for the clonal evolution of his disease. The cytogenetic findings in this patient are compared with the findings in 68 previously reported patients with JCML as well as those in 16 other patients seen at this institution.

From the Divisions of Hematology-Oncology and Pathology, St. Jude Children's Research Hospital, Memphis, Tenn., and the Department of Pathology, Baptist Memorial Hospital, Memphis, Tenn.

Submitted August 29, 1978; accepted December 19, 1978.

Supported in part by Clinical Cancer Education Grant CA-23944, Cancer Center Support (CORE) Grant CA-21765, Leukemia Program Project Grant CA-20180, and Research Project Grant CA-15956 from the National Cancer Institute and by ALSAC.

Address reprint requests to Garrett M. Brodeur, M.D., St. Jude Children's Research Hospital, Box 318, 332 North Lauderdale, Memphis, Tenn. 38101.

© 1979 by Grune & Stratton, Inc. ISSN 0006-4971/79/5305-0002\$01.00/0

CASE REPORT

A 4-yr-old Caucasian boy referred to St. Jude Children's Research Hospital had a 4-mo history of intermittent fever, generalized lymphadenopathy, hepatosplenomegaly, and easy bruisability. At the time of admission he had a hemoglobin of 7.0 g/dl, a reticulocyte count of 1.2%, and a platelet count of 16×10^9 /liter. The leukocyte count was 77×10^9 /liter, with 43% neutrophils, 34% lymphocytes, 10% monocytes, 9% eosinophils, 1% basophils, and 3% blasts. Hemoglobin electrophoresis showed 95% hemoglobin A₁ and 5% hemoglobin F. Blood chemistries were normal, and the leukocyte alkaline phosphatase score was 197 (normal 80–130). The cerebrospinal fluid was normal, but the bone marrow had increased cellularity, with a myeloid:erythroid (M:E) ratio of 20:1, 5% monocytes, and 1% blasts. Bone marrow cytogenetic analysis identified a marker chromosome, but no Ph¹ chromosome. The patient's blood lymphocytes, stimulated by phytohemagglutinin, had a normal karyotype, and both parents' lymphocytes had normal karyotypes.

The clinical and laboratory findings were compatible with a diagnosis of JCML. The patient improved clinically after blood transfusion and splenectomy. He remained stable and essentially asymptomatic without chemotherapy for 15 mo, but then his leukocyte count increased to 232×10^9 /liter, with 13% monocytes and 1% blasts. A repeat bone marrow examination again showed increased cellularity, with an increased M:E ratio, 11% monocytes, and 3% blasts.

Chemotherapy was begun with prednisone, vincristine (VCR), 6-mercaptopurine (6-MP), and 6-azauridine. Within 1 mo his leukocyte count had decreased to 5.4×10^9 /liter, and continuation therapy was begun with VCR, 6-MP, daunomycin, and cytosine arabinoside, administered every 1–2 wk. His leukocyte count remained relatively unchanged during this treatment, although thrombocytopenia and anemia persisted. Daunomycin was discontinued after 6 mo, when the cumulative dosage had reached 550 mg/sq m. He failed to respond to subsequent chemotherapy, including methotrexate, asparaginase, and hydroxyurea. He died about 2 yr after diagnosis with *Escherichia coli* sepsis and an intracranial hemorrhage.

MATERIALS AND METHODS

Cytogenetic studies of bone marrow cells were done by a modification of the method of Tjio and Whang,⁸ and chromosome studies of blood lymphocytes were done by a modification of the method of Moorhead et al.⁹ Banding was done with the trypsin-Giemsa technique of Seabright.¹⁰ Bone marrow karyotyping was done before chemotherapy was started and several times during the course of treatment. Thirty to 50 metaphases were analyzed at each time.

RESULTS

The results of the bone marrow cytogenetic studies of the patient are summarized in Table 1. Prior to chemotherapy, the modal number of chromosomes was 45, although one metaphase had 46 chromosomes. The modal karyotype was missing a number 2 chromosome and an E group chromosome, but it had a large subtelocen-

Table 1. Serial Cytogenetic Findings for the Patient With JCML

Duration of Chemotherapy (mo)	Modal Karyotype	Number of Cells (Percentage if Bimodal)
Prior to chemotherapy	45XY,t(2;8),-E	53
2	46XY (normal)	18(40%)
	46XY,t(2;8)	27(60%)
4	46XY,t(2;8)	19(50%)
	45XY,t(2;8),-E	19(50%)
6	45XY,t(2;8),-C	40
9	Random aneuploidy with t(2;8)	32


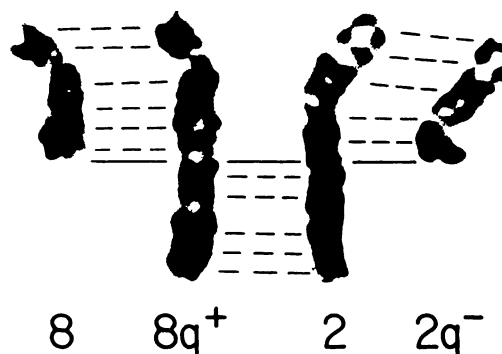


Fig. 1. Stem line karyotype 46,XY,t(2;8)(q21;q24),del(1)(p33-pter),7dup(1)(p21-p32) of bone marrow cells from the patient with JCM. Note the deleted portion from a chromosome number 2 that has been translocated to the long arm of a number 8. Also note the abnormality of the short arm of one of the chromosome 1 pair.

Fig. 2. A partial karyotype shows that the marker chromosome is composed of a chromosome 8 and the distal portion of a chromosome 2 (q21-qter) translocated to its long arm. Also shown for comparison are normal chromosomes 2 and 8, as well as the abnormal (deleted) chromosome 2. The solid line indicates the point of breakage or translocation.



tric marker. The metaphase with 46 chromosomes was missing only a number 2, and it also had the marker chromosome.

Banding studies identified the marker as a chromosome number 8, with the distal portion of the long arm of a number 2 (bands q21-qter) translocated to the ends of the long arm of the chromosome number 8. In addition, the short arm of a number 1 chromosome was abnormal, and this abnormality was consistently found in the banded metaphases. It appeared to be a deletion of the distal portion of the short arm (bands p33-pter) and a tandem duplication of bands p21-p32. A duplication was considered most likely, since no bands were missing from other chromosomes in the karyotypes. The probable stem line karyotype was 46,XY,t(2;8)(q21;q24),del(1)(p33-pter),?dup(1)(p21-p32). Figure 1 shows an example of this banded karyotype, and Fig. 2 shows a partial karyotype of the banded marker chromosome and the chromosomes from which it was derived.

After 2 mo of chemotherapy the patient continued to improve clinically, and the bone marrow karyotype was again analyzed. Forty percent of the cells had a normal 46XY karyotype, but 60% had the stem line karyotype described above. After 4 mo of chemotherapy, all of the cells had the marker chromosome; 50% had the stem line karyotype, and the other 50% had a mode of 45 but were missing an E group chromosome. After 6 mo of chemotherapy, bone marrow karyotyping showed a uniform population with a mode of 45. All cells had the marker chromosome, but were missing a C group chromosome instead of an E group chromosome. During the preterminal phase of his disease, a bone marrow karyotype did not show a clear mode, but the marker was present in all metaphases.

DISCUSSION

The presence of the marker chromosome in all bone marrow cells prior to therapy and its persistence throughout the course suggest a clonal etiology of JCML in this patient. Cells with a normal karyotype were only present early in therapy, presumably when there was some resumption of normal hematopoiesis. The marker chromosome was the most distinctive feature of the stem line karyotype, and it appeared to result from a translocation of the distal portion of the long arm of a number 2 to the long arm of a number 8, with little or no net loss of genetic material. Banding studies indicated that the marker chromosome did not result from a pericentric inversion of a number 2 (2p25 → 2q21). The overall length of the marker was two bands shorter than a normal number 2, and the length of the

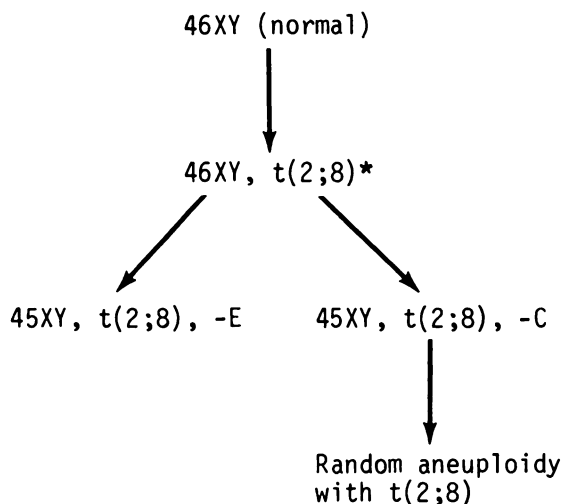


Fig. 3. Summary diagram of the karyotypic evolution of the bone marrow karyotype of the patient presented; asterisk indicates the stem cell karyotype.

“2q-” chromosome was correspondingly longer than a normal number 8. Also, the broad negative band between bands 2p16 and 2p22 was not present in the “8q+” marker, but was present in the “2q-” chromosome. Banding also identified the centromeric portion of the chromosome 2 that participated in the translocation. Had conventional techniques been used alone, this deleted chromosome 2 would have been identified as a C group chromosome.

The two different subclones that arose at different times during treatment were probably derived from the stem line karyotype (Fig. 3). The 45XY,t(2;8),-E subclone predominated at diagnosis. Soon after treatment was begun, the stem line karyotype became predominant, and the subclone temporarily disappeared. This subclone reappeared after 4 mo of chemotherapy and was entirely replaced by the 45XY,t(2;8),-C subclone 2 mo later. The marker chromosome persisted even in the preterminal phase of his illness. The abnormal chromosome 1 was also found during the clinical course, at each time that adequate banding was possible. The identity at the missing E or C group chromosomes in the two subclones could not be determined with certainty. Nevertheless, they were interpreted as distinct subclones, derived from the stem line karyotype. In order for the karyotype with a missing E group chromosome to give rise to the karyotype with a missing C group chromosome, there would have to be (1) simultaneous gain of an E and loss of a C group chromosome or (2) a deletion of material from a C to approximate the morphology of the missing E group chromosome. Since the E group chromosomes in the second clone could be easily matched as pairs, and the stem line karyotype had persisted, neither of the alternative possibilities appeared likely.

From 1962 through June 1978, 45 patients with CML were admitted to St. Jude Children's Research Hospital. Eighteen of these patients have been reported previously with respect to clinical, hematologic, and pathologic features.^{3,11} Most of the 24 patients with ACML had cytogenetic studies of the bone marrow, and all of them were Ph¹-positive. Seventeen of the 21 patients with JCML had bone marrow karyotyping, and none had a Ph¹ chromosome. Fourteen of these patients had normal karyotypes, as determined by conventional techniques. Two others had

Table 2. Summary of Abnormal Cytogenetic Findings for 12 Previously Reported Children with JCML

Reference	Case No.	Mode	Comments
Reisman and Trujillo ¹	7	47XX	Extra minute chromosome
	9	47XY	Extra minute chromosome
Hardisty et al. ²	3	46XX	Condensed G group chromosome
	4	46XY	Condensed G group chromosome
Weisgerber et al. ¹⁴	26	47	Trisomy C
	27	47	Trisomy C, 1q+
	28	46	Asymmetric chromosome 1 pair
Altman et al. ⁵	1	46XY	Translocation 3q+, 7q-
Hays et al. ²⁶	1	45X	Missing Y chromosome
Inoue et al. ²⁷	1	46XX	Translocation 3p-, 11p+
	2	45XY	Missing E group chromosome
	3	45(47)XX	45XX, -C(47XX, +G)

normal modal karyotypes, with an increase in random aneuploidy. Only the patient in the present case report had a consistently aneuploid population or marker.

Chromosome findings have been reported for 68 additional patients with JCML. Thirty-eight patients had a normal karyotype,^{1,2,4,5,12-19} and 18 others were described as "Ph¹ chromosome negative."²⁰⁻²⁵ Only 12 of the 68 patients (18%) were noted to have cytogenetic abnormalities.^{1,2,5,14,26,27} The karyotypes of these 12 patients are summarized in Table 2. Abnormalities included an extra minute chromosome, a condensed G group chromosome, trisomy C, missing Y chromosome, and various translocations and deletions, but no consistent cytogenetic abnormalities were found. An abnormality of a chromosome 1 was noted in 2 patients, but the abnormalities were not described in detail (Table 2). Our patient had an abnormality of the short arm of a chromosome 1, whereas patients with myeloproliferative disorders characteristically have trisomy for a portion of the long arm of a chromosome 1.^{28,29}

The presence of the Ph¹ chromosome in myeloid, erythroid, and megakaryocytic cells in ACML suggests that this abnormality of a hematopoietic stem cell gives rise to the clonal proliferation of most bone marrow elements. This contention is substantiated by studies with glucose-6-phosphate dehydrogenase isoenzymes, in which patients with ACML who were heterozygotic for two electrophoretically dissimilar X-linked isoenzymes had the same isoenzyme expressed in all of their myeloid, erythroid, megakaryocytic, and monocytic cells.³⁰ Such studies have not been done in JCML, but clinical and laboratory evidence indicates that the disease is also a panmyelopathy that involves granulocyte, monocyte, erythrocyte, and platelet precursors.⁵ Thus, chronic myelogenous leukemia is a more appropriate term than chronic myelocytic leukemia for both the juvenile and adult forms. The findings in our patient and those in a few other patients previously reported^{5,26,27} suggest that JCML may sometimes be a clonal disease. However, JCML differs from ACML in that it lacks a consistent marker and is characterized by a "normal" karyotype in over 80% of cases. Chromosomal abnormalities in JCML may be a secondary phenomenon, or subtle cytogenetic abnormalities may be identified when more cases are studied by banding techniques, as was the case with acute lymphoblastic leukemia.³¹

Moreover, JCML may be a heterogeneous disorder. All patients with an abnormal bone marrow karyotype and most patients with a normal karyotype probably have a malignant clonal disease, but some patients with a normal karyotype may have a nonleukemic disorder of hematopoiesis. Two pairs of young siblings with clinical and laboratory features similar to those of JCML have been reported from this institution.¹¹ These cases, now recognized as familial CML,³ all responded to splenectomy, and 1 of the 4 patients is alive and well 14 yr after diagnosis. More recently at this institution, an 8-mo-old infant was admitted with anemia, thrombocytopenia, leukocytosis, hepatosplenomegaly, and elevated fetal hemoglobin. She had a normal karyotype and has responded well to splenectomy. Although unusual, instances of a favorable outcome in disorders that are clinically similar to JCML provide evidence for the heterogeneity of this disorder and of its pathogenesis.

REFERENCES

1. Reisman LE, Trujillo JM: Chronic granulocytic leukaemia of childhood. *J Pediatr* 62:710, 1963
2. Hardisty RM, Speed DE, Till M: Granulocytic leukemia in childhood. *Br J Haematol* 10:551, 1964
3. Smith KL, Johnson WW: Classification of chronic myelocytic leukemia in children. *Cancer* 34:670, 1974
4. Kantha KRR, King M, Levy RN, Sawitsky A, Rosner F: Chronic myelogenous leukemia in childhood. *NY State J Med* 75:392, 1975
5. Altman AJ, Palmer CG, Baehner RL: Juvenile "chronic granulocytic" leukemia: A panmyelopathy with prominent monocytic involvement and circulating monocyte colony-forming cells. *Blood* 43:341, 1974
6. Altman AJ, Baehner RL: In vitro colony-forming characteristics of chronic granulocytic leukemia in childhood. *J Pediatr* 86:221, 1975
7. Mitelman F, Levan G, Nilsson PG, Brandt L: Non-random karyotypic evolution in chronic myeloid leukemia. *Int J Cancer* 18:24, 1976
8. Tjio JH, Whang J: Chromosome preparations of bone marrow cells without prior in vitro culture or in vivo colchicine administration. *Stain Technol* 37:17, 1962
9. Moorhead PS, Nowell PC, Mellman WJ, Battips DM, Hungerford DA: Chromosome preparations of leukocytes cultured from human peripheral blood. *Exp Cell Res* 20:613, 1960
10. Seabright M: A rapid banding technique for human chromosomes. *Lancet* 2:971, 1971
11. Holton CP, Johnson WW: Chronic myelocytic leukemia in infant siblings. *J Pediatr* 72:377, 1968
12. Weatherall DJ, Edwards JA, Donohoe WTA: Haemoglobin and red cell enzyme changes in juvenile myeloid leukaemia. *Br Med J* 1:679, 1968
13. Cao A, Berardi G, Leone P, Trabalza N, DeVirgilis S: Considerazioni clinico-ematologiche su di un caso di leucemia mieloide cronica "tipo giovanile." *Minerva Pediatr* 21:1646, 1969
14. Weisgerber C, Schaison G, Chavelet F, Seligmann M, Bernard J: Les leucemies myelomonocytaires de l'enfant. *Arch Fr Pediatr* 29:11, 1972
15. Maurer HS, Vida LN, Honig GR: Similarities of the erythrocytes in juvenile chronic myelogenous leukemia to fetal erythrocytes. *Blood* 39:778, 1972
16. Shapira Y, Polliack A, Cividalli G, Rachmilewitz EA: Juvenile myeloid leukemia with fetal erythropoiesis. *Cancer* 30:353, 1972
17. Dover GJ, Boyer SH, Zinkham WH, Kazazian HH, Pinney DJ, Sigler A: Changing erythrocyte populations in juvenile chronic myelocytic leukemia: Evidence for disordered regulation. *Blood* 49:355, 1977
18. Lilleyman, JS, Harrison JF, Black JA: Treatment of juvenile chronic myeloid leukemia with sequential subcutaneous cytarabine and oral mercaptopurine. *Blood* 49:559, 1977
19. Hoffman R, Zanjani ED: Erythropoietin dependent erythropoiesis during the erythroblastic phase of juvenile chronic granulocytic leukemia. *Br J Haematol* 38:511, 1978
20. Rosen RB, Nishiyama H: Leukocyte alkaline phosphatase in chronic granulocytic leukemia of childhood. *Ann NY Acad Sci* 155:992, 1968
21. Weatherall DJ, Brown MJ: Juvenile chronic myeloid leukaemia. *Lancet* 1:526, 1970
22. Stopoloni G, DiToro R: Juvenile chronic myeloid leukaemia. *Lancet* 1:1176, 1970
23. Graivier L, Gran G, Rhoades RB, Reynolds RC, Windmiller J: Priapism in a 7-week old infant with chronic granulocytic leukemia. *J Urol* 105:137, 1971
24. Weatherall DJ, Clegg JB, Wood WG,

Callender ST: Foetal erythropoiesis in human leukaemia. *Nature* 257:710, 1975

25. Mutz ID, Humphrey GB, Henderson ES: "Chronic myelogenous" leukemia of juvenile type. *Eur J Pediatr* 121:227, 1976

26. Hays T, Humbert JR, Peakman DC, Hutter JJ, Morse HG, Robinson A, August CS: Missing Y chromosome in juvenile chronic myelogenous leukemia. *Humangenetik* 29:259, 1975

27. Inoue S, Ravindranath Y, Thompson RI, Zuelzer WW, Ottenbreit MJ: Cytogenetics of juvenile type chronic granulocytic leukemia. *Cancer* 39:2017, 1977

28. Rowley JD: Mapping of human chromosomal regions related to neoplasia: Evidence from

chromosomes 1 and 17. *Proc Natl Acad Sci USA* 74:5729, 1977

29. Gahrton G, Friberg K, Zech L, Lindsten J: Duplication of part of chromosome No. 1 in myeloproliferative diseases. *Lancet* 1:96, 1978

30. Fialkow PJ, Jacobson RJ, Papayannopoulou T: Chronic myelocytic leukemia: Clonal origin in a stem cell common to the granulocyte, erythrocyte, platelet and monocyte/macrophage. *Am J Med* 63:125, 1977

31. Oshimura M, Freeman AI, Sandberg AA: Chromosomes and the causation of human cancer and leukemia. XXVI. Banding studies in acute lymphoblastic leukemia (ALL). *Cancer* 40:1161, 1977