

Fetal Cell Microchimerism in Papillary Thyroid Cancer: A Possible Role in Tumor Damage and Tissue Repair

Valentina Cirello,¹ Maria Paola Recalcati,² Marina Muzza,¹ Stefania Rossi,³ Michela Perrino,¹ Leonardo Vicentini,⁴ Paolo Beck-Peccoz,¹ Palma Finelli,² and Laura Fugazzola¹

¹Department of Medical Sciences and Endocrine Unit, University of Milan and Fondazione Policlinico Istituto Di Ricovero e Cura a Carattere Scientifico, ²Department of Biology and Genetics for Medical Sciences, University of Milan and Laboratory of Medical Cytogenetics and Molecular Genetics, Istituto Auxologico Italiano Istituto Di Ricovero e Cura a Carattere Scientifico, ³Pathology Unit, Department of Medicine, Surgery and Dentistry, University of Milan, Ospedale S. Paolo and Fondazione Policlinico Istituto Di Ricovero e Cura a Carattere Scientifico, and ⁴Endocrine Surgery Unit, Fondazione Policlinico Istituto Di Ricovero e Cura a Carattere Scientifico, Milan Italy

Abstract

Fetal cells enter the maternal circulation during pregnancy and can persist in the maternal blood or tissues for decades, creating a physiologic microchimerism. Because papillary thyroid cancer (PTC) is more frequent in women, the role of persisting fetal male cells in this tumor has been investigated. Tumor tissue specimens were obtained from 63 women with PTC who had a male pregnancy before the diagnosis. Male cells, identified by PCR amplification of a male-specific gene, the sex-determining region Y, was detected in 47.5% of women. By fluorescence *in situ* hybridization (FISH) analyses, the total number of microchimeric cells was significantly higher in neoplastic tissue than in controlateral normal sections. By combined FISH and immunohistochemistry (immuno-FISH), male cells expressing thyroglobulin were found in tumor and normal tissues, whereas male microchimeric cells stained with the CD45 antigen were detected only in tumor sections. Microchimeric cells negative for either marker were detected both in tumor and normal tissues. Moreover, both CD45⁺ and Tg⁺ fetal cells did not express MHC II antigens. In conclusion, fetal microchimerism has been documented in a high proportion of women with PTC. The immuno-FISH studies indicate that CD45⁺/MHC II⁻ male cells found in neoplastic tissues might be committed to destroy tumor cells, whereas Tg⁺/MHC II⁻ cells could have a repair function. Finally, microchimeric cells negative for either CD45 or Tg could have “progenitor-like” properties able to transdifferentiate in different cellular types. Although a pathogenetic mechanism cannot be excluded, the whole of the present results indicates a protective role of microchimerism in thyroid cancer. [Cancer Res 2008;68(20):8482–8]

Introduction

Fetal cell microchimerism (FCM) is defined as the persistence of fetal cells in maternal organs and circulation without any apparent graft-versus-host reaction or graft rejection (1, 2). It can take place during pregnancy, when a bidirectional trafficking of cells has been observed starting from the 4th to 6th week of gestation (3). A wide

variety of fetal cells have been detected in maternal blood, including trophoblasts, hematopoietic stem cells and CD34⁺CD38⁺ cells, mesenchymal stem cells, nucleated erythroblasts, T and B lymphocytes, monocytes, and natural killer (NK) cells (4). FCM have been hypothesized to be involved in chronic inflammatory responses leading to tissue damage (“bad microchimerism”) or to participate in the repair of damaged tissue and in the resistance to infections (“good microchimerism”), although it cannot be excluded that it might not have any biological significance (“neutral microchimerism”; ref. 5). The commonest approach to detect foreign cells has been the assay of male-specific gene markers in females with a previous male pregnancy, by PCR amplification of the sex-determining region Y (SRY; refs. 6, 7) or by Fluorescence *in situ* hybridization (FISH) with labeling of X- and Y-chromosomes (8). FCM was first documented in autoimmune diseases, such as systemic sclerosis, primary biliary cirrhosis, Sjögren’s syndrome or erythematosus systemic lupus, type 1 diabetes mellitus, Hashimoto’s thyroiditis, Graves’ disease, and has been hypothesized by several authors to be implicated in the pathogenesis (6, 7, 9–15). Differently, the role of microchimeric cells in nonautoimmune disorders, such as hepatitis C, thyroid adenoma and multinodular goitre, and cervical and breast cancer is still controversial (8, 16–18). In this context, it has been speculated that the presence of these foreign cells in tissues might be the consequence rather than the cause of disease, and that they might provide a source of progenitor cells, participating in maternal tissue repair processes (17, 19), as suggested by the finding of male cells forming a thyroid follicle in a woman with multinodular goiter (8). Finally, it has been recently suggested that FCM might contribute to reduce the risk to develop breast cancer (18).

In the present study, the role of microchimerism in papillary thyroid cancer (PTC) was investigated. A possible involvement of this phenomenon might be indeed hypothesized because this tumor is two to four times more prevalent in females. Molecular and cytogenetic analyses were performed to recognize fetal male cells in neoplastic and normal tissues from 63 women with PTC. Furthermore, to determine the phenotype of male cells, combined FISH and immunohistochemistry (immuno-FISH) studies were performed using common leukocyte antigen CD45 as a leukocyte marker, and thyroglobulin as a follicular thyroid cells marker. Finally, to obtain more insights into the understanding of the role of microchimeric cells, MHC II expression has been evaluated.

Materials and Methods

Thyroid tissue samples. Tumor tissue fresh-frozen specimens were obtained from 63 women who underwent thyroidectomy for PTC. They

Note: Supplementary data for this article are available at Cancer Research Online (<http://cancerres.aacrjournals.org/>).

Requests for reprints: Laura Fugazzola, Endocrine Unit, Pad. Granelli, Fondazione Policlinico Istituto Di Ricovero e Cura a Carattere Scientifico, Via F. Sforza, 35, 20122 Milan, Italy. Phone: 39-02-55033498; Fax: 39-02-50320605; E-mail: Lfugazzola@policlinico.mi.it.

©2008 American Association for Cancer Research.
doi:10.1158/0008-5472.CAN-08-0672

were divided into 2 groups: group 1 ($n = 40$) included women who had at least 1 male pregnancy before the diagnosis of PTC and group 2 ($n = 23$) that included women who had only female offspring or were nulliparous. The latter group was used as negative control, whereas DNAs obtained from the tumor thyroid tissue or blood samples of 10 men were used as positive controls. No patients or negative controls had history of other potential sources of microchimerism (i.e., blood transfusion, organ transplantation, or twin sibling). Moreover, none of the women from the negative control group had history of abortion.

DNA extraction from frozen tissue and from whole blood. Tissue DNA was extracted, by standard methods, from frozen thyroid tumors corresponding to the 63 women enrolled. In 20 of 40 patients of group 1, tissue DNA was also obtained from frozen normal thyroid samples contralateral to the tumor. As positive control, tissue DNA was extracted from frozen normal thyroid tissues corresponding to six men. Paraffin-embedded tissues have not been used to avoid differences in DNA yield and quality and thus in PCR sensitivity.

Genomic DNA was extracted, by standard methods, from whole blood of four men, who were used as positive controls. Female technicians handled all tissue samples.

PCR for Y-chromosome SRY sequence. For the detection of the human Y-chromosome, specific primers for the SRY locus corresponding to areas upstream of the SRY-coding region and adequate PCR conditions were used (6, 7). All PCR analysis contained two negative and two positive controls and were prepared taking special caution to avoid external contamination. In particular, all samples were handled by females, positive micropipettes

were used, and DNA extraction, PCR preparation, and PCR analysis were conducted in separate rooms. Moreover, all results have been confirmed twice.

FISH. FISH analyses were performed (patients #1, 3, 5, and 7) on 5- μ m thick paraffin-embedded tissue sections as previously described (20, 21). After revision of all the slides by the pathologist (S.R.), a total of two to six sections from each patient were scanned. The DNA probes used were specific for the α -satellite regions of the X (BAC probe pDMX1, locus DXZ1) and Y (band region Yp11.1-q11.1, locus DYZ3) chromosomes. The X probe was labeled with digoxigenin and detected using FITC-conjugated antibody antidigoxigenin (green signal; Roche), whereas the Y was labeled with a SpectrumOrange fluorochrome (Vysis) and detected as red signal.

Immuno-FISH. To immunophenotype fetal male cells, a FISH and immunohistochemistry combined method was used (22, 23). Tissues sections were first subjected to two-color immunohistochemistry with anti-CD45 (mouse monoclonal antibody; Dako) and anti-Tg (polyclonal rabbit antibody, Biogenex Laboratories, Inc.) antibodies. Secondary antibodies and peroxidase and phosphatase-alkaline enzymes conjugated to polymers (Picture Plus Double Staining kit; Zymed Laboratories, Inc.; Invitrogen) were used and developed with substrates 3,3'-diaminobenzidine (DAB; brown precipitate) and Fast Red (visible as red fluorescence or red precipitate). Subsequently, the same sections were probed for X- and Y-chromosomes and counterstained with 4',6-diamidino-2-phenylindole.

To study MHC class II expression in CD45⁺ and Tg⁺ fetal cells, male cells were identified by FISH analysis and electronic coordinates were taken. Anti-CD45 antibody was used together with a secondary antibody

Table 1. Patients with FCM: clinical, histologic, and genetic features

No./age at diagnosis (y)	Interval between delivery of last male and diagnosis (y)	pTNM/outcome	FCM in nontumoral tissue
1*/65	35	pT1mN0 ^{†,‡} /R	Yes
2/69	40	pT3N0 ^{†,§} /R	N.a.
3 /42	13	pT1mN0 ^{†,‡} /R	Yes
4*/49	30	pT1mN0 ^{†,¶} /R	No
5*/68	42	pT3mN1b ^{†,‡} /R	No
6/41	7	pT2N0 ^{§,**}	N.a.
7/34	2	pT3mN1b/P	Yes
8/62	36	pT3N1a ^{†,§} /P	No
9 ^{††} /58	29	PT1N0 ^{**¶} /n.a.	Yes
10/27	5	pT3N1b ^{†,‡} /R	N.a.
11/45	12	pT3N1b ^{†,¶} /R	N.a.
12/72	46	pT3mN0 ^{†,¶} /R	N.a.
13*/63	30	pT3N0 ^{†,‡} /R	N.a.
14/43	15	pT3N1a ^{†,¶} /P	Yes
15/49	24	pT3mN1 ^{†,‡} /R	No
16 ^{††} /66	36	pT4mN1b ^{†,¶,**} /R	No
17*/57	35	pT3N0 ^{†,¶} /R	N.a.
18/72	40	PT3N0 ^{†,§} /n.a.	No
19/62	28	pT3N0 ^{†,¶} /R	N.a.

NOTE: BRAF V600E mutation and RET rearrangements (*ret*/PTC1, 2, and 3) have been analyzed starting from tissue DNA and RNA, as previously described (26, 27). In all these cases, male cells were detected by PCR in the neoplastic tissue. The results obtained in the normal contralateral thyroid tissue, whenever available, are also reported.

* Associated nontoxic goiter.

† Classic variant.

‡ BRAF mutation.

§ *ret*/PTC rearrangement.

|| Associated resistance to thyroid hormones.

¶ no BRAF or *ret*/PTC mutations; P, persistence of disease; R, remission of disease; n.a., not available.

** Follicular variant.

†† Associated lymphocytic thyroiditis at histology.

Table 2. Number of microchimeric male cells identified in tumor and normal thyroid tissue and estimated total number of cells analyzed by FISH

No./tissue	Total number of FMC (number of FMC per section)	Estimated total number of cells examined	FMC per million total cells
1/tumor	14 (2.8)	1,690,000	8.3
1/normal	6 (1.5)	1,960,000	3.0
3/tumor	11 (1.8)	2,110,000	5.2
3/normal	3 (1)	1,540,000	1.9
5/tumor	39 (7.8)	1,900,000	20.5
5/normal	0	280,000	0
7/tumor	18 (4.5)	1,760,000	10.2
7/normal	4 (0.8)	1,830,000	2.2

NOTE: The number of microchimeric male cells/million total cells examined was significantly higher in neoplastic thyroid tissue than in normal sections ($P = 0.02$, by Mann-Whitney rank sum test).

antimouse phosphatase-alkaline conjugated (mouse IgG antibody preadsorbed; GeneTex) and developed with Fast Red, whereas for Tg staining, the same method described above was used. In both cases, antibodies were detached and samples stained with MHC II antibody (MHC DR+DP+DQ; monoclonal mouse; GeneTex). Secondary antibody and peroxidase enzyme conjugated to polymer were used and developed with DAB substrate.

Scoring and statistical analyses. Sections were blindly scanned by three separate experts (V.C., M.P.R., and P.F.) for the presence of male cells. Sections were considered only if the loss of cells from the section of tissue during the hybridization procedure was minimal and if >70% of the nuclei had at least one X (green) and one Y (red) signal within a clearly defined nucleus.

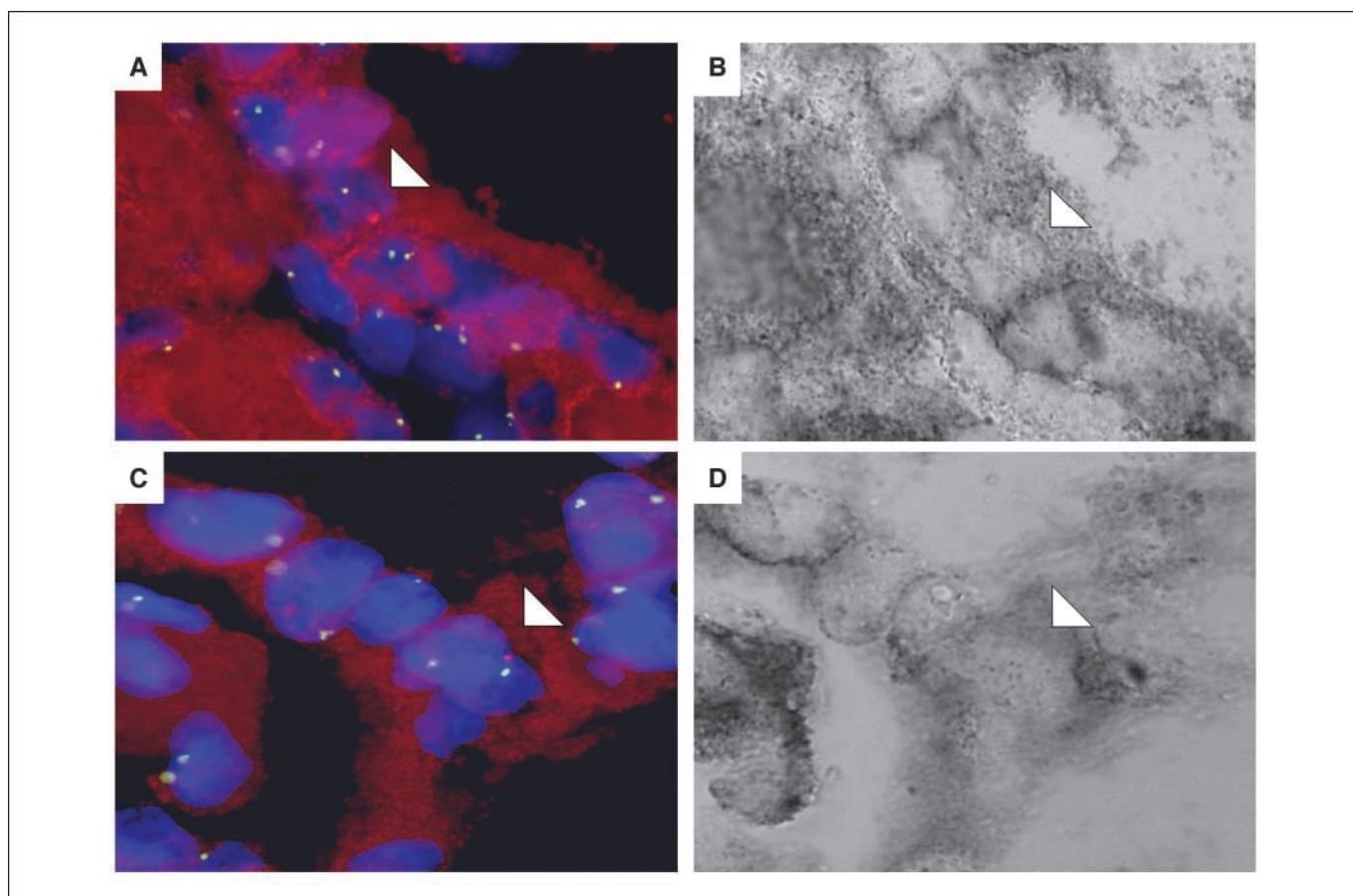


Figure 1. Immuno-FISH experiments using two-color immunohistochemistry (anti-Tg and anti-CD45 antibodies) and FISH (probes specific for X- and Y-chromosomes). A and C, papillary thyroid tumor section at fluorescence microscopy. Arrows, male cells (Y-chromosome in red and X-chromosome in green) surrounded by female cells. The thyroglobulin expression is indicated by the red staining within the cytoplasm (magnification, $\times 100$). B and D, the same male cells visualized by light microscopy (arrows). Thyroglobulin precipitates are visible as dark staining within the cytoplasm. Note that male cells positive for Tg are interposed between maternal follicular cells to form a thyroid follicle.

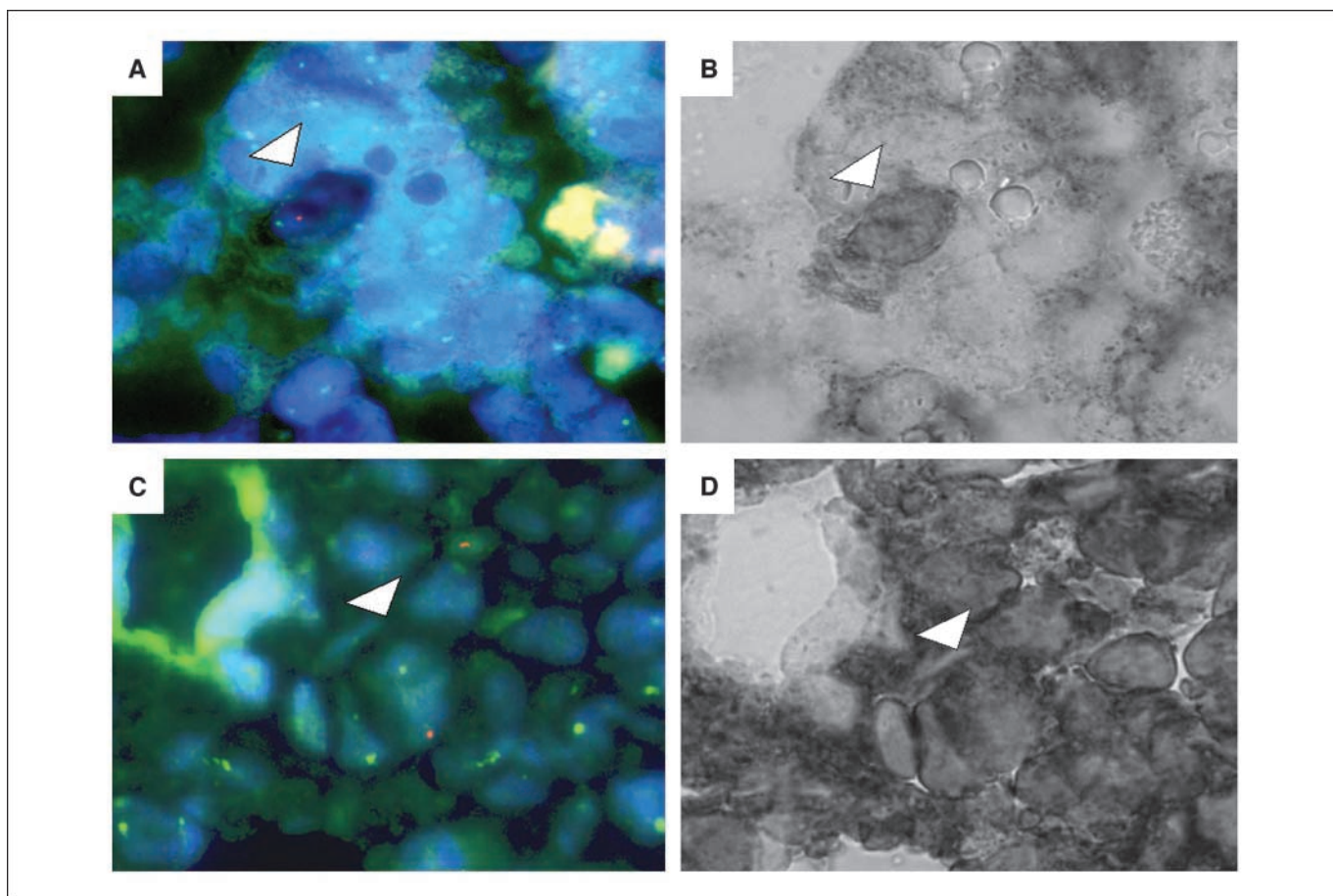


Figure 2. Immuno-FISH experiments using two-color immunohistochemistry (anti-Tg and anti-CD45 antibodies) and FISH (probes specific for X- and Y-chromosomes). *A* and *C*, papillary thyroid tumor section at fluorescence microscopy. *Arrows*, male cells (Y-chromosome in red and X-chromosome in green) surrounded by female cells (magnification, $\times 100$). *B* and *D*, the same male cells visualized by light microscopy (*arrows*). The darker staining on cell surface surrounding the male nucleus indicates CD45 expression, consistent with a leukocyte phenotype.

Within each section, the total number of microchimeric cells was estimated and a standardization per number of cells counted was done. In particular, the number of nuclei in three fields (1 mm^2 each) was counted separately and the total number of nuclei was obtained by multiplying the mean nuclei count/ mm^2 with the number of mm^2 of each section. The area of the tissue analyzed was calculated with the Image J program (Wayne Rasband; NIH)⁵ Finally, the frequency of microchimeric cells/million total cells was calculated. Comparisons between the absolute number of male cells, and between Tg^+ , CD45^+ , and $\text{Tg}/\text{CD45}$ -negative male cells, in normal and tumor tissues, were done by means of Mann-Whitney rank-sum test and χ^2 test. The difference between values was considered significant when *P* value is <0.05 .

Results

Identification of male DNA in tumor and normal thyroid tissues. The presence of male DNA was detected in the tumor tissue of 19 of 40 women with PTC who had at least one male pregnancy before the diagnosis of tumor (group 1), whereas it was absent in tumor thyroid tissue from 23 patients with only female offspring or nulliparous (group 2; Supplementary data). In 20 of 40 women of group 1, the normal tissue contralateral to the PTC was

also analyzed and male DNA was found only in 5 cases, who were positive also at the tumor level (Table 1). Interestingly, in patients positive for the presence of FCM, the delivery of male occurred up to 46 years before thyroidectomy. It is worth to note that only 2 of 19 tumors positive for FCM had an associated autoimmune thyroiditis at histology. No significant differences in the age at diagnosis, in the pathologic stage (tumor-node-metastasis classification, American Joint Committee on Cancer 6th edition; ref. 24), in the outcome, and in the genetic alteration (BRaf V600E mutation or *ret*/PTC rearrangements) were found between patients positive or negative for the presence of microchimerism.

Identification of male microchimeric cells in tumor and normal thyroid tissues. To further characterize the data obtained by PCR, a FISH was performed on paraffin-embedded neoplastic and normal tissues from women who were positive for the presence of SRY sequence. Due to the high number of cells to examine in each section (up to 2,000,000 per sample; Table 2), 4 exemplificative cases were selected based only on the availability of sufficient quantity of paraffin-embedded tissues. The presence of one chromosome Y (red signal) and one X chromosome (green signal) in the nuclei identified male cells. Microchimeric cells were detected in all cases, as single cells or in cluster. The number of microchimeric cells ranged 1.8 to 7.8 per section in tumors and 0 to 1.5 per section in normal samples (Table 2). The number of

⁵ <http://rsb.info.nih.gov>

microchimeric male cells per million total cells examined was significantly higher in neoplastic thyroid tissue than in normal sections ($P = 0.02$, by Mann-Whitney rank sum test).

Phenotype of male microchimeric cells in neoplastic and normal tissues. To characterize the phenotype of male cells in PTCs and normal contralateral tissues, immunohistochemistry with antibodies against the hematopoietic marker CD45 and against the thyrocyte marker Tg and FISH for X- and Y-chromosome were simultaneously performed (Figs. 1 and 2). Male cells expressing Tg were found both in tumor and normal thyroid tissues (66% versus 49%), whereas male microchimeric cells stained with CD45 were detected in a lower number and only in neoplastic tissue sections (13% versus 0%). Microchimeric cells negative for either marker were detected both in tumor and normal tissues, but they were significantly more frequent in normal tissue (51% versus 21%; Table 3). The immunophenotypic characterization resulted significantly different between tumoral and normal tissue ($P < 0.0001$, χ^2 test). No cells positive for both markers were found. Interestingly, in some sections, Tg⁺ male cells were interposed between maternal follicular cells forming a thyroid follicle (Fig. 1). Either CD45⁺ or Tg⁺ fetal cells did not express MHC II antigens (Fig. 3). On the contrary, a MHC II staining was observed at the

plasma membrane level in female leukocytic cells, and at the cytoplasmatic and membrane level in female thyrocytes (Fig. 3).

Discussion

The present study shows the presence of FCM, resulting from feto-maternal cell trafficking, in PTC. Male SRY sequences were identified in the tumor tissue of 19 of 40 (47.5%) women with PTC who had at least 1 male pregnancy and in normal contralateral thyroid tissue, whereas it was always absent in tumor tissue from patients with only female offspring or nulliparous. Because FCM has been shown in 40% to 50% of Hashimoto's and Graves' tissues (6, 15), it is worth to note that in the present series, only 2 of 19 PTC positive for FCM were associated with thyroiditis. At variance, the previously reported thyroid cancer cases with FCM were all associated with thyroiditis (8), which might be a possible confounding element especially because male cells were not immunophenotyped.

The number of microchimeric cells has been found to be independent on the number of male pregnancies and on the interval between pregnancy and disease, confirming that fetal cells are present in the maternal blood for decades after delivery (1, 2).

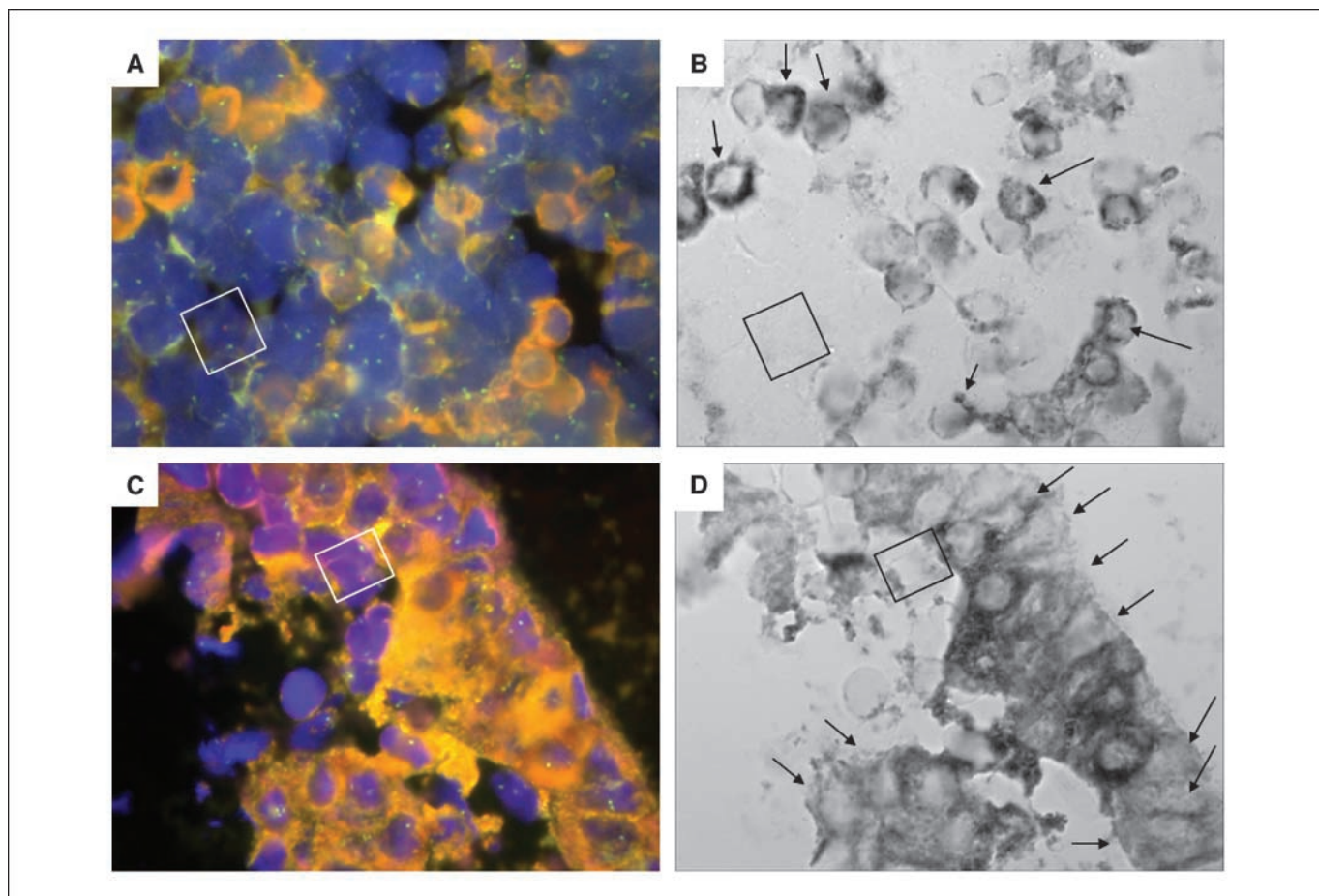


Figure 3. Immuno-FISH experiments by anti-MHC II staining and FISH (probes specific for X- and Y-chromosomes). Cells were immunocharacterized in previous experiments, classified as CD45⁺ or Tg⁺ and localized by electronic coordinates. *A*, papillary thyroid tumor section at fluorescence microscopy. A male cell (Y-chromosome in red and X-chromosome in green), previously characterized as CD45⁺ (square) is surrounded by CD45⁺ female cells. *B*, the same male cell visualized by light microscopy is negative for MHC II expression. Differently, MHC II is positive (dark staining on cell membrane; magnification, $\times 100$) in several surrounding female cells (arrows). *C*, papillary thyroid tumor section at fluorescence microscopy. A male cell, previously characterized as Tg⁺ and forming part of a papilla (square) is surrounded by Tg⁺ female cells. *D*, the same male cell visualized by light microscopy is negative for MHC II expression. In contrast, a weak MHC II staining was found (dark staining on thyrocytes membrane and cytoplasm; magnification, $\times 100$) in several surrounding cells (arrows).

Table 3. Phenotype of microchimeric male cells obtained by immuno-FISH experiments

Immuno-phenotype	% of FMC in total tumor tissue	% of FMC in total normal tissue
Tg ⁺	13	25
Tg ⁺	5	10
Tg ⁺	30	0
Tg ⁺	18	14
Tg ⁺ total	66	49
CD45 ⁺	6	0
CD45 ⁺	4	0
CD45 ⁺	0	0
CD45 ⁺	3	0
CD45 ⁺ total	13	0
Tg ⁻ CD45 ⁻	7	25
Tg ⁻ CD45 ⁻	4	13
Tg ⁻ CD45 ⁻	6	0
Tg ⁻ CD45 ⁻	4	15
Tg ⁻ CD45 ⁻ total	21	51

NOTE: Data relative to each patient and the pooled results are reported. The immunophenotypic characterization was significantly different between tumor and normal tissue ($P < 0.0001$, by χ^2 test).

FISH analyses confirmed and extended PCR data, allowing to quantify the number of fetal cells and demonstrating that they were significantly more represented in tumors than in normal tissue contralateral to PTC, likely excluding the possible role of male cells as innocent bystanders. These data are in accordance with previous data on cervical cancer showing that fetal cells positive for CD45 and for cytokeratin were significantly more abundant in the neoplastic tissue with respect to the adjacent normal tissue, suggesting a role in the repairing process (17). In the present study, male cells stained with the leukocyte marker CD45 were found at a low frequency (13% of microchimeric cells) and only in tumor tissue sections. Differently, microchimeric cells expressing Tg were detected both in tumor and normal thyroid tissues (66% and 49%, respectively). Interestingly, both CD45 and Tg-positive male cells were found to be negative for MHC II expression. On the contrary, several female cells either CD45⁺ or Tg⁺ expressed MHC II antigen, consistent with a role as antigen-presenting cells. Indeed, tumoral follicular cells, but not normal thyroid cells, have been shown to harbor the aberrant expression of MHC II antigen, which is believed to be triggered by oncogenes, such as ret/PTC, and to have an immunomodulatory function (25). Thus, the lack of MHC II expression in Tg⁺ male cells argues against a transformed phenotype and a role as antigen-presenting cells, supporting instead a possible function in the replacement of damaged cells and repair of the thyroid tissue. A role as antigen-presenting cells can be also excluded for CD45⁺ male cells, which

were negative for MHC II expression, suggesting that they could be referred as macrophage or NK cells, likely committed to destroy tumor cells.

Male cells negative for the differentiation markers CD45 and Tg were found both in neoplastic and normal tissues (21% and 51%, respectively). As hypothesized for other diseases (22), these "negative" microchimeric cells could be thyrocytes precursors, fibroblast, or stem-like cells migrated to the thyroid and able to differentiate in hematopoietic or epithelial cells. This is in agreement with the idea that during pregnancy, women could acquire pregnancy-associated progenitor cells with the capacity for multilineage differentiation in diseased or injured maternal tissue (2, 19, 23). Nevertheless, it should be considered that these cells could not be involved in host tissue repair, but they could have a role in carcinogenesis, for example, inducing an immune system alteration or making the thyroid tissue more susceptible to detrimental genetic or environmental factors.

This is the first report demonstrating FCM in normal thyroid tissue. Indeed, normal thyroids have been previously found to be negative for FCM (6, 8). This discrepancy could be due to the different origin of normal samples, from the thyroid tissue contralateral to a neoplastic lesion in the present, and from autoptic normal glands in the other studies. This finding further support the idea that, in the presence of a neoplastic process, microchimeric cells could migrate to the thyroid and participate in the repair process.

Nonetheless, FCM was not detected in tumor tissue from 21 of 40 (52.5%) women affected with PTC who had 1 male pregnancy, consistently with previous data (8). This could be the consequence of the incomplete analysis of surgical specimens or of the removal of fetal cells by the maternal immune system. It is also worth of mention that, at least in some of these patients, female fetal cells deriving from another pregnancy could have migrated to the maternal thyroid gland.

In conclusion, the present study shows the presence of FCM in a high proportion of women with PTC. The immuno-FISH studies indicate that CD45⁺/MHC II⁻ male cells found in the neoplastic tissues might be committed to eliminate tumor cells, whereas Tg⁺/MHC II⁻ cells could have a repair function. Finally, microchimeric cells negative either for CD45 or Tg could have "progenitor-like" properties able to differentiate in hematopoietic or epithelial cells. Although a pathogenetic mechanism cannot be excluded, the whole of the present results indicates a protective role of microchimerism in thyroid cancer.

Disclosure of Potential Conflicts of Interest

No potential conflicts of interest were disclosed.

Acknowledgments

Received 2/22/2008; revised 7/9/2008; accepted 8/11/2008.

The costs of publication of this article were defrayed in part by the payment of page charges. This article must therefore be hereby marked *advertisement* in accordance with 18 U.S.C. Section 1734 solely to indicate this fact.

We thank Mariano Rocchi who provided the BAC probe pDMX1, locus DXZ1.

References

- Bianchi DW, Zickwolf GK, Weil GJ, Sylvester S, DeMaria MA. Male fetal progenitor cells persist in maternal blood for as long as 27 years postpartum. *Proc Natl Acad Sci U S A* 1996;93:705-8.
- O'Donoghue K, Chan J, de la Fuente J, et al. Microchimerism in female bone marrow and bone
- Ariga H, Ohto H, Busch MP, et al. Kinetics of fetal cellular and cell-free DNA in the maternal circulation

- during and after pregnancy: implications for non-invasive prenatal diagnosis. *Transfusion* 2001;41:1524–30.
4. Lambert NC, Lo YM, Erickson TD, et al. Male microchimerism in healthy women and women with scleroderma: cells or circulating DNA? A quantitative answer. *Blood* 2002;100:2845–51.
 5. Nelson JL. Microchimerism: expanding new horizon in human health or incidental remnant of pregnancy? *Lancet* 2001;358:2011–2.
 6. Klitschar M, Schwaiger P, Mannweiler S, Regauer S, Kleiber M. Evidence of fetal microchimerism in Hashimoto's thyroiditis. *J Clin Endocrinol Metab* 2001;86:2494–8.
 7. Ando T, Imaizumi M, Graves PN, Unger P, Davies TF. Intrathyroidal fetal microchimerism in Graves' Disease. *J Clin Endocrinol Metab* 2002;87:3315–20.
 8. Srivatsa B, Srivatsa S, Johnson KL, Samura O, Lee SL, Bianchi DW. Microchimerism of presumed fetal origin in thyroid specimens from women: a case-control study. *Lancet* 2001;358:2034–8.
 9. Arlett CM, Smith JB, Jimenez SA. Identification of fetal DNA and cells in skin lesions from women with systemic sclerosis. *N Engl J Med* 1998;338:1186–91.
 10. Corpechot C, Barbu V, Chazouilleres O, Poupon RE, Poupon R. Fetal microchimerism in primary biliary cirrhosis. *J Hepatol* 2000;33:696–700.
 11. Johnson KL, McAlindon TE, Mulcahy E, Bianchi DW. Microchimerism in a female patient with systemic lupus erythematosus. *Arthritis Rheum* 2001;44:2107–11.
 12. Endo Y, Negishi I, Ishikawa O. Possible contribution of microchimerism to the pathogenesis of Sjogren's syndrome. *Rheumatol Oxford* 2002;41:490–5.
 13. Nelson JL, Gillespie KM, Lambert NC, et al. Maternal microchimerism in peripheral blood in type 1 diabetes and pancreatic islet β cell microchimerism. *Proc Natl Acad Sci U S A* 2007;104:1637–42.
 14. Badenhop K. Intrathyroidal microchimerism in Graves' disease or Hashimoto's thyroiditis: regulation of tolerance or alloimmunity by fetal-maternal immune interactions? *Eur J Endocrinol* 2004;150:421–3.
 15. Renné C, Ramos Lopez E, Steimle-Grauer SA, et al. Thyroid fetal male microchimerism in mothers with thyroid disorders: presence of Y-chromosomal immunofluorescence in thyroid-infiltrating lymphocytes is more prevalent in Hashimoto's thyroiditis and Graves' disease than in follicular adenomas. *J Clin Endocrinol Metab* 2004;89:5810–4.
 16. Johnson KL, Samura O, Nelson JL, McDonnell WM, Bianchi DW. Significant fetal cell microchimerism in a nontransfused woman with hepatitis C: evidence of long-term survival and expansion. *Hepatology* 2002;36:1295–7.
 17. Cha D, Khosrotehrani K, Kim Y, Stroh H, Bianchi DW, Johnson KL. Cervical cancer and microchimerism. *Am College Obstetric Gynaecol* 2003;102:774–81.
 18. Gadi VK, Nelson GL. Fetal microchimerism in women with breast cancer. *Cancer Res* 2007;67:9035–8.
 19. Bianchi DW. Fetomaternal cell trafficking: a story that begins with prenatal diagnosis and may end with stem cell therapy. *J Pediatr Surg* 2007;42:12–8.
 20. Johnson KL, Zhen DK, Bianchi DW. The use of fluorescence in situ hybridization (FISH) on paraffin-embedded tissue sections for the study of microchimerism. *Biotechniques* 2000;29:1220–4.
 21. Ronchetti D, Finelli P, Richelda et al. Molecular analysis of 11q13 breakpoints in multiple myeloma. *Blood* 1999;93:1330–7.
 22. Stevens AM, Hermes H, Rutledge J, Buyon J, Nelson JL. Myocardial-tissue-specific phenotype of maternal microchimerism in neonatal lupus congenital heart block. *Lancet* 2003;362:1617–23.
 23. Khosrotehrani K, Stroh H, Bianchi DW, Johnson KL. Combined FISH and immunolabelling on paraffin-embedded tissue sections for the study of microchimerism. *Biotechniques* 2003;34:242–4.
 24. American Joint Committee on Cancer TNM classification of malignant tumours. In: Greene FL, editor. *AJCC Cancer Staging Handbook*. New York: Springer-Verlag; 2002. p. 89–98.
 25. Jo YS, Lee JC, Li S, et al. Significance of the expression of major histocompatibility complex class II antigen, HLA-DR and -DQ, with recurrence of papillary thyroid cancer. *Int J Cancer* 2007;122:785–90.
 26. Fugazzola L, Puxeddu E, Avenia N, et al. Correlation between *B-RAF*^{V600E} mutation and clinico-pathologic parameters in papillary thyroid carcinoma: data from a multicentric Italian study and revision of the literature. *Endocr Relat Cancer* 2006;13:455–64.
 27. Thomas GA, Bunnell H, Cook HA, et al. High prevalence of ret/PTC rearrangements in Ukrainian and Belarussian post-Chernobyl thyroid papillary carcinomas: a strong correlation between ret/PTC3 and the solid-follicular variant. *J Clin Endocrinol Metab* 1999;84:4232–8.