

Telomere Maintenance Mechanisms in Liposarcomas: Association with Histologic Subtypes and Disease Progression

Aurora Costa,¹ Maria Grazia Daidone,¹ Laura Daprai,¹ Raffaella Villa,¹ Sabrina Cantù,¹ Silvana Pilotti,² Luigi Mariani,³ Alessandro Gronchi,⁴ Jeremy D. Henson,⁵ Roger R. Reddel,⁵ and Nadia Zaffaroni¹

Departments of ¹Experimental Oncology and Laboratories, ²Pathology, ³Biostatistics, and ⁴Surgery, Istituto Nazionale per lo Studio e la Cura dei Tumori, Milano, Italy and ⁵Children's Medical Research Institute, Westmead, Sydney, Australia

Abstract

Human cancer cells maintain telomeres by telomerase activity (TA) or by alternative lengthening of telomeres (ALT). We proposed to define the prevalence of the two telomere maintenance mechanisms (TMM), to assess their association with histology, and to compare their prognostic relevance in a series of 93 patients with liposarcoma. ALT was detected by assaying ALT-associated promyelocytic leukemia nuclear bodies and TA was assayed using the telomeric repeat amplification protocol. ALT or TA was found in 25.9% or 26.6% of 139 tested liposarcoma lesions, respectively. Three lesions were ALT+/TA+ whereas ~50% of lesions did not show any known TMM. TMM phenotype was consistent during disease progression. ALT was prevalent in dedifferentiated and in grade 3 liposarcomas whereas TA prevailed in most round-cell myxoid and in grade 2 liposarcomas. ALT and TA incidence was similar in primary and recurrent lesions whereas metastases were more frequently TA+ than ALT+ (59% versus 18%; $P = 0.04$). TMM presence negatively affected patient prognosis ($P = 0.001$): increased mortality was associated with positivity for TA ($P = 0.038$) or ALT ($P < 0.0001$) compared with TMM absence. ALT proved to be a stronger prognostic discriminant of increased mortality than TA even when adjusted for tumor location, grade, and histology (hazard ratio for cause-specific death, 3.58 versus 1.15). Our results indicate that ALT can support fully malignant liposarcomas and is associated with unfavorable disease outcome. (Cancer Res 2006; 66(17): 8918-24)

Introduction

In normal somatic cells, proliferation is accompanied by telomere shortening (1), due, at least in part, to the inability of the DNA replication machinery to completely replicate linear DNA. Shortening of telomeres with each round of cell division has been proposed to be the basis of a counting mechanism for regulating cellular senescence (2). A hallmark of cancer cells is their unlimited proliferative potential that can be achieved through the activation of a telomere maintenance mechanism (TMM). In ~85% of tumors, proliferation-dependent telomere shortening is counterbalanced by *de novo* synthesis of telomeric DNA catalyzed by telomerase (3). Some tumors, however, do not have telomerase

activity (TA) and maintain their telomeres by one or more mechanisms referred to as alternative lengthening of telomeres (ALT; ref. 4). Telomere dynamics in ALT cells are consistent with a recombination-based mechanism (5), and characteristics of ALT cells include unusually long and heterogeneous telomeres and subnuclear structures, termed ALT-associated promyelocytic leukemia bodies (APB), which contain telomeric DNA, telomere-specific binding proteins including terminal restriction fragment (TRF)-1 and TRF2, and proteins involved in DNA recombination and replication (6). Based on the limited information available thus far, it seems that ALT is more frequently present in tumors of mesenchymal origin, including osteosarcomas (7), soft-tissue sarcomas (8), and glioblastoma multiforme (9), than in those of epithelial origin, possibly because of a tighter repression of telomerase in normal mesenchymal than in epithelial cells (10).

An open question is whether telomerase and ALT may confer different properties on tumor cells *in vivo*. Evidence is accumulating that telomerase has cancer-promoting properties independent of its role in telomere maintenance (11), and although telomerase and ALT seem to be equivalent in their ability to support immortalization, their contribution to tumor growth and patient survival may differ. These findings indicate the importance of investigating the prognostic implications of TMMs in clinical tumors. In this context, the only available information relating ALT to patient prognosis has been obtained for brain tumors and sarcomas. The presence of ALT, assessed by telomere length or by APBs, was shown to correlate with prolonged survival in glioblastoma multiforme (9) whereas it did not affect clinical outcome in soft-tissue sarcomas overall and in malignant fibrous histiocytomas in particular (12). For osteosarcomas, the presence of ALT and/or TA was associated with a worse outcome than absence of any known TMM (7).

Liposarcomas are the largest single group of soft-tissue tumors and account for ~20% of all mesenchymal malignancies (13). They are heterogeneous as regards morphology and malignancy level and are classified into two groups according to karyotypic complexity (13), and a substantial fraction of cases utilizes ALT (12, 14). Taking advantage of a newly proposed assay for ALT in human tumors through detection of APBs (12) and of a large mono-institutional series of soft-tissue tumors from adult patients with long follow-up (15, 16), we investigated whether the expression of TMMs in liposarcomas might contribute to biological and clinical progression.

Materials and Methods

Study population. A total of 139 liposarcoma lesions from 93 adult patients treated with curative intent at the Istituto Nazionale Tumori of Milan from December 1986 to November 2003 were available for TMM

Requests for reprints: Nadia Zaffaroni, Unit #10, Department of Experimental Oncology and Laboratories, Istituto Nazionale Tumori, via Venezian 1, 20133 Milano, Italy. Phone: 39-02-2390-3260; Fax: 39-02-2390-3052; E-mail: nadia.zaffaroni@istitutotumori.mi.it.

©2006 American Association for Cancer Research.
doi:10.1158/0008-5472.CAN-06-0273

analysis (Fig. 1). These specimens were consecutive with respect to the availability of frozen tissue for the TMMs studies and of adequate clinicopathologic and follow-up information. Overall, 40 patients presented at Istituto Nazionale Tumori of Milan with primary disease (with the primary tumor available for TMM analyses in 19 cases) and 53 with recurrent locoregional tumors, and underwent different surgical procedures according to disease presentation. Median size of the primary tumor was 10 cm (interquartile range, 8-21 cm); 35 patients had deeply located tumors and the majority of patients (50) presented with grade 1 tumors. Patient and tumor characteristics are summarized in Table 1. Postoperative treatment was given when there were clinical grounds for concluding that a high risk of recurrence existed: 18 patients were submitted to radiotherapy, 8 to chemotherapy, and 4 to radio-chemotherapy according to the treatment protocols of the multidisciplinary Istituto Nazionale Tumori of Milan Soft Tissue Sarcoma Group. The median follow-up for the entire group, as of December 2004, was 92 months. During the follow-up period, 46 patients died (41 from liposarcoma-related causes).

This study was approved by Istituto Nazionale Tumori of Milan Institutional Review Board, and all patients provided written informed consent to donate to Istituto Nazionale Tumori of Milan the tissue that was left over after diagnostic procedures were completed.

Molecular studies. Tumor tissue was sampled by a pathologist at the time of surgery, flash frozen in liquid nitrogen, and stored at -80°C . On H&E-stained slides, diagnosis (according to the WHO Classification criteria of soft tissue tumors; ref. 17) and sampling adequacy were confirmed by the pathologist at the time of TMM analyses. For TMM analysis, a fragment of 70 to 100 mg was cut from each lesion and further subdivided into a long central portion and two ends. APBs were detected on frozen sections obtained from each end to control for intratumor clonal heterogeneity with

respect to TMM. Protein (for TA assay) and DNA (for telomere length assessment) were extracted from the central part of the sample.

Detection of APBs. Frozen sections were cut 5 to 7 μm thick, fixed in 1:1 methanol/acetone, and processed to detect APBs by combined promyelocytic leukemia immunofluorescence and telomere fluorescence *in situ* hybridization (FISH) according to Henson et al. (12). Images were captured on a Nikon Eclipse E600 fluorescence microscope with ACT-1 (Nikon, Tokyo, Japan) image analysis software and processed with Adobe Photoshop Image Reader 7.0 software.

APB status was determined according to previously defined criteria. The presence of an APB was defined by the localization of a telomeric DNA focus within a nuclear promyelocytic leukemia body; sections were scored as APB+ if they contained APBs in $\geq 0.5\%$ of tumor cells; and a tumor was considered ALT+ when at least one section was APB+. To avoid false positives, an APB was considered to be present only when the telomeric DNA fluorescence within a promyelocytic leukemia body was more intense than that of telomeres, and a cell was not considered to contain APBs if $>25\%$ of the colocalized foci occurred outside the nucleus. To avoid false negatives, at least 2,000 tumor nuclei were examined and the assay was repeated in the presence of negative results.

Tumor samples from ALT+ (IIICF/c-EJ-*ras*; ref. 6) or TA+ (HeLa) cell lines grown in nude mice were used as positive or negative controls for the APB assay.

Telomere length analysis. Total DNA was isolated with QuicKpicK genomic DNA kit (BioNobile, Medi Diagnostici, Milan, Italy), digested with *Hin*I restriction enzyme, electrophoresed using CHEF-DR II Pulsed Field system (Bio-Rad, Hercules, CA), transferred to a nylon membrane, and hybridized with a 5'-end [γ - ^{32}P]dATP-labeled telomeric oligonucleotide probe (TTAGGG) $_4$ as previously reported (18). Autoradiographs were

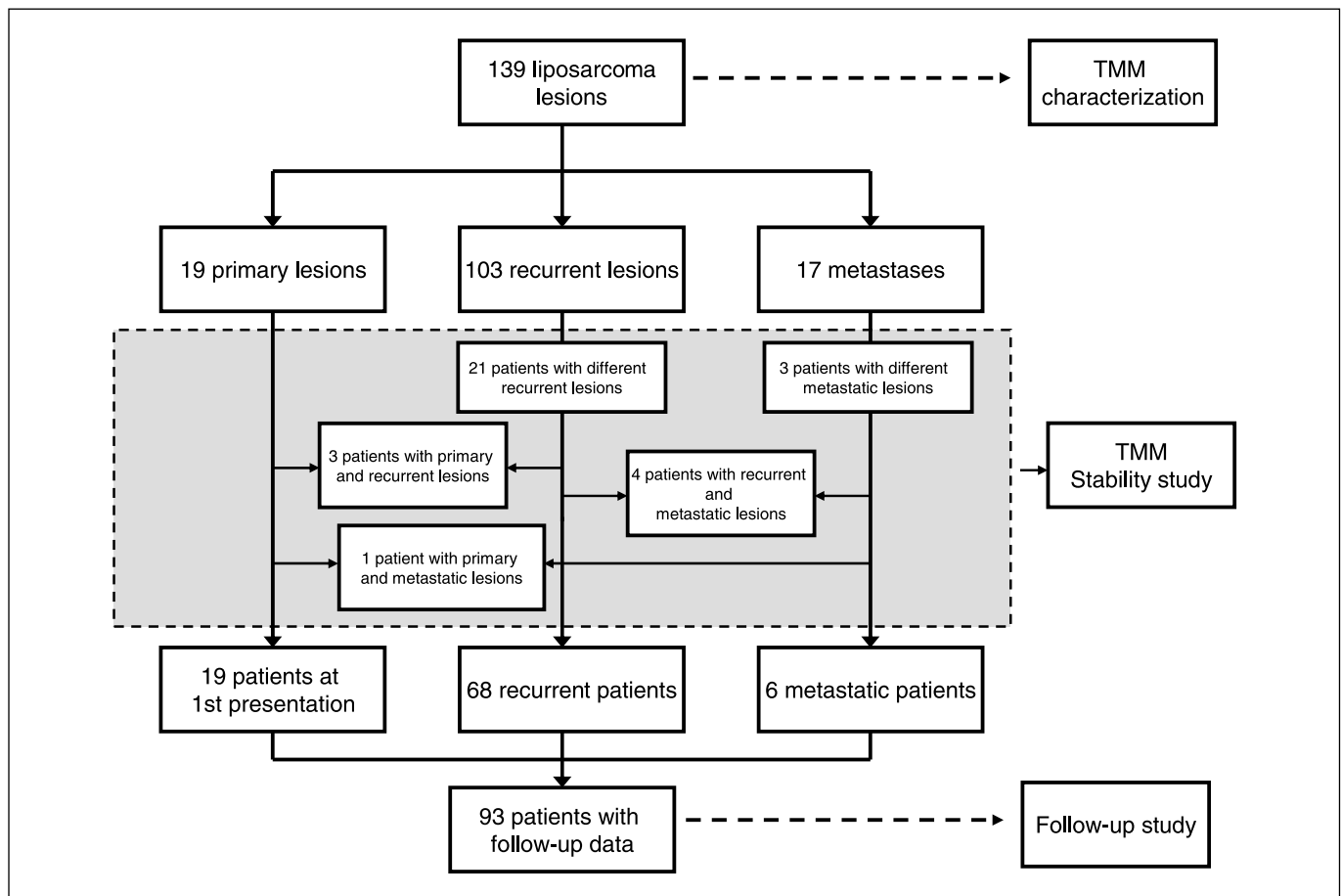


Figure 1. Flow diagram of the liposarcoma lesions analyzed for the different study end-points.

Table 1. Main patient and tumor characteristics

	Disease at presentation		
	Total	Primary	Recurrent
	No. patients (%)	No. patients (%)	No. patients (%)
Overall series	93 (100)	40 (100)	53 (100)
Age, years			
≤50	41 (44.1)	19 (47.5)	22 (41.5)
>50	52 (55.9)	21 (52.5)	31 (58.5)
Gender			
Female	39 (41.9)	18 (45.0)	21 (39.6)
Male	54 (58.1)	22 (55.0)	32 (60.4)
Site of the primary			
Extremity, trunk	58 (62.4)	28 (70.0)	30 (56.6)
Retroperitoneum	35 (37.6)	12 (30.0)	23 (43.4)
Histology			
Well differentiated	30 (32.3)	11 (27.5)	19 (35.8)
Dedifferentiated	22 (23.7)	10 (25.0)	12 (22.7)
Usual myxoid	16 (17.2)	8 (20.0)	8 (15.1)
Round-cell myxoid	18 (19.4)	10 (25.0)	8 (15.1)
Others	7 (7.4)	1 (2.5)	6 (11.3)
Grade			
1	50 (53.8)	22 (55.0)	28 (52.8)
2	27 (29.0)	12 (30.0)	15 (28.3)
3	16 (17.2)	6 (15.0)	10 (18.9)

scanned (ScanJet IICx/T; Hewlett Packard, Milan, Italy) and digitalized by Image Quant (Molecular Dynamics, Sunnyvale, CA). Each gel was standardized by inclusion of DNA from GM847 (ALT+) and HeLa (TA+) cell lines. ALT status was determined by calculating whether the mean, variance, and semi-interquartile range of the TRF length distribution were greater than 16 kb, 1,000 kb², and 4 kb, respectively. Tumors were classified as ALT+ when two or three of these criteria were met for unimodal or bimodal TRF length distributions, respectively. Statistical analysis of TRF length distributions was done with Telometric software (19). Each gel was standardized by inclusion of DNA from GM847 (ALT+) and HeLa (TA+) cell lines.

TA detection assay. TA was measured on 0.6 and 6 µg of protein by the telomeric-repeat amplification protocol (20) with the TRAPeze kit (Intergen Company, Oxford, United Kingdom). A tumor was scored as TA+ when positive telomeric-repeat amplification protocol results were obtained for at least one protein concentration. In the case of tumors negative at both protein concentrations, the telomeric-repeat amplification protocol assay was repeated to avoid false negatives.

Statistical analysis. TMM measurements were done by personnel blinded to patient data and clinical outcome (L.D., R.V., and S.C.) whereas clinical data were collected by personnel blinded to TMM results (A.C., A.G., and L.M.). Fisher's exact and χ^2 tests were used to assess the relationship between TMM status and clinical or pathologic features. The association between ALT and TA was assessed by Kendall's coefficient τ_b . The clinical end-point of this study was cause-specific mortality, and the time of its occurrence was computed from the date of first diagnosis to the time of death, or censored at the date of the last recorded follow-up for living patients or for those who died from liposarcoma-unrelated conditions. To avoid a possible time-length selection bias, a delayed-entry approach was adopted for patients who underwent surgery for recurrent locoregional disease: observation times for these patients were "left truncated" at the time of surgery (i.e., they were not considered among those at risk during the interval between diagnosis and curative surgery at Istituto Nazionale Tumori of Milan); however, their time 0 was left at the time of diagnosis. Survival analysis

was done with Cox regression models after checking for the proportional hazard assumption (21).

SAS software (SAS Institutes, Inc., Cary, NC) and S-Plus (StatSci, MathSoft, Seattle, WA) libraries were used for modeling and statistical calculations. All *P* values were two sided; *P* < 0.05 was considered to be statistically significant.

Results

We tested 139 frozen tumor samples obtained from 93 adult patients with liposarcoma for TA and ALT (Fig. 1). Overall, 36 (25.9%) lesions were defined as ALT+ on the basis of APBs being present (detected by colocalization of promyelocytic leukemia immunostaining and telomere FISH) in at least 0.5% of 2,000 tumor cells (Fig. 2A). APBs were observed in a variable percentage of cells in the ALT+ tumors, ranging from 0.5% to 51.4%, with a median value of 4.7%. Two separate sections of each tumor were assayed for APBs and the results indicated minimal intratumor spatial heterogeneity for ALT: we found one site to be APB+ and the other APB- in only 3 of 139 (2.2%) lesions. For 92 lesions, results of TRF analyses were also available (Fig. 2B) and we found concordance between APB and TRF results in 75 cases (81.5%; *P* = 3.5×10^{-5}).

Thirty-seven of 139 (26.6%) liposarcoma specimens were classified as TA+ based on positive telomeric-repeat amplification protocol results; among these, 3 lesions were defined as ALT+/TA+ due to the concomitant expression of APBs and TA. Interestingly, about half (69 of 139; 49.6%) of the lesions did not express any TMM. ALT and TA proved to be negatively associated [Kendall's coefficient τ_b = -0.24; 95% confidence interval (95% CI), -0.37 to -0.12; *P* = 0.0039]. A similar incidence of ALT and TA was found in primary and recurrent lesions (Table 2), with at least one TMM expressed in ~50% of the cases. The proportion increased to

76.4% in metastatic sites, which were more frequently TA+ than ALT+ (58.8 versus 17.6%; $P = 0.0438$).

TMM phenotype was stable in 26 of the 32 patients ($P = 2.5 \times 10^{-7}$) for whom ALT and TA assays were carried out in metachronous lesions (2-4 lesions from each patient, with 48 possible comparisons and 85% agreement over time; Fig. 1). In particular, of the seven patients whose liposarcomas were ALT+/TA- at first presentation, six maintained the same phenotype in all lesions analyzed whereas one later developed a tumor that was ALT-/TA+. Of the 10 patients whose tumors were initially ALT-/TA+, seven maintained the same phenotype throughout whereas the remaining three patients had metachronous liposarcomas that were ALT-/TA-. Fifteen patients initially had ALT-/TA-

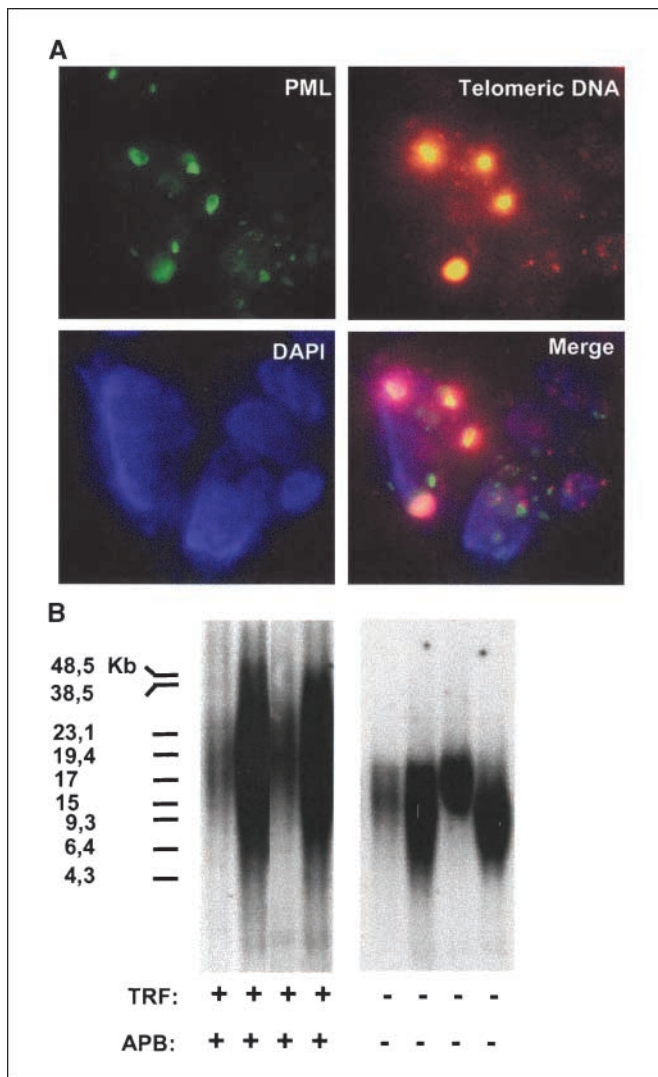


Figure 2. ALT assays in liposarcoma. **A**, APB assay: combined promyelocytic leukemia (PML) immunofluorescence and telomere fluorescence *in situ* hybridization in a frozen section of an APB+ liposarcoma. Indirect immunofluorescence was used for the promyelocytic leukemia protein (FITC label, green stain); telomere FISH was done using a Cy3 conjugated telomeric peptide nucleic acid probe (red stain); nuclei were counterstained with 4',6-diamidino-2-phenylindole (blue stain); the foci of telomeric DNA that colocalize with promyelocytic leukemia represent APBs. **B**, agreement of the APB assay with the TRF Southern blot analysis. Telomere length distribution of a representative series of liposarcomas is reported. The lengths of telomeres in ALT+ cells typically range from <3 to >50 kb. ALT- cells typically have a more homogeneous distribution of telomere length and a shorter average length.

liposarcomas, and of these 13 had subsequent lesions that maintained this phenotype whereas two of them subsequently had an ALT-/TA+ recurrence.

ALT and TA were present at significantly different frequency ($P < 0.0001$) in the histologic subtypes (Table 2). ALT occurred more frequently in well-differentiated and dedifferentiated liposarcomas whereas TA occurred more frequently in myxoid liposarcomas. The expression of at least one TMM correlated with histologic progression because ALT occurred more often in dedifferentiated than in well-differentiated tumors, and similarly TA occurred more often in round-cell myxoid than in usual myxoid liposarcomas. In addition, ALT and TA were more frequently observed in grade 3 and grade 2 tumors, respectively, whereas 65.7% of grade 1 liposarcomas did not show any known TMM (Table 2; $P < 0.0001$). The presence of ALT and TA, singly and/or in association, was unrelated to gender ($P = 0.49$), tumor location ($P = 0.16$), and presentation ($P = 0.36$), whereas an association was found with patient age, ALT-/TA+ tumors being more frequent in younger (≤ 50 years) and ALT+/TA- in older (> 50 years) patients ($P = 0.017$). Moreover, the percentage of APB+ liposarcoma cells was unrelated to clinical variables such as gender, age of patient, and tumor lesion, whereas a trend in favor of an association was observed with histologic subtype and tumor grade. Specifically, the percentage of APB+ cells was shifted towards higher values in dedifferentiated ($> 20\%$ positive cells in 20% of the cases) than in well-differentiated tumors ($\leq 5\%$ positive cells in 97% of the cases) as well as in grade 3 versus grade 1 to 2 liposarcomas (42% of grade 3 cases with $> 20\%$ positive cells versus only 3% of grade 1-2 cases).

Clinical outcome was analyzed on 93 patients (19 with primary, 68 with recurrent, and 6 with metastatic lesions; Fig. 1), categorized by their ALT/TA status as follows: ALT-/TA- ($n = 42$), ALT-/TA+ ($n = 23$), ALT+/TA- ($n = 24$), or ALT+/TA+ ($n = 4$). For six patients in whom ALT/TA status changed during the course of the disease, the appearance of any TMM defined the final phenotype (e.g., if metachronous tumors were ALT+/TA- and ALT-/TA+, the patient would be categorized as ALT+/TA+). In our case series, tumor site, grade, histology, and gender were associated with survival in univariate analysis whereas age, presentation, and size were not (Table 3). TA alone did not prove to be associated with disease-specific mortality. In contrast, significant results were obtained for ALT both from univariable ($P = 0.0022$) and multivariable (Table 3; $P = 0.0006$) analyses. Specifically, patients with ALT+ liposarcomas had a 3.6-fold hazard of death compared with those with ALT- tumors after adjustment for tumor location, grade, and histology (Table 3). No interaction was found between covariates (tumor location, grade, and histology) and TA or ALT. Overall, the presence of one or more TMM significantly ($P = 0.001$) affected patient prognosis (Table 3; Fig. 3A). Separately considering TA and ALT phenotypes within TMM, we could stratify our series into TA+, ALT+, and TMM- cases. Compared with TMM- cases, increased mortality was shown for both TA positivity and ALT positivity (Table 3; Fig. 3B), with adjusted hazard ratio estimates from the multivariable model of 2.6 (95% CI, 1.05-6.32; $P = 0.0382$) and 6.4 (95% CI, 2.64-15.49; $P < 0.0001$), respectively.

Discussion

This is the first report of a comparative analysis of the expression and clinical significance of the two currently known TMMs, ALT and TA, in a large group of liposarcomas with an

Table 2. TMMs in liposarcoma lesions

	No. specimens	ALT+/TA-	ALT-/TA+	ALT+/TA+	ALT-/TA-
Overall	139	33 (23.8%)	34 (24.5%)	3 (2.1%)	69 (49.6%)
Type of lesion					
Primary	19	4 (21.0%)	4 (21.0%)	1 (5.3%)	10 (52.7%)
Recurrence	103	26 (25.2%)	20 (19.4%)	2 (1.9%)	55 (53.5%)
Metastasis	17	3 (17.6%)	10 (58.8%)		4 (23.6%)
Histologic subtype					
Well differentiated	43	6 (14.0%)	1 (2.3%)		36 (83.7%)
Dedifferentiated	33	10 (30.3%)	6 (18.2%)	1 (3.0%)	16 (48.5%)
Usual myxoid	23	3 (13.0%)	9 (39.1%)		11 (47.9%)
Round-cell myxoid	26	4 (15.4%)	18 (69.2%)	2 (7.7%)	2 (7.7%)
Others	14	10 (71.4%)			4 (28.6%)
Grade					
1	73	15 (20.6%)	10 (13.7%)		48 (65.7%)
2	41	7 (17.1%)	20 (48.8%)	2 (4.9%)	12 (29.2%)
3	25	11 (44.0%)	4 (16.0%)	1 (4.0%)	9 (36.0%)

adequate follow-up, carried out according to REMARK guidelines (22). The results we obtained allowed us to show for the first time the correlation of ALT with tumor progression on the basis of its higher frequency in dedifferentiated and grade 3 liposarcomas, and to attribute to ALT an independent prognostic significance, even when adjusted for the most important clinicopathologic variables.

In our mono-institutional series of 139 specimens, ALT phenotype, as detected by the presence of APBs, and TA were expressed in balanced proportions and in ~25% of the cases, with minimal overlap and with stability during patient progression. These proportions are in keeping with previous reports assessing ALT in smaller liposarcoma case series with the same methodologic approach (12, 14). Specifically, by using the APB assay, we confirmed (a) a >80% agreement in a head-to-head comparison of ALT assessment by TRF length and (b) minimal spatial heterogeneity for ALT, with only 2.2% discordance in separated sections of the same tumor. Moreover, the APB assay allows the analysis of individual tumor cells whereas the TRF pattern is sometimes difficult to interpret possibly due to admixture of normal and tumor cells (12), which would suggest that the former is the most suitable assay for clinical specimens.

Consistent with the observations of Johnson et al. (14) in a smaller liposarcoma case series, we found that ~50% of the lesions that were examined in this study had neither ALT nor TA. Such a lack of any detectable TMM, previously observed also in a subset of retinoblastoma (23), osteosarcoma (7), Ewing's sarcoma (24), and glioblastoma multiforme (9), is in accord with recent experimental data suggesting that TMM acquisition is not strictly required for tumorigenesis (25). However, the possibility that the lack of TMM expression observed in half of the tested liposarcomas may be related, at least in part, to the sensitivity of the assays used cannot be excluded.

Coexistence of two TMMs in the same tumor, previously shown in other human tumor types (4, 9), occurred occasionally in our study and in the liposarcomas analyzed by Johnson et al. (14). However, at present it is not known whether TA and ALT can coexist within the same tumor cell or whether a given tumor lesion may contain distinct ALT+ and TA+ subpopulations, although experimental evidence obtained in ALT cells genetically engineered to express the catalytic component of telomerase suggests that the

two TMMs can function concurrently in most (26–29) but not all (30) cases.

The evidence that in liposarcoma the frequency of tumors that activate ALT is comparable with that of tumors that express telomerase, and that approximately half of the cases do not have any known TMM, opens important questions about the mechanisms that may determine which TMM becomes activated in individual tumors and the requirement for telomere maintenance during the development of this malignancy. Adult mesenchymal stem cells are considered to be the likely cellular targets for transformation giving rise to different types of cancers of mesenchymal origin including liposarcoma (31). Mesenchymal stem cells lack TA, but forced expression of hTERT in these cells

Table 3. Hazard ratio estimates for cause-specific death with 95% CI and *P* value: Cox proportional hazard regression models

Category (reference)	Hazard ratio (95% CI)	<i>P</i>
Univariable analysis		
TA (absent)	0.90 (0.46-1.78)	0.7663
ALT (absent)	2.70 (1.43-5.10)	0.0022
TMM (absent)	3.13 (1.50-6.58)	0.0027
Site (extremities and trunk)	3.58 (1.86-6.89)	0.0001
Histology (well differentiated)	2.45 (1.29-4.67)	0.0064
Grade (1)	1.68 (1.15-2.45)	0.0070
Age (up to 50 years)	0.99 (0.53-1.85)	0.9637
Gender (female)	0.54 (0.29-1.00)	0.0507
Size (up to 10 cm)	1.71 (0.85-3.45)	0.1335
Presentation (primary)	1.34 (0.69-2.62)	0.3864
Multivariable analysis adjusted for histology, grade, and tumor location		
TA, present (absent)	1.15 (0.56-2.38)	0.6999
ALT, present (absent)	3.58 (1.73-7.41)	0.0006
TMM		
Present (absent)	3.73 (1.76-7.88)	0.0010
ALT-/TA+ (ALT-/TA-)	2.58 (1.05-6.32)	0.0382
ALT+/TA- (ALT-/TA-)	6.39 (2.64-15.49)	<0.0001

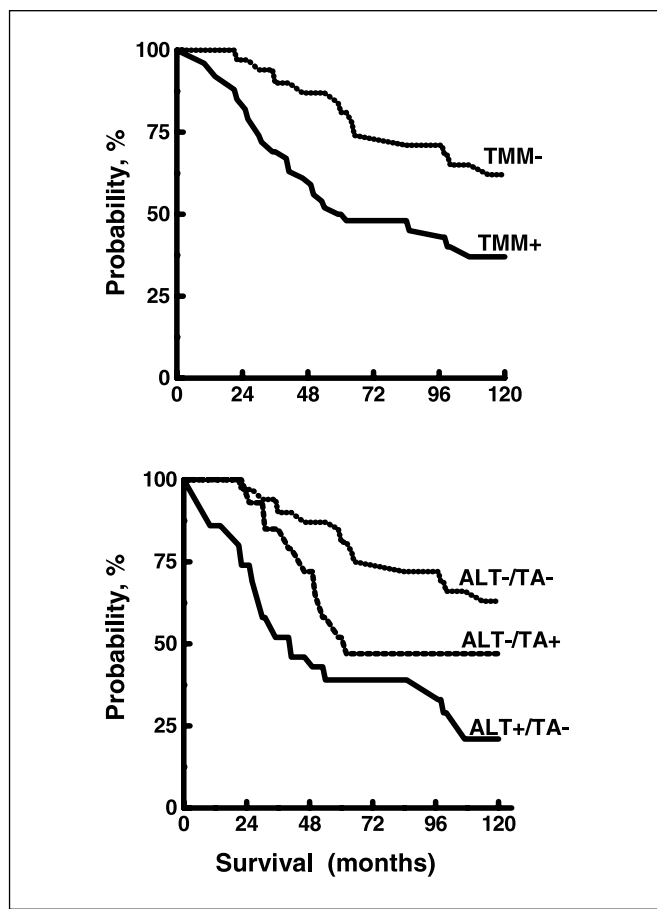


Figure 3. Overall survival by TMM phenotype in liposarcoma. *Top*, comparison between patients with TMM– tumors and those with TMM+ tumors; *bottom*, comparison between patients with TMM– tumors and those with TA+ or ALT+ tumors.

led to the acquisition of characteristics consistent with transformation, including the ability to form tumors in immunosuppressed mice (31). In mesenchymal stem cells (32), as well as in ALT+ immortalized cell lines (33), lack of telomerase expression seems to be due to the repressive chromatin environment surrounding telomerase gene promoters. Whether such epigenetic mechanisms of telomerase repression are operating in telomerase-negative liposarcomas deserves further analysis.

Liposarcomas represent a unique model encompassing two groups of tumors characterized by the presence of specific translocations, such as myxoid liposarcomas, or by complex karyotypes with severe genetic and chromosomal instability, such as well-differentiated/dedifferentiated liposarcomas, with each group containing low-grade (usual myxoid and well-differentiated liposarcoma) and high-grade (round-cell myxoid and dedifferentiated liposarcoma) subtypes (34). Our data highlight the segregation of TA and ALT phenotypes with myxoid and well-differentiated/dedifferentiated liposarcomas, respectively. Among the 34 myxoid liposarcomas based on histologic criteria present in our case series, 9 (2 usual myxoid and 7 round-cell myxoid) had cytogenetic confirmation of the presence of the t(12;16) translocation (35) and all of them were TA+ (data not shown). These findings corroborate and extend previous results (8, 36) showing an association between TA and tumors with simple translocations, between ALT and complex karyotype in soft-tissue sarcomas, and between ALT and

chromosomal instability in osteosarcoma. The ALT mechanism was hypothesized to be one of the possible causes of karyotypic complexity because very short and dysfunctional telomeres present in ALT cells might give rise to chromosomal end-to-end associations and breakage-fusion-bridge cycles, resulting in an increased number of complex nonreciprocal chromosomal rearrangements (36).

Our study showed an increased incidence of TMMs in the more aggressive liposarcoma subtypes, which in turn correlated with an unfavorable outcome. Higher frequencies of ALT+ and TA+ cases were observed in dedifferentiated and round-cell myxoid than in well-differentiated and usual myxoid subtypes, in agreement with earlier evidence about TA in malignant lipomatous tumors (37). The association of TMMs with tumor progression is further substantiated by the higher frequency of expression of ALT and TA we observed in grade 3 and grade 2 liposarcomas, respectively, compared with grade 1 tumors, which did not show any known TMM in about two thirds of the cases. In contrast, Johnson et al. (14) found a similar frequency of ALT and TA activation in grade 1 and 2 liposarcomas, which may reflect a different sample composition because in that study there was a predominance of grade 1, few grade 2, and no grade 3 tumors.

The question arises whether ALT per se is responsible for unfavorable outcome in liposarcoma. Results in animal models would suggest that ALT is less potent than TA in generating fully malignant tumors (11, 38). However, ALT+ spontaneously immortalized Li-Fraumeni cells transfected with oncogenic H-RAS formed tumors in athymic nude mice (6) and, more recently, it was shown that ALT+ human SV40-immortalized fibroblast cell lines require only oncogenic H-RAS to be converted to a fully tumorigenic state and metastasize to lung after implantation in the kidney capsule of an immunodeficient mouse (39). In contrast to liposarcomas, ALT is associated with a favorable outcome in glioblastoma multiforme (9). The explanation of these differing outcomes may be that activation of ALT results from sets of genetic changes that are tumor type specific, with those present in ALT+ glioblastomas or ALT+ liposarcomas causing better or worse prognosis, respectively, than those present in the corresponding TA+ tumors.

In our liposarcoma series, the prevalence of ALT in metastases was significantly lower than that of TA, possibly because ALT+ cells may take longer than TA+ cells to acquire the ability to metastasize. However, the evidence that three metastases showed ALT as the sole TMM would indicate that ALT+ tumors may nevertheless be highly malignant, as previously observed (4, 7, 12, 40).

Our retrospective study showed that ALT correlates more strongly with worse prognosis than TA even by multivariable analysis, which takes into account heterogeneous disease presentation, and notwithstanding its association with tumor grade. However, this result should be interpreted by considering TMM distribution within the two liposarcoma subgroups, which are also characterized by different clinical histories. The ALT mechanism, principally expressed in well-differentiated/dedifferentiated liposarcomas with greater prevalence in the dedifferentiated subgroup and in grade 3 tumors, contributed to the identification of a subset of tumors within the aggressive group with a worse prognosis, rapid recurrence, and death from local disease. The prevalence of TA in myxoid liposarcomas, with a peak of 70% in the round-cell myxoid subgroup, made it less specific in identifying, among putatively high-risk patients, those who will die. This observation is also consistent with the clinical outcome of round-cell myxoid liposarcomas,

characterized by a homogeneously dismal prognosis with metastasis-related death.

In summary, the finding that the presence of APBs provides prognostic information independent of tumor location, grade, and histology, which still remain the strongest determinants of clinical outcome, further supports the notion that in liposarcomas ALT positivity is associated with an aggressive behavior. Such an association held true regardless of TA because the combined consideration of TMMs was able to identify patients at a very low and at a very high risk of disease-specific death, but nonetheless ALT status proved to be the strongest discriminant. Notwithstanding the potential bias of a retrospective analysis carried out on a large but clinically heterogeneous series of liposarcomas, our results are in keeping with the clinical outcome of the patients but need to be validated in a prospective study also to better define the clinical role of the

two TMMs. Such a validation could have practical implications because telomerase inhibitors are already entering clinical trials, but they are likely to be ineffective against ALT+ tumors. In liposarcomas where ALT is relatively common, we suggest that TMM status should be characterized in individual tumors before starting an anti-telomerase treatment.

Acknowledgments

Received 1/23/2006; revised 6/29/2006; accepted 6/30/2006.

Grant support: Associazione Italiana per la Ricerca sul Cancro and European Community grants LSHC-CT-2004-502943 and LSHC-CT-2005-018806 and project grants and a postgraduate scholarship from the National Health and Medical Research Council of Australia.

The costs of publication of this article were defrayed in part by the payment of page charges. This article must therefore be hereby marked *advertisement* in accordance with 18 U.S.C. Section 1734 solely to indicate this fact.

We thank Roberta Erdas and Rosita Motta for skilled technical assistance.

References

- Allsopp RC, Chang E, Kashefi-Azham M, et al. Telomere shortening is associated with cell division *in vitro* and *in vivo*. *Exp Cell Res* 1995;220:194-200.
- Harley CB, Vaziri H, Counter CM, et al. The telomere hypothesis of cellular aging. *Exp Gerontol* 1992;27:375-82.
- Shay JW, Zou Y, Hiyama E, et al. Telomerase and cancer. *Hum Mol Genet* 2001;10:677-85.
- Bryan TM, Englezou A, Dalla-Pozza L, et al. Evidence for an alternative mechanism for maintaining telomere length in human tumors and tumor-derived cell lines. *Nat Med* 1997;3:1271-4.
- Dunham MA, Neumann AA, Fasching CL, et al. Telomere maintenance by recombination in human cells. *Nat Genet* 2000;26:447-50.
- Yeager TR, Neumann AA, Englezou A, et al. Telomerase-negative immortalized human cells contain a novel type of promyelocytic leukemia (PML) body. *Cancer Res* 1999;59:4175-9.
- Ulaner GA, Huang HY, Otero J, et al. Absence of a telomere maintenance mechanism as a favorable prognostic factor in patients with osteosarcoma. *Cancer Res* 2003;63:1759-63.
- Montgomery E, Argani P, Hicks JL, et al. Telomere lengths of translocation-associated and nontranslocation-associated sarcomas differ dramatically. *Am J Pathol* 2004;164:1523-9.
- Hakin-Smith V, Jellinek DA, Levy D, et al. Alternative lengthening of telomeres and survival in patients with glioblastoma multiforme. *Lancet* 2003;361:836-8.
- Henson JD, Neumann AA, Yeager TR, et al. Alternative lengthening of telomeres in mammalian cells. *Oncogene* 2002;21:598-610.
- Blasco MA. Telomerase beyond telomeres. *Nat Rev Cancer* 2002;2:627-33.
- Henson JD, Hannay JA, McCarthy SW, et al. A robust assay for alternative lengthening of telomeres in tumors shows the significance of alternative lengthening of telomeres in sarcomas and astrocytomas. *Clin Cancer Res* 2005;11:217-25.
- Sandberg AA. Update on the cytogenetics and molecular genetics of bone and soft tissue tumors: liposarcoma. *Cancer Genet Cytogenet* 2004;155:1-24.
- Johnson JE, Varkonyi RJ, Schwalm J, et al. Multiple mechanisms of telomere maintenance exist in liposarcomas. *Clin Cancer Res* 2005;11:5347-55.
- Gronchi A, Casali PG, Fiore M, et al. Retroperitoneal soft tissue sarcomas: patterns of recurrence in 167 patients treated at a single institution. *Cancer* 2004;100:2448-55.
- Gronchi A, Casali PG, Mariani L, et al. Status of surgical margins and prognosis in adult soft tissue sarcomas of the extremities: a series of patients treated at a single institution. *J Clin Oncol* 2005;23:96-104.
- Fletcher CDM, Unni KK, Mertens F, editors. *Pathology and genetics of tumours of soft tissue and bone*. Lyon: IARC Press; 2002.
- Villa R, Folini M, Perego P, et al. Telomerase activity and telomere length in human ovarian cancer and melanoma cell lines: correlation with sensitivity to DNA damaging agents. *Int J Oncol* 2000;16:995-1002.
- Grant JD, Broccoli D, Muquit M, et al. Telometric: a tool providing simplified, reproducible measurements of telomeric DNA from constant field agarose gels. *Biotechniques* 2001;31:1314-6.
- Kim NW, Piatyszek MA, Prowse KR, et al. Specific association of human telomerase activity with immortal cells and cancer. *Science* 1994;66:2011-5.
- Cox DR. Regression models and life tables. *J R Stat Soc B* 1972;34:187-220.
- McShane LM, Altman DG, Sauerbrei W, et al. Reporting recommendations for tumor marker prognostic studies (REMARK). *J Natl Cancer Inst* 2005;97:1180-4.
- Gupta J, Han LP, Wang P, et al. Development of retinoblastoma in the absence of telomerase activity. *J Natl Cancer Inst* 1996;88:1152-7.
- Ulaner GA, Hoffman AR, Otero J, et al. Divergent patterns of telomere maintenance mechanisms among human sarcomas: sharply contrasting prevalence of the alternative lengthening of telomeres mechanism in Ewing's sarcomas and osteosarcomas. *Genes Chromosomes Cancer* 2004;41:155-62.
- Seeger YR, Garcia-Cao M, Piccinin S, et al. Transformation of normal human cells in the absence of telomerase activation. *Cancer Cell* 2002;2:401-13.
- Perrem K, Colgin LM, Neumann AA, et al. Coexistence of alternative lengthening of telomeres and telomerase in hTERT-transfected GM847 cells. *Mol Cell Biol* 2001;21:3862-75.
- Cerone MA, Londono-Vallejo JA, Bacchetti S. Telomere maintenance by telomerase and by recombination can coexist in human cells. *Hum Mol Genet* 2001;10:1945-52.
- Grobelyny JV, Kulp-McEliece M, Broccoli D. Effects of reconstitution of telomerase activity on telomere maintenance by the alternative lengthening of telomeres (ALT) pathway. *Hum Mol Genet* 2001;10:1953-61.
- Stewart SA, Hahn WC, O'Connor BF, et al. Telomerase contributes to tumorigenesis by a telomere length-independent mechanism. *Proc Natl Acad Sci U S A* 2001;99:12606-11.
- Ford LP, Zou Y, Pongracz K, et al. Telomerase can inhibit the recombination-based pathway of telomere maintenance in human cells. *J Biol Chem* 2001;276:32198-203.
- Keith WN. From stem cells to cancer: balancing immortality and neoplasia. *Oncogene* 2004;23:5092-4.
- Serakinci N, Hoare SF, Kassem M, Atkinson SP, Keith WN. Telomerase promoter reprogramming and interaction with general transcription factors in the human mesenchymal stem cells. *Regenerative Med* 2006;1:125-31.
- Atkinson SP, Hoare SF, Glasspool RM, Keith WN. Lack of telomerase gene expression in alternative lengthening of telomere cells is associated with chromatin remodeling of hTR and hTERT gene promoters. *Cancer Res* 2005;65:7585-90.
- Pilotti S, Della Torre G, Lavarino C, et al. Distinct mdm2/p53 expression patterns in liposarcoma subgroups: implications for different pathogenetic mechanisms. *J Pathol* 1997;181:14-24.
- Knight JC, Renwick PJ, Cin PD, Van den Berghe H, Fletcher CD. Translocation t(12:16) (q13:p11) in myxoid and round cell liposarcoma: molecular and cytogenetic analysis. *Cancer Res* 1995;55:24-7.
- Scheel C, Schaefer KL, Jauch A, et al. Alternative lengthening of telomeres is associated with chromosomal instability in osteosarcomas. *Oncogene* 2001;20:3835-44.
- Schneider-Stock R, Boltze C, Jager V, et al. Elevated telomerase activity, c-MYC-, and hTERT mRNA expression: association with tumour progression in malignant lipomatous tumours. *J Pathol* 2003;199:517-25.
- Chang S, Khoo CM, Naylor ML, et al. Telomere-based crisis: functional differences between telomerase activation and ALT in tumour progression. *Genes Dev* 2003;17:88-100.
- Sun B, Chen M, Hawks CL, et al. Immortal ALT+ human cells do not require telomerase reverse transcriptase for malignant transformation. *Cancer Res* 2005;65:6512-5.
- Reddel RR, Bryan TM. Alternative lengthening of telomeres: dangerous road less travelled. *Lancet* 2003;361:1840-1.