

Minimal Iliac Bone Harvesting in Sinus Lift Surgery

G. Thiéry*

N. Lari

S. Adam

F. Salles

For sinus grafting, the authors propose a minimal posterior iliac bone harvesting, with local anesthesia. Autogenous bone grafting continues to be considered the gold standard for sinus grafting. The classic harvesting sites are calvarial, anterior iliac, and tibial, and harvesting is usually practiced under general anesthesia. We performed this technique in 7 patients under local anesthesia. In the posterior iliac crest, with a specific trocar for bone puncture biopsy, bone was harvested. We performed 1 cm longer for 5-mm diameter of bone. Three bone biopsies were harvested on each side. The harvested cancellous bone (5 cm³) was mixed with triphosphocalcic (TCP) material (2 cm³), and blood (1 cm³). A classic sinus lift was realized. After 6 months, the success rate of bone grafting was 100%. Each of the 7 patients could be implanted by an average of 4 dental implants by superior maxillary. For sinus lift, this simple posterior iliac-bone biopsy harvesting under local anesthesia is very comfortable for the patient and also safe. It provides enough marrow bone to be mixed with TCP for a sinus lift.

Key Words: bone grafting, iliac, local anesthesia, sinus lift

INTRODUCTION

In cases of severe atrophy of the maxillary alveolar process, the sinus lift surgery¹ allows for implant insertion. Autogenous bone grafting continues to be considered the gold standard for sinus grafting.² General anesthesia is often required. However, in some cases, the patient's health does not permit such anesthesia, or the patient may refuse this general anesthesia.

Some authors have already described iliac bone harvesting with manual or electric trephine.³ These techniques concern only cortical bone. In our technique, we harvest cancellous bone rich in osteoblasts. Other authors propose local anesthesia to harvest the anterior iliac crest.⁴ This technique results in a painful postoperative period because of the large quantity of bone required. In our technique, the quantity of autogenous bone is reduced because we mix it with triphosphocalcic (TCP) material.

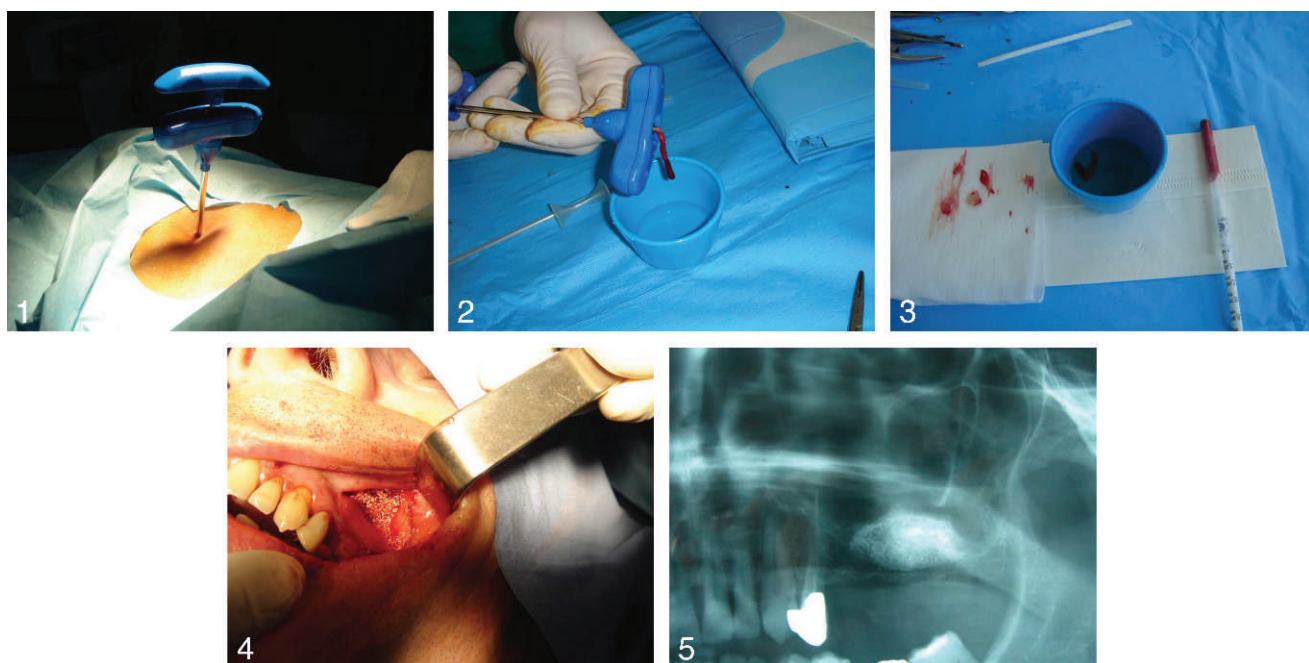
Our minimal iliac bone harvesting technique is new and presents many advantages: the use of local anesthesia; cancellous bone harvesting, which is easy to perform; painlessness of the procedure; reduced quantity of bone required because of the mix with TCP material; and reduction in scars due to the transcutaneous trocar.

Technical method

The patient is premedicated with light anxiolytic per os (hydroxyzine [Atarax] 50 mg, 1 hour before the operation) and initially placed in the ventral position. The iliac crest is palpated from forward to behind. The superior-posterior iliac spine site is repaired, which is the harvesting site. The landmarks are positioned laterally of the crest. The cutaneous, muscular, and cortical planes are infiltrated with 3 mL of Xylocaine adrenaline (lidocaine epinephrine 2%). The specific trocar for bone puncture biopsy (trocar Jamshidi for medullar biopsy, ref IT12306, Holtex, Aix-en-Provence, France) is introduced directly percutaneously (Figure 1). This trocar is usually used for bone biopsy in internal medicine. A handheld trephine was used. One centimeter longer for a 5-mm diameter of bone is harvested. Three

Department of Maxillofacial Surgery, Hôpital d'Instruction des Armées, Armées, France.

* Corresponding author, e-mail: thiery.gaetansophie@free.fr
DOI: 10.1563/AAID-JOI-D-09-00002



FIGURES 1–5. **FIGURE 1.** Specific trocar for bone puncture biopsy in the superior-posterior iliac spine. **FIGURE 2.** The harvesting bone was preserved in physiologic serum. **FIGURE 3.** (Right) Mixed material: cancellous bone and triphosphocalcic. (Left) Platelet-rich fibrin. **FIGURE 4.** The mixed material in the new cavity, under the Schneiderian membrane; platelet-rich fibrin closes a small membrane's hole. **FIGURE 5.** Radiographic control at 6 months showing the graft's success.

bone biopsies are possible by the same skin puncture. The punctiform wound does not need to be closed. A band-aid is applied by sticky strip. The bone's volume is about 4 to 5 cm³. The bone is preserved in physiologic serum (15 mm in block's temperature; Figure 2). The patient is returned to a dorsal position. A nerve-block anesthesia (under orbital nerve) completed by a mucosa infiltration provides total anesthesia. After creating a window in the maxillary sinus and dissecting beneath the sinus mucosa, a new sinus floor is fashioned 15 mm above its previous position.⁵ Care is taken to avoid perforation of the Schneiderian membrane. In such a situation, a platelet-rich fibrin (PRF)⁶ closes a small perforation. This physiologic membrane minimizes the possibility of graft extravasation in the maxillary sinus. The graft material is now prepared. We mix 4 to 5 cm³ harvested cancellous bone with 2 cm³ of TCP material (Graftek, Austin, Tex) and 2 cm³ blood from the elevated sinus cavity (Figure 3). The mixed graft material is introduced through the osteotomy in the new cavity. The TCP-bone mixture is compressed strongly (Figure 4).⁷ The mucosa is imperviously stitched with interrupted suturing techniques. A postoperative radiograph eliminates any material's extravasation in the sinus. The patient

is informed of temporary pain in the iliac crest. This pain is well controlled by standard analgesics. The success of the graft will be determined 4 to 6 months postoperatively by radiographic control (Figure 5). This technique, under local anesthesia, is able to enhance enough new bone to allow implant osseointegration.

DISCUSSION

We used this surgical technique in 7 patients for unilateral sinus lift. All were successful. The length of time for the sinus graft to be acceptable for implant surgery is about 4 months. The success of the graft is assessed by computerized tomodensitometry scan.

The only complication noted was pain in the iliac bone. This pain was evaluated as 2 on a scale of 10, and is completely calmed by standard analgesics (paracetamol, 6 g/d for 2 days). One patient presented an ecchymosis of the harvesting site.

With tree biopsy, the volume of bone is about 5 cm³. This volume is more important than the bone usually harvested in oral sites: chin, anterior ramus, or tuberosity. The iliac bone is a marrow bone, richer in osteoblasts.

The use autogenous bone guarantees osteoinduction with bone morphogenetic protein. The TCP is a filler material with volumetric effect and ensures osteoconduction. We prefer this synthetic material to the allograft to avoid the potential risk of pathology transmission. We respect the principle of precaution. The platelets of the PRF contain a lot of growth hormone, facilitating osteogrowth.

Other authors⁸ have proposed calvarial-bone harvesting under local anesthesia with a minibone plane. The 2 different techniques are systematically proposed to our patients. The 7 patients in this study preferred iliac harvesting.

CONCLUSION

Autogenous bone remains the gold standard for preimplant bone-grafting procedure. To simplify the procedure, the authors propose iliac-bone biopsy harvesting under local anesthesia. The technique remains very comfortable for the patient and also safe. It provides enough marrow bone to be mixed with TCP, for a sinus lift.

ABBREVIATIONS

PRF: platelet-rich fibrin

TCP: triphosphocalcic

REFERENCES

1. Boyne M, James RA. Grafting of the maxillary sinus floor with autogenous marrow and bone. *J Oral Surg.* 1980;38:613–616.
2. Lorenzetti M, Mozzati M, Campanino P, Valent G. Bone augmentation of the inferior floor of the maxillary sinus with autogenous bone or composite bone grafts: a histologic-histomorphometric preliminary report. *Int Oral Maxillofac Implants.* 1998;13:69–76.
3. Freilich MM, Sandor GK. Ambulatory in-office anterior iliac crest bone harvesting. *Oral Surg Oral Med Oral Pathol Oral Radiol Endod.* 2006;101:291–298.
4. Kinsel RP, Turbow MM. The use of a trephine biopsy needle to obtain corticocancellous bone from the iliac crest: technical note. *Int J Oral Maxillofac Implants.* 2004;19:438–442.
5. Tulasne JF, Saade J, Riachi A. Greffe osseuse du sinus maxillaire et implants de Branemar. *Implant.* 1993;2:101–114.
6. Choukroun J, Adda F, Schoeffler C, Vervelle A. Une opportunité en paro-implantologie: le PRF. *Implantodontie.* 2001;42:55–62.
7. Elachkar IY. Bone injector in sinus lift surgery. *Br J Oral Maxillofac Surg.* 2001;39:450–451.
8. Paraque A. Cranial-bone grafting under local anesthesia. *Rev Stomatol Chir Maxillofac.* 2008;109:40–43.