

EDENTULOUS ARCH TREATMENT WITH A CAD/CAM SCREW-RETAINED FRAMEWORK AND CEMENTED CROWNS: A CLINICAL CASE REPORT

Mirza-Rustum Baig, MDS; Gunaseelan Rajan; Manoj Rajan, MDS

This article describes the rehabilitation of a completely edentulous patient using a milled titanium implant framework and cemented crowns. This combined approach significantly offsets unsuitable implant position, alignment, or angulation, while ensuring the easy retrievability, repair, and maintenance of the prosthesis. Hence, the dual advantage of cemented-retained crowns reproducing appropriate esthetics and function, irrespective of where the screw access openings are located in the substructure, can be obtained, along with the splinting effect and management of soft and hard tissue deficits achievable with a screw-retained framework.

Key Words: implant-retained FPD, titanium, computer milling, hybrid prostheses

INTRODUCTION

Fixed rehabilitation of completely edentulous situations can be achieved with the use of a screw-retained implant hybrid prosthesis, conventional screw-retained metal-ceramic prosthesis, cemented metal-ceramic prosthesis, and cemented hybrids.¹⁻³

Screw-retained implant fixed prostheses have been advocated traditionally because of their ease of retrievability, benefit of splinting, and low profile retention. Hybrid screw-retained prostheses additionally compensate for lost tissues in moderately to severely resorbed alveolar ridges. However, lack of passive fit of the cast framework and distortion of the framework upon porcelain firing remain problem areas. In severe ridge resorption, off-axial implant positioning may result in the labial or buccal emergence of the access screw channel, thus com-

promising esthetics and preventing ideal occlusal morphology.^{1,4}

Cement-retained fixed implant prostheses have the advantages of passively fitting frameworks and better esthetics. Custom abutment options can compensate for malaligned implants, thus improving esthetics.⁵⁻⁷ However, retrievability, repair and maintenance, choice of cement, and excess cement in the sulcus remain areas of concern.

Thus, the combination of a screw-retained framework with cemented crowns in a fully edentulous situation would combine the advantages of the 2 approaches. Earlier reports have discussed the management of partially edentulous cases by adopting this combination approach using cast^{8,9} and zirconia¹⁰ frameworks. However, no reports on the use of this combination approach with titanium-milled (computer-aided manufacturing [CAM]) frameworks have been published.

This article describes the management of a completely edentulous patient using metal-ceramic cement-retained crowns in combination with a customized (milled) titanium screw-retained framework.

CLINICAL REPORT

A 43-year-old completely edentulous female reported to the clinic seeking fixed prosthesis for her condition.

Mirza-Rustum Baig, MDS, is an assistant professor, Department of Prosthetic Dentistry, University Malaya, Kuala Lumpur, Malaysia, and a visiting assistant professor in the Department of Prosthodontics, Ragas Dental College and Hospital, Chennai, India. Gunaseelan Rajan, is a medical director and senior consultant oral surgeon at Rajan Dental Institute, Chennai, India. Manoj Rajan, MDS, is an associate professor in the Department of Prosthodontics, Ragas Dental College and Hospital, Chennai, India. Address correspondence to Dr Baig at Department of Prosthetic Dentistry, Faculty of Dentistry, University Malaya, Jalan University, Kuala Lumpur 50603, India. (e-mail: drmrbaig@yahoo.com)

She had lost all of her teeth as the result of inadequate oral hygiene and periodontal disease. The last of her extractions was done 10 years earlier. She had been restored with heat cure acrylic removable complete dentures but faced psychological problems caused by poor retention.

Clinical and radiologic examination revealed moderate to severe resorption of the alveolar ridges (Figure 1). Implant-retained fixed prostheses were planned to restore her arches. Maxillary alveolar onlay bone grafting was done under general anesthesia using corticocancellous blocks and cancellous chips from the iliac crest. This procedure was done to improve the width of the alveolar ridge. Simultaneously, a direct sinus lift procedure was done in the right maxilla for augmentation of posterior maxillary bone height. The graft was allowed to heal for 6 months.

Maxillary and mandibular diagnostic complete dentures were made for the upper and lower arches. Dental implant placement was done through an open flap procedure by using the diagnostic dentures as surgical guide stents. In the maxilla, 9 dental implants (Replace Select, Nobel Biocare, Cologne, Germany) were placed, and in the mandible, 6 dental implants (Replace Select, Nobel Biocare) were placed.

After a period of 6 months, open-tray impressions of the maxillary and mandibular arches were made with open-tray impression transfer copings (Nobel Biocare) using polyether elastomeric impression material (Impregum, 3M Espe, St Paul, Minn). The transfer copings were splinted with autopolymerizing resin (GC Pattern Resin, GC Corp, Tokyo, Japan) before the impressions were taken. Master casts were poured in Type IV dental stone (Silky Rock, Whip Mix Corp, Louisville, Ky) with implant replicas (NobRpl, Nobel Biocare AB, Goteborg, Sweden). A wax trial (using denture teeth with screw-retained acrylic resin bases made on the master casts) was performed for clinical evaluation and approval by the patient. Nonengaging plastic abutments then were attached to the implant replicas on the master cast, and resin patterns (GC Pattern Resin, GC Corp) were fabricated using the diagnostic denture wax-up as a guide. Adequate cutback was done on the resin framework to accommodate conventional full-coverage crown restorations in both maxillary and mandibular arches. In the maxillary arch, only 6 implants and abutments were used in construction of the resin framework. Three maxillary implants could not be accommodated into the final prosthesis because of severe labial inclination and were left as sleepers, although they had osseointegrated well.

The resin pattern frameworks were scanned using the Procera Forte scanner (Nobel Biocare, Benelux B.V.,

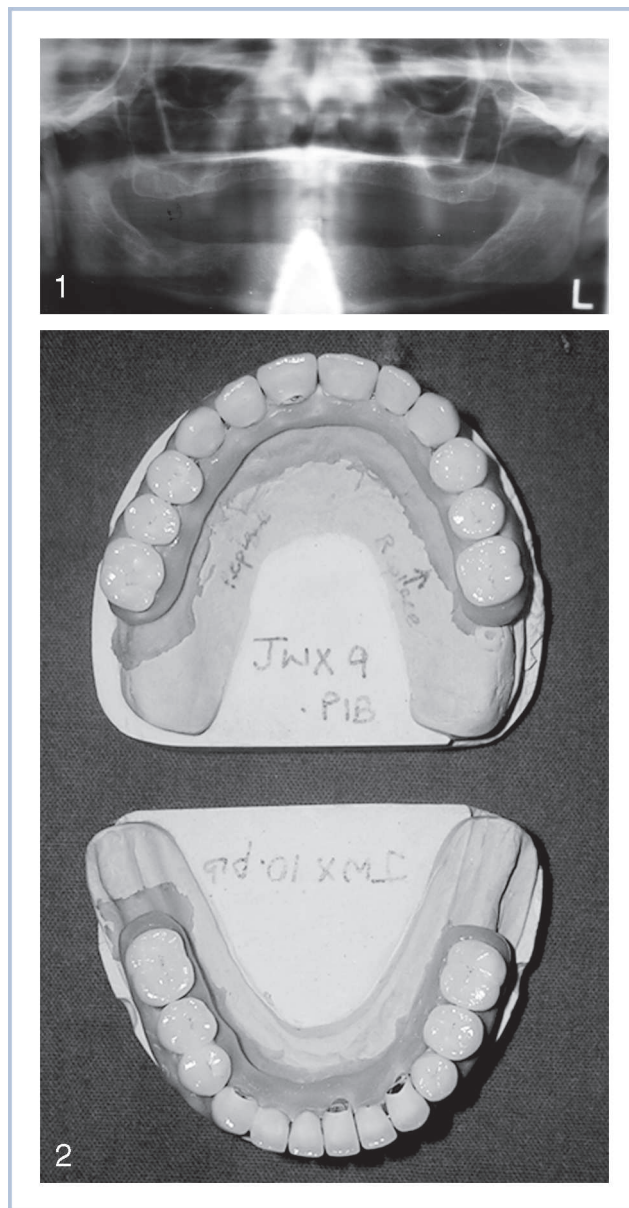


FIGURE 1. Panoramic view of the maxillae and mandible pretreatment. FIGURE 2. Metal ceramic restorations positioned on completed infrastructures of the maxillary and mandibular master casts.

Houten, Utrecht, The Netherlands), and frameworks were milled from solid pieces of titanium (Figure 2). The titanium frameworks were manually finished before clinical evaluation was performed. Framework try-in was done to check for passivity of fit (Figure 3a and b). The fit was found satisfactory, and frameworks were veneered with gingival pink porcelain to resemble soft tissue in gingival areas. Metal-ceramic cement-retained crowns (Degudent U, Degudent GmbH, Hanau-Wolfgang, Germany; IPS d.SIGN, Ivoclar Vivadent, Schann, Leichtenstein) then were fabricated. The crowns were provided with lingual and palatal

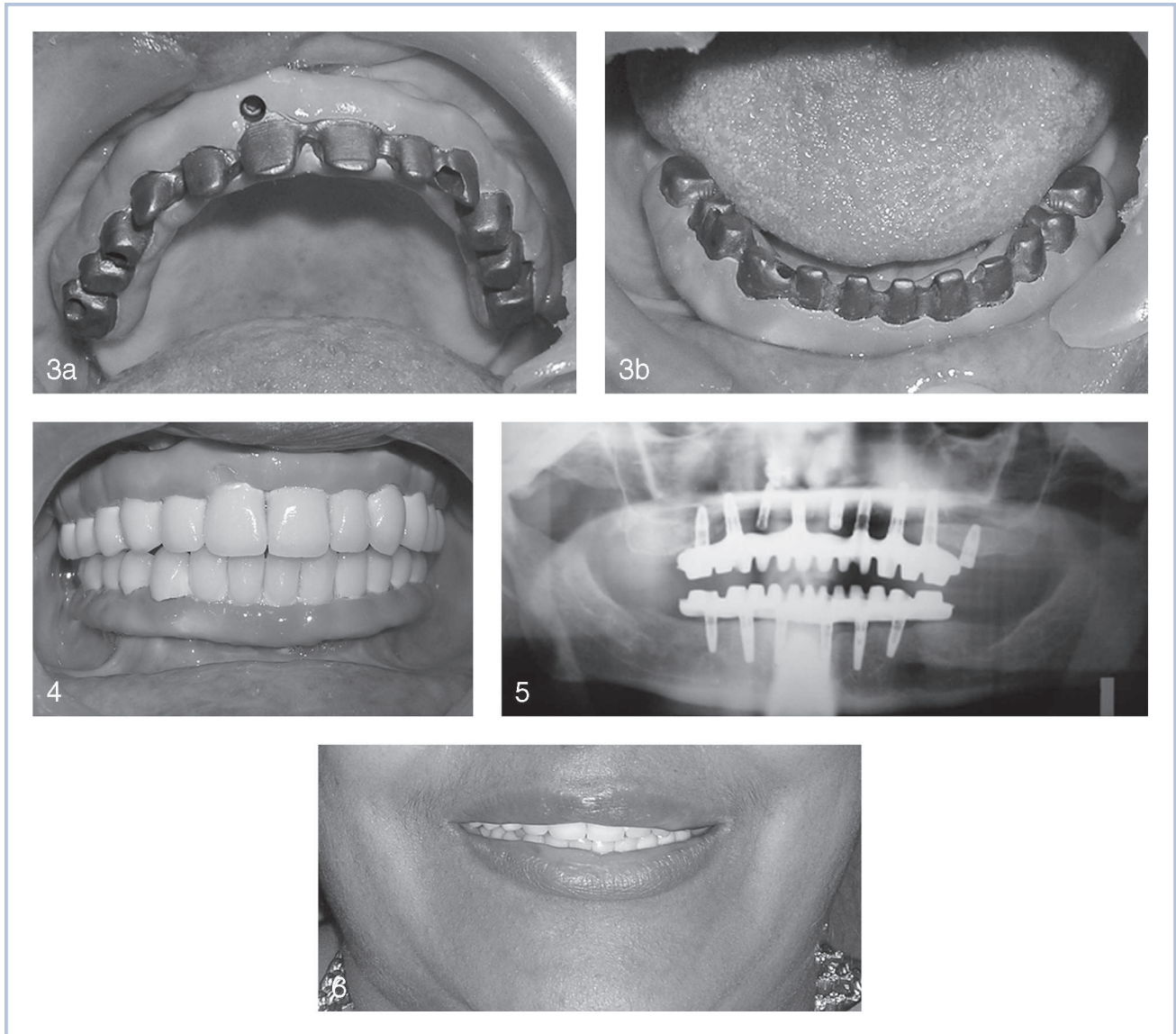


FIGURE 3. (a) Maxillary screw-retained infrastructure in place. (b) Mandibular screw-retained infrastructure in place.

FIGURE 4. Crowns cemented on individual infrastructure abutments using provisional cement.

FIGURE 5. Panoramic view of the maxillae and mandible post treatment.

FIGURE 6. Post treatment (patient's smile).

notches near the crown/framework junction to enhance retrievability of the individual crowns, if required. Of 24 units (crowns) fabricated for the maxillary and mandibular arches, 20 were single units and 4 were splinted crowns of 2 units each. The splinted units were both used in the mandibular arch. Splinting was done to offset the inadequate height and retention form of the abutments/framework in some regions. The screw-retained framework then was secured to the implants at 35 Ncm torque. The screw access holes were sealed with gutta-percha, and composite fillings were placed on top of it. The crowns were cemented over the framework individu-

ally, using provisional (TempBond, Kerr Corporation, Orange, Calif) cement in a conventional manner (Figure 4). The patient was placed on an oral hygiene and periodontal maintenance protocol (Figure 5). The implant prosthesis restored lost function and provided the necessary esthetics; the patient was seen at follow-up maintenance with no complaints (Figure 6).

DISCUSSION

The prosthesis described in this case report combined the advantages of cement and screw-retained implant

restorations. The screw-retained infrastructure was not influenced to a major extent by implant position or angulation. The crowns were individually cemented onto the framework, reproducing desirable esthetics and morphology, regardless of where the screw access openings were found in the framework. The crowns were luted only provisionally to the framework, hence enabling easy retrievability, repair, and maintenance without jeopardizing the entire framework. The customized screw-retained titanium framework was layered with gingiva-colored porcelain to resemble soft tissue in gingival areas.³ The prosthesis design introduced in this article was a modification of a technique described earlier by Hagiwara et al.⁸ However, a computer-milled titanium screw-retained framework was used in the present study instead of a cast framework, as described in the earlier report. Studies have shown that computer numeric controlled (CNC) milled implant titanium frameworks yield a more accurate fit than is provided by conventional implant cast frameworks.¹¹⁻¹⁴

Passive fit is assumed to be a significant prerequisite for maintaining the integrity of the bone-implant interface.^{15,16} Failure to produce passive fit may cause mechanical failure of the prostheses or implants and biologic complications in surrounding tissues.^{17,18} Branemark suggested that precision of the prosthesis fit should be within the range of 10 μm .¹⁹ However, studies have shown that full-arch frameworks do not attain this level of accuracy.²⁰ The milled titanium frameworks attempt to eliminate some of the laboratory steps involved in the fabrication of cast frameworks, which are known to cause distortion and subsequent misfit.²¹⁻²³ However, it does not eliminate the impression stage distortion.

A completely edentulous patient had been restored using this technique, whereas in earlier studies, only partially edentulous arches were restored. Grafting procedures were used in conjunction with this technique in treatment of this patient.

The original concept of combined screw and cement retention that had been advocated initially by Rajan and Gunaseelan,⁹ for fabricating a retrievable cement- and screw-retained implant prosthesis, combined the advantages^{5,24-26} of cement retention and screw retention for single-tooth implant-supported restorations. These advantages included retrievability of the abutment and the prosthesis, avoidance of the use of provisional cements, and ease of intentional removal of the prosthesis to clean excess cement.

This technique was improvised further by Uludag et al, using a zirconium-fixed partial denture.¹⁰ In both of these studies, however, the screw access channel

had been maintained even in the final restoration, thereby enabling intentional removal of the entire prosthesis by screw removal. Since that time, additional modifications have been made to the original technique, whereby screw access holes were not maintained in the final restorations, and intentional removal, if required, involved removing only the provisionally cemented individual crowns.

Although the technique described in this article addresses most of the concerns of the complete-mouth, fixed, implant-supported restoration in the atrophic jaw, it has some limitations. The crowns were cemented with provisional cement, and this could lead to dislodgement of the prosthesis in usage and could create an undesirable complication for the patient. The use of stronger cements may avoid dislodgement but may make retrieval, if necessary, more difficult. Some techniques²⁷ have described retrievable metal-ceramic crowns with computer-aided design/computer-aided manufacturing (CAD-CAM) milled titanium frames for completely edentulous arches, without the use of cements. The crowns are retained to the titanium substructure using lingual set screws. However, this involves greater numbers of screws and associated potential complications with single-tooth screw-retained restorations, especially with off-axial loading (lingual retention screws) and nonengagement of the crown directly into the titanium substructure (for antirotation).

Passive fit concerns and the weight of the cast framework were prime reasons for deciding on CAD-CAM substructure for this patient. The provisionally luted crowns with special features (lingual and palatal notches) ensured retrievability. Esthetic concerns led to the preferential use of both screw and cement retention in the final prosthesis.

SUMMARY

This report describes the management of a completely edentulous patient with highly resorbed maxillae and mandible using fixed screw-retained implant prostheses with cemented crowns. The technique adopted in the fabrication of the prostheses in this patient overcame to a major extent the difficulties encountered with compromised dental implant angulations. Furthermore, the use of cemented crowns on the screw-retained framework negated the possibility of warpage of the frame when a large amount of porcelain is fired on it, thereby improving fit to the implants.

If a crown were to fracture in function, it could be replaced individually without the need to refabricate

or refire the frame. Finally, the technique enabled restoration of lost soft tissue and bone.

REFERENCES

- Balshi TJ. Preventing and resolving complications with osseointegrated implants. *Dent Clin North Am.* 1989;33:821–868.
- Lekholm U. Surgical considerations and possible shortcomings of host sites. *J Prosthet Dent.* 1998;79:43–48.
- Salenbauch NM, Langner J. New ways of designing superstructures for fixed implant-supported prostheses. *Int J Periodontics Restorative Dent.* 1998;18:604–612.
- Golden WG, Wee Ag, Danos TL, Cheng AC. Fabrication of a two-piece superstructure for a fixed detachable implant-supported mandibular complete denture. *J Prosthet Dent.* 2000;84:205–209.
- Hebel KS, Gajjar RC. Cement-retained versus screw-retained implant restorations: achieving optimal occlusion and esthetics in implant dentistry. *J Prosthet Dent.* 1997;77:28–35.
- Henriksson K, Jemt T. Evaluation of custom-made Procera ceramic abutments for single-implant tooth replacement: a prospective 1-year follow-up study. *Int J Prosthodont.* 2003;16:626–630.
- Singer A, Serfaty V. Cement-retained implant-supported fixed partial dentures: a 6-month to 3-year follow-up. *Int J Oral Maxillofac Implants.* 1996;11:645–649.
- Hagiwara Y, Nakajima K, Tsuge T, McGlumphy EA. The use of customized implant frameworks with gingival-colored composite resin to restore deficient gingival architecture. *J Prosthet Dent.* 2007;97:112–117.
- Rajan M, Gunaseelan R. Fabrication of a cement and screw-retained implant prosthesis. *J Prosthet Dent.* 2004;92:578–580.
- Uludag B, Ozturk O, Celik G, Goktug G. Fabrication of a retrievable cement- and screw-retained implant-supported zirconium fixed partial denture: a case report. *J Oral Implantol.* 2008;34:59–62.
- Al-Fadda SA, Zarb GA, Finer Y. A comparison of the accuracy of fit of 2 methods for fabricating implant-prosthodontic frameworks. *Int J Prosthodont.* 2007;20:125–131.
- Ortorp A, Jemt T, Back T, Jalevik T. Comparison of precision of fit between cast and CNC-milled titanium implant frameworks for the edentulous mandible. *Int J Prosthodont.* 2003;16:194–200.
- Torselle F, di Torresanto VM, Ercoli C, Cordaro L. Evaluation of the marginal precision of one-piece complete arch titanium frameworks fabricated using five different methods for implant-supported restorations. *Clin Oral Implants Res.* 2008;19:772–779.
- Ehrenkranz H, Langer B, Marotta L. Complete-arch maxillary rehabilitation using a custom-designed and manufactured titanium framework: a clinical report. *J Prosthet Dent.* 2008;99:8–13.
- Klineberg IJ, Murray GM. Design of superstructure for osseointegrated implants. *Swed Dent J.* 1985;28(suppl):63–69.
- Goll GE. Production of accurately fitting full-arch implant frameworks, Part 1: clinical procedures. *J Prosthet Dent.* 1991;66:377–384.
- Kallus T, Bessing C. Loose gold screws frequently occur in full-arch fixed prostheses supported by osseointegrated implants after 5 years. *Int J Oral Maxillofac Implants.* 1994;9:169–178.
- Uludamar A, Leung T. Inaccurate fit of implant superstructures, Part II: efficacy of the Preci-disc system for the correction of errors. *Int J Prosthodont.* 1996;9:16–20.
- Branemark PI. Biological principles relative to osseointegrated implants. Continuing education course; October 1985; Rochester, Minn.
- Carr AB, Stewart RB. Full-arch implant framework casting accuracy: preliminary in-vitro observation for in-vivo testing. *J Prosthodont.* 1993;2:2–8.
- Jemt T. Three dimensional distortion of gold alloy castings and welded titanium frameworks: measurement of the precision of fit between completed implant prostheses and the master cast in routine edentulous situations. *J Oral Rehabil.* 1995;22:557–564.
- Tan KB, Rubenstein JE, Nicholls JI, Yuodelis RA. Three-dimensional analysis of the casting accuracy of one piece, osseointegrated implant retained prostheses. *Int J Prosthodont.* 1993;6:346–363.
- Calderini A, Maiorana C, Garlini G, Abbondanza T. A simplified method to assess precision of fit between framework and supporting implants: a preliminary study. *Int J Oral Maxillofac Implants.* 2007;22:831–838.
- Chee W, Felton DA, Johnson PF, Sullivan DY. Cemented versus screw retained prosthesis: which is better? *Int J Oral Maxillofac Implants.* 1999;14:137–141.
- Misch CE. *Contemporary Implant Dentistry.* 2nd ed. St Louis, Mo: Mosby; 1998:549–573.
- Taylor TD, Agar JR. Twenty years of progress in implant prosthodontics. *J Prosthet Dent.* 2002;88:89–95.
- Piermatti J. Using CAD-CAM technology for the full-mouth, fixed, retrievable implant restoration: a clinical report. *J Oral Implantol.* 2007;33:23–27.