

An Evaluation of Biocompatibility of Indigenously Produced Pure Titanium: An Experimental Study in Rabbits

Bhogisetty Chittaranjan, MDS^{1*}
Late Bhamidipati Sreerama Murthy, MDS²
Turaga Ravindranath, MDS³

The indigenously produced pure titanium dental implants are economical and useful for common human use in India. The aim of this study is to test the biocompatibility of the indigenously produced pure titanium dental implant material obtained from the Defense Metallurgical Research Laboratory, Hyderabad, India, and the Institute of Nuclear Medicine and Allied Science, Delhi, India. An experimental study in rabbits was done to study the amount of ordered bone formation around the screw and cylinder type of indigenously produced pure titanium metal implant specimens. The experimental animals were killed at 4, 6, 8, 12, and 16 weeks from the date of implantation. The histopathological examination of the animals killed at 16 weeks demonstrates the presence of osteoblastic cell proliferation and early ordered bone formation toward the implant site, indicating signs of osseointegration of both screw- and cylinder-type indigenously produced pure titanium specimens.

Key Words: *indigenously produced pure titanium, biocompatibility, osseointegration*

INTRODUCTION

An ideal prosthesis, besides having good retention, should have the other ideal requirements of biocompatibility, esthetics, phonetics, and masticatory function to achieve patient acceptance. Prosthesis without adequate retention creates problems to the patient and the dental professional.

Improvements in metal technology led to an era of expanded surgical use of metallic implants.¹ Pure titanium as an implant material is extremely well tolerated by the body tissues.^{2,3} Titanium and its alloys are important in dental and surgical implants because of their high degree of biocompatibility, strength, and corrosion resistance.⁴ Biocompatibility

includes physical, mechanical, chemical, and electrical properties of the materials per se. All of the implant materials should be biologically inert without producing any host tissue reactions.⁵ The concept of osseointegration was developed and the term conceived by Dr Per Ingvar Branemark.^{2,6} Branemark's experimental and clinical applications have been replicated in several centers and indicate an important advance in the field of tissue-integrated prostheses.⁷⁻¹¹ The concept of osseointegration is based on research that began in 1952 with microscopic in situ of bone marrow in the fibula of rabbits.² There are various reports^{4,12} about the use of titanium in its pure form or its alloys as implant materials. There are many reports¹³⁻¹⁵ to substantiate the soft-tissue biocompatibility of pure titanium. It has been demonstrated that the epithelial cells attach to the titanium surface in the same manner, as observed around the surface of natural teeth.¹⁶ There are reports regarding the nontoxic and noncarcinogenic nature of titanium implants.¹

Many companies abroad are producing different

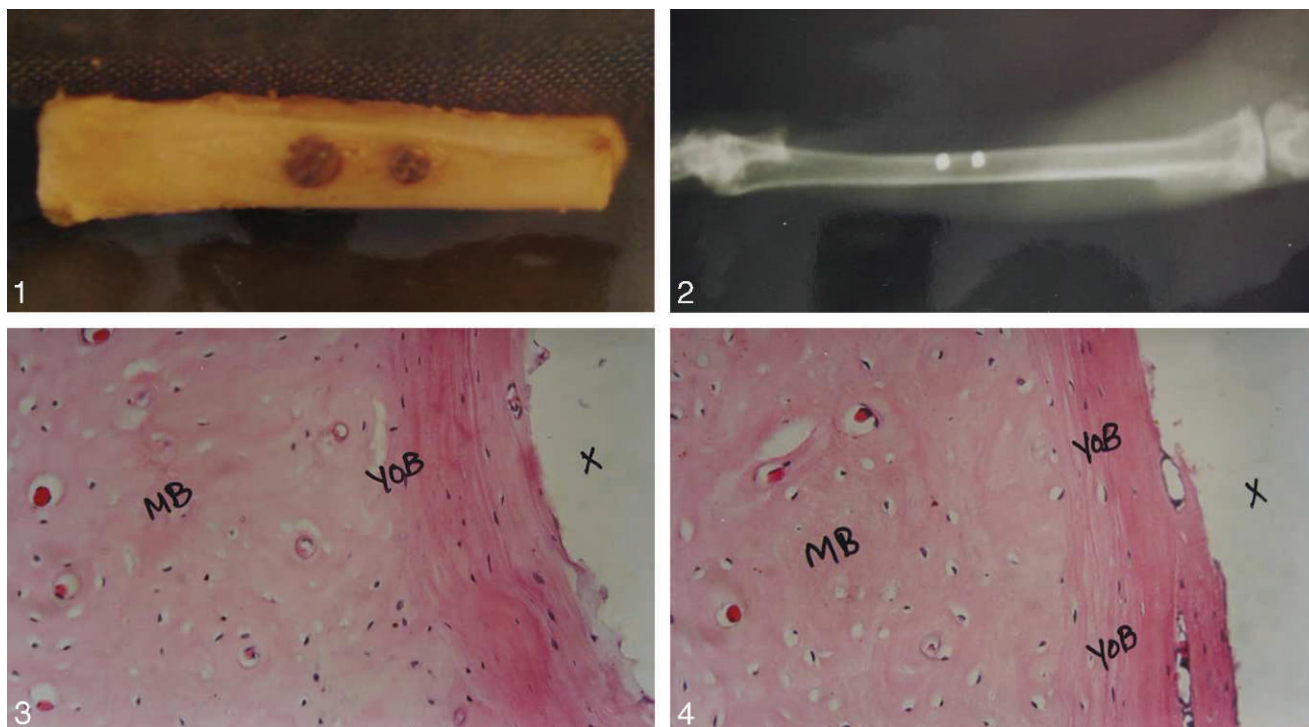
¹ Department of Prosthodontics, ITS-CDSR, Muradnagar, India.

² Government Dental College, Hyderabad, India.

³ Army Dental College, Secunderabad, India.

* Corresponding author, e-mail: prosthoranjan@yahoo.com

DOI: 10.1563/AAID-JOI-D-09-00099



FIGURES 1–4. **FIGURE 1.** Rabbit right tibial bone with both screw type and cylinder type of pure titanium test specimens. **FIGURE 2.** Radiograph showing the pure titanium test specimens in the rabbit right tibial bone. **FIGURE 3.** F1 (16 weeks): A cross section showing the presence of young ordered bone (YOB) around implant site (X). Mature bone (MB) was seen adjacent to the young ordered bone ($\times 100$). **FIGURE 4.** F2 (16 weeks): A cross section showing the formation of young ordered bone (YOB) toward the implant site (X). Mature bone (MB) was seen adjacent to the young ordered bone ($\times 250$).

types of dental implants. The Defense Metallurgical Research Laboratory in Hyderabad and Institute of Nuclear Medicine and Allied Science (INMAS) in Delhi, India, have collaborated to launch an indigenous pure titanium dental implant system in India. These implants are economical for common prosthetic applications. Multicenter clinical trials have been completed to establish the acceptability of the indigenously manufactured implants. These implants were designed for their suitability and acceptability. They meet American Society for Testing and Materials and Bureau of Indian Standards standards and are approved by the drug controller of India and Indian Council of Medical Research.¹⁰

MATERIALS AND METHODS

The indigenous pure titanium metal dental implant was used as the test specimen in this study. An experimental design using animals was done to examine the amount of ordered bone formation on cylindrical and screw-type forms of pure titanium metal implant specimens. Six male adult New

Zealand white rabbits (Centre for Cellular and Molecular Biology, Hyderabad, India) were used as experimental animals for this study. All animals were between 1 to 1½ years of age, and the weight of the animals was about 2–3 kg.

The pure titanium dental implants used in this study were designed in the form of cylinders and screws to suit available bone where the implant is to be placed. To facilitate implantation into the rabbit tibial bone, 12 pure titanium dental implants were used as test specimens for this animal experimental study; 6 were screw type and 6 were cylindrical type. Each pure titanium dental implant test specimen is 2 mm in length and 2 mm in diameter, to facilitate easy implantation into the rabbit tibial bone. Twelve samples of chrome-cobalt alloy cylindrical-shaped implants of similar dimensions to the pure titanium dental implants were used as controlled samples. All surgical instruments and implant specimens were sterilized prior to surgical use. The animals were anesthetized with Intravan (thiopental sodium) injection. An aseptic technique was used throughout the procedure. One cylinder and one screw type of the indigenous pure

titanium dental implant sample were placed in the right tibial bone of the experimental rabbit (Figures 1 and 2). The 2 chromium-cobalt samples were placed in the left tibial bone of the same rabbit. A uniform pattern of using right and left tibial bone for implantation of both of the specimens is followed to avoid confusion at any stage during the study. After the animal was anesthetized, hair around the surgical site was removed with scissors. A full-thickness incision was made in the mid-thigh region with a No. 11 B.P. blade, and the muscles were carefully separated to expose the underlying metaphysis of the tibia. Using a surgical bur of 1.7-mm diameter in a hand drill bit with continued saline irrigation, 2 osteotomy sites were prepared over the right side of the tibial bone. One cylinder and one screw type of pure titanium dental implant specimens were placed into the osteotomy sites prepared on the right side of the tibial bone. A minimum 3-mm gap was maintained between the 2 osteotomy sites. Two similar osteotomy sites were prepared in the left tibial bone region following the same procedure to accommodate 2 chromium-cobalt alloy specimens. With gentle tapping, the samples were implanted into the osteotomy sites, ensuring the snug fitting of the test specimen. After placement of test specimens, the muscle layer was closed with an ethicon resorbable suture and the skin approximated with 5-0 silk suture material. The same surgical procedure was followed subsequently for all other animals used in this study.

The animals were divided into 6 groups. Group A was killed at 4 weeks, group B at 6 weeks, group C at 8 weeks, group D at 12 weeks, and groups E and F at 16 weeks after the insertion of implant material. In the group A animal, the test specimens were subgrouped into A1, A2, A3, and A4 for histological interpretation

- A1: Screw-type pure titanium metal implant specimen
- A2: Cylinder-type pure titanium metal implant specimen
- A3: Cylinder-type cobalt-chromium alloy implant specimen
- A4: Cylinder type chromium-cobalt alloy implant specimen

The same procedure of subgrouping was followed for the other specimens. All of the experimental animals were placed in separate

cages, and the postoperative health of all the animals was also evaluated by recording the weight of the animals at periodic intervals. The specimens were sacrificed and the implants along with the surrounding bone were resected at time points of 4, 6, 8, 12, and 16 weeks from the date of implantation. All of the specimens were subjected to histopathological observation under stereomicrograph at the National Institute of Nutrition, Hyderabad, India.

RESULTS

All animals were found apparently healthy during the postoperative phase of the study. Feeding habits and the general activity of the animals were within normal limits. According to Branemark, the healing time of the tissue after fixture insertion has been empirically estimated in large clinical trials in humans at about 3 to 6 months.²

Group A animals (4 weeks). A1 and A2 specimens revealed chronic inflammatory cell formation around screw- and cylinder-type pure titanium metal implants. Small areas of bone necrosis were also seen around the implant site.

Group B animals (6 weeks). B1 and B2 specimens had shown the presence of osteoblastic cell proliferation around the implant and tissue interface. The areas of necrosis and chronic inflammatory cells were not seen.

Group C animals (8 weeks). C1 specimens had shown the presence of a few layers of collagen tissue (CT) around the implant site. The C2 specimen had shown the osteogenesis of bone with osteoblasts lined up toward the implant site. There was no CT formation.

Group D animals (12 weeks). The D1 specimen had shown the presence of osteogenesis of bone with osteoblasts and also collagen tissue (CT) around the implant site. Mature bone (MB) was seen adjacent to the implant site. The D2 specimen had shown the proliferating CT along the bone-implant interface. Osteoblasts were seen adjacent to the collagen matrix.

Group E and F animals (16 weeks). E1 and E2 specimens had shown the young immature and young ordered bone formation (YOB) toward the bone-implant interface, indicating the signs of osseointegration. There was no CT. The MB was

seen adjacent to the early ordered bone. F1 and F2 specimens had shown the presence of new ordered bone formation (YOB) around the implant-bone interface. The MB was adjacent to the YOB (MB). The lamellar bone formation with osteoblasts was seen within the YOB (Figures 3 and 4).

All of the chromium-cobalt control specimens have shown a similar type of histopathological reactions as compared with the indigenously produced pure titanium metal implants used in this study.

DISCUSSION

Generalizations on the various histological aspects of implants are valuable guides in evaluating the success of an intervention and predicting the future of implantology.³ In this study, soft-tissue reactions to the indigenously produced pure titanium were not observed. For analyzing biocompatibility, animal models were used for testing hard-tissue response to implant materials.

In this study, rabbits were used as animal models, which was considered to be adequate for simulating the human bone response to pure titanium implant material. The thickness of the tibial bone of rabbit is sufficient to implant indigenously produced pure titanium metal and also chromium-cobalt alloy test specimens.

The histological observations at 4 weeks revealed the presence of acute and chronic inflammatory cells, small areas of bone necrosis, and an intervening fibroblasts along with inflammatory cells on the screw-type indigenously produced pure titanium metal implant specimen. Similar tissue reactions were observed on the cylinder-type indigenously produced pure titanium test specimen, with significant growth of fibroblasts toward the implant site. The reaction of bone tissue around the 2 cylindrical chromium-cobalt alloy test specimens had shown the presence of chronic inflammatory cells, small areas of necrosis, and CT formation. The necrosis of bone may be due to its functional response, and remodeling of the bone occurs slowly after a few weeks. Eriksson et al¹⁷ suggested that these necrotic zones were insignificant as the bone may remodel slowly following several weeks of implantation.

The histological observations at the 6-week time

point revealed the absence of chronic inflammatory cells with no evidence of bone necrosis around indigenously produced pure titanium and chromium-cobalt alloy test specimens. The most remarkable feature was formation of osteoblasts toward both the screw and cylinder types of indigenously produced pure titanium metal test specimens. The 2 cylinder-type chromium-cobalt test specimens had also shown the presence of osteoblast formation around the implant site. All of these reactions indicate the normal bone healing response toward the implant site. Branemark et al² reported that healing of bone differs from healing of other kinds of tissue in that the injured bone is replaced by healthy bone, leaving the healed site as strong as it was before injury. Basically, inflammation, revascularization, collagen tissue formation, and finally substitution by new bone cells derived are from adjacent endosteum and periosteum.

The histological observation of cross section of the implant site at the 8-week time point had shown the presence of few layers of CT, osteogenesis of the bone with the osteoblasts lined up toward the implant site in screw-type indigenously produced pure titanium implant test specimen. Osteoblast formation with new ordered bone formation was also seen around the cylinder type of indigenously produced pure titanium implant test specimen. The 2 cylinder-type chromium-cobalt alloy test specimens had shown the presence of osteoblastic activity toward the implant site. Linder¹⁸ suggested that osseointegration should be regarded not as an exclusive reaction to a specific implant material but as the expression of a nonspecific and basic healing potential in bone. However, when any foreign material is placed in the bone, the initial tissue response occurs immediately. The acceptance or rejection of any material is predicted by doing histological observations of tissue reactions around the implant-bone interface. Secord and Breck¹⁹ reported the normal healing response of bone to the chromium-cobalt alloy implants.

Histological observations at 12 weeks revealed the formation of new ordered bone around both the screw and cylinder types of pure titanium test specimens. Johansson and Albrektsson,²⁰ in their study of rabbits, and Branemark et al,² in their studies of dogs, have observed true osseointegration around pure titanium implants. Osteogenesis of bone with proliferating osteoblasts and new

ordered bone formation was seen around both cylinder types of chromium-cobalt alloy test specimens. There was slow bone-healing response around chrome-cobalt alloy test specimens from the 4-week to 12-week time points.

Histological observations at the 16-week time point revealed the presence of new ordered bone formation around both screw and cylinder types of indigenous pure titanium metal implant test specimens. Branemark and Albrektsson²¹ have reported the presence of direct bone-to-implant interface contact at the electron microscopic level, thereby suggesting the possibility of direct chemical bonding between bone and pure titanium. Weinlaender²² proposed that for the complete understanding of stimulation of bone growth around dental implants, a thorough knowledge is necessary regarding the reaction of bone to trauma and to a variety of implant materials. Atraumatic preparation of the bone implant bed serves to create the most favorable situation for the formation of bone around implant material. New ordered bone formation is also seen around both cylinder-type chromium-cobalt alloy test specimens. Venable²³ first reported that chromium-cobalt alloy could be considered an acceptable implant material because of its excellent corrosion resistance. The histological study under the stereomicrograph had shown normal bone healing to indigenously produced pure titanium metal implant test specimens over a period of 4 weeks to 16 weeks after implantation. Histological observations of a cross section of the implant site at 16 weeks were suggestive of osseointegration of bone around indigenously produced pure titanium metal implant test specimens. Many studies are still going on to assess the osseointegration of dental implants.²⁴

CONCLUSION

There was ample evidence indicating the bioacceptability of indigenously produced pure titanium dental implant material. There was no variation in tissue reactions to both screw and cylinder types of pure titanium dental implant test specimens. New ordered bone was formed around indigenously produced pure titanium dental implant material over a period of 16 weeks after implantation, suggestive of osseointegration around the bone-implant interface. Results of this research indicate

the suitability and acceptability of indigenously produced pure titanium metal dental implants.

ABBREVIATIONS

CT: collagen tissue
MB: mature bone
YOB: young ordered bone

ACKNOWLEDGMENTS

I express my immense gratitude and indebtedness to my professor and guide, Late B. Sreerama Murthy, for his help, suggestions, and constant encouragement throughout this study. I am thankful to former Lt Gen T. Ravindranath for his kind help in providing the test specimen samples and encouragement for this study. This work was supported by the Institute of Nuclear Medicine and Allied Science, New Delhi, and the Defense Metallurgical Research Laboratory, Hyderabad, which supplied the indigenously produced pure titanium implant specimens for this study. The study was done on rabbits at the Center for Cellular and Molecular Biology, Hyderabad, India. The histological findings of the specimens were done at the National Institute of Nutrition, Hyderabad, India.

REFERENCES

1. Lemans J, Natiellah J. Biomaterials biocompatibility and peri-implant considerations. *Dent Clin North Am.* 1986;30:3–23.
2. Branemark PI, Zarb, Albrektsson T. Tissue integrated prosthesis. In *Osseointegration in Clinical Dentistry*. Chicago, Ill: Quintessence; 1985; 108–113.
3. Leonard LI. *Theories and Techniques of Oral Implantology: Evolution of Dental Implants, Vol 1*. St Louis, Mo: C.V. Mosby; 1970.
4. Parr GR, Kirk GL. Titanium: the mystery metal of implant dentistry: dental Materials aspects. *J Prosthet Dent.* 1985;54:410–414.
5. Garcia DA, Sullivan TM, O'Neill D. The biocompatibility of dental implant materials in an animal model. *J Dent Res.* 1981;60:44–49.
6. Hobo S. *Theory and Practice of Osseointegration: Histological Review*. Chicago, Ill: Quintessence; 1990.
7. Bwayne R. Response of bone marrow to titanium implants: osseointegration and the establishment of a bone marrow-titanium interface in mice. *Int J Oral Maxillofacial Implants.* 1993;8:573–579.
8. Gotredsen K, Rostrup E, Hjørting-Hansen E, Stoltze K, Budtz-Jørgensen E. Histological and histomorphometrical evaluation of tissue reactions adjacent to endosteal implants in monkeys. *Clin Oral Implants Res.* 1991;2:30–37.
9. Ntiellow JR. The use animal model in research on dental implants. *J Dent Educ.* 1998;52:792–795.
10. Mehta RK, Ravindranath T, Khandelwal BL. Indigenously

developed titanium implants: oral and skeletal rehabilitation aids. *IEEE*. 1995;15-18: SPC 29-30.

11. Hobo S. *Theory and Practice of Osseointegration: Histological Review*. Chicago, Ill: Quintessence; 1990.

12. Veneable CS, Stuck WG, Beach A. The effect of bone on the presence of metals based upon electrolysis: experimental studies. *Ann Surg*. 1937;105:917-938.

13. Kenzo A, Norihico K, Osamu O. Mechanical properties and biomechanical compatibility of porous titanium for dental implants. *J Bio Mater Res*. 1985;19:699-713.

14. Listgarten MA, Lang MP, Schroeder HE. Periodontal tissues and their counterparts around endosseous implants. *Clin Oral Implant Res*. 1991;2:1-19.

15. Lum LB, Beirne OR, Dilliges M. Osseointegration of two types of implants in non-human primates. *J Prosthet Dent*. 1998;60:700-705.

16. Perala DG, Ghapman RJ, Gelfand JA, Adams DF. Relative production of IL-1 beta and TNF alpha and mononuclear cells after exposure to dental implants. *J Periodontol*. 1992;63:426-430.

17. Eriksson AR, Albrektsson T. Temperature threshold levels

for heat-induced bone tissue injury: a vital-microscopic study in the rabbit. *J Prosthet Dent*. 1983;50:101-107.

18. Linder L. Osseointegration of metallic implants: light microscopy in the rabbit. *Acta Orthop Scand*. 1989;60:129-134.

19. Secord EW, Breck LW. Report of a case in which vitallium plate could not be removed. *J Bone Joint Surg*. 1940;22:749.

20. Johansson C, Albrektsson T. Integration of screw implants in the rabbit: a 1-year follow-up of removal torque of titanium implants. *Int J Oral Maxillofac Implants*. 1987;2:69-73.

21. Branemark PI, Albrektsson T. *Tissue-Integrated Prosthesis: Osseointegration in Clinical Dentistry*. Chicago, Ill: Quintessence; 1983.

22. Weinlaender M. Bone growth around dental implants. *Dent Clin North Am*. 1991;35:585-601.

23. Venable SC. Three years of experiment with vitallium in bone surgery. *Ann Surg*. 1941;114:309.

24. Park YS, Yi KY, Lee IS, Jung YC. Correlation between the microtomography and histomorphometry for assessment of implant osseointegration. *Clin Oral Implants Res*. 2005;16:156-160.