

# The Effect of Interleukin-1 Allele 2 Genotype (IL-1a<sup>-889</sup> and IL-1b<sup>+3954</sup>) on the Individual's Susceptibility to Peri-Implantitis: Case-Control Study

Ahmed Abd El-Meguid Mostafa Hamdy, DDS\*  
Mohamed Abd El-Moniem Ebrahim, DDS

Individuals bearing the combination of interleukin (IL)-1 allele 2 at IL-1A<sup>-889</sup> and IL-1B<sup>+3954</sup> are referred to as being genotype positive and are susceptible to increased periodontal tissue destruction. The aim of this study was to assess the possible association of IL-1 allele 2 (IL-1A<sup>-889</sup> and IL-1B<sup>+3954</sup>) genotypes with the severity of peri-implantitis progression and the effect of this combination on treatment outcomes. Fifty patients with International Team for Implantology implants were studied; patients ranged in age from 35–55 years, and each patient had 1 implant. According to peri-implant tissue status, patients were divided into 2 groups: group I consisted of 25 patients with peri-implantitis, and group II comprised 25 patients with healthy peri-implant tissue. Clinical parameters were assessed at baseline and after 3 and 6 months. Epithelial cells were collected from the oral mucosa by plastic spatula and were used for IL-1 genotyping by the polymerase chain reaction technique. Group I patients were subjected to a peri-implantitis treatment and maintenance program. In all, 17 patients from group I and 5 patients from group II were genotype positive, with a statistically significant difference noted between the 2 groups. Group I genotype-positive patients presented with higher scores and measurements of clinical parameters with increased suppuration from peri-implant tissues compared with group II; differences were statistically significant ( $P < .05$ ). In terms of response to treatment, genotype-negative patients demonstrated better response than genotype-positive patients. The combination of IL-1 allele 2 (IL-1A<sup>-889</sup> and IL-1B<sup>+3954</sup>) in patients with inflamed periodontal or peri-implant tissues acts as a risk factor that leads to greater tissue destruction. IL-1 gene polymorphism at IL-1A<sup>-889</sup> and IL-1B<sup>+3954</sup> may affect outcomes of treatment for peri-implantitis in genotype-positive individuals.

**Key Words:** IL-1 allele 2 genotype, peri-implantitis, case-control study

Faculty of Dentistry, Minia University, Minia, Egypt.  
\* Corresponding author, e-mail: hamdy.ahmed63@gmail.com  
DOI: 10.1563/AAID-JOI-D-09-00117.1

## INTRODUCTION

**H**ost/parasite interactions may result in periodontal tissue destruction if elevated quantities of inappropriate mediators are released.<sup>1</sup> Among these mediators, cytokines such as interleukin-1 (IL-1) have been shown to play a dominant role in the pathogenesis of periodontitis.<sup>2-5</sup> This cytokine is a primary activator of early chemotactic cytokines, as well as of the expression of adhesion molecules that facilitate migration of leukocytes into tissues. IL-1 is also known to be one of the most active stimulators of osteoclastic bone reabsorption.<sup>6</sup>

Three genes regulate the production of IL-1: IL-1A, IL-1B, and IL-1RN.<sup>7</sup> These genes are located on the long arm of chromosome 2 (2q13). Genes IL-1A and IL-1B control the production of the proinflammatory proteins (IL-1 $\alpha$  and IL-1 $\beta$ ), respectively. IL-1RN controls the synthesis of an antagonist protein (IL-1-ra).<sup>8</sup> Polymorphism in the +3954 locus of the IL-1B gene has been associated with increased production of this cytokine.<sup>8</sup> Polymorphisms of the IL-1 gene cluster have been described as IL-1 alleles. Some of these alleles have been associated with stable interindividual differences in IL-1 levels upon bacterial challenge.<sup>9,10</sup> It has been suggested recently that this polymorphism may explain why some people have a more vigorous response than others to the same stimulus.<sup>11</sup>

A specific genotype characterized by the presence of allele 2 in the polymorphic gene clusters IL-1A (-889) and IL-1B (+3954), also referred to as genotype positive, has been associated with severe chronic periodontitis in a nonsmoking population of certain ethnicities.<sup>12</sup>

Higher IL-1 levels in gingival crevicular fluid and gingival biopsies were detected at shallow sites of genotype-positive patients compared with genotype-negative patients with comparable periodontal status, indicat-

ing that the specific IL-1 genotype may result in an exaggerated local inflammatory response.<sup>13</sup>

In 1997, Kornman et al<sup>14</sup> found an association between polymorphisms in the genes encoding for IL-1A (-889) and IL-1B (+3954) and increased severity of periodontitis. This specific genotype was associated with severity of periodontitis only in nonsmokers, and it distinguished individuals with severe periodontitis from those with mild disease. Functionally, the specific periodontitis-associated IL-1 genotype consists of a variant in the IL-1B gene that is associated with high levels of IL-1 production.<sup>15,16</sup> Many reports have indicated that 86% of patients with severe periodontitis were accounted for by smoking status or by IL-1 genotype.<sup>14,17-20</sup> The composite genotype showed a strong interaction with smoking, whereas nonsmokers, even if genotype positive, were not at increased risk.<sup>21,22</sup> The prognostic utility of the IL-1 genotype in chronic periodontitis progression following surgical and nonsurgical therapy was studied by many authors.<sup>23-27</sup> They reported no significant differences in tooth or attachment loss between those with and those without the genotype.

Oral endosseous implant systems with 2 different healing modalities (submerged and nonsubmerged) have been developed and used successfully for the rehabilitation of partially or completely edentulous patients.<sup>28-30</sup> Knowledge of the biology of osseointegration and peri-implant soft tissue healing has expanded rapidly.<sup>31-34</sup> A comparative study on the beagle dog has provided histologic evidence that peri-implant hard and soft tissues around 1-stage and 2-stage implant systems do not significantly differ with respect to morphology and composition.<sup>35</sup>

Longitudinal evaluation of oral implant systems is important for the assessment of long-term survival and complication rates of

each system. This, in turn, would help in determining factors that affect the success of therapy and in identifying specific problems related to the various implant systems.<sup>36</sup>

Biologic complications in implant dentistry include peri-implant mucositis and peri-implantitis. According to the First European Workshop on Periodontology, peri-implantitis was defined as an inflammatory process affecting the tissues around an osseointegrated implant in function, resulting in loss of supporting bone. Peri-implant mucositis was defined as reversible inflammatory changes in peri-implant soft tissues with no bone loss.<sup>37</sup>

The microflora associated with peri-implantitis is complex and closely resembles that found in chronic periodontitis. Therefore, it is not surprising that therapies proposed for the management of peri-implant disease appear to be based on available evidence for the treatment of periodontitis. Most therapies seek to reduce the bacterial load within the peri-implant pocket, decontaminating the implant surface and in many cases attempting to regenerate bone. Proposed therapies include nonsurgical debridement, antimicrobial therapy, access flap surgery, implant surface decontamination, bone grafts or bone substitute grafts, barrier membranes, combinations of grafts and barrier membranes, and supportive therapy. Treatment outcomes are most commonly assessed using criteria that include peri-implant probing depth (PD), presence of bleeding on probing (BOP), presence of suppuration, and changes in radiographic bone level or density.<sup>38,39</sup>

#### AIM OF THE WORK

The aim of this study was to assess the possible association of IL-1 allele 2 (IL-1A<sup>-889</sup> and IL-B<sup>+3954</sup>) genotype with the severity of peri-implantitis, and the effect of this association on treatment outcomes.

## PATIENTS AND METHODS

### Patient selection

The present study focused on 50 male and female patients whose ages ranged between 35 and 55 years, and who had received International Team for Implantology (ITI) oral implants at least 3 years before the time of the study. Each of the 50 patients had received 1 implant. Patients were selected from the outpatient clinic of the Oral Medicine and Periodontology Department, Faculty of Dentistry. In terms of peri-implant tissue status, patients were divided into 2 groups: group I consisted of 25 patients with ITI implants affected by peri-implantitis, and group II was made up of 25 patients with healthy ITI implants, who acted as a control group.

All patients were informed of the nature and objectives of the study, and their full signed consent was obtained prior to entry into the study. Study investigators complied with the rules set by the International Conference on Harmonisation of Good Clinical Practice Guidelines and the Declaration of Helsinki. The ethics committee of the Faculty of Dentistry, Minia University, approved the study proposal.

The main inclusion criteria were as follows:

1. Patients should be systemically free.
2. Group I patients had to exhibit bleeding on probing of peri-implant tissues, together with probing depth >4 mm with the use of 0.25 N/cm probing force and a 0.4-mm-diameter tip, bone loss around the implant on X ray, mean modified gingival index (mGI) >1.5, and mean modified plaque index (mPLI) >1.5.
3. Patients had to be nonsmokers.
4. Patients had to report no history of antibiotics or periodontal therapy for at least 6 months before the time of this study.

### **Clinical parameters**

Patients in the study were examined and diagnosed with the use of diagnostic clinical parameters, including mPLI and mGI to detect the presence of BOP,<sup>40</sup> PD,<sup>41</sup> and detection of suppuration from 4 sites of each implant. Clinical parameters were recorded at baseline and after 3 and 6 months.

### **Sample collection and DNA extraction**

Epithelial cells were obtained with the use of an oral swab and a sterile plastic spatula. After gentle scraping of the oral mucosa, the tip of the spatula was immediately immersed in 2-mL sterile microtubes containing 1500  $\mu$ L of Krebs buffer (NaCl 20%, KCl 2%, CaCl<sub>2</sub> 2%, H<sub>2</sub>O 2%, MgSO<sub>4</sub>, KH<sub>2</sub>PO<sub>4</sub>, c6H<sub>12</sub>O<sub>6</sub>). Each sample taken from patients was assigned a study code number. These codes were deciphered after statistical analysis had been undertaken. DNA extraction was performed as described by Moreira et al<sup>42</sup>; a pellet of epithelial cells was obtained by centrifugation at 200g for 5 minutes. The supernatant was removed, and 20  $\mu$ L of silica (SiO<sub>2</sub>; Sigma, St Louis, Mo) and 450  $\mu$ L of lysis buffer (6.0 M GuSCN, 65 mM Tris-HCl, pH 6.4, 25 mM ethylenediaminetetraacetic acid [EDTA], and 1.5% Triton X-100) were added to the microtubes. Samples were homogenized with the use of vortex mixing and were incubated for 30 minutes at 56°C. Then, they were submitted to another centrifugation, and the supernatant was discharged. The pellet obtained (with DNA adsorbed on the silica) was washed twice with 450  $\mu$ L of washing buffer (6.0 M GuSCN, 65mM Tris-HCl, pH 6.4), twice with 450  $\mu$ L of 70% ethanol, and once with 450  $\mu$ L acetone, and was dried at 56°C for 20 minutes. Finally, 100  $\mu$ L of TE buffer (10 mM Tris-HCl, pH 8.0, and 1 mM EDTA) was added and incubated at 56°C for 12 hours to release the DNA. After incubation, the solution was homogenized and centrifuged, and the supernatant containing DNA was transferred to a new tube for polymerase chain reaction (PCR) analysis.

### **Polymerase chain reaction and restriction endonuclease digestion**

The IL-1A (−889) and IL-1B (+3954) polymorphisms were assessed by PCR amplification. The sequence of PCR primers for IL-1A (−889) was 5′AAGCTTGTCTACCACCTGAAC-TAGGC3′ and 5′TTACATATGAGCCTCCATG3′ with an expected PCR product size of 99 base pairs (bp). The sequence of PCR primers for IL-1B (+3954) was 5′CTCAGGTGTCCTCGAAGAAATCAA3′ and 5′GCTTTTTTGCTGTGAGT-CCCG3′ with an expected PCR product size of 194 bp. PCR was carried out in a total volume of 50  $\mu$ L, containing 10  $\mu$ L of solution DNA, premix buffer (50 mM KCl, 10 mM Tris-HCl, pH 8.4, 0.1% Triton X-100, 1.5 mM MgCl<sub>2</sub>, deoxynucleoside triphosphates, *Taq* DNA polymerase), and 20 pmol/reaction of the PCR primers. Temperature settings for the PCR reaction consisted of denaturation at 94°C for 3 minutes followed by 35 cycles of annealing at 94°C for 30 seconds, and extension at 54°C for 35 seconds and 72°C for 30 seconds. The run was terminated by a final extension period at 72°C for 5 minutes. Amplification was performed in a PTC-100-60 thermocycler (MJ Research, Waltman, Mass). PCR products were digested with 5 U of *Taq* I DNA polymerase at 65°C for 4 hours. Visualization of PCR products was performed in 10% polyacrylamide gel electrophoresis with the use of ultraviolet light transillumination. Running within each gel, 1 kbp (kilo base pair) DNA size was used as marker for assessment of the PCR product.

### **Treatment of peri-implantitis**

Treatment of peri-implant infection was provided in keeping with the Cumulative Interceptive Supportive Therapy (CIST) protocols.<sup>43</sup> Every implant inserted in patients from group I was subjected to mechanical cleansing using rubber cups and polishing paste. Scaling was performed with the use of acrylic scalers and carbon fiber cures. In addition

TABLE 1  
Clinical data from the 2 patient groups studied\*

	Group I (N = 25)	Group II (N = 25)	P Value
Genotype + ve	17 (68%)	5 (20%)	<.001
Genotype – ve	8	20	
Mean age, y	43 ± 5.51	38.5 ± 5.4	>.05
Age range, y	37–55	35–53	
Sex	20 males 5 female	18 male 7 females	>.05
Number of involved implants	25	25	<.001

\*+ ve indicates positive; – ve, negative.

to mechanical debridement, every patient was instructed to use 10 mL of 0.12% chlorhexidine digluconate as mouth rinse for 30 seconds for 1 month, with local irrigation by 0.2% chlorhexidine. This was done in combination with systemic metronidazole 250 mg plus amoxicillin 375 mg 3 times per day for 10 days.

Each patient was instructed to use a prophylactic maintenance program consisting of the use of a soft toothbrush 3 times daily with regular toothpaste and the use of an interdental toothbrush. Patients continued this maintenance program for 6 months. After 3 and 6 months, patients were reexamined according to the previous clinical parameters.

### Statistical analysis

The  $\chi^2$  test was used to compare genotype distributions in groups I and II. Paired *t* tests were used to compare differences in scores and measurements in clinical parameters at baseline between the 2 groups and between genotype-positive and genotype-negative patients in group I. The  $\chi^2$  test was used to compare changes in the numbers of suppurating sites before and after treatment for peri-implantitis. One-way analysis of variance testing was used to detect differences in scores and measurements of clinical parameters from baseline to 3 and 6 months in the 2 groups. A *P* value <.05 was considered significant.

### RESULTS

The present study focused on 50 patients with ITI dental implants with an age range of 35–55 years. Patients in this study were divided into 2 groups according to peri-implant tissue status. Group I included 25 patients (20 males and 5 females) affected by peri-implantitis. Group II included 25 patients (18 males and 7 females) with healthy peri-implant tissues. The distribution of the combination of the genotypes (IL-1A<sup>-889</sup> and IL-1B<sup>+3954</sup>) (Figures 1 and 2), the mean ages and age ranges, and the sex of patients in the 2 patient groups examined are shown in Table 1. In group I, patient age ranged from 37–55 years, with a mean age of 43 ± 5.51 years; 17 patients (68%) in this group were genotype positive. In group II, patient age ranged from 35–53 years, with a mean age of 38.5 ± 5.4 years; 5 patients (20%) in this group were genotype positive. A statistically significant difference was noted between group I and group II when IL-1 genotype detection was considered.

Means and standard deviations of the clinical parameters in groups I and II at baseline are shown in Table 2. In group I, scores and measures of mGI, mPLI, and PD were 2.71 ± 0.35, 2.51 ± 0.41, and 5.11 ± 0.71, respectively, with 80.8% of sites suppurating. In group II, scores and measures of the same clinical parameters were 1.12 ± 0.12, 1.36 ± 0.06, and 2.8 ± 0.48, respectively, with no suppurating sites in all examined patients. Comparison of means



	mGI	mPLI	PD	Number of Sites Detected for Suppurating (4 sites × 25 implants)	
				+ ve	- ve
Group I	2.71 ± 0.35	2.51 ± 0.41	5.11 ± 0.71	n = 55 sites/17 implants (80.8%)	n = 20 sites/8 implants (62.5%)
Group II	1.12 ± 0.12	1.36 ± 0.06	2.8 ± 0.48		0%
<i>P</i> value	<.05	<.05	<.001		<.001

\*mGI indicates modified gingival index; mPLI, modified plaque index; PD, probing depth.

and standard deviations of the clinical parameters revealed a statistically significant difference between the 2 patient groups ( $P < .05$ ).

Means and standard deviations of the clinical parameters of IL-1 genotype-positive and genotype-negative patients in group I at baseline, and at 3 and 6 months after, are shown in Table 3. Among genotype-positive patients, little difference in clinical parameters from baseline to 6 months was reported; 10.2% reduction was noted in suppurating sites after 3 months, and 10.1% after another 3 months. Comparison of mean scores and measurements of clinical parameters obtained at baseline vs those obtained after 3 and 6 months revealed a statistically nonsignificant difference in mGI and PD, and in the percentage of suppurating sites among genotype-positive patients ( $P > .05$ ). Comparison of mean scores of mPLI obtained at baseline vs those obtained after 3 and

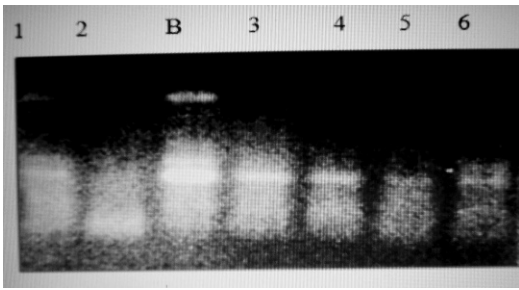
6 months in group I (genotype positive) revealed a statistically significant difference ( $P < .05$ ). When genotype-negative patients were considered, changes in all clinical parameters were reported from baseline to 3 and 6 months after. At baseline, mGI was  $2.54 \pm 0.46$ ; this value changed to  $1.43 \pm 0.12$  and  $1.16 \pm 0.13$  at 3 and 6 months, respectively ( $P < .05$ ). Mean mPLI scores showed changes from  $2.51 \pm 0.34$  at baseline to  $1.15 \pm 0.19$  at 3 months and  $1.09 \pm 0.15$  at 6 months ( $P < .05$ ). Probing depth changed from  $5.35 \pm 0.56$  at baseline to  $4.07 \pm 0.15$  at 3 months and  $2.9 \pm 0.41$  at 6 months ( $P < .05$ ). The number of suppurating sites was reduced from 62.5% at baseline to 8% after 6 months ( $P < .001$ ).

## DISCUSSION

The present study focused on 50 patients who had received ITI oral implants and

	Genotype + ve (n = 17)				Genotype - ve (n = 8)			
	mGI	mPLI	PD	Supp Sites (n = 55)	mGI	mPLI	PD	Supp Sites (n = 20)
Baseline	2.87 ± 0.85	2.76 ± 0.66	5.8 ± 0.75	80.8%	2.54 ± 0.46	2.51 ± 0.34	5.35 ± 0.56	62.5%
3 mo	2.61 ± 0.35	1.56 ± 0.37	5.5 ± 0.72	70.6%	1.43 ± 0.12	1.15 ± 0.19	4.07 ± 0.15	28%
6 mo	2.50 ± 0.41	1.15 ± 0.61	5.11 ± 0.63	60.5%	1.16 ± 0.13	1.09 ± 0.15	2.9 ± 0.41	8%
<i>P</i> value	>.05	<.05	>.05	>.05	<.05	<.05	<.05	<.001

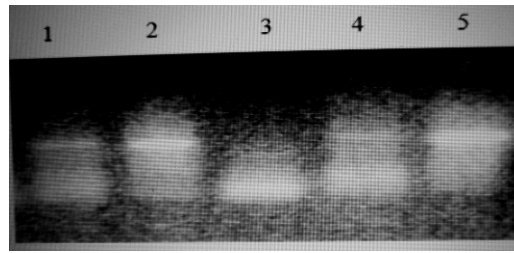
\*mGI indicates modified gingival index; mPLI, modified plaque index; PD, probing depth; Supp, suppurating.



**FIGURE 1.** Polymerase chain reaction (PCR) assay result for interleukin (IL)-A<sup>-889</sup> showing positive assay result at lanes 1, 3, 4, 5, and 6 at 99 base pairs. Lane 2 shows a negative PCR assay result. Lane B represents the reaction in the positive control.

ranged in age from 35–55 years to evaluate the effects of the combination of IL-1A<sup>-889</sup> and IL-B<sup>+3954</sup> genotypes on progression of peri-implantitis and on its treatment outcomes. Patients in the study were classified into 2 groups: Group I included 25 patients affected by peri-implantitis, and group II consisted of 25 patients with healthy peri-implant tissues. Patients in the study were examined with the use of clinical parameters (mGI, mPLI, PD, and detection of suppuration from 4 sites of each implant) and X-ray examination to identify the peri-implant bone level. Peri-implantitis was treated according to the CIST protocols.<sup>43</sup> Each patient was subjected to a preventive maintenance program that lasted for 6 months. Patients were reexamined in terms of the same clinical parameters after 3 and 6 months.

Individuals bearing the combination of IL-1 allele 2 at IL-1A<sup>-889</sup> and IL-1B<sup>+3954</sup> were referred to as being genotype positive and were susceptible to increased periodontal tissue destruction. The prevalence of this combination differed among ethnic groups. This genotype-positive classification has been associated with the detection of higher concentrations of IL-1 in gingival tissues and in inflammatory exudates originating from the marginal periodontium.<sup>14</sup> Results of the present study were consistent with previous observations in that genotype-positive pa-



**FIGURE 2.** Polymerase chain reaction (PCR) assay result for interleukin (IL)-B<sup>+3954</sup> showing positive assay result at lanes 1, 2, 4, and 5 at 194 base pairs. Lane 3 shows negative PCR assay result.

tients had more severe peri-implant tissue destruction and higher scores and measurements of clinical parameters. Although the differences were not significant, they were noted. Moreira et al<sup>42</sup> reported that the occurrence of these 2 functional polymorphisms results in increased production of IL-1 $\alpha$  and IL-1 $\beta$  cytokines, and this plays an important role in the upregulation of a host response resulting in tissue destruction.

Ehmke et al<sup>24</sup> examined the effect of IL-1 composite genotype on nonsurgical therapy of chronic periodontitis. They found that 48% of subjects in the study were genotype positive. They found that no differences in attachment loss were detected between genotype-positive and genotype-negative subjects. Cullinan et al<sup>25</sup> demonstrated an interaction of the IL-1-positive genotype with age, smoking, and the presence of *Porphyromonas gingivalis*, which suggests that IL-1 genotype is a contributory but nonessential risk factor for periodontal disease progression. This was inconsistent with results of the present study, in that differences in clinical parameters were noted between genotype-positive and genotype-negative subjects. Furthermore, although subjects in the present study were all nonsmokers, differences in response to nonsurgical treatment of peri-implantitis were observed between genotype-positive and genotype-negative subjects after 3 and 6 months. This may be due to the age

difference among patients, differences in the levels of *P. gingivalis* in peri-implant tissues, or differences in the duration of peri-implantitis. De Sanctis and Zucchelli<sup>27</sup> showed that genotype expression had a great impact on the long-term stability of guided tissue regeneration treatment. Over a 3-year period, patients with positive IL-1 genotype lost about 50% of the clinical attachment gained in the first year. This was consistent with results of the present study in that genotype-positive subjects reported no improvement in clinical parameters (mGI or PD) and little reduction in suppurating sites.

The microflora associated with peri-implantitis is complex and closely resembles that found in chronic periodontitis. Therefore, therapies proposed for the management of peri-implant disease are based on available evidence for the treatment of periodontitis.<sup>39</sup> In the present study, nonsurgical treatment of peri-implantitis had caused obvious clinical improvement in the status of inflamed tissues in genotype-negative patients. This was evident in the reduction in scores and measures of clinical parameters and may be due mainly to a reduction in the quantity of causative microorganisms.

### CONCLUSION

The combination of IL-1 allele 2 (IL-1A<sup>-889</sup> and IL-1B<sup>+3954</sup>) in patients with inflamed periodontal or peri-implant tissues may act as a risk factor that increases tissue destruction. IL-1 gene polymorphism may have a negative effect on treatment outcomes of peri-implantitis in genotype-positive individuals.

Additional research is needed to assess specific polymorphisms that could be associated with commercially available genetic susceptibility tests and that may be integrated reliably into the daily management of patients receiving implants.

### ABBREVIATIONS

BOP: bleeding on probing  
EDTA: ethylenediaminetetraacetic acid  
IL-1: interleukin-1  
ITI: International Team for Implantology  
mGI: modified gingival index  
mPLI: modified plaque index  
PCR: polymerase chain reaction  
PD: probing depth

### ACKNOWLEDGMENT

The authors would like to express thanks and gratitude to Dr Amal Mahmoud, Lecturer of Clinical Pathology, for conducting the laboratory portion of this study.

### REFERENCES

- Gemmell E, Seymour GJ. Immunoregulatory control of Th1/Th2 cytokine profiles in periodontal disease. *Periodontology* 2000. 2004;35:21–41.
- Masada MP, Persson R, Kenney JS, Lee SW, Page RC, Allison AC. Measurement of interleukin-1 alpha and -1 beta in gingival crevicular fluid: implications for the pathogenesis of periodontal disease. *J Periodont Res*. 1990;25:156–163.
- Salvi GE, Yalda B, Collins JG, et al. Inflammatory mediator response as a potential risk marker for periodontal diseases in insulin-dependent diabetes mellitus patients. *J Periodontol*. 1997;68:127–135.
- Figueredo CM, Ribeiro MS, Fischer RG, Gustafsson A. Increased interleukin-1beta concentration in gingival crevicular fluid as a characteristic of periodontitis. *J Periodontol*. 1999;70:1457–1463.
- Graves DT, Cochran D. The contribution of interleukin-1 and tumor necrosis factor to periodontal tissue destruction. *J Periodontol*. 2003;74:391–401.
- Lang NP, Tonetti MS, Suter J, Sorrell J, Duff GW, Kornman KS. Effect of interleukin-1 polymorphisms on gingival inflammation assessed by bleeding on probing in a periodontal maintenance population. *J Periodont Res*. 2000;35:102–107.
- Nicklin MJ, Weith A, Duff GW. A physical map of the region encompassing the human interleukin 1 alpha, beta and the interleukin 1 receptor antagonist genes. *Genomics*. 1994;19:382–384.
- Greenstein G, Hart TC. A critical assessment of interleukin-1 (IL-1) genotyping when used in a genetic susceptibility test for severe chronic periodontitis. *J Periodontol*. 2002;73:231–247.
- Mølviq J, Baek L, Christensen P, et al. Endotoxin stimulated human monocyte secretion of interleukin 1, TNF alpha, and prostaglandin E2 shows stable inter individual differences. *Scand J Immunol*. 1988;27:705–716.
- Pociot F, Mølviq J, Wogensen L, Worsaae H, Nerup J. A Taq I polymorphism in the human



interleukin 1 beta gene correlates with secretion in vitro. *Eur J Clin Invest.* 1992;22:396–402.

11. Armitage GC, Wu Y, Wang HY, Sorell J, Di Giovine FS, Duff GW. Low prevalence of a periodontitis-associated interleukin-1 composite genotype in individuals of Chinese heritage. *J Periodontol.* 2000;71:164–171.

12. Kornman KS, Crane A, Wang HY, et al. The interleukin-1 genotype as a severity factor in adult periodontal disease. *J Clin Periodontol.* 1997;24:72–77.

13. Engebretson SP, Lamster IB, Herrera-Abreu M, et al. The influence of interleukin gene polymorphism on expression of interleukin-1beta and tumor necrosis factor-alpha in periodontal tissue and gingival crevicular fluid. *J Periodontol.* 1999;70:567–573.

14. Kornman KS, Crane A, Wang HY, di Giovine FS, Newman MG, Pirk FW. The interleukin-1 genotype as a severity factor in adult periodontal disease. *J Clin Periodontol.* 1997;24:72–77.

15. Pociot F, Molvig J, Wogensen L, Worsaae H, Nerup J. A *TaqI* polymorphism in the human interleukin-1 beta (IL-1 beta) gene correlates with IL-1 beta secretion in vitro. *Eur J Clin Invest.* 1992;22:396–402.

16. Pociot F, Briant L, Jongeneel CV, Molvig J, Worsaae H, Abbal M. Association of tumor-necrosis-factor (TNF) and class-II major histocompatibility complex alleles with the secretion of TNF-alpha and TNF-beta by human mononuclear-cells—a possible link to insulin-dependent diabetes-mellitus. *Eur J Immunol.* 1993;23:224–231.

17. McDevitt MJ, Wang HY, Knobelmann C, Newman MG, di Giovine FS, Timms JM. Interleukin-1 genetic associations with periodontitis in clinical practice. *J Periodontol.* 2000;71:156–163.

18. McGuire MK, Nunn ME. Prognosis versus actual outcome. IV. The effectiveness of clinical parameters and IL-1 genotype in accurately predicting prognoses and tooth survival. *J Periodontol.* 1999;70:49–56.

19. Laine ML, Farre MA, Gonzalez G, van Dijk LJ, Ham AJ, Winkel EG. Polymorphisms of the interleukin-1 gene family, oral microbial pathogens, and smoking in adult periodontitis. *J Dent Res.* 2001;80:1695–1699.

20. Gore EA, Sanders JJ, Pandey JP, Palesch Y, Galbraith GM. Interleukin-1beta+3953 allele 2: association with disease status in adult periodontitis. *J Clin Periodontol.* 1998;25:781–785.

21. Meisel P, Siegemund A, Dombrowa S, Sawaf H, Fanghaenel J, Kocher T. Smoking and polymorphisms of the interleukin-1 gene cluster (IL-1alpha, IL-1beta, and IL-1RN) in patients with periodontal disease. *J Periodontol.* 2002;73:27–32.

22. Kinane DF, Hodge PJ, Eskdale J, Ellis R, Gallagher G. Analysis of genetic polymorphisms at the interleukin-10 (IL-10) and tumour necrosis factor (TNF) loci in early-onset periodontitis. *J Periodontol Res.* 1999;34:1–8.

23. Papapanou PN, Neiderud AM, Sandros J, Dahlen G. Interleukin-1 gene polymorphism and periodontal status: a case-control study. *J Clin Periodontol.* 2001;28:389–396.

24. Ehmke B, Kress W, Karch H, Grimm T, Klaiber B, Fleming TF. Interleukin-1 haplotype and periodontal disease progression following therapy. *J Clin Periodontol.* 1999;26:810–813.

25. Cullinan MP, Westerman B, Hamlet SM, Palmer JE, Faddy MJ, Lang N. A longitudinal study of interleukin-1 gene polymorphisms and periodontal

disease in a general adult population. *J Clin Periodontol.* 2001;28:1137–1144.

26. Cattabriga M, Rotundo R, Muzzi L, Nieri M, Verrocchi G, Cairo F. Retrospective evaluation of the influence of the interleukin-1 genotype on radiographic bone levels in treated periodontal patients over 10 years. *J Periodontol.* 2001;72:767–773.

27. De Sanctis M, Zucchelli G. Interleukin-1 gene polymorphisms and long-term stability following guided tissue regeneration therapy. *J Periodontol.* 2000;71:606–613.

28. Karoussis IK, Müller S, Salvi GE, Heitz-Mayfield LJA, Brägger U, Lang NP. Association between periodontal and periimplant conditions: a 10-year prospective cohort study of the ITI Dental Implant System. *Clin Oral Implants Res.* 2004;15:1–7.

29. Karoussis IK, Salvi GE, Heitz-Mayfield LJA, Brägger U, Hämmerle CHF, Lang NP. Long-term implant prognosis in patients with and without a history of chronic periodontitis: a 10-year prospective cohort study of the ITI Dental Implant System. *Clin Oral Implants Res.* 2003;14:329–339.

30. Levine RA, Clem D, Beagle J. Multicenter retrospective analysis of the solid-screw ITI implant for posterior single-tooth replacements. *Int J Oral Maxillofac Implants.* 2002;17:550–556.

31. Berglundh T, Abrahamsson I, Lang NP, Lindhe J. De novo alveolar bone formation adjacent to endosseous implants: a model study in the dog. *Clin Oral Implants Res.* 2003;14:251–262.

32. Botticelli D, Berglundh T, Buser D, Lindhe J. Appositional bone formation in marginal defects at implants: an experimental study in the dog. *Clin Oral Implants Res.* 2003;14:1–9.

33. Botticelli D, Berglundh T, Buser D, Lindhe J. The jumping distance revisited: an experimental study in the dog. *Clin Oral Implants Res.* 2003;14:35–42.

34. Wennerberg A, Sennerby L, Kulteje C, Lekholm U. Some soft tissue characteristics at implant abutments with different topography: a study in humans. *J Clin Periodontol.* 2003;30:88–94.

35. Abrahamsson I, Berglundh T, Wennström J, Lindhe J. The periimplant hard and soft tissues at different implant systems: a comparative study in the dog. *Clin Oral Implants Res.* 1996;7:212–219.

36. Salvi GE, Lang NP. Diagnostic parameters for monitoring peri-implant conditions. *Oral Maxillofac Implants.* 2004;19(suppl):116–127.

37. Albrektsson T, Isidor F. Consensus report of session IV. In: Lang NP, Karring T, eds. *Proceedings of the First European Workshop on Periodontology.* London: Quintessence; 1994:365–369.

38. Ericsson I, Berglundh T, Marinello C, Liljenberg B, Lindhe J. Long-standing plaque and gingivitis at implants and teeth in the dog. *Clin Oral Implants Res.* 1992;3:99–103.

39. Schou S, Holmstrup P, Jorgensen T. Implant surface preparation in the surgical treatment of experimental peri-implantitis with autogenous bone graft and ePTEE membrane in cynomolgus monkeys. *Clin Oral Implants Res.* 2003a;14:412–422.

40. Mombelli A, Van Oosten MAC, Schurch E, Lang NP. The microbiota associated with successful or failing osseointegrated titanium implants. *Oral Microbiol Immunol.* 1987;2:145–151.

41. Bragger U, Hugel-Pisoni C, Burgin WB, Buser D, Lang NP. Correlations between radiographic, clinical

and mobility parameters after loading of oral implants with fixed partial dentures. *Clin Oral Implants Res.* 1996;7:230–239.

42. Moreira PR, De Sa AR, Xavier GM, Costa JE, Gollob KJ, Dutra WO. A functional interleukin-1B gene polymorphism is associated with chronic periodontitis

in a sample of Brazilian individuals. *J Periodont Res.* 2005;40:306–311.

43. Lang NP, Wilson TG, Corbet EF. Biological complications with dental implants; their prevention, diagnosis and treatment. *Clin Oral Implants Res.* 2000;11(suppl):146–155.