

Osseointegrated Implant Fracture: Causes and Treatment

Walter Cristiano Gealh, DDS, MSc^{1*}

Valéria Mazzo, DDS²

Francisco Barbi, DDS, MSc³

Edevaldo Tadeu Camarini, DDS, PhD³

Despite its high success rate, therapy with osseointegrated dental implants is not free of complications. Among the problems that may occur is fracture of implants, which, albeit a rare phenomenon, may lead to unpleasant clinical outcomes for the patient, as well as for the clinician. Thus, it is paramount to know the factors related to the biological processes involved in maintenance of osseointegration and biomechanics applied to dental implants to prevent such complications, as well as treatment options available to deal with the problem. Therefore, the objectives of this work were to investigate the literature to identify causative factors that may lead to fracture of dental implants and to discuss available procedures.

Key Words: *implant fracture, bone resorption, occlusal loads, parafunctional forces, metal fatigue*

INTRODUCTION

Osseointegrated dental implants represent an advance in modern odontology, which has become an interesting option for the rehabilitation of missing single teeth in partially or totally edentulous patients, with very high success rates.¹ Despite this, complications associated with treatment with implants may occur, and failure may be divided into two categories: early failure, which tends to occur before the prosthetic phase of treatment takes place and is mainly related to surgical problems that occur during implant placement; and late failure, which can arise from pathologic

events involving an implant that has already osseointegrated.²

In some situations, one of the most serious complications to be faced is the fracture of implants. It is a frustrating problem not only for the patient but also for the clinician, because it usually involves loss of both the implant and the prosthesis. Thus, the objective of this work was to investigate possible causes that may lead to fracture of dental implants, as well as options available for treatment.

BACKGROUND

Fracture of dental implants is a rare phenomenon. According to Balshi,³ only 0.2% of 4045 placed implants presented with fracture during 5 years of function. Data from a study carried out by Adell,¹ in which 4636 implants were employed, revealed an average total fracture rate of less than 5%, 6% in

¹ Araçatuba Dentistry School, UNESP-Univ Estadual Paulista, São Paulo, Brazil.

² Private practice.

³ Maringá State University, Parana, Brazil.

*Corresponding author, e-mail: gealh@bol.com.br

DOI: 10.1563/AAID-JOI-D-09-00135.1

the maxilla, and 3% in the mandible after 15 years of follow-up. Eckert⁴ reported that among 4937 implants, the fracture rate was just 0.6%, with no statistically significant difference noted between the arches.

Causes of implant fracture may be divided into 3 categories: (1) defects in the design of the material, (2) nonpassive fit of the prosthetic structure, and (3) biomechanical or physiologic overload.³ Possible causes of fracture include failure in the production and design of dental implants, bruxism or large occlusal forces, superstructure design, implant localization, implant diameter, metal fatigue, and bone resorption around the implant.⁵ In addition, the galvanic activity of metals used in prosthetic restorations can be cited as a cause.⁶

Defects in the production and design of dental implants are very unlikely reasons for fracture. Microscopic analysis of fractured fixtures revealed no porosity or any other defects in the titanium structure, a finding that eliminated failure in the manufacturing process as causative.^{3,7}

The stress caused by retaining screws of prostheses with a nonpassive fit may result in constant tension on the implant, predisposing it to fracture. Often, screw loosening precedes implant fracture and may be a warning sign that the prosthetic structure needs to be reassessed (Figure 1).^{3,4} According to Schwarz,⁸ on the trail of screw loosening, metal fatigue occurs, which may result in implant fracture.

Load factors are related to the magnitude and direction of occlusal forces. Ninety percent of dental implant fractures are located in the molar and premolar regions of the mouth, where chewing forces and lateral movements associated with cusp inclination generate undesirable forces.⁹ Chewing occlusal forces when in function are 3 times more intense in the posterior region than in the anterior region.¹⁰ Chewing involves vertical forces mainly; however,

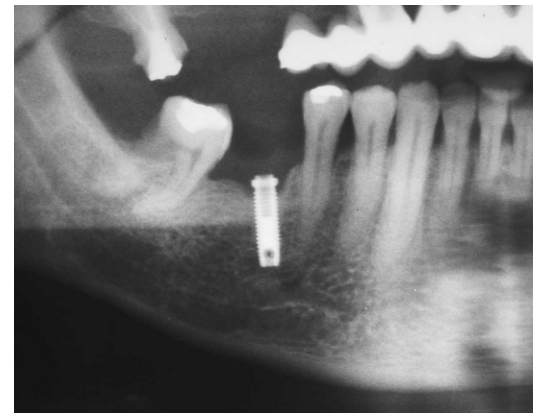


FIGURE 1. Bone loss around 3.75-mm osseointegrated implant in molar area. Screw loosening and fracture had occurred before this.

horizontal movement of the mandible and the inclination of the dental cusps create lateral forces that are transferred to the implant and to the bone.⁹

Biomechanical and physiologic overload seems to be the most common cause of dental implant fracture; overload may be caused primarily by two factors: parafunctional habits and prosthesis design.³ Parafunctional habits such as bruxism or clenching may increase overload on the implant/prosthesis system through the magnitude, duration, frequency, and direction of forces applied. According to Rangert,¹¹ around 56% of patients with fractured dental implants presented with bruxism and marked occlusal forces. Parafunctional habits have been identified as the major causative factor associated with fixture fractures.³

In any clinical situation, the presence of an extension or cantilever considerably increases the load on implants.¹² Shackleton and Slabbert¹³ studied the existence of a relationship between survival time span of implant-supported prostheses and the length of their posterior cantilever extensions. They concluded that short cantilevers provide longer survival rates and recommended the use of mandibular extensions for a maximum of 15 mm. According to Rangert et al,⁹ good mandibular bone

quality allows the use of cantilevers that measure 15–20 mm in length, whereas porous maxillary bone should not support cantilevers longer than 10 mm. It has been suggested that posterior cantilevers should be avoided or minimized, especially in partially edentulous patients.³

The localization position of dental implants also has a direct influence on the biomechanical distribution of forces. If the implant axis is placed at a certain distance from the center of the prosthetic crown, forces created by this distance from the occlusal contact point to the implant axle may cause screw loosening or component fracture. Nevertheless, in cases of fixed prostheses, if this compensation is part of a tripod organization, conditions may become favorable.¹² The installation plan for implants must, whenever possible, avoid configuration in a straight line.^{3,11}

The addition of a third implant in a free end region, to prevent the use of cantilevers, reduces stress forces in approximately two-thirds of cases. Yet, when these implants are placed in a nonlinear geometric configuration, overload on the implant/prosthesis system is reduced 6-fold, compared with prostheses with cantilevers.¹¹

Implants with small diameters tend to fracture more easily than those with large diameters, especially when placed in the posterior region.⁵ According to Krogh,¹⁴ among the causes of implant fracture are standard implants used in the molar region. In an implant of 3.75 mm diameter, just 0.4 mm corresponds with the thickness of the titanium wall. Therefore, implants that are 5 and 6 mm in thickness are 3 and 6 times more resistant, respectively, than standard implants.¹⁵ However, Rangert et al¹¹ point out that sturdier implants will not solve the problem of overload, but will simply transfer these forces to other, less resistant points (retaining screws) or to surrounding bone.

Through a microscopic analysis, Piattelli⁷ found fatigue grooves in all fractured implants. The high stresses needed to initiate and propagate fissures in dental implants seem to be the result of three conditions: cross-sectional variations in the implant, stress concentration in the screw threads, and peri-implant bone resorption.⁵ Variations in the section of an implant occur when the abutment screw is short, creating a hollow space. Despite the fact that Beaty¹⁶ mentioned that grade 1 titanium implants have approximately half the tensile force of grade 3 titanium implants, Rangert et al¹¹ suggest that this increase has a limited influence on fatigue behavior.

According to Tonetti and Schmid,² bone loss around implants may occur as the result of rupture of the biomechanical balance and/or host/parasite balance. Biomechanical unbalance is caused by loads that are dissipated around the implant and go beyond the bone functional adaptation capacity. On the other hand, host/parasite unbalance corresponds to superficial (peri-implant mucositis) and deep (peri-implantitis) inflammatory alterations that lead to marginal bone loss. In a significant number of patients who present with dental implant fracture, a characteristic bone loss pattern is evident, with a radiolucent image around the coronal portion of the implant in a "V" shape (Figure 2).¹¹ This bone resorption submits the implant to high stress forces caused by support tissue loss, normally located at the end of the abutment screw level, where resistance to tension forces is reduced.^{11,17}

In the analyses carried out by Green,⁵ it was observed that bone loss may be intensified by the release of cytotoxic ions from nonprecious metal alloys used in the prosthetic superstructure in direct contact with the implant, which, in the presence of oral fluids, produce galvanic currents, leading to corrosion of non-noble metals and contributing to bone loss around the implant.

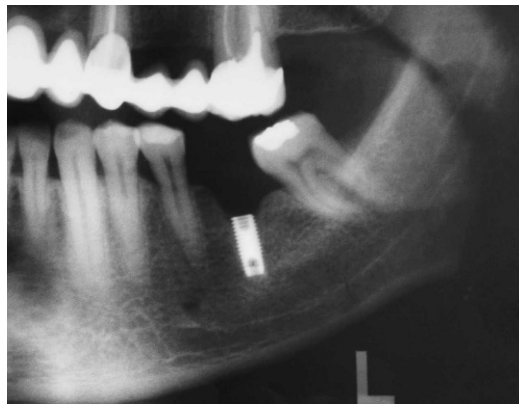


FIGURE 2. Typical bone loss around fractured implant.

Balshi³ suggests three methods for treating fractures of dental implants: (1) removal of the fractured implant (replace the implant and manufacture a new prosthesis), (2) alteration of the existing prosthesis and maintenance of the osseointegrated fractured part, and (3) alteration of the fractured implant and remanufacturing of the prosthetic portion.

Treatment of fractured implants represents a clinical challenge. First, the fractured fragment must be atraumatically removed with minimum bone removal. A new fixture is placed and the time to osseointegration must pass; only after that, the prosthetic phase begins.⁶

It is suggested that, for removal of the intraosseous portion of a dental implant, a trephine bur should be used, and, if possible, another implant with a larger diameter should be installed immediately.^{6,14}

DISCUSSION

Despite the fact that implant therapy has been consolidated with high success rates, as demonstrated in a study by Adell,¹ problems may arise with this type of treatment. Despite its low incidence, consensus in the literature suggests that one of the possible complications that may occur with dental implants is fracture, and treat-

ment represents a serious challenge to clinicians.^{1,3,5,11}

Implant diameter also has a direct influence on the occurrence of fracture, in that dental implants with small diameters have reduced resistance to fatigue. In several of the cases analyzed, fracture took place in implants with reduced (3.5 mm) or standard (3.75 mm) diameters.^{3,4,6,7} Therefore, Eckert,⁴ Rangert et al,¹¹ Krogh,¹⁴ Graves,¹⁵ and Beaty¹⁶ describe the advantages of dental implants with large diameters and advise their use whenever possible, especially in the mandibular and maxillary posterior regions, where most fractures take place.

Adequate prosthetic planning is fundamental to reduce dental implant fracture rates even further. Biomechanical factor, besides achieving a passive fit of the prosthetic superstructure, must be taken into consideration from the moment implants are placed until prostheses are installed.^{3,9,11}

Cantilevers act as crowbars, generating tension in the fixtures and making them susceptible to fracture, especially in the posterior regions of the mouth.¹³ In this situation, whenever possible, the number of implants must be increased, and their placement in a straight-line configuration must be avoided.^{3,5,11} Frequent loosening or fracture of the retaining screws and bone loss around the implant are characteristic signs that precede the fracture of implants.^{3,7,9,11}

It is understood that bone resorption is a consequence of several adverse factors to which the implant/prosthesis system is exposed. Bone loss will increase the cantilever effect with the consequent increase in tension forces, generating stress in the thread portion of the implant, where a hollow cylinder is normally found along with greater fragility, resulting in metal fatigue.^{3,5,7,9,11}

Among the treatment options mentioned by Balshi,³ removal of the fractured implant followed by placement of a new one is the choice of most authors.^{6,7,14}

To reduce the possibility of bone resorption, regular monitoring is essential. Clinical assessment can confirm whether the occlusion is well balanced and the load is well distributed on the dental implants. It is fundamental to include routine radiographic examinations to observe bone loss related to stress caused by overload.¹⁷ Rangert⁹ suggested the following sequence: If the prosthesis retaining screw fractures or loosens frequently (even though it had been adequately tightened), precision in prosthetic structure fit may be insufficient. The structure adaptation should be reassessed before any other measure is taken. In cases of correct adaptation of the implant/prosthesis system, overload should be suspected. Thus, cantilever length and the design, occlusion, and position of implants must be reassessed. Cantilever length reduction, prosthetic crown size reduction, cusp inclination rectification, and occlusal contact centralization, as well as consideration of the addition of extra implants and subsequent manufacturing of a new prosthesis, may constitute the range of appropriate measures in most situations.¹¹

CONCLUSION

After this review of the literature, it is possible to conclude that fracture of osseointegrated dental implants is a late complication that, despite its low incidence, is highly frustrating. Causes attributed to the fracture of dental implants are multifactorial. Treatment of implant fractures usually consists of removal of the fractured fragment, installation of another implant, and the manufacture of another prosthesis.

REFERENCES

1. Adell R, Eriksson B, Lekholm U, Branemark PI, Jemt T. A long-term follow-up study of osseointegrated implants in the treatment of totally edentulous jaws. *Int J Oral Maxillofac Implants.* 1990;5:347–358.
2. Tonetti MS, Schmid J. Pathogenesis of implant failures. *Periodontol 2000.* 1994;4:127–138.
3. Balshi TJ. An analysis and management of fractured implants: a clinical report. *Int J Oral Maxillofac Implants.* 1996;11:660–666.
4. Eckert SE, Meraw SJ, Cal E, Ow RK. Analysis of incidence and associated factors with fractured implants: a retrospective study. *Int J Oral Maxillofac Implants.* 2000;15:662–667.
5. Green NT, Machtei EE, Horwitz J, Peled M. Fracture of dental implants: literature review and report of a case. *Implant Dent.* 2002;11:137–143.
6. Muroff FI. Removal and replacement of a fractured dental implant: case report. *Implant Dent.* 2003;12:206–210.
7. Piatelli A, Piatelli M, Scarano A, Montesani L. Light and scanning electron microscopic report of four fractured implants. *Int J Oral Maxillofac Implants.* 1998;13:561–564.
8. Schwarz MS. Mechanical complications of dental implants. *Clin Oral Implants Res.* 2000;11(suppl):156–158.
9. Rangert B, Jemt T, Jorneus L. Forces and moments on Branemark Implants. *Int J Oral Maxillofac Implants.* 1989;4:241–247.
10. Traiani T, Paoli SD, Caputi S, Lezzi G, Piatelli A. Collagen fiber orientation near a fractured dental implant after a 5 year loading period: case report. *Implant Dent.* 2006;15:70–74.
11. Rangert B, Krogh PHT, Langer B, Roedel NV. Bending overload and implant fracture: a retrospective clinical analysis. *Int J Oral Maxillofac Implants.* 1995;10:326–333.
12. Renouard F, Rangert B. *Fatores de Risco em Implantodontia: Planejamento Clínico Simplificado para Prognóstico e Tratamento.* São Paulo: Quintessence; 2001. [In Portuguese]
13. Shackleton J, Slabbert JCG. Survival of fixed implant supported prostheses related to cantilever lengths. *J Prosthet Dent.* 1994;71:23–26.
14. Krogh P. Surgical and biomechanical advantages of large-diameter implants. In: Siddiqui AA, Caudill R. Proceedings of the Fourth International Symposium on Implant Dentistry: Focus on Esthetics; January 27 through 29, 1994; San Diego, CA. *J Prosthet Dent.* 1994;72:623–634.
15. Graves S. Surgical and biomechanical advantages of large-diameter implants. In: Siddiqui AA, Caudill R. Proceedings of the Fourth International Symposium on Implant Dentistry: Focus on Esthetics; January 27 through 29, 1994; San Diego, CA. *J Prosthet Dent.* 1994;72:623–634.
16. Beaty K. Surgical and biomechanical advantages of large-diameter implants. In: Siddiqui AA, Caudill R. Proceedings of the Fourth International Symposium on Implant Dentistry: Focus on Esthetics; January 27 through 29, 1994; San Diego, CA. *J Prosthet Dent.* 1994;72:623–634.
17. Rangert MJ, James DF, Pilliar RM. Fractures of the fixture components of an osseointegrated implant. *Int J Oral Maxillofac Implants.* 1993;8:409–414.