

# Edentulous Maxillary Arch Fixed Implant Rehabilitation Using a Hybrid Prosthesis Made of Micro-Ceramic-Composite: Case Report

Onur Geckili, PhD, DDS\*  
Hakan Bilhan, PhD, DDS  
Gulsum Ceylan, PhD, DDS  
Altug Cilingir, PhD, DDS

The prosthetic treatment of patients with an edentulous maxilla opposing mandibular natural teeth is one of the most challenging endeavors that face clinicians. Occlusal forces from the opposing natural teeth may cause fractures in the maxillary prosthesis and also result in advanced bone loss of the edentulous maxilla. With the presence of extreme gagging reflex, the treatment may become more complicated. This article describes and illustrates the 2-stage surgical and prosthetic treatment of a patient with an edentulous maxilla opposing natural teeth. In the beginning, the patient was treated with 4 implants and a maxillary implant-supported overdenture. The extreme gagging reflex and the occlusal forces from the mandibular natural teeth obligated the team a second stage surgical and prosthetic treatment, which included increasing the number of implants after bilateral sinus lifting in the posterior maxilla and fabricating a maxillary fixed hybrid prosthesis made of micro-ceramic composite that yielded a satisfactory result.

**Key Words:** *hybrid prosthesis, dental implant, sinus floor elevation*

## INTRODUCTION

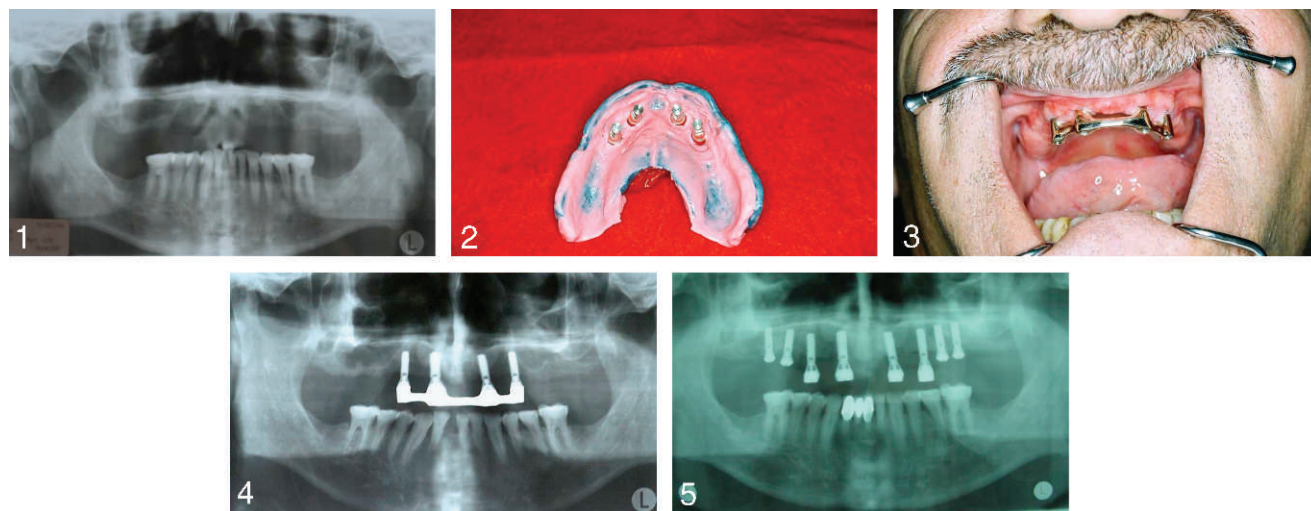
Patients with an edentulous maxilla opposing mandibular natural teeth may experience problems with maxillary complete dentures (MCD).<sup>1,2</sup> The ability of the patient to generate heavy occlusal forces due to the existence of opposing natural teeth may cause the implacable fractures on the MCD.<sup>2-4</sup> It is assumed by several authors that there may be an association of the unsuitability of the denture bearing tissues to resist high occlusal forces from the opposing natural teeth and advanced bone loss of the residual alveolar ridges.<sup>1,2</sup> In addition, malpositions of the opposing natural teeth decrease the stability and may cause loosening

of the MCD.<sup>1-3</sup> Other rarely seen factors such as an extreme gagging reflex may also influence the treatment outcomes.<sup>5</sup> The exaggerated gag reflex is a somatic natural response in which the body attempts to eliminate instruments or agents from the oral cavity by muscle contraction at the base of the tongue and the pharyngeal wall.<sup>6</sup> The patient who gags may present with a range of disturbing reactions, from simple contraction of palatal or circumoral musculature to spasm of the pharyngeal structures, together with vomiting.<sup>6,7</sup> Overextended borders of a prosthesis, particularly the posterior aspect of the MCD can impinge on the "trigger zones" and produce gagging.<sup>6</sup> Some patients cannot tolerate any foreign subject from entering the oral cavity even if the denture does not have overextended borders.<sup>7</sup> Dental implants offer an effective rehabilitative treatment for the patients with an edentulous maxilla opposing mandibular natural teeth. With the use of implant-supported

Faculty of Dentistry, Department of Prosthodontics, Istanbul University, Istanbul, Turkey.

\* Corresponding author, e-mail: geckili@istanbul.edu.tr

DOI: 10.1563/AAID-JOI-D-10-00040



**FIGURES 1–5.** **FIGURE 1.** Panoramic radiograph of the patient prior to the treatment. **FIGURE 2.** The view of the impression for fabrication of the maxillary overdenture. **FIGURE 3.** The intraoral view of the fabricated Hader bar tried. **FIGURE 4.** The view of panoramic radiograph 1 year after the delivery of the maxillary overdenture. **FIGURE 5.** The view of panoramic radiograph after sinus lifting and increasing the number of implants.

prosthesis, progress in masticatory function, retention and stability, and preservation of the alveolar bone have been reported.<sup>8–11</sup> Benefits from the construction of a maxillary implant-supported prosthesis opposing natural teeth instead of MCD are also the inevitable consecutive drops in the fracture rate of maxillary prosthesis because of the increased chewing efficiency and the distribution of the occlusal forces throughout the maxillary arch.<sup>12,13</sup> In addition, the palatal border of the maxillary implant-supported prosthesis can be finished shorter, yet more of the palate can be left totally open compared to the MCD, which in turn reduces or eliminates the gagging reflex of the patients.<sup>6,7</sup> Several designs of prostheses can be used to restore the edentulous maxilla with implant-supported fixed or removable prosthesis.<sup>14</sup> When assessing the outcomes of oral implant therapy for the maxilla, implant survival, anatomic conditions, prosthesis longevity, and the frequency of complications are the most significant parameters that should be judged.<sup>14,15</sup>

In the atrophic maxilla, fixed hybrid prosthesis has been reported to be superior to fixed metal ceramic restorations in providing lip support, phonetics, and esthetics.<sup>16–18</sup> The esthetic material used upon the metal framework of hybrid prosthesis can be acrylic or porcelain.<sup>13,18</sup> Micro-ceramic composites are recently developed resins containing silanized microhybrid inorganic filler embedded in a light-polymerizable organic matrix and can be

an alternative to these materials because of their improved wear resistance, the degree of conversion, water absorption, polymerization shrinkage, and high fracture strength.<sup>19,20</sup>

The purpose of this case report is to demonstrate the efficiency of the micro-ceramic composite in the treatment of a patient with an atrophic maxilla and natural mandibular teeth, and additionally demonstrate the hybrid prosthesis as a valuable alternative for patients with an intense gagging reflex.

#### CLINICAL REPORT

A 62-year-old man presented with an edentulous maxillary and a dentate mandibular arch to a university clinic for prosthetic treatment. The patient reported extreme difficulties in using a maxillary complete denture because of gagging and repeated fracture problems. A clinical examination and a radiographic assessment were conducted and revealed an edentulous maxilla with bilateral sinus cavity enlargement and severe alveolar bone resorption in the posterior region and a fully dentate mandible except for a mandibular right central incisor (Figure 1).

Various treatment alternatives such as conventional and implant-supported fixed or removable prosthodontic options were discussed. The main desire of the patient was receiving a fixed maxillary

denture. However, he was opposed to the sinus lifting procedure, which was essential for fabricating a fixed prosthesis. So, the final decision was an implant-retained maxillary overdenture fabrication following the insertion of 4 implants in the anterior maxilla.

The patient received 4 endosseous dental implants ( $3.3 \times 12$  mm, Straumann, Waldenburg, Switzerland) in the maxillary lateral and first premolar regions by an experienced oral surgeon, who performed the implant surgery according to the guidelines of the manufacturer. Three months after the surgery, the maxillary impression was made with a polyether impression material (Impregum soft, 3M ESPE, St Paul, Minn) in the company of open tray synOcta impression copings (Straumann), and the mandibular impression was made with irreversible hydrocolloid (Alginoplast, Heraeus Kulzer, Hanau, Germany). Implant analogs (Straumann) were attached to the completed maxillary impression (Figure 2) before pouring the impressions in type IV dental stone (Moldano, Heraeus Kulzer). The synOcta abutments (Straumann) were screwed into the analogs and a maxillary Hader bar was fabricated and tried in the mouth for accuracy (Figure 3).

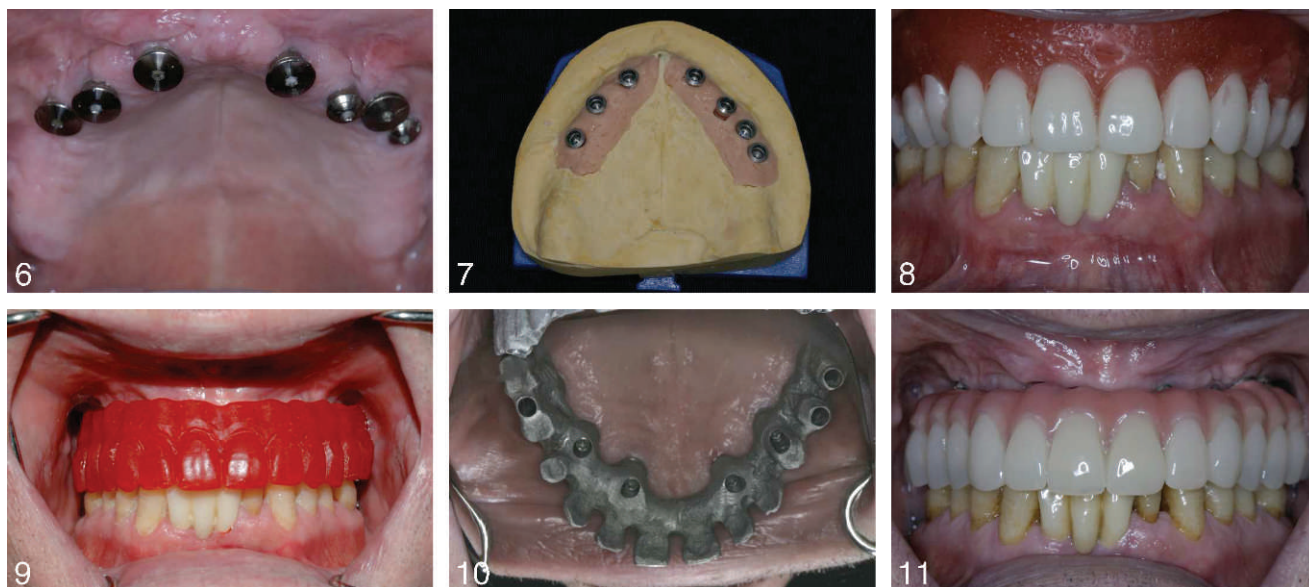
After obtaining horizontal and vertical maxillo-mandibular records with record bases and occlusion rims, the casts were transferred to a semi-adjustable articulator (IML ARTI S4, IML-Instrumenta Mechanik Labor System GmbH, Wiesloch, Germany). Artificial teeth (Enigma, Davis Schottlander & Davis, Tonawanda, NY) were arranged and verified in the mouth, and the maxillary overdenture was processed with the fabricated Hader bar. At delivery, the synOcta abutments (Straumann) were torqued to 35 Ncm and the maxillary Hader bar was seated on the synOcta abutments (Straumann) and the screws were tightened to 15 Ncm. After the occlusion was checked and adjusted, the maxillary overdenture was delivered to the patient.

During the 1-year follow-up period, the patient complained about his enduring gagging reflex, and the different acrylic parts of the overdenture was fractured 4 times; however, a 2-mm nightguard (Biocryl, Great Lakes Orthodontics, Tonawanda, NY) was fabricated and given to the patient immediately after the delivery of the overdenture. Moreover, a high marginal bone loss was observed radiographically around the maxillary implants

supporting the bar (Figure 4). Therefore, a fixed hybrid treatment option after increasing the number of implants was determined.

Since the patient consented, he received a bilateral sinus lift in his posterior maxilla. After a 6-month healing period, 4 endosseous dental implants (Straumann) were placed in the posterior maxilla using the standard submerged surgical procedure established for the ITI dental implant system in the regions of the left and right second premolars and first molars (Figure 5). Four months after surgery the closure screws (Straumann) were removed under local anesthesia, and it was realized that the implant in the maxillary right first molar region was mobile. The implant was removed and the appropriate healing caps (Straumann) were screwed to the remaining 3 implants for gingival healing (Figure 6).

After 1 month of gingival healing, a maxillary definitive impression was made using the above-mentioned technique. A record base and a wax rim were prepared on the prepared maxillary cast (Figure 7). The maxillomandibular relation was recorded into a semiadjustable articulator (IML ARTI S4, IML-Instrumenta Mechanik Labor System) by using a facebow transfer. Artificial teeth (Enigma, Davis Schottlander & Davis) were arranged and tried in (Figure 8). A silicone index and an occlusal splint were prepared from the tooth arrangement in the laboratory. A verification index, which would also serve as the substructure of the fixed-hybrid framework, was fabricated by using the occlusal splint with pattern resin (GC Pattern Resin, GC America, Alsip, Ill). The verification index was checked intraorally (Figure 9) and since no discrepancies were observed, it was casted with chrome-cobalt (Biosil F, DeguDent GmbH, Hanau, Germany) in the laboratory. The completed framework was returned for try in to verify the accuracy of the fit, both on the cast and intraorally (Figure 10). The framework was sandblasted (Micro etcher ERC, Danville Engineering, San Ramon, Calif), a metal primer (Metal Primer II, GC America) was applied to enhance the bond, and an opaquer (Gradia Opaque, GC America) was applied to disguise the reflection of metal to the final restoration. After the application of bonding agent (Syntac, Ivoclar Vivadent, Amherst, NY), an indirect micro-ceramic composite (Gradia Indirect, GC America) was placed on the spaces of silicone



**FIGURES 6-11.** **FIGURE 6.** Intraoral view of the inserted implants. **FIGURE 7.** The prepared cast showing the 7 maxillary implants. **FIGURE 8.** Try in of the tooth arrangement. **FIGURE 9.** Try in of the verification index for accuracy. **FIGURE 10.** Intraoral view of the hybrid prosthesis framework. **FIGURE 11.** Final intraoral view of the hybrid prosthesis.

index using the appropriate shades. After polymerization, final polishing was accomplished with various points, brushes, and polishers. The final hybrid prosthesis with micro-ceramic composite processed to the metal framework was delivered to the patient with the reinforcement of daily hygiene instructions (Figure 11). During the 1-year follow-up period, the patient was recalled after 1 week, 3 weeks, and thereafter on a 3-month basis. The success rate was recorded according to the criteria suggested by Albrektsson and colleagues<sup>21</sup> as follows: the unattached implant was immobile when tested clinically; there was no evidence of radiographic peri-implant radiolucency and no incidence of excessive bone loss around implants; there was no recorded incident of peri-implant inflammation; absence of persistent and/or irreversible signs and symptoms such as pain or infection were observed. Additionally, no complications associated with the prosthesis were detected and the patient satisfaction was extremely high.

#### DISCUSSION

When restoring the edentulous maxilla with dental implants, the most important decision to make is whether the patient should be restored with a fixed or removable prosthesis.<sup>1</sup> In the present case, the

fixed prosthesis option was not considered initially because the patient had disagreed to the sinus lifting procedures and the extreme clenching habits were not known. The maxillary overdenture was designed in an arch shape to reduce tactile stimulation to the soft palate and tongue dorsum and thereby was thought to reduce or eliminate the gagging reflex of the patient. Also, the occlusal forces were considered to be more evenly distributed compared to a conventional denture and consequently inhibit the denture fracture, which was one of the reasons why the patient had been unable to use MCD. However, the arch shape of the maxillary overdenture was not sufficient in eliminating gagging of the patient, and the overdenture was broken 4 times during the first year of service. Another encountered problem was the excessive bone loss around the maxillary implants supporting the bar in the first year of loading. Since it was not due to inflammation or a systemic problem, it was decided that the implants had been overloaded.

It has previously been pointed out that an implant-supported overdenture on 4 bar-splinted implants without palatal coverage opposing a natural dentition may overload the implants.<sup>22,23</sup> The transformation of an implant-supported overdenture to a tissue implant-supported overdenture with a full palatal coverage was recommended in a similar case like ours.<sup>22</sup> However, it was not possible

to use such a simple technique for the presented patient because of his exaggerated gagging reflex.

In order to distribute the masticatory load, an increase in the number of implants was recommended in the edentulous maxillae.<sup>12,13,24</sup> It was also reported that higher bending moments may develop on the implants supporting overdentures than a fixed prosthesis.<sup>12,13</sup> Therefore, it was recommended to increase the number of implants supporting the prosthesis in order to prevent the bending moments that may cause bone loss.<sup>12,13</sup> In the light of these studies, in order to distribute the masticatory force and eliminate overloading of the implants, it was decided to increase the number of implants and fabricate fixed hybrid prosthesis for the presented patient.

The loss rate of implants in the posterior maxilla, especially after grafting and/or sinus elevation procedures is the highest in comparison to other situations.<sup>13,25</sup> Although 1 implant was lost, a fixed solution with 7 implants could be achieved. Compared to the first year of the first reconstruction, the posterior implants showed minimal crestal bone loss.

A stereolithographic template obtained from cone beam computerized tomography (CBCT) images could be used for the planning of the implant positions of the presented case. It is known that the use of stereolithographic guides for the placement of dental implants is designed to provide greater control and eliminate the risks that are involved in standard implant surgery. However, the patient refused CBCT due to his fears and extra cost.<sup>26,27</sup>

As a fixed solution, the hybrid prostheses was preferred to a full-arch implant-supported fixed bridge for several reasons, such as its proven superiority on cosmetic and phonetic results in patients with atrophic edentulous maxillae.<sup>16,17</sup> The provided treatment gave the patient self-confidence and comfortable function due to palatal freedom, and the esthetic was improved dramatically with the use of an indirect micro-ceramic composite having above-mentioned superior properties instead of acrylic base and artificial teeth in the fabrication of the prosthesis.

#### ABBREVIATIONS

CBCT: cone beam computerized tomography  
MCD: maxillary complete dentures

#### REFERENCES

1. Jivraj S, Chee W, Corrado P. Treatment planning of the edentulous maxilla. *Br Dent J*. 2006;201:261–279.
2. Driscoll CF, Masri RM. Single maxillary complete denture. *Dent Clin North Am*. 2004;48:567–583.
3. Jameson WS. Use of linear occlusion with fixed restorations opposing a mandibular complete denture: a clinical report. *Gen Dent*. 2003;51:274–279.
4. Da Silva L, Martinez A, Rilo B, Santana U. Titanium for removable denture bases. *J Oral Rehabil*. 2000;27:131–135.
5. Fiske J, Dickinson C. The role of acupuncture in controlling the gagging reflex using a review of ten cases. *Br Dent J*. 2001;190:611–613.
6. Bassi GS, Humphris GM, Longman LP. The etiology and management of gagging: a review of the literature. *J Prosthet Dent*. 2004;91:459–467.
7. Yoshida H, Ayuse T, Ishizaka S, Ishitobi S, Nogami T, Oi K. Management of exaggerated gag reflex using intravenous sedation in prosthodontic treatment. *Tohoku J Exp Med*. 2007;212:373–378.
8. Rismanchian M, Bajoghli F, Mostajeran Z, Fazel A, Eshkevari P. Effect of implants on maximum bite force in edentulous patients. *J Oral Implantol*. 2009;35:196–200.
9. Cooper LF, Moriarty JD, Guckes AD, et al. Five-year prospective evaluation of mandibular overdentures retained by two microthreaded, TiOblast nonsplinted implants and retentive ball anchors. *Int J Oral Maxillofac Implants*. 2008;23:696–704.
10. Sadig W. A comparative in vitro study on the retention and stability of implant-supported overdentures. *Quintessence Int*. 2009;40:313–319.
11. Alfadda SA, Attard NJ, David LA. Five-year clinical results of immediately loaded dental implants using mandibular overdentures. *Int J Prosthodont*. 2009;22:368–373.
12. Misch CE. Consideration of biomechanical stress in treatment with dental implants. *Dent Today*. 2006;25:80, 82, 84–85.
13. Balshi TJ, Wolfinger GJ. Management of the posterior maxilla in the compromised patient: historical, current, and future perspectives. *Periodontol*. 2003;33:67–81.
14. Zitzmann NU, Marinello CP. Treatment outcomes of fixed or removable implant-supported prostheses in the edentulous maxilla. Part II: clinical findings. *J Prosthet Dent*. 2000;83:434–442.
15. Feine JS, Lund JP. Treatment outcomes of fixed or removable implant-supported prostheses in the edentulous maxilla. *J Prosthet Dent*. 2000;84:372–373.
16. Norton MR, Ferber C. The nonresilient hybrid removable prosthesis: treatment of choice for the atrophic maxilla. *Int J Periodontics Restorative Dent*. 1999;19:189–197.
17. Small BW. Maxillary immediately loaded fixed hybrid prosthesis: a case report. *Gen Dent*. 2009;57:10–13.
18. Kuo SL, El-Gendy T, Chou J, Miller RB. Fabrication of a laser-welded fixed-detachable prosthesis for immediate loading. *J Prosthodont*. 2006;15:264–269.
19. Mandikos MN, McGivney GP, Davis E, Bush PJ, Carter JM. A comparison of the wear resistance and hardness of indirect composite resins. *J Prosthet Dent*. 2001;85:386–395.
20. Pereira G, Nunes TG, Kalachandra S. Low viscosity dimethacrylate comonomer compositions [Bis-GMA and CH3Bis-GMA] for novel dental composites; analysis of the network by stray-field MRI, solid-state NMR and DSC & FTIR. *Biomaterials*. 2002;23:3799–3806.
21. Albrektsson T, Zarb G, Worthington P, Eriksson AR. The long-term efficacy of currently used dental implants: a review and proposed criteria of success. *Int J Oral Maxillofac Implants*. 1986;1:11–25.
22. Grossmann Y, Pasciuta M. Rehabilitation of the edentulous maxilla after the failure of an implant-supported bar. *J Prosthodont*. 2007;16:319–323.

23. Ochiai KT, Williams BH, Hojo S, Nishimura R, Caputo AA. Photoelastic analysis of the effect of palatal support on various implant-supported overdenture designs. *J Prosthet Dent.* 2004;91:421–427.

24. Testori T, Meltzer A, Del Fabbro M, et al. Immediate occlusal loading of Osseotite implants in the lower edentulous jaw. A multicenter prospective study. *Clin Oral Implants Res.* 2004;15:278–284.

25. Herrmann I, Lekholm U, Holm S, Kultje C. Evaluation of patient and implant characteristics as potential prognostic factors

for oral implant failures. *Int J Oral Maxillofac Implants.* 2005;20:220–230.

26. Kopp KC, Koslow AH, Abdo OS. Predictable implant placement with a diagnostic/surgical template and advanced radiographic imaging. *J Prosthet Dent.* 2003;89:611–615.

27. van Steenberghe D, Naert I, Andersson M, Brajnovic I, Van Cleynenbreugel J, Suetens P. A custom template and definitive prosthesis allowing immediate implant loading in the maxilla: a clinical report. *Int J Oral Maxillofac Implants.* 2002;17:663–670.