

# Precision of Implant Placement With Stereolithographic Templates: A Pilot In Vitro Study

Hakan Bilhan, DDS, PhD  
Selda Arat, DDS, PhD  
Emre Mumcu, DDS, PhD  
Onur Geckili, DDS, PhD\*  
Olcaç Şakar, DDS, PhD

This pilot study assesses the accuracy of 2 bone-supported stereolithographic surgical templates with respect to placement of implants in originally planned positions, and it tests the precision of dental volumetric tomography planning. Two mandibles retrieved from formalin-fixed human cadavers were scanned by dental volumetric tomography for planning of the implant positions, leading to stereolithographic models and fabrication of surgical guides. The situation immediately following drilling and implant insertion by an experienced surgeon was scanned and the outcome compared with the initial planning. The 3-dimensional discrepancies were then analyzed and determined. The results show deviations of the placed implants from the original planning, especially in the vertical direction, making the seating of a prefabricated denture impossible. At present, the flapless surgery technique based on stereolithographic surgical templates appears unsafe; further improvement is required.

**Key Words:** dental volumetric tomography, stereolithographic surgical template, flapless surgery, dental implants

## INTRODUCTION

Since the introduction of the concept of osseointegration in dentistry, the technology and science of endosseous implants has improved greatly, and the current trend is to decrease the number of surgical interventions, thereby reducing costs and patient discomfort. With the advent of 3-dimensional (3D) computer technology, simulated ideal implant locations are assumed to be transferred intraorally via a stereolithographic surgical template obtained from cone-beam computerized tomography (CBCT) images.<sup>1</sup> Indeed, while implant selection and placement have always been based on radiological judgment, usually determined via 2-dimensional radiographic images, this new method

provides the clinician with radiological data in all 3 dimensions.

The stereolithographic template is reported to have the ability to precisely control implant positions in 3D.<sup>1-3</sup> This capability is claimed to make possible flapless surgery<sup>4</sup> and fabrication of provisional or definitive implant dentures prior to implant surgery.<sup>5-10</sup> Flapless surgery for dental implants decreases postoperative patient discomfort and reduces intraoperative bleeding, although it is a blind procedure (because of the difficulty in evaluating alveolar bone shape).

Alveolar bone-supported templates were preferred until recently as stereolithographic guides; however, there was no depth control of the osteotomy drills.<sup>11</sup> Tooth or mucosa-supported guides were then used to insert implants without the need for flap elevation.<sup>12,13</sup>

With implant insertion via stereolithographic surgical templates based on dental volumetric tomography, soft tissue was reported to create a

Department of Prosthodontics, Istanbul University, Istanbul, Turkey.

\* Corresponding author, e-mail: geckili@istanbul.edu.tr

DOI: 10.1563/AAID-JOI-D-10-00109

difficulty.<sup>14</sup> The accuracy of placed implants, compared with the planned implants, has been a significant concern with all guide systems.<sup>14</sup> Without a doubt, the soft tissue is an important factor affecting the precision of implant positioning. Mucosa-supported guides are seated over the mucosa using a previously prepared occlusal bite registration and fixed through previously planned osteosynthesis screw holes to the underlying alveolar bone. In this technique, the soft tissue is an additional factor rise to discrepancies between planned and placed implant positions. Therefore, it would be important to determine whether, by elimination of the soft-tissue factor, the desired precision can be achieved.

The goal of this pilot study, then, is to assess the accuracy of 2 different bone-supported stereolithographic surgical templates in placing implants in originally planned positions.

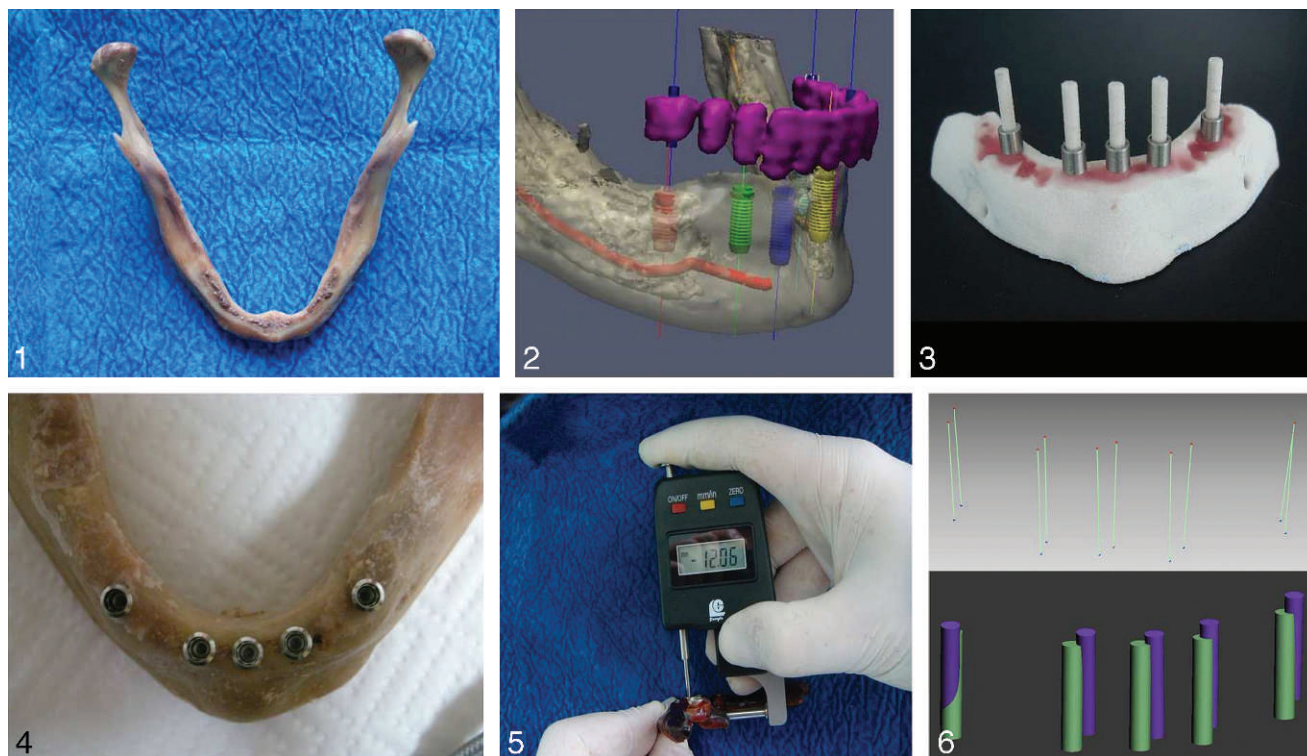
#### MATERIALS AND METHODS

Two mandibles of formalin-fixed human cadavers were used. After removal of the mandibles from both cadavers, the remaining teeth were extracted and the alveolar ridges flattened (Figure 1). The obtained mandibles were scanned by DVT for planning of the implant positions (Figure 2), leading to stereolithographic models and fabrication of surgical guides. The scan of the first mandible was performed with a Newtom (NewTom Cone Beam 3D Imaging, AFP Imaging Corporation, New York, NY), and the second with an ILUMA (Imtec Imaging, a 3M Company, Ardmore, Okla). All images were obtained using the standard setup of 120 kilovolt (peak), 3.8 mA, with an exposure time of 40 seconds. After CBCT imaging and data acquisition, segmentation of bone and prosthesis scanning were performed by a specialist in maxillofacial radiology trained in post-CBCT imaging analysis and segmentation, using a software program (Stent CAD, Media Lab, La Spezia, Italy). Computer-aided planning records were generated, and the final positions of the implants determined by the software were saved for postoperative comparison. Two surgical guides were fabricated for each mandible on the obtained stereolithographic models (Figure 3): the first stent with 2.2-mm drill holes, and the second with 2.8-mm drilling holes. For fabrication of the surgical guides of both mandibles, the Aytasarim System

(Classic and Otete Systems, Kos-gep, ODTU, Ankara, Turkey) was used.

On the first mandible, five 4.1/12-mm Straumann implants were placed in the lateral incisor and first premolar positions bilaterally and in the midline (Figure 4). On the second mandible, the planned implant positions were mandibular lateral incisors, first premolars, and first molars, bilaterally. Six 3.3-mm-wide, 8-mm-long Straumann dental implants (Institut Straumann, Basel, Switzerland) were placed symmetrically according to defined principles. Before drilling, the height of each ring was measured with a Guanglu 0- to 15-mm Digital Thickness Gage (Guilin Guanglu Measuring Instrument Co, Ltd, Guilin Hi-Tech Industrial Zone, China; Figure 5) in millimeters and added to the implant length to determine the drilling depth. Following insertion of the implants, a new tomographic scan was performed to compare the outcome with the planning.

The coronal discrepancy (deviation of the entry point), apical difference (deviation of the apex), deviation in the vertical position (height), and angular deviation of each implant were calculated. Special image-processing software (Rhinoceros 4.0, McNeel North America, Seattle, Wash) was used to match preoperative planning images with postoperative data, using the criteria described in a previous study.<sup>15</sup> The planning and postoperative CBCT data sets were converted and imported into the software. Base (planning) and match (postoperative CBCT) image series were visualized using the 3D voxel registration tool of the software. The 2 data sets were first fused with the automated register tool. The software allows checking and evaluation of the correct registration of both images in the transverse, coronal, and sagittal planes in the fused column window that is placed between the data set panes. If a registration was unsuccessful, the images were then manually registered using the manual, threshold, and transformation tools. Implants and the remaining anatomical structures in the planning and postoperative CBCT data were rendered as 3D volumes using the render volume tool. Finally, the bone volume was removed, leaving the planned and placed implant volumes superimposed on the identical 3D spatial image. Merged images were then exported to the planning software. The removal of the bone volume from the 3D reconstructed model allowed for visualization of the



**FIGURES 1–6.** **FIGURE 1.** The mandible taken from formalin-fixed human cadaver. **FIGURE 2.** Planning of the implant positions on the 3D models of the mandible in the CAD software. **FIGURE 3.** Stereolithographic model. **FIGURE 4.** On the first mandible, 5 implants placed in the lateral incisor and first premolar positions bilaterally and in the midline. **FIGURE 5.** The height of each ring as measured with a Digital Thickness Gage. **FIGURE 6.** Measurements of deviations.

planned (realistic) and placed (rendered) 3D implant volumes in different colors. Two points (in the x, y, and z coordinates) in the implant shoulder and tip for the planned and placed implants were determined in the 3D implant volumes. These 2 points were then connected by a line constituting the axis of the implants. Using the pan and zoom features of the software, the fused implant volumes were rotated and magnified for measurement in the shoulder, tip, and horizontal aspects. Angular deviation (angle between the axis of the planned and placed implants) and linear deviation at the implant shoulder (distance between the coronal centers of the planned and placed implants) and at the implant tip (distance between the center tip of the planned and placed implants) were then measured (Figure 6). The average of these measurements was then recorded as one value.

## RESULTS

In total, 11 implants in 2 mandibles were evaluated, and the discrepancies between planned and

achieved implant positions were determined (Table).

- Coronal discrepancy: mean 1.12 mm (max 1.40 mm, min 0.69 mm)
- Apical difference: mean 1.21 mm (max 2.16 mm, min 0.29 mm)
- Vertical discrepancy: mean 1.42 mm (max 1.92 mm, min. 1.00 mm)
- Angular deviation: mean 4.71° (max 7.58°, min 2.51°)

## DISCUSSION

To justify the higher costs of stereolithographic surgical templates and dental volumetric tomography scanning, these methods must provide concrete advantages, such as flapless surgery and/or fabrication of provisional or definitive implant dentures prior to implant surgery. Limited studies show encouraging results,<sup>16–19</sup> whereas there is controversy about the precision of implant placement exactly in the planned position. Although the use of

stereolithographic guides for the placement of dental implants is designed to provide greater control and to eliminate the risks inherent in standard implant surgery, there are studies reporting mean linear and angular transfer errors of up to 4.5 mm and 4.5° between treatment plan and final implant positions.<sup>3,16,19–21</sup> Such deviations could lead to fenestration or dehiscence and damage to anatomical structures such as the maxillary sinus, nasal cavity, mandibular canal, or neighboring teeth during flapless surgery. When performed with the goal of immediate loading by prefabricated dentures, these transfer errors could additionally result in superstructure misfit. A recent study discusses how such a misfit could even lead to excessive marginal bone loss around the related implant.<sup>20</sup> Stereolithographic templates can be used in completely as well as partially edentulous situations, supported by soft or hard tissue such as bone or remaining teeth. Working with a soft-tissue-supported template makes the use of horizontal fixation compulsory, because misalignment of the implants is reported to be otherwise inevitable.<sup>16</sup> After all, the described technique reveals difficulties in evaluation of the depth of each site during surgery, depending on the height of the mucosa, which can be altered because of, for example, local anesthesia.<sup>12</sup> To eliminate the soft-tissue factor and to test the accuracy of a stereolithographic template fabricated on the dental volumetric tomography images, the mandible of a formalin-fixed human cadaver was taken and peeled. Although it is assumed that formalin fixation alters the mechanical properties of bone, studies have failed to deduce quantitative data.<sup>22</sup> Tissue fixation with 10% formalin (4% formaldehyde) is widely used to preserve specimens without refrigeration, offering researchers the added benefit of protection from specimens with communicable diseases.<sup>23,24</sup> The formalin-fixed mandible used in the present study showed an atypical interforaminal bone. The type III bone used for this in vitro study, which shows a thin cortical layer and a large cancellous core, could have been a factor negatively influencing the precise placement of the implants. It is evident that there is an accumulation of minor differences between a living patient's tissue and that of a cadaver, which may contribute to errors in implant placement; this is evident in comparison with the planned implant positions in a recent study as well.<sup>25</sup>

The soft tissue reveals additional difficulties in achieving precision. Nevertheless, if the stent is placed on the alveolar bone, the advantage of flapless surgery is lost and even then discrepancies appear due to several factors, varying from scanning and imaging to conversion of the data in a software program, to obtaining a stereolithographic model, to manufacture of a template, and to clinical difficulties influencing the surgery.

The clinician converts the digital imaging and communications in medicine files to a 3D format of the patient's bone. During this conversion, minor errors depending on the software may arise and influence the targeted precision adversely. It is assumed that a physical cast (stereolithographic model) of a selected anatomic region is produced by prototyping, facilitating the construction of a more accurate surgical template. However, minor cumulative errors at this stage may additionally contribute to deviations. Last but not least, the dimensional instability of the polymer used for production of the template could constitute another source of error. In a recent study, it was reported that in 12 of 17 situations, a visible gap was evident between the tissue and the guide.<sup>25</sup>

Both analog<sup>26,27</sup> and digital methods<sup>28,29</sup> have been used to measure deviations. Since digital methods give more accurate results, software suitable for this purpose was used in the present study. In vitro studies are free of confounding clinical factors that cause movement of the guide and restriction of access during surgery and that increase the deviation. When a system is applied clinically, the maximum possible deviation should be taken into account, because the incidental contact of the implant body with any critical anatomical structure can cause serious complications.<sup>30</sup> The use of a single guide throughout an osteotomy is recommended to reduce deviations.<sup>14</sup> Integration of a depth-control mechanism is also reported to ensure a safe osteotomy and accurate positioning of the implants. In a human cadaver study,<sup>28</sup> an angular deviation of 0.7° to 4° and linear deviations of 0.3 mm to 2.3 mm (neck of the implant) and 0.3 mm to 2.4 mm (apex of the implant) were reported in 12 implants that were placed by single guides with depth control. The magnitude of deviations in the present study was comparable to the published data of similar studies.<sup>25,28</sup> Smaller deviations were observed with

TABLE				
The numeric deviations in several dimensions				
	Apical deviation, mm	Coronal deviation, mm	Angular deviation	Vertical deviation, mm
Implant 1	1.26	0.93	4.36	1.87
Implant 2	2.03	1.40	2.51	1.92
Implant 3	2.16	1.38	4.72	1.61
Implant 4	0.29	1.27	7.58	1.63
Implant 5	1.03	0.69	7.29	1.00
Implant 6	1.20	1.12	4.72	1.43
Implant 7	0.89	1.20	3.16	1.06
Implant 8	1.28	1.18	4.28	1.33
Implant 9	0.76	0.99	4.80	1.46
Implant 10	1.27	1.27	5.56	1.11
Implant 11	1.09	0.88	2.87	1.24
Mean	1.206	1.119	4.713	1.423
Maximum	2.16	1.4	7.58	1.92
Minimum	0.29	0.69	2.51	1.00

tooth-supported guides, and screw fixation of the guide was recommended to reduce errors. Tooth-supported guides have been reported to show lower angular and linear deviations than bone-supported guides. The lowest deviations were reported for tooth-supported guides in several studies.<sup>28,29,31</sup> Nevertheless, there are too many factors influencing implant positioning via stereolithographic surgical templates.

The results of this pilot study indicate that stereolithographic surgical templates may be a good aid in conventional implant placement. However, as pointed out in several studies, the technique must be refined and brought to a much higher state of development to justify flapless surgery or fabrication of provisional or definitive implant dentures prior to implant surgery,<sup>32,33</sup> since there are still too many sources of error for precise implant placement.<sup>25,34</sup>

### CONCLUSION

Because of several factors that may cause discrepancies, the accurate placement of dental implants and the flapless surgery technique, which depends on stereolithographic templates after planning by dental volumetric tomography, need further improvement.

### ABBREVIATIONS

3D: 3-dimensional

CBCT: cone-beam computerized tomography

### ACKNOWLEDGMENTS

The authors thank Mr Asim Horasan from Teknogem (Istanbul, Turkey) and Mr Ayberk Yagiz from Aytasarim Systems (Ankara, Istanbul, Turkey) for their kind efforts in analyzing the data. The authors also thank Mr Kutay Eryilmaz from Net Medical Imaging (Istanbul, Turkey) and Dr Sinan Horasan from Teknodent Dental Imaging Center (Istanbul, Turkey) for making the imaging with ILUMA possible. The authors further thank the Department of Anatomy of Istanbul University Medical School for providing the human cadavers for this in vitro study.

### REFERENCES

1. Kopp KC, Koslow AH, Abdo OS. Predictable implant placement with a diagnostic/surgical template and advanced radiographic imaging. *J Prosthet Dent*. 2003;89:611–615.
2. Sudbrink SD. Computer-guided implant placement with immediate provisionalization: a case report. *J Oral Maxillofac Surg*. 2005;63:771–774.
3. van Steenberghe D, Naert I, Andersson M, Brajnovic I, Van Cleynebreugel J, Suetens P. A custom template and definitive prosthesis allowing immediate implant loading in the maxilla: a clinical report. *Int J Oral Maxillofac Implants*. 2002;17:663–670.
4. Brodala N. Flapless surgery and its effect on dental implant outcomes. *Int J Oral Maxillofac Implants*. 2009;24:118–125.
5. Kan JY, Rungcharassaeng K, Oyama K, Chung SH, Lozada JL. Computer-guided immediate provisionalization of anterior multiple adjacent implants: surgical and prosthodontic rationale. *Pract Proced Aesthet Dent*. 2006;18:617–623.
6. Balshi SF, Wolfinger GJ, Balshi TJ. Surgical planning and prosthesis construction using computer technology and medical imaging for immediate loading of implants in the pterygomaxillary region. *Int J Periodontics Restorative Dent*. 2006;26:239–247.
7. Becker W, Doerr J. Three-dimensional software for fabrication of a surgical template and final implant-supported restoration for a fully edentulous maxilla: a case report. *Compend Contin Educ Dent*. 2005;26:802, 804–807.

8. Kupeyan HK, Shaffner M, Armstrong J. Definitive CAD/CAM-guided prosthesis for immediate loading of bone-grafted maxilla: a case report. *Clin Implant Dent Relat Res*. 2006;8:161–167.
9. Marchack CB, Moy PK. The use of a custom template for immediate loading with the definitive prosthesis: a clinical report. *J Calif Dent Assoc*. 2003;31:925–929.
10. van Steenberghe D, Glauser R, Blombäck U, et al. A computed tomographic scan-derived customized surgical template and fixed prosthesis for flapless surgery and immediate loading of implants in fully edentulous maxillae: a prospective multicenter study. *Clin Implant Dent Relat Res*. 2005;7:111–120.
11. Rosenfeld AL, Mandelaris GA, Tardieu PB. Prosthetically directed implant placement using computer software to ensure precise placement and predictable prosthetic outcomes. Part 2: rapid-prototype medical modeling and stereolithographic drilling guides requiring bone exposure. *Int J Periodontics Restorative Dent*. 2006;26:347–353.
12. Terzioğlu H, Akkaya M, Ozan O. The use of a computerized tomography-based software program with a flapless surgical technique in implant dentistry: a case report. *Int J Oral Maxillofac Implants*. 2009;24:137–142.
13. Azari A, Nikzad S. Flapless implant surgery: review of the literature and report of 2 cases with computer-guided surgical approach. *J Oral Maxillofac Surg*. 2008;66:1015–1021.
14. Vercruyssen M, Jacobs R, Van Assche N, van Steenberghe D. The use of CT scan based planning for oral rehabilitation by means of implants and its transfer to the surgical field: a critical review on accuracy. *J Oral Rehabil*. 2008;35:454–474.
15. Maes F, Collignon A, Vandermeulen D, Marchal G, Suetens P. Multimodality image registration by maximization of mutual information. *IEEE Trans Med Imaging*. 1997;16:187–198.
16. Di Giacomo GA, Cury PR, de Araujo NS, Sendyk WR, Sendyk CL. Clinical application of stereolithographic surgical guides for implant placement: preliminary results. *J Periodontol*. 2005;76:503–507.
17. Fortin T, Isidori M, Blanchet E, Perriat M, Bouchet H, Coudert JL. An image-guided system-drilled surgical template and trephine guide pin to make treatment of completely edentulous patients easier: a clinical report on immediate loading. *Clin Implant Dent Relat Res*. 2004;6:111–119.
18. Ganz SD. Use of stereolithographic models as diagnostic and restorative aids for predictable immediate loading of implants. *Pract Proced Aesthet Dent*. 2003;15:763–771.
19. Arisan V, Karabuda ZC, Ozdemir T. Accuracy of two stereolithographic guide systems for computer-aided implant placement: a computed tomography-based clinical comparative study. *J Periodontol*. 2010;81:43–51.
20. Sarment DP, Sukovic P, Clinthorne N. Accuracy of implant placement with a stereolithographic surgical guide. *Int J Oral Maxillofac Implants*. 2003;18:571–577.
21. Widmann G, Bale RJ. Accuracy in computer-aided implant surgery—a review. *Int J Oral Maxillofac Implants*. 2006;21:305–313.
22. Cömert A, Kökat AM, Akkocaoğlu M, Tekdemir I, Akça K, Cehreli MC. Freshfrozen vs. embalmed bone: is it possible to use formalin-fixed human bone for biomechanical experiments on implants? *Clin Oral Implants Res*. 2009;20:521–525.
23. Nuccion SL, Otsuka NY, Davey JR. The effect of freezing and intraosseous fluid on the stiffness behavior of canine trabecular bone. *Orthopedics*. 2001;24:375–380.
24. Moreno J, Forriol F. Effects of preservation on the mechanical strength and chemical composition of cortical bone: an experimental study in sheep femora. *Biomaterials*. 2002;23:2615–2619.
25. Pettersson A, Kero T, Gillot L, et al. Accuracy of CAD/CAM-guided surgical template implant surgery on human cadavers: Part I. *J Prosthet Dent*. 2010;103:334–342.
26. Naitoh M, Arijji E, Okumura S, Ohsaki C, Kurita K, Ishigami T. Can implants be correctly angulated based on surgical templates used for osseointegrated dental implants? *Clin Oral Implants Res*. 2000;11:409–414.
27. Al-Harbi SA, Sun AYT. Implant placement accuracy when using stereolithographic template as a surgical guide: preliminary results. *Implant Dent*. 2009;18:46–56.
28. Van Assche N, van Steenberghe D, Guerrero ME, et al. Accuracy of implant placement based on pre-surgical planning of three-dimensional cone-beam images: a pilot study. *J Clin Periodontol*. 2007;34:816–821.
29. Ersoy AE, Turkyilmaz I, Ozan O, McGlumphy EA. Reliability of implant placement with stereolithographic surgical guides generated from computed tomography: clinical data from 94 implants. *J Periodontol*. 2008;79:1339–1345.
30. Hegedus F, Diecidue RJ. Trigeminal nerve injuries after mandibular implant placement—practical knowledge for clinicians. *Int J Oral Maxillofac Implants*. 2006;21:111–116.
31. Ozan O, Turkyilmaz I, Ersoy AE, McGlumphy EA, Rosenstiel SF. Clinical accuracy of 3 different types of computed tomography-derived stereolithographic surgical guides in implant placement. *J Oral Maxillofac Surg*. 2009;67:394–401.
32. Schneider D, Marquardt P, Zwahlen M, Jung RE. A systematic review on the accuracy and the clinical outcome of computer-guided template-based implant dentistry. *Clin Oral Implants Res*. 2009;20:73–86.
33. Oyama K, Kan JY, Kleinman AS, Runcharassaeng K, Lozada JL, Goodacre CJ. Misfit of implant fixed complete denture following computer-guided surgery. *Int J Oral Maxillofac Implants*. 2009;24:124–130.
34. Widmann G, Zangerl A, Keiler M, Stoffner R, Bale R, Puelacher W. Flapless implant surgery in the edentulous jaw based on three fixed intraoral reference points and image-guided surgical templates: accuracy in human cadavers. *Clin Oral Implants Res*. 2010;21:835–841.