

# Pterygoid Implants for Maxillofacial Rehabilitation of a Patient With a Bilateral Maxillectomy Defect

Avinash S. Bidra, BDS, MS, FACP<sup>1\*</sup>  
George W. May, DDS<sup>2</sup>  
Greggory E. Tharp DMD<sup>2</sup>  
Mark S. Chambers, DMD, MS<sup>3</sup>

Bilateral maxillectomy is known to have serious esthetic and functional consequences. The retention and support of a maxillary obturator prosthesis in these patients is particularly challenging. Surgical placement of implants is also challenging because of the lack of available bone. Therefore, implant placement into remote sites such as zygoma has been advocated. Very few articles in the literature have discussed the use of pterygoid/pterygomaxillary implants in patients undergoing maxillectomy. This case report describes the maxillofacial rehabilitation of an elderly man who underwent a bilateral subtotal maxillectomy due to basaloid squamous cell carcinoma of the hard palate. After initial healing, the patient had a pterygoid implant placed on each side of the oral cavity. Zygomatic implants were also attempted, but they failed to osseointegrate. Both pterygoid implants showed successful osseointegration. These 2 implants significantly helped to retain a hollow maxillary obturator prosthesis that aided in improved swallowing, speech, and esthetics. To the authors' knowledge, this is the first report in the literature that describes usage of pterygoid implants for rehabilitation of a patient undergoing bilateral maxillectomy.

**Key Words:** pterygoid, pterygomaxillary, implant, tuberosity, maxillectomy, hollow obturator

## INTRODUCTION

**M**axillectomy or maxillary resection is defined as surgical removal of a part or all of the maxilla.<sup>1</sup> This definition is broad and does not describe the resection in lateral, superior, or posterior extensions. For better description and for communication purposes, several classifications have been proposed with no unanimity of use.<sup>2-9</sup> A classification system described by Spiro et al<sup>6</sup> is simple and is popular among surgeons and maxillofacial prosthodontists. In this system, adjectives are used to describe the extent of maxillary resection as limited, subtotal, or total.

Limited maxillectomy is defined as any maxillary resection that primarily removes 1 wall of the antrum, usually the floor or the medial wall. Subtotal maxillectomy is defined as any maxillectomy that removes at least 2 walls, including the floor of the antrum (hard palate) but not the posterior wall. Total maxillectomy is defined as complete removal of the maxilla, usually involving orbital exenteration. Additional details, such as unilateral or bilateral and the contiguous structures involved, are usually specified along with the classified resection.<sup>6</sup>

Obturation of bilateral subtotal or total maxillectomy defects presents a significant challenge to the maxillofacial prosthodontist.<sup>10-13</sup> Often there is inadequate retention, stability, and support for the prosthesis because of the apparent loss of anatomic structures. Patients with such defects have significant difficulties in swallowing, speech, mastication, and esthetics.<sup>10,11</sup> They often have poor lip support, scarring of the lip, midfacial collapse, lip incompetency, drooping commissures, and trismus due to

<sup>1</sup> Department of Reconstructive Sciences, University of Connecticut, Farmington, Conn.

<sup>2</sup> Private practice, Jackson, Miss.

<sup>3</sup> Section of Dental Oncology, University of Texas, M.D Anderson Cancer Center, Houston, Tex.

\* Corresponding author, e-mail: avinashbidra@yahoo.com  
DOI: 10.1563/AAID-JOI-D-10-00181

surgical morbidities.<sup>10,11</sup> The nose is often collapsed due to loss of nasal septum and anterior nasal spine, resulting in esthetic and breathing difficulties. Successful rehabilitation depends on understanding the patient's expectations and educating the patient about the advantages and disadvantages of all surgical and prosthetic options.

Various methods have been described for retention and support of a complete bilateral obturator prosthesis, including engagement of (1) existing anatomic undercuts and lateral scar band<sup>11,13</sup>; (2) remaining maxillary structures, such as the posterior third of the soft palate<sup>13</sup>; (3) titanium hollow reconstruction plate attached to the zygomatic bone<sup>14</sup>; (4) implants placed in the remnant of the maxilla, grafted bone, or distracted bone<sup>12</sup>; and (5) zygomatic implants.<sup>10,15-17</sup> Irrespective of the method of retention, the prosthodontic principles are the same, and the clinician should aim to minimize the weight of the prosthesis. Increased weight of an obturator may contribute to its own dislodgement.

Pterygoid implant has been defined as "implant placement through the maxillary tuberosity and into the pterygoid plate."<sup>18</sup> These implants were first introduced by Tulasne in 1989.<sup>19,20</sup> The pterygoid implant originates in the tuberosity region and then follows an oblique mesiocranial direction proceeding posteriorly toward the pyramidal process; it subsequently proceeds upward between both wings of the pterygoid processes and finds its encroachment in the pterygoid or scaphoid fossa of the sphenoid bone.<sup>21,22</sup> The length of these implants ranges from 15 to 20 mm, and they are generally placed at an angle of 45° to 50° to the horizontal plane.<sup>20,21</sup> Usually, a combination of osteotomes and surgical drills with long extensions are used because of the semi-blinded nature of the surgical procedure and the bone density of the pterygoid plates and to minimize the potential for injuring vital structures.<sup>21-23</sup> Though previous reports have advocated the use of general anesthesia for implant placement in this region, more recent reports have described the use of local anesthesia.<sup>23,24</sup> Some of the complications with surgical placement reported in the literature include slight venous bleeding,<sup>23</sup> minor trismus,<sup>23</sup> misplacement of the implant,<sup>22,25</sup> and a unique case of continuous episode of pain and discomfort.<sup>26</sup> A recent case report described the use of a long zygomatic

implant in the pterygoid region that resulted in an intracerebral penetration.<sup>27</sup> Careful planning and use of cone-beam computerized tomography imaging may help prevent some of these complications.

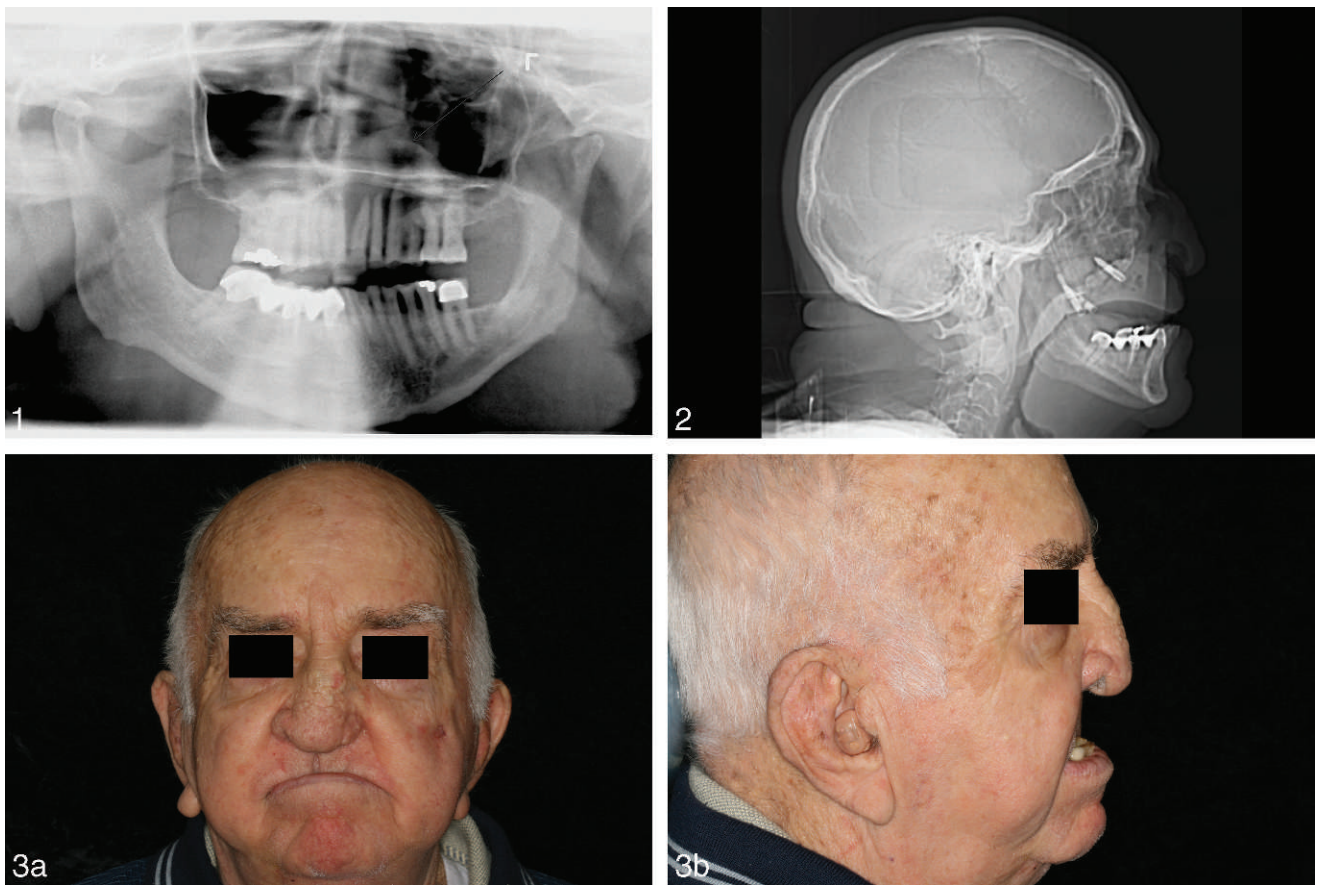
Pterygoid implants have been primarily used in the rehabilitation of patients with atrophic maxilla or for purposes of avoiding maxillary sinus augmentation procedures. Only 1 article in the literature has mentioned the use of pterygoid implants in patients undergoing maxillectomy.<sup>28</sup> However, this article did not describe the number of pterygoid implants or the number and type of patients who received these implants. The primary advantage of using pterygoid implants is that the density of bone in this area affords good anchorage potential, which may be superior to that of any other part of the maxilla.<sup>19,29</sup> However, the main disadvantage of this procedure is the technique sensitivity and difficulty in access for clinicians and patients.<sup>19,29</sup> The long-term survival rate of these implants is not well reported but one study depicting survival over a period of up to 10 years calculated a cumulative survival rate of 95.3%.<sup>23</sup> Other studies have found similar survival rates over a varying time period.<sup>29-31</sup>

The purpose of this clinical report is to describe the comprehensive rehabilitation of a patient undergoing bilateral maxillectomy using pterygoid implants for retention and support.

### CASE REPORT

A 76-year-old white man presented with a large swelling in the hard palate. The patient had a history of complex comorbidities, such as congenital heart disease, diabetes, artificial knee-joint replacements, nephrolithiasis, peptic ulcers, and neurologic disorders. At the time of presentation, he had a complex list of medications that included more than 10 different types of drugs. After a complete diagnostic workup involving a multidisciplinary oncology team, he was given a diagnosis of basaloid squamous cell carcinoma of the hard palate. As a result, the planned treatment was a bilateral subtotal maxillectomy (Figure 1).

Diagnostic impressions were made in irreversible hydrocolloid impression material (Supergel, Bosworth, Skokie, Ill) and a diagnostic cast was fabricated. Autopolymerizing resin (Repair Material, Dentsply, York, Pa) was used to fabricate a surgical



**FIGURES 1–3.** **FIGURE 1.** Preoperative panoramic radiograph of the patient at the time of initial presentation. **FIGURE 2.** Lateral radiographic image showing the placement of 2 pterygoid implants and 1 regular implant in the right zygoma, after bilateral maxillectomy. **FIGURE 3.** (a) Frontal view of the patient after bilateral maxillectomy, before the start of the prosthetic procedures. Note the drooping commissures and collapsed nose. (b) Profile view of the patient after bilateral maxillectomy and before the start of the prosthetic procedures. Note the collapse of the midfacial profile.

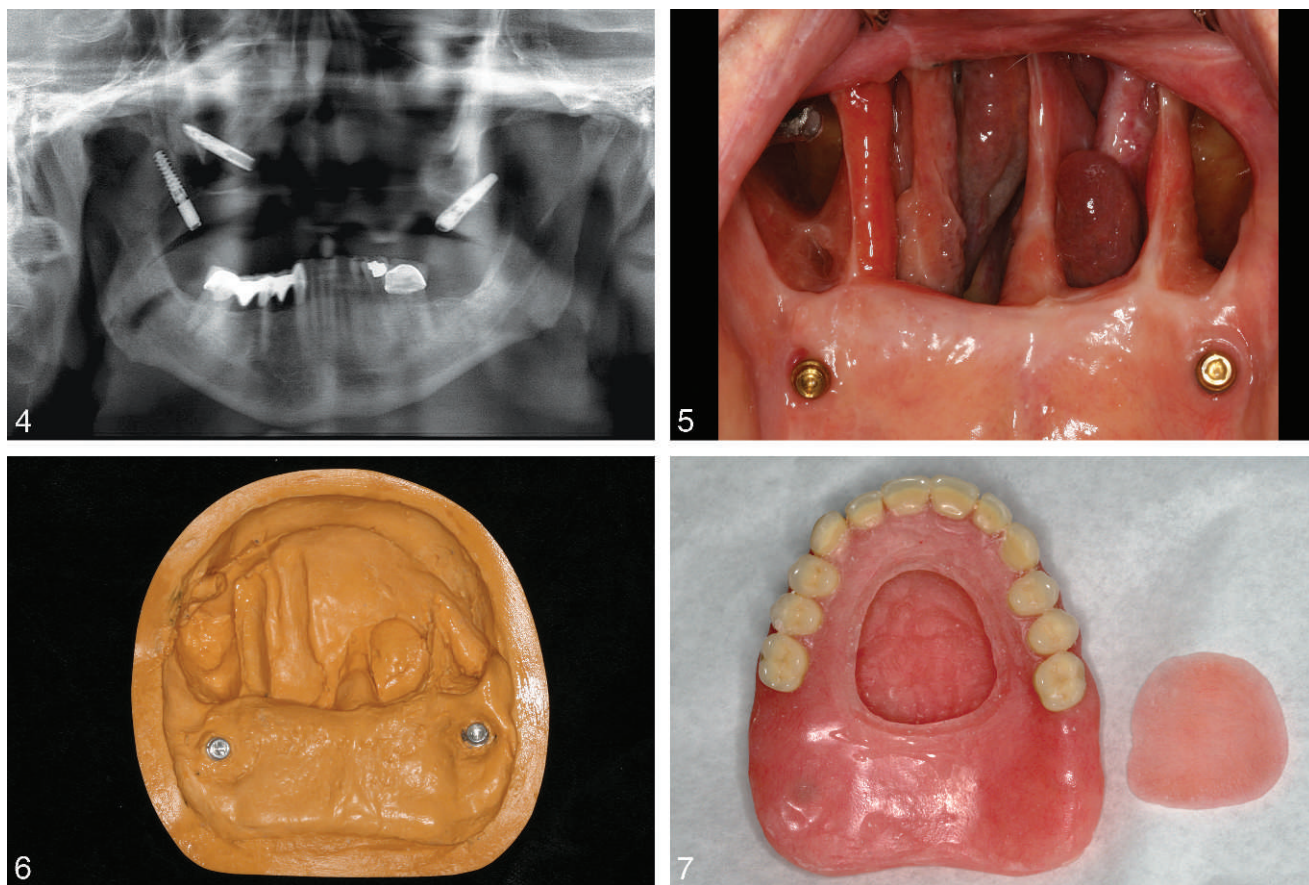
obturator. The surgical resection of the maxilla was unremarkable and was classified in 3 dimensions as bilateral, subtotal, and not involving the soft palate. Negative tumor margins were confirmed by frozen sections. The inferior turbinates were removed to provide sufficient access to the superior aspect of the defect and allow proper extension of the planned obturator. A split-thickness skin graft procedure to line the walls of the surgical defect was considered but not performed because of the patient's complex medical history.

The surgical obturator was then inserted and retained by using circumzygomatic wires. Two weeks later, the surgical obturator was removed and an interim obturator without prosthetic teeth was inserted. The patient was in considerable discomfort during the healing process because of difficulty in retaining the interim obturator and his dissatisfaction with the prosthesis. The patient

expressed a strong desire to have prosthetic teeth incorporated in the interim obturator to enhance the esthetics and be able to engage socially. The patient was educated on the increased weight of the prosthesis due to incorporation of denture teeth and additional acrylic resin; furthermore, he was counseled about problems related to lack of retention and support from the underlying structures. As the patient was adamant about having denture teeth incorporated into the prosthesis, a diagnostic imaging and clinical evaluation were performed to determine placement of implants in the pterygoid plates and zygoma to help retain and support the obturator.

After initial healing of the tumor-ablated defect, an attempt was made to place a pterygoid and a zygomatic implant on each side of the oral cavity. A 4 mm × 15 mm implant was placed on the right and left pterygoid plate (Mk III RP, Branemark System-





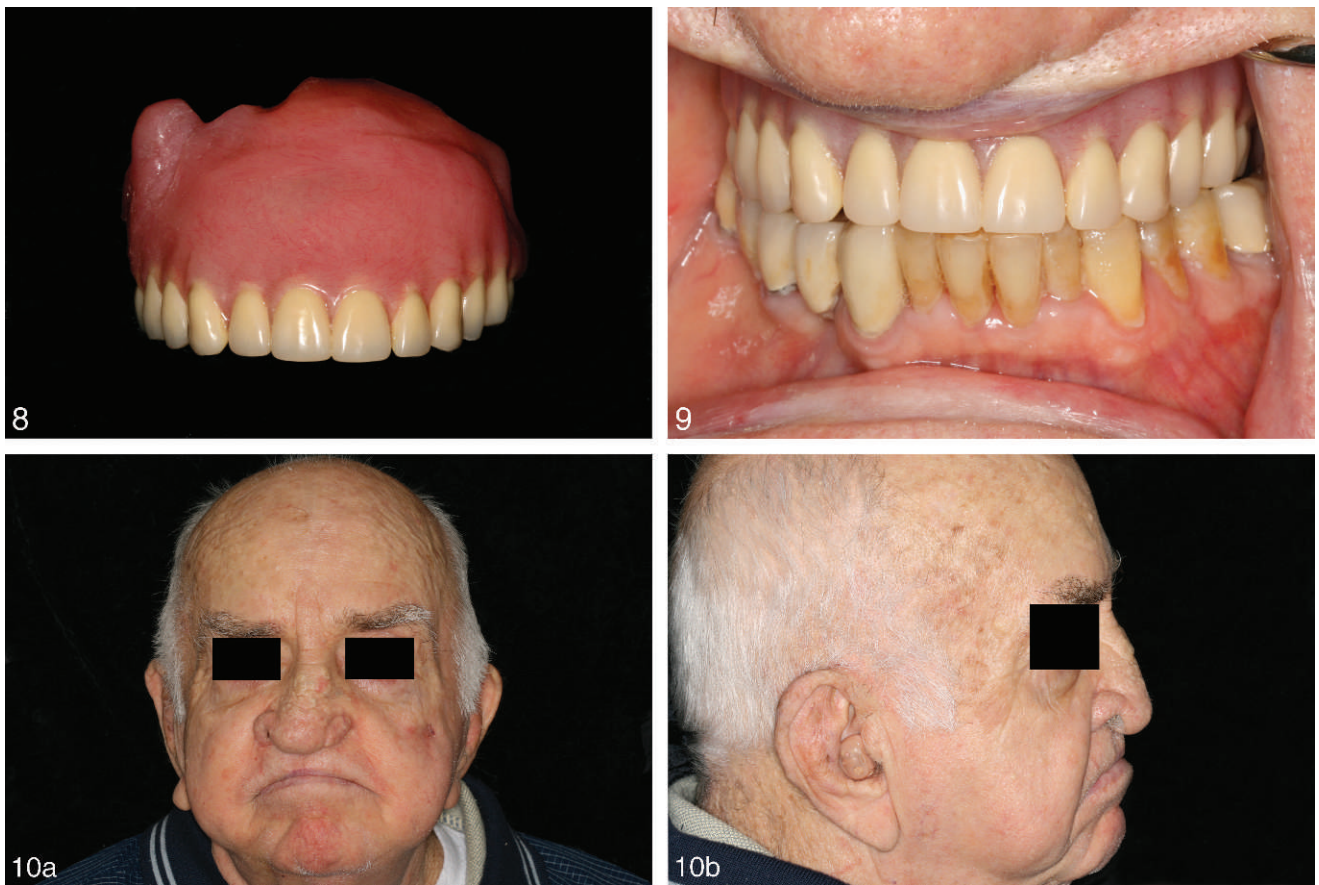**FIGURES 4–7.** **FIGURE 4.** Panoramic radiograph showing the pterygoid implants with locator abutments and an implant in the right zygoma. Note the missing anatomic structures in comparison to Figure 1. Both locator abutments were confirmed as completely seated before prosthodontic treatment. **FIGURE 5.** Intraoral view of the patient’s surgical defect showing implant abutments on pterygoid implants. **FIGURE 6.** Definitive cast of the surgical defect. Compare with Figure 5. **FIGURE 7.** Obturator that was trimmed hollow from the palatal surface. Note the lid ready to be placed.

Nobel Biocare, Yorba Linda, Calif) with good primary stability. These implants engaged the pterygoid plates and had an angle of about 45° to the horizontal plane. Zygomatic implant placement on the right side was aborted because of bone insufficiency, and a regular root-form implant of dimensions 4.3 mm × 13 mm (Replace Select, Nobel Biocare) was placed instead (Figure 2). This implant had good primary stability. A zygomatic implant (Zygoma TiUnite, Branemark System-Nobel Biocare) was placed on the left side; however, it failed 2 weeks after initial placement. The patient continued to wear his interim obturator during the healing period (Figure 3a and b).

Six months after implant surgery, a second-stage surgery was performed and the pterygoid implants were uncovered. They demonstrated no mobility, bone loss, or clinical signs of infection. Abutments (Locator, Zest Anchors, Escondido, Calif) 5 mm in

cuff heights were torqued to 25 Ncm on both of the implants (Figures 4 and 5). At this stage, another attempt was made to place a zygomatic implant on the left side but was unsuccessful because of the quality and quantity of the bone. After the healing period, a custom abutment was fabricated to connect to the root-form implant that had been placed in the right zygoma. This abutment was only intended to serve as a vertical stop to the obturator prosthesis as it was deemed unusable for prosthesis retention purposes.

A new diagnostic impression was made to begin fabrication of the definitive obturator. Border molding and final impression procedures were then performed, and a definitive cast was poured in type III dental stone (Figure 6). A heat polymerized record base (Lucitone, Dentsply, York, Pa) was fabricated on this cast and carefully adjusted in the mouth for proper fit. Minor remnant of the hard



**FIGURES 8–10.** **FIGURE 8.** Frontal view of the hollow obturator (31.9 g) to demonstrate the volume of tissues restored. **FIGURE 9.** Intraoral view of the obturator prosthesis in maximum intercuspation. **FIGURE 10.** (a) Posttreatment frontal view of the patient with obturator in place. (b) Posttreatment profile view of the patient with obturator in place. Compare with Figure 3b to note restoration of the midfacial profile.

palate and the custom abutment of the implant in the right zygoma helped to provide a vertical stop for the record base. Small holes were predrilled on this record base, and the locator attachments were connected to it intraorally, using autopolymerizing resin. Thereafter, standard prosthodontic principles were followed to obtain facebow, maxillomandibular relationship records, and denture teeth arrangement. After approval of the wax trial prosthesis by the patient and his family, it was processed using heat-polymerized acrylic resin.

To decrease the weight of the prosthesis and aid in its retention, it was decided to hollow the prosthesis. The procedure was done from the palatal surface, yet maintaining the established palatal contours using the technique described by Paprocki et al.<sup>32</sup> Light-polymerizing resin material was used to form the lid of the hollow prosthesis (Figure 7). This procedure significantly reduced the

weight of the prosthesis (Figure 8). The implant attachment patrices (Locator) were then placed in the completed prosthesis. After finishing and polishing, the obturator was then inserted in the patient's mouth and evaluated (Figure 9).

Intelligibility of speech and swallowing ability were deemed satisfactory to the clinician, the patient, and the patient's family. The patient was particularly pleased with the restoration of dento-facial esthetics and the midfacial profile (Figure 10a and b). The patient and his family were trained in the insertion and removal of the prosthesis. Patient was instructed about the lack of sufficient support for the prosthesis and told to chew only soft foods because of the potential for dislodgement. The patient was stressed about the limitations of the prosthesis and related complications. Home care instructions for the implants, prosthesis, and mandibular natural teeth were reviewed with the



patient. The patient initially experienced difficulties inserting and seating of the prosthesis over the pterygoid implant attachments because of the posterior nature of their position. At a 1.5-year follow-up after prosthesis delivery, both pterygoid implants were stable, and the patient reported no complications with the obturator. The patient remained satisfied with the prosthesis for speech, swallowing, and esthetics. He was placed on a 1-year follow-up with the oncology team.

### DISCUSSION

Various methods have been described for reconstruction and rehabilitation of patients who require bilateral maxillectomy. They include obturator prosthesis, myocutaneous free flaps, and osseocutaneous free flaps.<sup>33,34</sup> Both types of free flaps can successfully close the surgical defect and establish a partition between nasal and oral cavities, eliminating the need for a removable oral prosthesis. However, myocutaneous free flaps do not provide support for conventional complete denture prosthesis. The bulky and flaccid nature of the flap precludes a sound supporting foundation for the denture prosthesis. Furthermore, presence or absence of the soft palate may affect the treatment choice and outcome in these patients. Patients who request this option to eliminate the use of an obturator need to be educated that they may not be able to wear any prosthesis in the future; this may affect their dentofacial esthetics and eating habits.

Therefore, osseocutaneous flaps may be an option for some patients. Dental implants placed in osseocutaneous free flaps are known to be successful for prosthetic rehabilitation.<sup>35,36</sup> This option may provide the most optimal form of rehabilitation as it can successfully close the surgical defect and provide the patient with an implant-supported prosthesis that restores dentofacial esthetics and function. However, free-flap techniques are associated with additional expenses and morbidities, which may preclude their use on elderly patients with medical problems. Early detection of postoperative recurrence is difficult when defects are closed with a free flap.<sup>17</sup> Additionally, free-flap techniques often require multiple revision surgeries, adding to the complexity of care. These were the reasons for not choosing

the free-flap procedure in our patient, who had significant medical comorbidities.

It was initially planned to support the patient's obturator with a zygomatic and a pterygoid implant on each side of the oral cavity. However, the quantity and quality of bone precluded the successful placement of implants in the patient's zygoma. To aid in providing a vertical stop, a regular root-form implant was attempted in the right zygoma, which integrated successfully. This only aided in providing adjuvant support for the obturator. Admittedly, incorporating a zygomatic implant on each side would have exponentially increased the success of this prosthesis. Stereolithic surgical guides were considered but not used because of the additional expenses for the patient; in addition, the open surgical defect provided better access to the surgeon for conventional technique of implant placement into the zygoma and pterygoid plates. The biomechanics of this obturator being primarily supported by 2 pterygoid implants and a small remnant of the posterior hard palate represented a class III lever system. Only minimal contact was established with the vomer for additional support. Therefore, all occlusal contacts in the anterior region were eliminated, and the patient was given detailed instructions to consume soft foods only. Fabrication of the obturator without incorporation of prosthetic teeth was considered to decrease the weight and ameliorate issues of retention and occlusal load on the prosthesis; however, esthetics and quality of life were one of the primary concerns for this patient and therefore denture teeth were added to the prosthesis and it was made hollow and light.

### SUMMARY

This clinical report described the maxillofacial rehabilitation of a patient undergoing bilateral maxillectomy using pterygoid implants. Zygomatic implants were also attempted but failed to osseointegrate. Therefore, pterygoid implants were the primary source of support for the obturator. The advantages and disadvantages of various options for rehabilitation of patients undergoing bilateral maxillectomy were discussed in this article. The use of pterygoid implants may provide a viable option for clinicians in the rehabilitation of patients undergoing bilateral maxillectomy.

## REFERENCES

1. The glossary of prosthodontic terms. *J Prosthet Dent.* 2005; 94:50–52.
2. Ohngren L. Malignant tumors of the maxillo-ethmoidal region. *Acta Otolaryngol.* 1933;19:476.
3. Sakai S, Fuchihata H, Hamasaki Y. Treatment policy for maxillary sinus carcinoma. *Acta Otolaryngol.* 1976;82:172–181.
4. Aramany MA. Basic principles of obturator design for partially edentulous patients. Part I: classification. *J Prosthet Dent.* 1978;40:554–557.
5. Earley MJ. Primary maxillary reconstruction after cancer excision. *Br J Plast Surg.* 1989;42:628–637.
6. Spiro RH, Strong EW, Shah JP. Maxillectomy and its classification. *Head Neck.* 1997;19:309–314.
7. Brown JS, Rogers SN, McNally DN, Boyle M. A modified classification for the maxillectomy defect. *Head Neck.* 2000;22:17–26.
8. Cordeiro PG, Santamaria E. A classification system and algorithm for reconstruction of maxillectomy and midfacial defects. *Plast Reconstr Surg.* 2000;105:2331–2346.
9. Okay DJ, Genden E, Buchbinder D, Urken M. Prosthodontic guidelines for surgical reconstruction of the maxilla: a classification system of defects. *J Prosthet Dent.* 2001;86:352–363.
10. Uckan S, Oguz Y, Uyar Y, Ozyesil A. Reconstruction of a total maxillectomy defect with a zygomatic implant-retained obturator. *J Craniofac Surg.* 2005;16:485–489.
11. Cheng AC, Somerville DA, Wee AG. Altered prosthodontic treatment approach for bilateral complete maxillectomy: a clinical report. *J Prosthet Dent.* 2004;92:120–124.
12. Oh WS, Roumanas E. Dental implant-assisted prosthetic rehabilitation of a patient with a bilateral maxillectomy defect secondary to mucormycosis. *J Prosthet Dent.* 2006;96:88–95.
13. Ortegon SM, Martin JW, Lewin JS. A hollow delayed surgical obturator for a bilateral subtotal maxillectomy patient: a clinical report. *J Prosthet Dent.* 2008;99:14–18.
14. Sjövall L, Lindqvist C, Hallikainen D. A new method of reconstruction in a patient undergoing bilateral total maxillectomy. *Int J Oral Maxillofac Surg.* 1992;21:342–345.
15. Parel SM, Brånemark PI, Ohrenell LO, Svensson B. Remote implant anchorage for the rehabilitation of maxillary defects. *J Prosthet Dent.* 2001;86:377–381.
16. Schmidt BL, Pogrel MA, Young CW, Sharma A. Reconstruction of extensive maxillary defects using zygomatic implants. *J Oral Maxillofac Surg.* 2004;62:82–89.
17. Tamura H, Sasaki K, Watahiki R. Primary insertion of implants in the zygomatic bone following subtotal maxillectomy. *Bull Tokyo Dent Coll.* 2000;41:21–24.
18. Laney WR. *Glossary of Oral and Maxillofacial Implants.* Chicago, Ill: Quintessence Publishing; 2007.
19. Tulasne JF. Implant treatment of missing posterior dentition. In: Albrektsson T, Zarb GA, eds. *The Branemark Osseointegrated Implant.* Chicago, Ill: Quintessence Publishing; 1989;103–108.
20. Tulasne JF. Osseointegrated fixtures in the pterygoid region. In: Worthington P, Branemark PI, eds. *Advanced Osseointegration Surgery: Applications in the Maxillofacial Region.* Chicago, Ill: Quintessence Publishing; 1992;182–188.
21. Graves SL. The pterygoid plate implant: a solution for restoring the posterior maxilla. *Int J Periodont Restor Dent.* 1994;14: 512–523.
22. Vrielinck L, Politis C, Schepers S, Pauwels M, Naert I. Image-based planning and clinical validation of zygoma and pterygoid implant placement in patients with severe bone atrophy using customized drill guides. Preliminary results from a prospective clinical follow-up study. *Int J Oral Maxillofac Surg.* 2003;32:7–14.
23. Valerón JF, Valerón PF. Long-term results in placement of screw-type implants in the pterygomaxillary-pyramidal region. *Int J Oral Maxillofac Implants.* 2007;22:195–200.
24. Peñarrocha M, Uribe R, García B, Martí E. Zygomatic implants using the sinus slot technique: clinical report of a patient series. *Int J Oral Maxillofac Implants.* 2005;20:788–792.
25. Krekmanov L. Placement of posterior mandibular and maxillary implants in patients with severe bone deficiency: a clinical report of procedure. *Int J Oral Maxillofac Implants.* 2000;15:722–730.
26. Balshi TJ, Lee HY, Hernandez RE. The use of pterygomaxillary implants in the partially edentulous patient: a preliminary report. *Int J Oral Maxillofac Implants.* 1995;10:89–98.
27. Reychler H, Olszewski R. Intracerebral penetration of a zygomatic dental implant and consequent therapeutic dilemmas: case report. *Int J Oral Maxillofac Implants.* 2010;25:416–418.
28. Roumanas ED, Nishimura RD, Davis BK, Beumer J III. Clinical evaluation of implants retaining edentulous maxillary obturator prostheses. *J Prosthet Dent.* 1997;77:184–190.
29. Balshi TJ, Wolfinger GJ. Analysis of 356 pterygomaxillary implants in edentulous arches for fixed prosthesis anchorage. *Int J Oral Maxillofac Implants.* 1999;14:398–406.
30. Balshi SF, Wolfinger GJ, Balshi TJ. Analysis of 164 titanium oxide-surface implants in completely edentulous arches for fixed prosthesis anchorage using the pterygomaxillary region. *Int J Oral Maxillofac Implants.* 2005;20:946–952.
31. Peñarrocha M, Carrillo C, Boronat A, Peñarrocha M. Retrospective study of 68 implants placed in the pterygomaxillary region using drills and osteotomes. *Int J Oral Maxillofac Implants.* 2009;24:720–726.
32. Paprocki GJ, Jacob RF, Kramer DC. Seal integrity of hollow-bulb obturators. *Int J Prosthodont.* 1990;3:457–462.
33. Davison SP, Sherris DA, Meland NB. An algorithm for maxillectomy defect reconstruction. *Laryngoscope.* 1998;108:215–219.
34. Sakuraba M, Kimata Y, Ota Y, et al. Simple maxillary reconstruction using free tissue transfer and prostheses. *Plast Reconstr Surg.* 2003;111:594–598.
35. Chiapasco M, Biglioli F, Autelitano L, Romeo E, Brusati R. Clinical outcome of dental implants placed in fibula-free flaps used for the reconstruction of maxillo-mandibular defects following ablation for tumors or osteoradionecrosis. *Clin Oral Implants Res.* 2006;17:220–228.
36. Gbara A, Darwich K, Li L, Schmelzle R, Blake F. Long-term results of jaw reconstruction with microsurgical fibula grafts and dental implants. *J Oral Maxillofac Surg.* 2007;65:1005–1009.