

# An Early Loaded Implant-Supported Mandibular Complete Arch Fixed Prosthesis in a Young Completely Edentulous Patient: A Case Report

Miriam Mathew, MDS<sup>1,2\*</sup>  
 Bobby John, MDS<sup>3</sup>  
 Arun George, MDS<sup>4</sup>

The restoration of the mandibular arch up to the first molars with 5 one-piece implants presents a viable and cost-effective treatment plan in patients with adequate bone volume and favorable ridge relationships. The early loading of the implants with a provisional restoration reduces the period of edentulousness and restores the patient's ability to eat, talk, and smile effectively. Implants in younger patients prevent resorption of the residual alveolar ridge. This article presents a case report of the restoration of an edentulous mandibular arch with an early loaded implant-supported fixed restoration in a young patient.

**Key Words:** *early loading, fixed, mandibular, implant, prosthesis*

## INTRODUCTION

Completely edentulous patients with adequate bone height and width can be successfully restored with fixed implant-supported prostheses as opposed to implant-supported overdentures. Younger patients benefit tremendously in the long term as the implants preserve bone,<sup>1</sup> enhance esthetics<sup>2</sup> and phonetics,<sup>2</sup> and restore the patients' masticatory efficiency<sup>3</sup> and self-esteem.<sup>4-6</sup> Finances, ridge anatomy, jaw relationships, prosthesis design, and patient factors permitting, the edentulous mandible can be restored successfully with an early loaded implant-supported fixed prosthesis.

A case report describing the restoration of an edentulous mandibular arch using 5 one-piece

implants with the early loading approach is presented in this article. The advantages of implant-supported fixed restorative therapy and the various implant-supported fixed restorative modalities in practice to restore completely edentulous mandibular arches are also discussed.

### ***Advantages of implant-supported fixed complete arch prostheses over implant-supported and retained removable overdentures<sup>7</sup>***

1. The labial flange along with the maxillary anterior teeth of a maxillary denture help in restoring upper-lip fullness and support, whereas the profile of the lower face is reestablished to a large extent by the mandibular anterior teeth and to a lesser extent by the mandibular labial flange.
2. Chair time, laboratory fees, and component cost for a fixed implant-supported restoration work out to be almost the same as fully implant-supported overdenture (removable prosthesis type 4, RP-4).<sup>8-15</sup>
3. A fixed restoration has the advantage of being similar to natural teeth by virtue of its being a fixed prosthesis, whereas an implant-supported

<sup>1</sup> Private practice, International Dental Centre-Kochi, Kerala, India.

<sup>2</sup> Department of Prosthodontics, Mar Baselious Dental College, Kerala, India.

<sup>3</sup> Department of Oral and Maxillofacial Surgery, Government Dental College, Kerala, India.

<sup>4</sup> Department of Oral and Maxillofacial Surgery, Mar Baselious Dental College, Kerala, India.

\* Corresponding author, e-mail: geoliz@gmail.com

DOI: 10.1563/AAID-JOI-D-10-00182

- overdenture remains a removable prosthesis. It therefore has a psychological advantage.<sup>9,16-18</sup>
4. The design of the mandibular fixed restoration prevents food entrapment to a greater extent as compared with the removable overdenture, which permits food to travel and lodge beneath the denture borders and flanges during the mastication and deglutition of food.
  5. The daily oral hygiene regimens for a mandibular overdenture and a fixed full arch prosthesis are comparable as ridge lap pontics are not always required (except in the anterior region) for speech and esthetics.
  6. Removable implant overdentures require more maintenance visits by the patient and present more frequent prosthetic-related complications than fixed restorations.<sup>8</sup>

#### ***Treatment strategies for mandibular complete arch implant supported fixed prostheses***

Among others, factors to be taken into consideration while treatment planning for mandibular complete arch implants supported prosthesis are the following:

- Evaluation of the maxillary-mandibular relationship.
- Prosthesis design.
- Evaluation of the bone quantity and quality, both corono-apical and buccal-palatal/lingual.
- Evaluation of the quality and quantity of soft tissue.
- Implant number and their location on the ridge.
- Timing and type of occlusal loading.

#### ***Implant number and location: timing and type of occlusal loading***

The traditional Branemark approach<sup>19</sup> follows the delayed loading protocol, with 4 or 6 root form implants inserted between the mental foramina. The implants are splinted and restored with distal cantilevers off each side to replace the posterior teeth after a healing period.

Misch<sup>7</sup> proposed various treatment options for restoring the completely edentulous mandibular arch with a fixed implant-supported prosthesis: placing 4 to 5 implants between the mental foramina and additional implants over the foramina or at posterior locations distal to the foramina. The

increase in the number of implants and their distal locations increases the implant surface area and A-P spread and reduces distal cantilevers. The former option necessitates placing wider-diameter implants with enhanced surface area as the available bone over the foramina is limited in the apical coronal dimension.

The mandible exhibits medial movement on opening and protrusive jaw movements, distal to the mental foramina. The medial movement has been measured to be as much as 0.8 mm in the first molar area to 1.5 mm in the ramus area. The mandible also undergoes torsion. Splitting the fixed prostheses in full arch mandibular restorations instead of cross-arch splinting prevents lateral stresses to the implants brought about by mandibular flexure.<sup>7,20</sup> Zarone et al<sup>21</sup> evaluated the biomechanical effect of mandibular functional flexure on stress buildup in implant-supported fixed restorations. Their analysis of the stress distributions generated by the different restorative patterns suggests that a division of the superstructure at the level of the symphysis significantly restores the natural functional flexure of the mandible.

The Branemark Novum concept (Nobel Biocare AB, Göteborg, Sweden) was introduced to load implants immediately with a definitive fixed prosthesis in the edentulous mandible within a single day. This concept is based on the use of prefabricated templates to allow precise placement of 3 implants and a prefabricated bar structure for the prosthetic procedure, which eliminates the time required for conventional impressions and a casting. To obtain 3-dimensional stability in these prefabricated templates, surgical bone reduction may be necessary to obtain a stable adaptation between the templates and the recipient bone site.

The All-on-4 and the All-on-4 with Nobel Guide clinical solutions approaches developed by Dr Paulo Maló<sup>22</sup> is another immediate loading concept in which 4 implants support a mandibular fixed complete-arch prosthesis provided they are placed as "cornerstones": 2 posteriorly and 2 anteriorly, all well spread. The protocol uses a guide for the positioning and inclination of the implants. The posterior implants are tilted, which helps avoid the mental foramina, and they can be anchored in better-quality anterior bone and offer maximum support for the prosthesis by reducing cantilevers.

They also help to reduce the need for bone grafting by increasing bone-to-implant contact.

The International Team of Implantology (ITI)<sup>23</sup> in 2004 defined the various types of loading categories based on the time of surgical implant placement to attachment of a prosthetic restoration and whether or not the prosthesis was in occlusion.

The ITI definitions of the various categories are as follows:

- Conventional loading: prosthesis attached to the implants in a second procedure for a minimum of 3 months healing following implant placement.
- Immediate restoration: a restoration inserted within 48 hours of implant placement but not in direct occlusion with the opposing dentition.
- Immediate loading: a restoration placed in occlusion with the opposing dentition within 48 hours of implant placement.

There have been 2 protocols for immediate load in the complete edentulous patient.<sup>24</sup> One is to immediately load additional implants with a provisional restoration, which is not required for the definitive restoration. If these immediately loaded implants fail to integrate, the submerged implants may be uncovered later for the definitive restoration. The second protocol often uses a greater number of implants than used in the 2-stage approach and loads all of the implants at the same time. Cross-arch splinting, sharing of the load, greater surface area, and improved biomechanical distribution reduce chances of overload.

- Early loading: placement of a restoration in occlusion with the opposing dentition at least 48 hours after implant placement but no later than 3 months afterward.
- Delayed loading: placement of prosthesis on implants in a second procedure sometime after the conventional healing period of 3 to 6 months.

Progressive loading<sup>25</sup> is another loading category in which

- the implants are exposed to the full magnitude of functional forces after an extended time period,
- the dominant forces are limited to those in the vertical direction, and
- bone adapts to a gradual increase in loads.

Histological observations<sup>26–31</sup> clearly demonstrated that osseointegration could occur under loaded

conditions. From these observations, it is clear that osseointegration can occur with all healing time periods under certain conditions.

The early loading protocol for implant placement is clinically documented.

Esposito et al<sup>32</sup> identified randomized controlled clinical trials (RCTs) of root-form osseointegrated oral implants and compared implant-loading protocols: immediate vs conventional loading, early vs conventional loading, immediate vs early loading, and occlusally vs nonocclusally loaded implants, in which immediately occurred within 1 week, early occurred between 1 week and 2 months, and conventionally occurred after 2 months. They concluded that

It is possible to successfully load dental implants immediately or early after their placement in selected patients, though not all clinicians may achieve optimal results. It is unclear whether it is beneficial to avoid occlusal contacts during the osseointegration phase. Trends suggest that immediately loaded implants fail more often than those conventionally loaded, but less commonly than those loaded early. If a clinician wishes to load the implants early, it might be wiser to load them immediately (within 1 week) rather than waiting for 1 or 2 months. A high degree of primary implant stability (high value of insertion torque) seems to be one of the prerequisites for a successful immediate/early loading procedure. More well designed RCTs according to the CONSORT guidelines are needed and should be reported.<sup>32</sup>

Gallucci et al<sup>33</sup> conducted a systematic review to present the current scientific and clinical evidence related to implant-supported rehabilitations for the edentulous mandible and maxilla. They concluded that

while the highest level of scientific and clinical validation was found for conventional loading with mandibular overdentures and maxillary fixed dental prostheses, insufficient scientific or clinical documentation/validation was found for immediate loading of maxillary overdentures, as well as for immediate loading of immediately placed implants combined with fixed or removable dental prostheses in either jaw. All other loading protocols for edentulous arches showed different degrees of clinical documentation.<sup>33(p140)</sup>

The following were the conclusions of Gallucci et al<sup>33</sup> for early loading of mandibular fixed implant-supported rehabilitations:

- Early loading of mandibular fixed implant prostheses is clinically documented.
- Implant survival rates (1 to 3 years) range from 98.6% to 100%.
- Prosthodontic survival rates range from 97.8% to 100%.
- Prosthesis design was full arch, one piece, supported by four to five implants.<sup>33(pX)</sup>

Studies<sup>34–36</sup> support excellent success rates for early loading of a full arch, implant-supported prosthesis that uses rigid cross-arch stabilization.

A prospective study by Randow et al<sup>34</sup> reported a success rate of 100% after 18 months in 16 patients who had received full arch splinted restorations on 5 to 6 implants, which were loaded after a period of 16 days. Ericsson et al<sup>35</sup> in a prospective study of the same group of patients reported a 100% success rate after 6 years.

According to Norkin et al,<sup>37</sup> clinical reports by many authors comparing conventional, early, and immediate protocols have not shown significant differences within the limits of their studies, and summarizing the knowledge obtained through research and clinical observations, they stated that for a dental implant to achieve osseointegration, 3 factors are important:

1. Placement of an implant composed of or coated with a suitable biocompatible material, such as titanium, hydroxyl apatite, zirconium oxide, or other.
2. Site preparation without excessive thermal, traumatic, bacterial, or biological injury to the host bed.
3. Adequate stabilization of the implant to eliminate movement below the threshold of deleterious micro movement, estimated to be 50  $\mu\text{m}$  to 150  $\mu\text{m}$ .<sup>38</sup>

As the immediate loading approach is becoming more popular among dentists and patients alike, experienced clinicians and researchers<sup>37</sup> caution that “the opportunities for failure with immediate function implant procedures are theoretically increased due to their potential complexity. Similarly, the consequences for failure are magnified as compared to conventional treatment protocols

due to heightened patient expectations and the frequent lack of a secondary treatment plan.”

## CASE REPORT

### *Examination, diagnosis, and treatment plan*

A 30-year-old unmarried female patient presented to the department with bimaxillary protrusion and incompetent lips. Examination revealed missing maxillary anteriors and a denuded posterior dentition. The remaining teeth and root stumps were periodontally compromised. The occlusal plane posteriorly was uneven owing to the supraeruption of the remaining teeth. The patient was unhappy about her appearance, was withdrawn, and showed signs of depression. It was decided that the patient, being young, would benefit from an implant-supported and implant-retained fixed restoration on 5 implants rather than an implant-retained and tissue-supported removable overdenture restoration.

The patient accepted the treatment plan of prosthetic rehabilitation with a maxillary complete denture and a mandibular full arch implant-supported and implant-retained fixed prosthesis.

### *Extraction of remaining teeth: maxillary and mandibular preimplant provisional removable prosthetic phase*

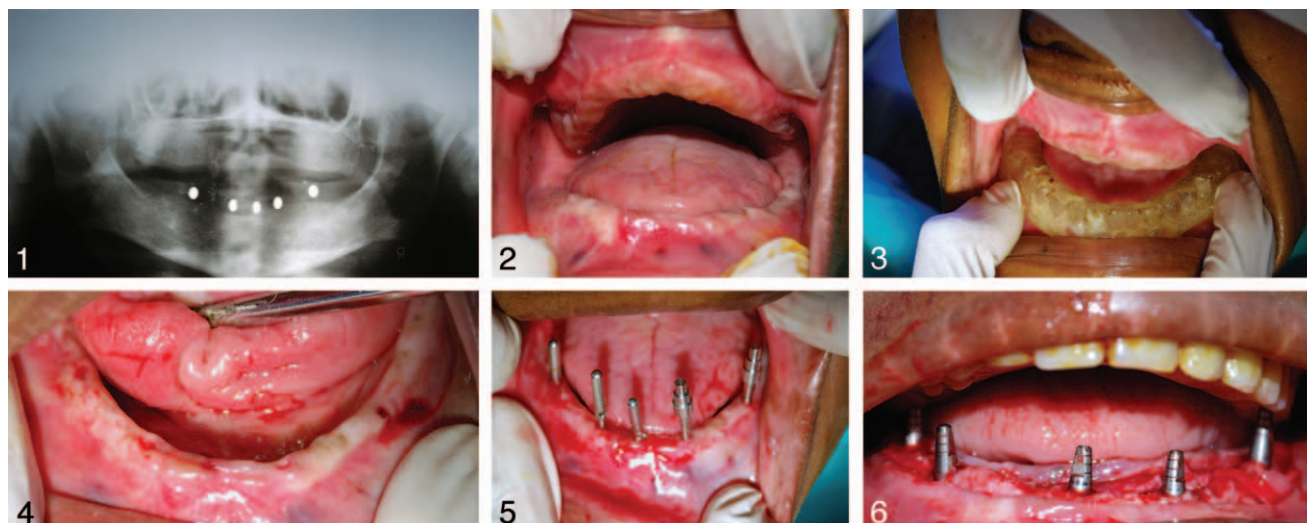
Extraction of the remaining teeth and root stumps was carried out. After a 3-month healing period, provisional upper and lower complete denture fabrication and insertion were completed.

### *Presurgical planning phase*

The lower complete denture was used as a guide for the approximate locations of implants. Five-mm diameter stainless-steel ball bearings were glued onto the occlusal and lingual surfaces of the lower right central incisor, lower canines, and first molars of the trial denture at the locations of the proposed implant sites, and an orthopantograph (OPG) was taken (Figure 1).

The approximate available height of bone at the proposed implant sites was quantified after adjusting for radiographic magnification.

The available width of bone was evaluated at the proposed implant sites by marking the sites on the intaglio surface of the lower trial denture and transferring the locations onto the ridge. The



**FIGURES 1–6.** **FIGURE 1.** Pretreatment orthopantograph with 5-mm-diameter metal ball bearings. **FIGURE 2.** Intraoral view, pretreatment. **FIGURE 3.** Surgical template positioned on the edentulous mandibular ridge. **FIGURE 4.** Ten-millimeter-long pilot osteotomies, made using the surgical stent. **FIGURE 5.** Paralleling pins positioned within the osteotomies to verify parallelism and angulation of the osteotomies. **FIGURE 6.** One-piece implants inserted at Nos. 19, 22, 25, 29, and 30 tooth locations.

approximate width of the residual ridge was then measured intraorally at the proposed sites. The available bone height and width were found to be favorable for the placement of 2.8 mm D × 13 mm L, 1-piece implants in the anterior region and 3.7 mm D × 10 mm L, 1-piece (abutment-integrated) implants posteriorly.

#### ***Surgical stent fabrication***

The lower trial denture was duplicated in clear acrylic autopolymerizing resin to create a surgical stent. Drill holes, 2.5 mm in diameter, were made at the lower right and left first molars, canines, and the left central incisor sites on the acrylic stent.

#### ***Premedication and local anesthesia***

The patient was premedicated with the standard antibiotic prophylactic protocol and analgesics and anti-inflammatory drugs. Local anesthesia was administered by submucosal infiltration labially, buccally, and lingually using lignocaine 2% with 1 in 100 000 epinephrine (Figure 2).

#### ***Surgical phase***

The surgical stent was stabilized on the ridge over the mucosa, and the pilot drill (2 mm) was used to drill 10-mm-long osteotomies at the No. 30, 27, 25, 22, and 19 tooth locations (Figure 3 and Figure 4).

Paralleling pins were inserted into the pilot

osteotomies to confirm parallelism and angulation of the osteotomies (Figure 5).

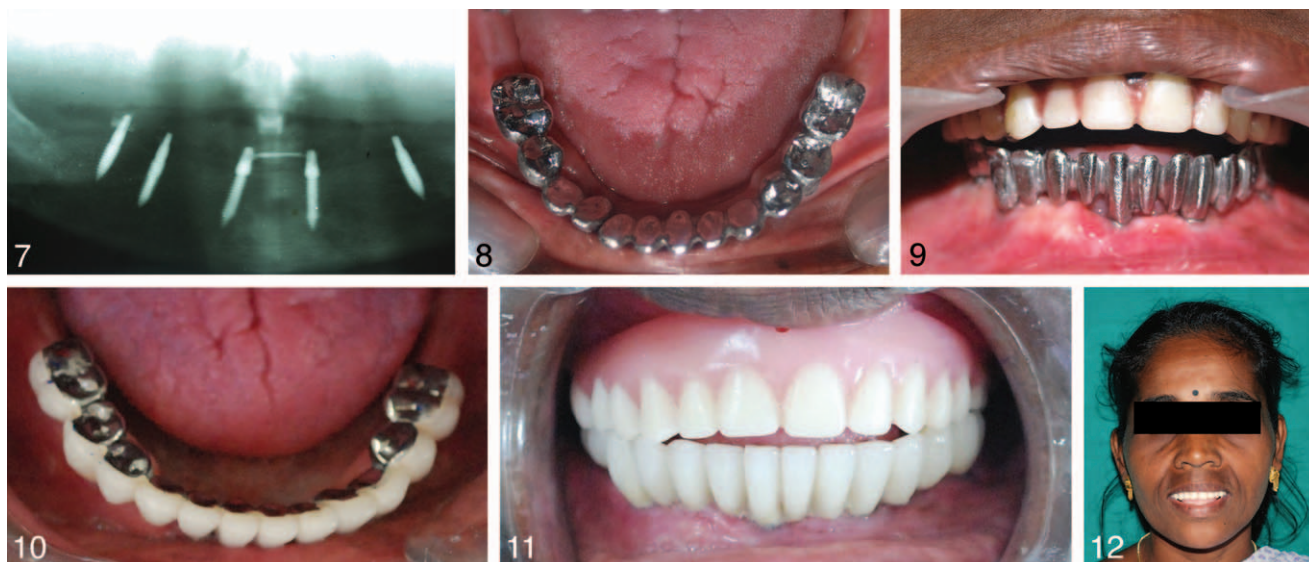
Buccal and lingual flaps were then reflected to fully expose the ridge and the location of the pilot osteotomies. The location of the No. 27 osteotomy was abandoned as the width of the available bone was found to be insufficient, and a new osteotomy was made at the No. 29 location.

The osteotomies were then prepared to the full depth and width, and 5 one-piece implants (EZ Hi-Tec Implants, Lifecare Devices Private Limited, Herzlia, Israel) were inserted. All of the implants demonstrated primary stability at the time of insertion (Figure 6).

Two implants, 2.8 mm in diameter and 13 mm long, were placed at the lower left canine and lower right central incisor locations; 1 implant, 3.7 mm in diameter and 13 mm long, was placed at the lower right second premolar location and 2 implants, 3.7 mm in diameter and 10 mm long, were placed at the right and left first molar locations. The flaps were sutured with modified horizontal mattress sutures using 4-0 silk sutures. An OPG was taken postoperatively (Figure 7).

#### ***Postoperative medication and postoperative instructions***

The patient was prescribed antibiotics, analgesics, and anti-inflammatory medication; given postoperative instructions; and advised a soft diet.



**FIGURES 7–12.** **FIGURE 7.** Postoperative orthopantograph. **FIGURE 8** Sectioned metal frame, work try in. **FIGURE 9.** Sectioned metal framework and maxillary trial denture. **FIGURE 10.** Ceramo-metal restorations cemented onto implant abutments. **FIGURE 11.** Maxillary complete denture and mandibular implant-supported ceramo-metal restorations. **FIGURE 12.** Posttreatment.

### ***Provisional mandibular fixed prosthetic phase***

The sutures were removed after a 2-week healing period.

A complete arch, splinted temporary acrylic prosthesis was fabricated and cemented in place with definitive cement to avoid dislodgement of the prosthesis during the healing period. Uniform contacts on the implant-supported temporary prosthesis opposed by the upper complete denture were ensured in centric relation occlusion. The patient was advised to continue a soft diet.

### ***Definitive maxillary removable and mandibular fixed prosthetic phase***

After 3 months, the patient was recalled, and the temporary prosthesis was removed from the implant abutments. Clinical examination revealed that the implants were nonmobile and free of infection.

Radiographic examination revealed bone levels up to the first thread of all 5 implants.

Jaw relations were registered. A new maxillary trial denture and a split full arch metal framework of 12 units for a ceramometal restoration for the mandibular arch were fabricated. The anterior plane of the maxillary denture was raised to reduce excessive incisal visibility (Figures 8 and 9).

The framework was sectioned between the

lower left canine and lower left lateral incisor locations, so that the shorter 4-unit section (Nos. 22, 21, 20, and 19) was supported by 2 implants (2.8 mm in diameter and 13 mm long; 3.7 mm in diameter and 10 mm in length).

The longer 8-unit section (Nos. 23, 24, 25, 26, 27, 28, 29, and 30) was supported by 3 implants (2.8 mm in diameter and 13 mm long; 3.7 mm in diameter and 10 mm long) with 2 anterior cantilever units (Nos. 24 and 23; Figure 10).

The framework sections were tried in, and a passive fit of the sections was ensured. The mandibular full arch ceramo-metal restoration was completed along with the definitive maxillary complete denture (Figure 11).

The sectioned restorations were cemented with a soft access cement to enable future retrievability (Figure 12).

A dramatic improvement in the patient's self-esteem was observed as she now had "fixed teeth" in her lower jaw.

### **DISCUSSION**

Six to 7 implants and a fixed ceramo-metal implant-supported restoration in sections were planned to restore the mandibular edentulous arch. The patient could not afford more implants even though the

options with more implants and better support was given to her.

The number of implants and prosthesis design were intended to restore the patient successfully with a fixed implant-supported restoration while keeping the costs as low as possible and without incorporating any major flaws in the design that could lead to failure in the future.

The prosthesis was sectioned in such a way that the longer section and the anterior cantilever would be supported by 3 implants and the shorter section (without any cantilever) by 2 implants. The maximum biting force is in the molar region and decreases as measurements progress anteriorly.<sup>39,40</sup> The situation of overload has been reduced as the cantilevers are in the region of the central and lateral incisors where forces would be less.

The traditional Branemark approach uses 5 splinted implants between the mental foramina with distal cantilevers bilaterally. In this prosthesis design, posterior cantilevers have been eliminated.

If the upper arch had been fixed, we would have placed more than 5 implants, at least 7, if the patient had had the financial capability to do so at the time of treatment. In the meantime, she could have an implant-retained mandibular overdenture with 2 implants positioned anteriorly independent of each other, which could be used as an interim prosthesis. A fixed restoration could be constructed at a later stage after placing more implants when the patient would be able to afford them.

If the patient requested a fixed prosthesis in the future, we would replace the lower restoration and put in more 1-piece implants at the right canine and left premolar area. The new implants would be wider-diameter ones where possible. A new prosthesis splinting the existing implants with the new implants would be constructed. The new prosthesis would be in 2 sections without any cantilevers. This would, of course, create an additional financial burden on the patient.

Two 2.8-mm D × 13-mm L implants were placed. The 2.9-mm-diameter hybrid implants are almost as large as the 3.0-mm-diameter implants, which are the smallest diameter regular implants. A retrospective study by Froum et al<sup>41</sup> reported on the results of the use of a screw-retained narrow-diameter implant (NDI) system as an option for implant placement in areas of limited bone volume. They reported no implant failures for 5 years postloading,

with a 100% survival rate. The diameters used were 1.8 mm, 2.2 mm, and 2.4 mm. They concluded that "these NDIs present a cost-effective alternative for restoring limited spaces with implant restorations, without the bone augmentation or orthodontic procedures required for conventional fixed restorations. The NDI system is approved by the U.S. Food and Drug Administration for long-term use."<sup>41</sup>(p449)

The occlusal scheme of choice in a situation with a traditional soft-tissue-supported complete maxillary denture opposing a mandibular implant-supported restoration is a bilaterally balanced occlusion with a medially positioned lingualized tooth setup and a raised posterior plane.<sup>42</sup>

In this case, we provided uniform bilateral contacts in centric and eccentric positions with lingual cusps in contact in the position of centric occlusion to additionally stabilize the maxillary denture.<sup>43–45</sup>

The maxillary anterior plane was raised. This was done to reduce the incisal visibility to improve esthetics.

It also reduced the load on the premaxilla under the maxillary complete denture as the mandibular implant-supported restoration may exert a greater force on the premaxilla than a mandibular denture and result in accelerated bone resorption.<sup>42</sup>

The mandibular occlusal table was made as narrow as was possible to minimize off-axial forces, to reduce the force required to penetrate the food bolus, and to facilitate daily home care of the prosthesis.<sup>42</sup>

The raised anterior plane and anterior open bite were brought to the patient's attention and discussed with her at the trial denture appointment. The patient did have difficulty in enunciating "f" and "v" sounds and lisping with "s" and "z" sounds owing to the anterior open bite but was not unduly concerned as she was very pleased with the anterior esthetics and the reduced incisal visibility.

An osteoplasty would have enabled us to insert wider implants but would have increased the crown height space and converted the FP-1 prosthesis to an FP-2 design. As we were planning on placing only 5 implants at the time, this might have magnified the force factors because of the increased vertical height of the prosthesis. However, inserting more than 5 implants at the time of treatment was not possible.

## CONCLUSION

The restoration of the mandibular arch up to the first molars with 5 one-piece implants and a split full-arch fixed restoration presents a viable and cost-effective treatment plan in patients with adequate bone volume and favorable ridge relationships. The early loading of the implants with a provisional restoration eliminates the need for second-stage surgery, reduces the period of edentulousness, and restores the patient's ability to eat, talk, and smile effectively. At the same time, these advantages must be weighed carefully against the chances of increased risk of failure, and further documentation with RCTs of early loading protocols is required.

## ABBREVIATIONS

OPG: orthopantograph

RCT: randomized controlled clinical trial

## REFERENCES

- Zarb G, Schmitt A. Edentulous predicament. 1. A prospective study of the effectiveness of implant supported fixed prostheses. *J Am Dent Assoc.* 1996;127:59–72.
- Misch CE. Rationale for dental implants. In: Misch CE, ed. *Dental Implant Prosthetics.* St Louis, Mo: Elsevier; 2005:1–17.
- Carlsson GE, Haraldson T. Functional response. In: Branemark PI, Zarb GA, Albrektsson T, eds. *Tissue Integrated Prostheses: Osseointegration in Clinical Dentistry.* Chicago, Ill: Quintessence; 1985: 155–164.
- Blomberg S. Psychological response. In: Branemark PI, Zarb GA, Albrektsson T, eds. *Tissue Integrated Prostheses: Osseointegration in Clinical Dentistry.* Chicago, Ill: Quintessence; 1985.
- Albrektsson T, Blomberg S, Branemark PI, et al. Edentulousness: oral handicap-patient reactions to treatment with jawbone-anchored prosthesis. *J Oral Rehabil.* 1987;14:503–511.
- Blomberg S, Lundquist S. Psychological reactions to edentulousness and treatment with jaw bone-anchored bridges. *J Prosthet Dent.* 1983;50:262–270.
- Misch CE. Mandibular full-arch implant fixed prosthetic options. In: Misch CE, ed. *Dental Implant Prosthetics.* St Louis, Mo: Elsevier Mosby; 2005:252–264.
- Walton JN, McEntee MI. Problems with prostheses on implants: a retrospective study. *J Prosthet Dent.* 1994;71:283–288.
- Misch CE. The completely edentulous mandible: treatment plans for fixed restorations. In: Misch CE, ed. *Contemporary Implant Dentistry.* 3rd ed. St Louis, Mo: Elsevier Mosby; 2008:314–326.
- Chee W, Jivraj S. Treatment planning of the edentulous mandible. *Br Dent J.* 2006;201:337–347.
- Walton JN, MacEntee MI. A prospective study on the maintenance of implant prostheses in private practice. *Int J Prosthodont.* 1997;10:453–458.
- Sadowsky SJ. The implant restoration of the edentulous patient. In: *Perspectives in Prosthodontics: 1970–2010.* Chicago, Ill: American College of Prosthodontists; 2010:7–14.
- Watson RM, Davis DM. Follow up and maintenance of

implant supported prostheses: a comparison of 20 complete mandibular overdentures and 20 complete mandibular fixed cantilever prostheses. *Br Dent J.* 1996;181:321–327.

14. Walton JN, MacEntee MI, Hanvelt R. A retrospective study on the maintenance and repair of implant-supported prostheses. *Int J Prosthodont.* 1993;6:451–455.

15. Goodacre CJ, Bernal G, Rungcharassaeng K, Kan JY. Clinical complications with implants and implant prostheses. *J Prosthet Dent.* 2003;90:121–132.

16. Trulsson U, Engstrand P, Berggren U, Nannmark U, Branemark PI. Edentulousness and oral rehabilitation: experiences from the patients' perspective. *Eur J Oral Sci.* 2002;110:417–424.

17. Feine JS, de Grandmont P, Boudrias P, et al. Within-subject comparisons of implant-supported mandibular prostheses: choice of prosthesis. *J Dent Res.* 1994;73:1105–1111.

18. Chee W, Jivraj S. Treatment planning of the edentulous mandible. *Br Dent J.* 2006;201:337–347.

19. Adell R, Lockholm U, Rockler B, et al. A 15 year study of osseointegrated implants in the treatment of the edentulous jaw. *Int J Oral Surg.* 1981;10:387–416.

20. Fishman BM. The influence of fixed splints on mandibular flexure. *J Prosthet Dent.* 1976;35:643–667.

21. Zarone F, Apicella A, Nicolais L, Aversa R, Sorrentino R. Mandibular flexure and stress build-up in mandibular full-arch fixed prostheses supported by osseointegrated implants. *Clin Oral Implants Res.* 2003;14:103–114.

22. Maló P, Rangert B, Nobre M. "All-on-four" immediate-function concept with Branemark system implants for completely edentulous mandibles: a retrospective clinical study. *Clin Implant Dent Related Res.* 2003;5(suppl 1):2–9.

23. Cochran DL, Morton D, Weber HP. Consensus statements and recommended clinical procedures regarding loading protocols for endosseous dental implants. *Int J Oral Maxillofac Implants.* 2007;19(suppl):109–113.

24. Misch CE, Wang HL. Implantology: immediate occlusal loading for fixed prostheses. <http://www.oralhealthjournal.com/issues/story.aspx?aid=1000129181&type=Print%20Archives11>. Accessed November 2, 2010.

25. Misch CE. Progressive bone loading. In: Misch CE, ed. *Dental Implant Prosthetics.* St Louis, Mo: Elsevier Mosby; 2005:511–530.

26. Sagara M, Akagawa Y, Nikai H, et al. The effects of early occlusal loading on one-stage titanium alloy implants in beagle dogs: a pilot study. *J Prosthet Dent.* 1993;69:281–288.

27. Piattelli A, Paolantonio M, Corigliano M, et al. Immediate loading of titanium plasma-sprayed screw-shaped implants in man: a clinical and histological report of two cases. *J Periodontol.* 1997; 68:591–597.

28. Ledermann PD, Schenk RK, Buser D. Long-lasting osseointegration of immediately loaded, bar-connected TPS screws after 12 years of function: a histologic case report of a 95-year-old patient. *Int J Periodontics Restorative Dent.* 1998;18:552–563.

29. Meyer U, Joos U, Mythili J, et al. Ultrastructural characterization of the implant/bone interface of immediately loaded dental implants. *Biomaterials.* 2004;25:1959–1967.

30. Testori T, Szmukler-Moncler S, Francetti L, et al. Immediate loading of Osseotite implants: a case report and histologic analysis after 4 months of occlusal loading. *Int J Periodontics Restorative Dent.* 2001;21:451–459.

31. Romanos GE, Testori T, Degidi M, et al. Histologic and histomorphometric findings from retrieved, immediately occlusally loaded implants in humans. *J Periodontol.* 2005;76:1823–1832.

32. Esposito M, Grusovin MG, Achille H, Coulthard P, Worthington HV. Interventions for replacing missing teeth: different times for loading dental implants. *Cochrane Database Syst Rev.* 2013;3: CD003878.



33. Gallucci GO, Morton D, Weber H-P. Loading protocols for dental implants in edentulous patients. *Int J Oral Maxillofacial Implants*. 2009;24(suppl):132–146.
34. Randow K, Ericsson I, Nilner K, Petersson A, Glantz PO. Immediate functional loading of Branemark dental implants: an 18-month clinical follow-up study. *Clin Oral Implants Res*. 1999;10:8–15.
35. Ericsson I, Randow K, Nilner K, Peterson A. Early functional loading of Branemark dental implants: 5-year clinical follow-up study. *Clin Implant Dent Related Res*. 2000;2:70–77.
36. Misch CE, Degidi M. Five-year prospective study of immediate/early loading of fixed prosthesis in completely edentulous jaws with a bone quality based implant system. *Clin Implant Dent Related Res*. 2003;5:17–28.
37. Norkin FJ, Ganeles J, Sekler J, Zfaz S. Immediate loading of endosseous dental implants: a review of the evidence. *Functional Esthetics Restor Dent*. 2008;2:38.
38. Szmukler-Moncler S, Piattelli A, Favero GA, et al. Considerations preliminary to the application of early and immediate loading protocols in dental implantology. *Clin Oral Implants Res*. 2000;11:12–25.
39. Misch CE. The completely edentulous mandible: treatment planning: force factors related to patient conditions. In: Misch CE, ed. *Contemporary Implant Dentistry*. 3rd ed. St Louis, Mo: Elsevier Mosby; 2008:105–129.
40. Carlsson GE. Bite force and masticatory efficiency. In: Kawamura Y, ed. *Physiology of Mastication*. Basel, Switzerland: Karger; 1974.
41. Froum JS, Cho S-C, Cho YS, Elian N, Tarnow D. Narrow-diameter implants: a restorative option for limited interdental space. *Int J Periodontics Restorative Dent*. 2007;27:449–455.
42. Misch CE. Occlusal considerations in implant supported prostheses. In: Misch CE, ed. *Dental Implant Prosthetics*. St Louis, Mo: Elsevier Mosby; 2005:472–510.
43. Misch CE. Maxillary denture opposing an implant prosthesis and modified occlusal concepts. In: Misch CE, ed. *Dental Implant Prosthetics*. St Louis, Mo: Elsevier Mosby; 2005:568–586.
44. Payne SH. A posterior tooth set up to meet individual requirements. *Dent Dig*. 1941;47:20–22.
45. Pound E, Murell GA. An introduction to denture simplification, phase II. *J Prosthet Dent*. 1973;29:598–607.