

# Gingival Conditioning in an Implant-Supported Prosthesis: A Clinical Report

Flávio Domingues das Neves, PhD<sup>1\*</sup>  
 Clébio Domingues Silveira-Júnior, DDS, MS<sup>2</sup>  
 Vitor Coró, DDS, MS<sup>1</sup>  
 João Paulo Silva-Neto, DDS, MSc<sup>1</sup>  
 Paulo César Simamoto-Júnior, DDS, MSc, PhD<sup>2</sup>  
 Célio Jesus do Prado, DDS, MSc, PhD<sup>1</sup>

The loss of gingival volume is a major challenge for dental surgeons with implant-supported fixed prosthesis manufactures, particularly from an aesthetics perspective in patients with a high smile line. Gingival tissue remodeling can help in papillae formation to avoid soft tissue surgery by reestablishing the appropriate shape and gingival contour of the tissues. This improves not only the aesthetics, but also the phonetics of the patient. This paper describes a clinical case of gingival conditioning obtained with interim implant-supported fixed partial dentures via incremental addition and adjustment of acrylic resin. The purpose of the gingival conditioning was to obtain improved aesthetics. Gingival conditioning by gradual pressure application is presented as an easy, non-traumatic technique that improves gingival aesthetics.

**Key Words:** *gingiva, fixed partial dentures, aesthetics*

## INTRODUCTION

**T**reatment with osseointegrated implants and fixed partial dentures has a high success rate with respect to implant loss and prosthesis functionality.<sup>1</sup> The biggest challenge currently facing dental surgeons is the creation of favorable esthetics. This problem is highly dependent upon the maintenance of bone to support soft tissue.<sup>2,3</sup> The resorption of the adjacent alveolar bone results in loss of gingival volume and interdental papillae.<sup>4-6</sup> Common in the anterior maxilla, the condition increases the difficulty associated with obtaining adequate gingival esthetics.<sup>6-9</sup> This is particularly true if the smile line of the patient is unfavorable.<sup>10</sup>

The management of soft tissue to improve esthetics sometimes requires corrective surgeries,

which are not possible in some cases. Rehabilitation using a fixed prosthesis over implants is complex because the residual ridge, pontics, and gingival papillae must be harmoniously integrated in the final result.<sup>2,3,6,11,12</sup> Given that the use of a provisory prosthesis can often enhance peri-implant gingival contour, surgery can be avoided.<sup>2,8,9,13,14</sup>

This case describes the use of a provisional prosthesis to enhance esthetics of a Kennedy Class IV patient with 3 implants. Selective pressure through the incremental addition of acrylic resin followed by acrylic adjustment was used to improve gingival esthetics.

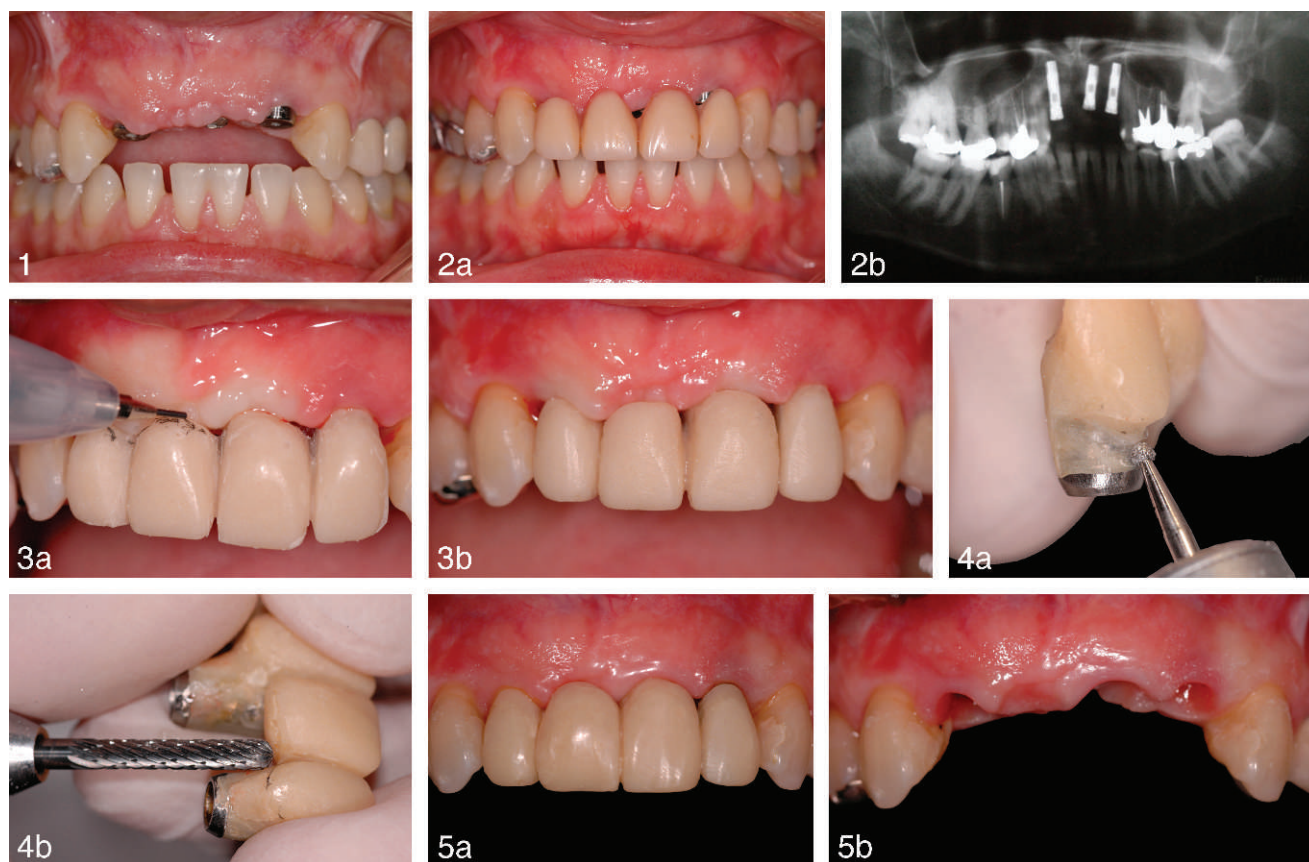
## CLINICAL REPORT

A female patient lacking teeth numbers 7, 8, 9, and 10 underwent surgery for implant exposure in the region of teeth numbers 7, 9, and 10 and healing abutment installation. The alveolar ridge presented irregular topography, compromising tooth and soft tissue esthetics (Figures 1 and 2).

Acrylic resin was utilized to perform gingival conditioning of the provisional prosthesis in order

<sup>1</sup> Department of Occlusion, Fixed Prosthesis, and Dental Materials, Federal University of Uberlândia, Uberlândia, Minas Gerais, Brazil.

<sup>2</sup> Federal University of Uberlândia, School of Health, Uberlândia.  
 \* Corresponding author, e-mail: neves@triang.com.br  
 DOI: 10.1563/AAID-JOI-D-10-00199



**FIGURES 1–5. FIGURE 1.** Initial clinical situation. **FIGURE 2.** (a) The exposure of the healing abutment over the implant in site number 10 and the presence of black triangle between teeth numbers 8 and 9. (b) Panoramic radiograph. **FIGURE 3.** (a) Ischemia induced by adding resin. (b) Color following adjustments. **FIGURE 4.** (a) A groove was created with a spherical drill (0.0394-inch diameter) on the vestibular facial surface. (b) Polishing of the groove. **FIGURE 5.** (a) The final provisional prosthesis was installed over the implants and the conditioning was finalized. (b) Final gingival tissue architecture.

to create an esthetically harmonious relationship between the gingival tissue and prosthesis. Figure 2 demonstrates an exposure of the healing abutment over the implant in site number 10 and the presence of a black triangle between teeth numbers 8 and 9.

A provisional prosthesis was created to conform to the initial emergence profile of the implants. Gingival tissue becomes ischemic in response to increased pressure applied by additional resin material (Figure 3a). A return to normal coloring within minutes indicates that the tissues adapt to the pressure application without causing damage. If normal coloring does not return, the provisional in that specific area is adjusted to prevent damage resulting from tissue ischemia.

To recreate papillae form, gingival conditioning was performed in small increments on the facial cervical region of the provisional pontic. The conditioning on each section (approximately

0.0394–0.5 in thickness<sup>3</sup>) was controlled by gradual addition of resin and removal when necessary. When screwing the prosthesis over the implants, the mucosa over the pontic should exhibit initial ischemia without pain. If pain was induced, the thickness of the added resin was reduced. After approximately 15 minutes, if the mucosa remained ischemic, the prosthesis was removed and the applied resin was adjusted (Figure 3b). This was done to reduce the risk of adjacent tissue failure. Grinding was followed by finishing and polishing, primarily in the areas of tissue contact. The resin thickness was manipulated so that, when in position, the prosthesis allowed the passage of dental floss under the pontic. This made proper oral hygiene possible.<sup>3</sup>

One goal of the provisional was to promote cervical-occlusal displacement of the gingival tissue over the implant in site number 7. A groove was created with a spherical drill (0.0394-inch diameter)

on the vestibular tooth face at the level of the marginal gingiva (Figure 4). This groove promoted migration and filling in the gingival tissue filling it. Gingival tissue encouraged gingival migration. Each time a groove was filled, the gingival tissues migrated incisally. This process was repeated until the tissue clearly migrated or stopped responding to the stimulus.

In the conditioned areas, acrylic resin was added and adjusted until more favorable esthetics were achieved (Figure 5). At this point, the provisional fixed partial denture followed similar biological principles as the definitive restoration, with similar convex pontics and an adequate emergence profile and papillae form.

### SUMMARY

Gingival conditioning by incremental addition and adjustment of acrylic resin was presented as an easy, nontraumatic technique that can improve soft tissue esthetics around implant-supported fixed partial dentures. Treatment success depends on the preexisting gingival volume, the response of the gingival tissue of each patient (which is unpredictable), and patient compliance during multiple conditioning sessions.

### REFERENCES

1. Salinas TJ, Eckert SE. In patients requiring single-tooth replacement, what are the outcomes of implant—as compared to

tooth-supported restorations? *J Oral Maxillofac Implants*. 2007; 22(suppl):71–95.

2. Touati B, Guez G, Saadoun A. Aesthetic soft tissue integration and optimized emergence profile: provisionalization and customized impression coping. *Pract Periodontics Aesthet Dent*. 1999;11:305–314.

3. Jacques LB, Coelho AB, Hollweg H, Conti PCR. Tissue sculpturing: an alternative method for improving esthetics of anterior fixed prosthodontics. *J Prosthet Dent*. 1999;81:630–633.

4. Lam RV. Contour changes of the alveolar process following extractions. *J Prosthet Dent*. 1960;10:25–32.

5. Saadoun AP, Touati B. Soft tissue recession around implants: is it still unavoidable?—Part I. *Pract Proced Aesthet Dent*. 2007;19:55–62.

6. Rompen E, Raepsaet N, Domken O, Touati B, Van Dooren E. Soft tissue stability at the facial aspect of gingivally converging abutments in the esthetic zone: a pilot clinical study. *J Prosthet Dent*. 2007;97(6 suppl):S119–S125. Erratum in: *J Prosthet Dent*. 2008;99:167.

7. Kois JC, Kan JY. Predictable peri-implant gingival aesthetics: surgical and prosthodontic rationales. *Pract Proced Aesthet Dent*. 2001;13:691–698.

8. Neale D, Chee WWL. Develop of implant soft tissue emergence profile: a technique. *J Prosthet Dent*. 1994;71:364–368.

9. Dylina TJ. Contour determination for ovate pontics. *J Prosthet Dent*. 1999;82:136–142.

10. Pasquinelli KL. Periodontal plastic surgery. *J Calif Dent Assoc*. 1999;27:597–610.

11. Al-Harbi SA, Edgin WA. Preservation of soft tissue contours with immediate screw-retained provisional implant crown. *J Prosthet Dent*. 2007;98:329–332.

12. Cavazos E Jr. Tissue response to fixed partial denture pontics. *J Prosthet Dent*. 1968;20:143–153.

13. Tarlow JL. Procedure for obtaining proper contour of an implant-supported crown: a clinical report. *J Prosthet Dent*. 2002;87: 416–418.

14. Tripodakis A, Constantinides A. Tissue response under hyperpressure from convex pontics. *Int J Periodontics Restorative Dent*. 1990;10:409–414.