

# Efficacy of Guided Bone Regeneration Using Composite Bone Graft and Resorbable Collagen Membrane in Seibert's Class I Ridge Defects: Radiological Evaluation

Saravanan Pushparajan, MDS\*  
Ramakrishnan Thiagarajan, MDS  
Ambalavanan Namasi, MDS  
Pamela Emmadi, MDS  
Harshini Saravanan, BDS

The purpose of the study was to evaluate radiologically the efficacy of guided bone regeneration using composite bone graft (autogenous bone graft and anorganic bovine bone graft [Bio-Oss]) along with resorbable collagen membrane (BioMend Extend) in the augmentation of Seibert's class I ridge defects in maxilla. Bone width was evaluated using computerized tomography at day 0 and at day 180 at 2 mm, 4 mm, and 6 mm from the crest. There was a statistically significant increase in bone width between day 0 and day 180 at 2 mm, 4 mm, and 6 mm from the crest. The results of the study demonstrated an increase in bone width of Seibert's class I ridge defects in the maxilla of the study patients.

**Key Words:** CT scan, Ebner grafter, guided bone regeneration

## INTRODUCTION

During the past decade, the use of osseointegrated implants has become an increasingly important treatment modality for the replacement of missing teeth in fully and partially edentulous patients.<sup>1</sup> However, in patients with advanced atrophy of the alveolar process, especially in the maxilla, implant treatment is sometimes difficult to perform. A sufficient volume of healthy jawbone should be present at potential implant recipient sites to expect a predictable long-term prognosis for such implants.

Resorption after tooth loss has been shown to follow a predictable pattern; the labial aspect of the alveolar crest is the principal site of resorption, which first reduces in width and later in height of

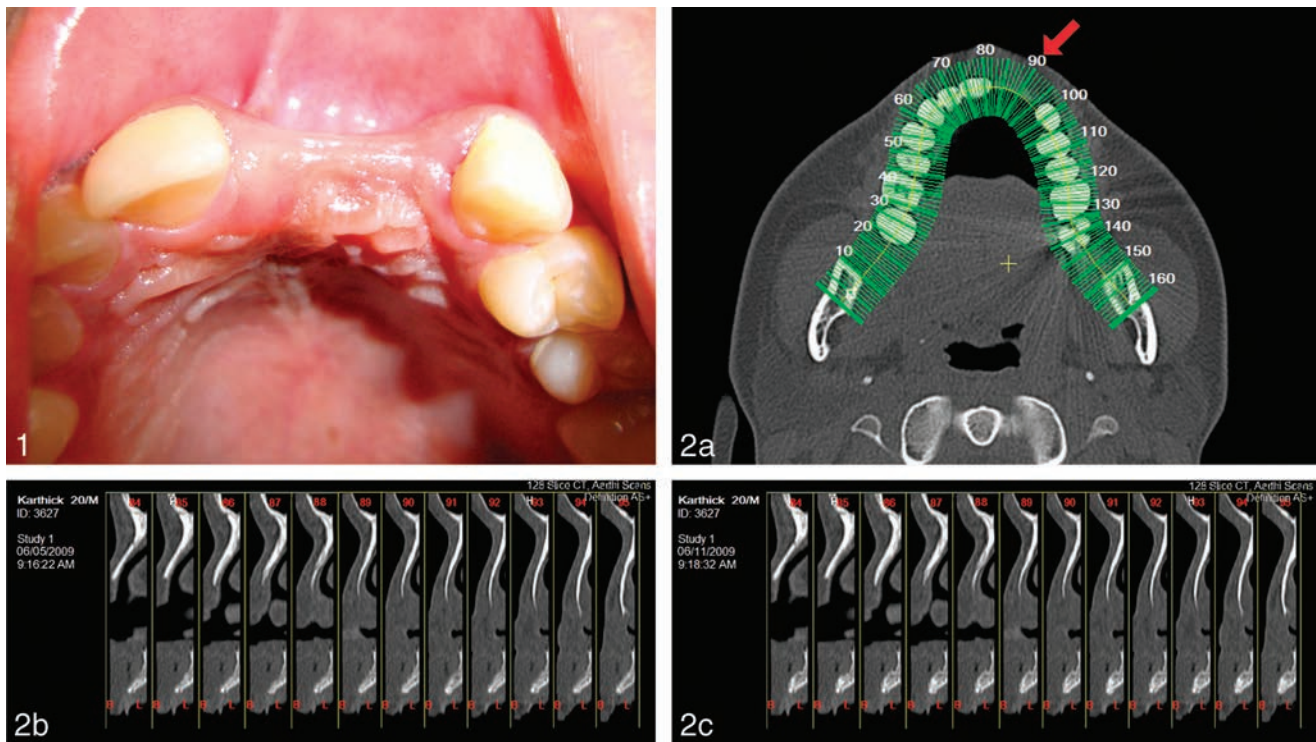
the alveolar bone.<sup>2</sup> Alveolar bone is resorbed after tooth extraction or avulsion, most rapidly during the initial years. Nontraumatic loss of anterior maxillary teeth is followed by a progressive loss of bone, mainly from the labial side. The magnitude of bone loss is estimated to be 40%–60% during the first 3 years following tooth loss and then decreases to a 0.25%–0.5% annual loss rate thereafter.<sup>3</sup> The cause of resorption of alveolar bone after tooth loss has been assumed to be disuse atrophy, decreased blood supply, localized inflammation, or nonfitting prosthesis pressure.<sup>4</sup>

The use of membranes is a controversial issue in implantology, and their use is certainly very technique sensitive.<sup>5</sup> Nevertheless, good results with augmentation procedures using membranes have been presented.<sup>6</sup>

BioMend Extend absorbable collagen membrane is a compressed, nonfriable matrix fabricated from collagen-derived bovine deep flexor tendons.<sup>7</sup> Bovine tendon is known to be one of the purest sources of type I collagen that can be readily obtained and

Department of Oral Pathology & Oral Medicine & Periodontology, Faculty of Dentistry, University of Malaya, Kuala Lumpur, Malaysia.

\*Corresponding author, e-mail: sarav\_dentist@yahoo.com  
DOI: 10.1563/AAID-JOI-D-10-00211



**FIGURES 1 AND 2.** **FIGURE 1.** Preoperative, occlusal view. **FIGURE 2.** (a) Computerized tomography scan at 1-mm slices, specification of edentulous site (84–95 mm). (b) Reformed sectional view, preoperative. (c) Reformed sectional view, postoperative.

processed in commercial amounts.<sup>8</sup> Being semi-occlusive, it allows essential nutrients to pass through the membrane. It incorporates into the surrounding tissue and is generally absorbed within 18 weeks.

One of the main principles of ridge augmentation procedures is space maintenance. The downsides of placing a membrane around an area without some sort of rigid support system is that it may fail to maintain its desired shape due to the forces put upon it.<sup>9</sup> This results in less than desired bone growth. To combat this problem, various titanium frameworks or meshworks have been added to, or used underneath, the membranes, but new bone formation occurs when bone grafts are combined with barrier membranes.<sup>10</sup>

Autogenous bone grafts had been used successfully to graft alveolar defects, and they became the bone graft material of choice for much of the early work done on guided bone regeneration. However, autogenous grafting results in donor site morbidity and limited supply.<sup>11,12</sup>

Bio-Oss (Geistlich Pharma AG), a bovine-derived bone xenograft, has been introduced as a bone replacement graft.<sup>13</sup> It is either cortical or cancellous

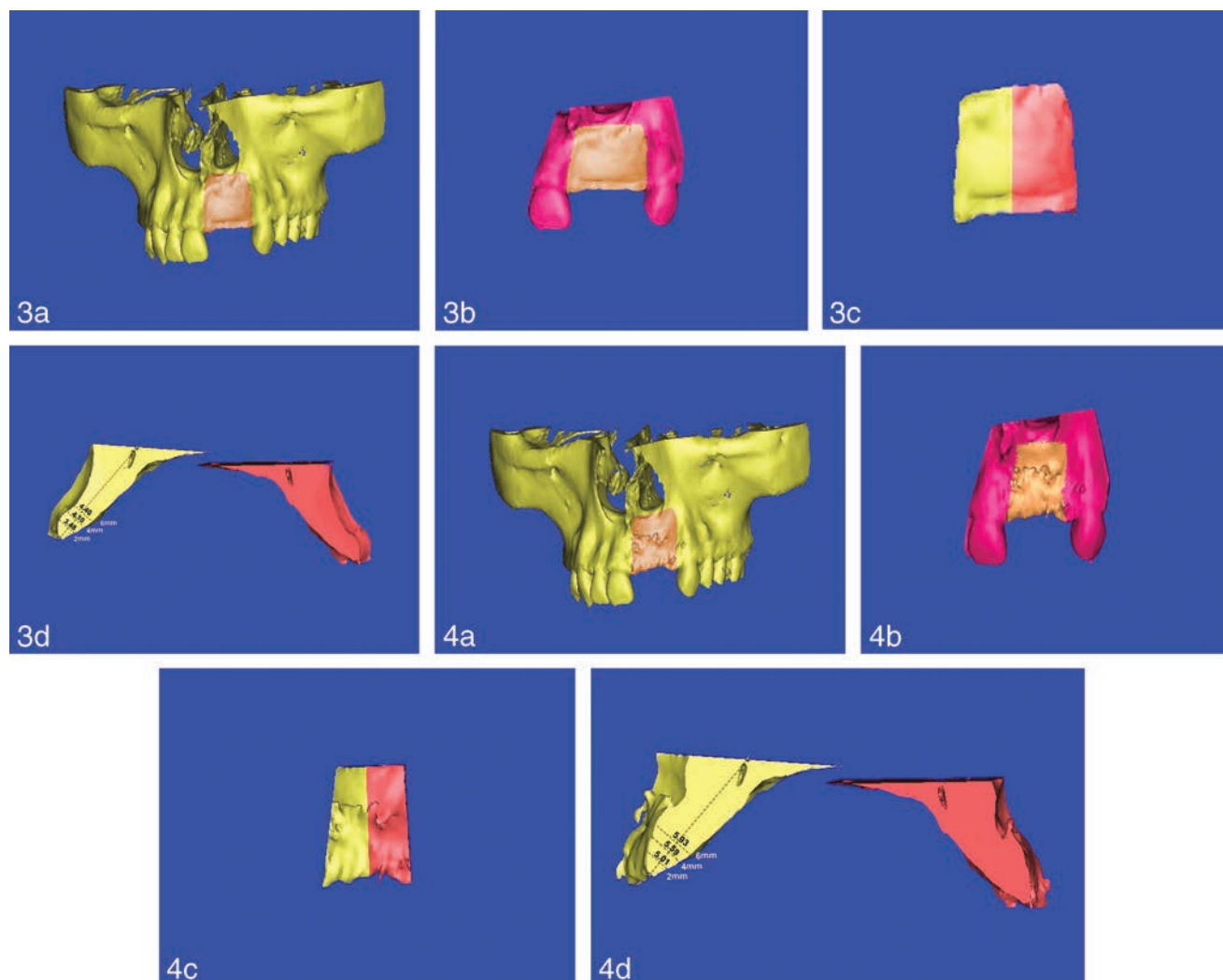
bovine bone produced by the chemical extraction of all organic material. It is similar to human bone mineral<sup>14</sup> in inner surface area, porosity, crystalline size, and calcium-to-phosphorous ratio. In periodontal regeneration, Bio-Oss has been shown to improve attachment levels and reduce pocket depths when used alone or in combination with absorbable membranes.<sup>15,16</sup>

However, this material, when used in combination with an autogenous graft, creates a composite graft, which results in an increased success rate.

### STUDY DESIGN

Ten patients were selected from the outpatient Department of Periodontology, Meenakshi Ammal Dental College and Hospital, Chennai, India, with Seibert's class I ridge defects in maxilla for ridge augmentation by guided bone regeneration. This study was done after obtaining approval from the Meenakshi University Ethical Committee.

The inclusion criteria for patients was age 20–50 years, at least a single missing tooth with Seibert's class I ridge defect (2–5 mm in the buccolingual



**FIGURES 3 AND 4. FIGURE 3.** (a) Three-dimensional reconstruction using mimic software, preoperative. (b) Reconstructed edentulous site. (c) Sectioning the bone at the center. (d) Calculated bone width at 2 mm, 4 mm, and 6 mm. **FIGURE 4.** (a) Three-dimensional reconstruction using mimic software, postoperative. (b) Reconstructed edentulous site, postoperative. (c) Sectioning the bone at center. (d) Calculated bone width at 2 mm, 4 mm, and 6 mm.

dimension in the maxilla as measured by bone caliper; Figure 1), and evidence of the patient's ability to maintain good plaque control. The following group of patients was excluded from the study: those with uncontrolled diabetes, immunodeficiency or systemic diseases that affect the alveolar bone, smokers, severe periodontal diseases, unwillingness to undergo periodontal treatment, and allergy to any material or medication used in the study. Written consent was obtained from each patient prior to his or her inclusion in this study.

The horizontal component (buccolingual dimension) of the bone defect at 2 mm, 4 mm, and 6 mm from the crest was recorded at day 0 and at

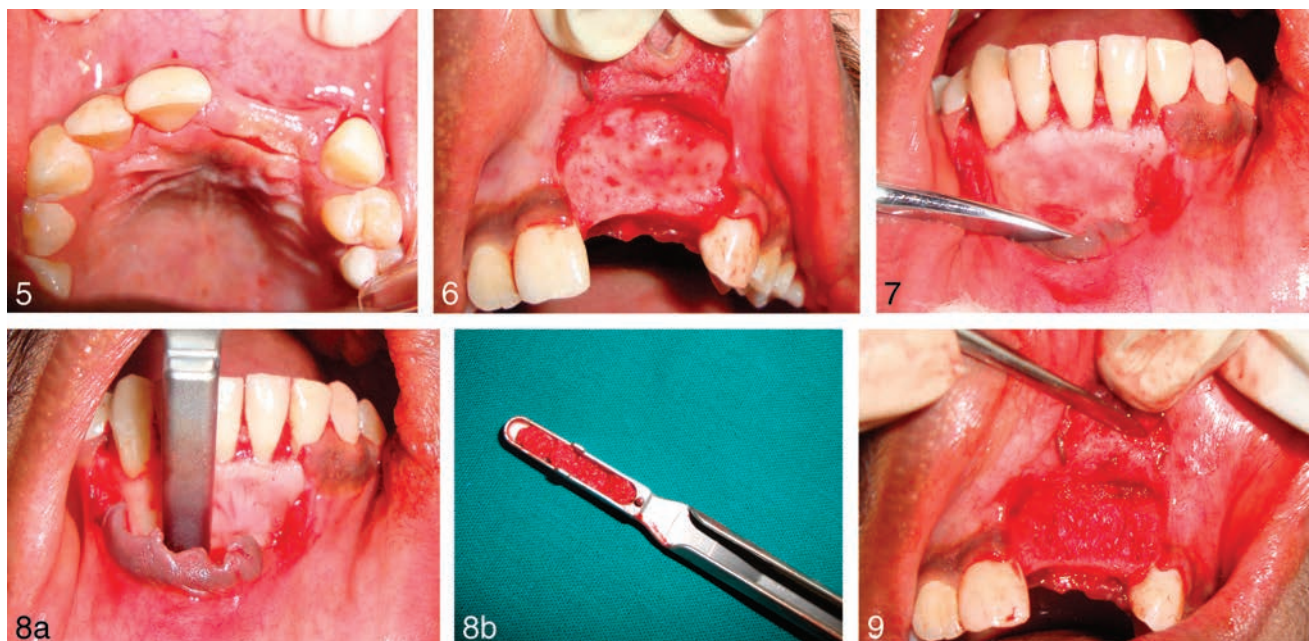
day 180 postoperatively with computerized tomography (CT).

The buccolingual ridge width was measured by CT (Figure 2a and b). The images were obtained from 1 mm CT axial, sagittal, and coronal sections. The CT data were imported into the MIMICS software (Figures 3 and 4).

MIMICS is a MEDCAD software (MATERIALISE, Belgium). Using this software, the CT data were reconstructed into a virtual object by the thresholding technique. The site of interest (edentulous site) was then cut, and the section was measured with a 3-dimensional measuring tool.

The cemento-enamel junction (CEJ) of the adjacent teeth on either sides was kept as the





**FIGURES 5–9.** **FIGURE 5.** Paracrestal incisions given. **FIGURE 6.** Flap was elevated, and bone was decorticated. **FIGURE 7.** Donor site flap elevated. **FIGURE 8.** (a) Procurement of particulate autogenous bone graft. (b) Ebner grafter with particulate autogenous bone graft. **FIGURE 9.** Placement of particulate autogenous bone graft.

reference point, an imaginary line was drawn to connect the CEJ, and the bone width was calculated at exactly 2 mm, 4 mm, and 6 mm from crest of the ridge center (Figures 3a–c and 4a–c).

#### SURGICAL PROCEDURE

##### *Preparation of the recipient bed*

Patients were anesthetized with 2% lidocaine with 1:200 000 adrenaline. Horizontal incisions were made slightly palatal to the midcrestal region with care taken to preserve keratinized tissue on both sides of the incision (Figure 5). Vertical incisions were made on the buccal surface from the mesial and distal extents of the horizontal incision extending to the mucogingival junction. A full-thickness mucoperiosteal flap was reflected on the buccal side, and a pouch was created on the palatal side to insert the barrier membrane (Figure 6).

A measurement of the approximate length and width of the membrane required was obtained with the use of a periodontal probe and sterile tin foil cut to the size of the defect. Intramarrow cortical perforations were made at the recipient site with a round bur at a slow speed with copious saline irrigation (Figure 6).

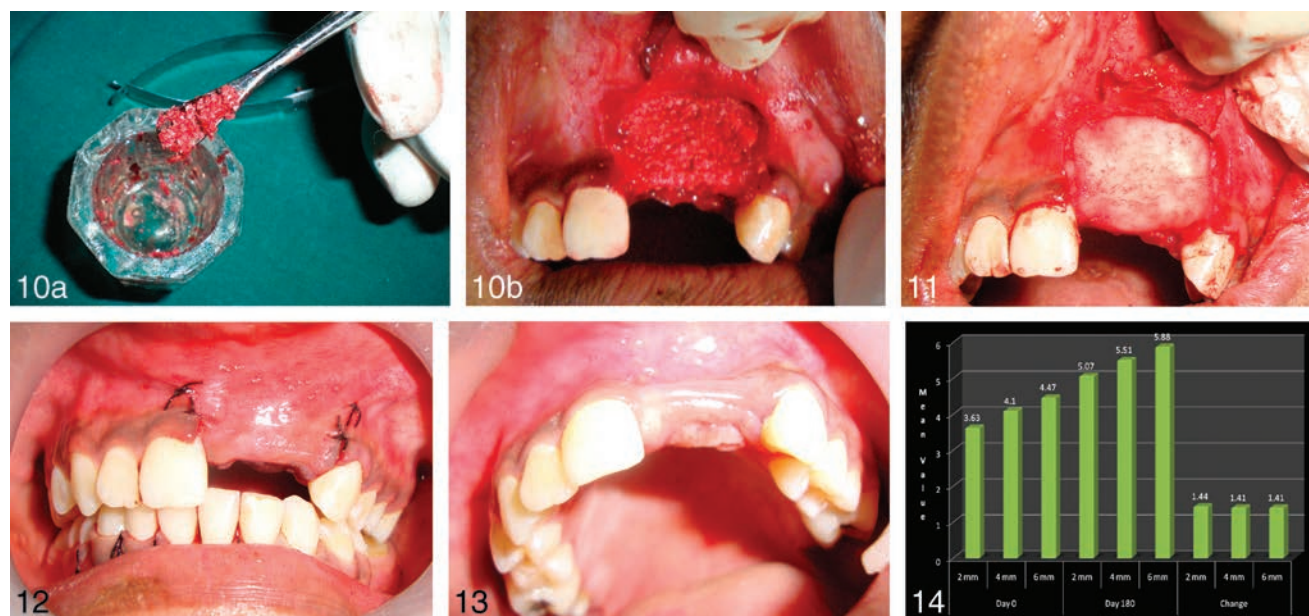
##### *Preparation of donor site*

Crevicular incision was given in relation to mandibular anteriors, and then a vertical releasing incision was given on the buccal aspect from the mesial and distal extents of the horizontal incision extending to the mucogingival junction. A full-thickness mucoperiosteal flap was reflected (Figure 7).

The Ebner 502 expanded bone grafter was used for bone removal and autogenous grafting. The blade was used to shave bone from the cortical surfaces of the symphysis menti, producing short convoluted ribbons (Figure 8a). Then, the donor site was sutured. The particulate autogenous graft material, an osseous coagulum (Figure 8b), was then delivered with the handle directly in the prepared recipient bed covering the decortication site (Figure 9). A layer of Bio-Oss cancellous granules (0.25–1.0 mm  $\mu$ m) was then mixed with particulate graft and placed in the recipient site (Figure 10a and b).

The rehydrated BioMend membrane was placed in direct contact with the bone graft and extended at least 3 mm beyond the graft border in all directions (Figure 11). The flap was coronally repositioned for complete wound coverage without tension.

Primary closure was then obtained using a nonresorbable monofilament (Vicril, Ethicon, 4.0)



**FIGURES 10–14.** **FIGURE 10.** (a,b) Composite graft (particulate autogenous graft + Bio-Oss). **FIGURE 11.** Resorbable collagen membrane placed (BioMend Extend). **FIGURE 12.** Recipient site sutured. **FIGURE 13.** Postoperative (occlusal view). **FIGURE 14.** Comparison of mean values among various dimensions at different time points.

suture (Figure 12). Periodontal dressing was done with Coe-Pack. All procedures were documented with clinical photographs.

Patients were given amoxicillin 500 mg, 1 capsule 3 times a day for 5 days; ibuprofen 400 mg, 1 tablet 3 times a day for 3 days; and chlorhexidine 0.12% twice daily rinse for 3 weeks. Written hand-outs of postoperative instructions to be followed by the patient were given. All patients were seen at 2 weeks postoperatively, and oral hygiene reinforcement was done. Sutures were removed 2 weeks postoperatively, and patients were followed up 6 months postoperatively (Figure 13).

### Statistical analysis

Means and standard deviations for both groups at preoperation, day 0, and day 180 were estimated. Since the measurements (responses) did not show normal distribution, nonparametric procedures were followed for analysis. Mean values were compared by using a Wilcoxon signed rank test after adjusting the *P* values for multiple comparison by using the Bonferroni correction method. The data were finalized using the Statistical Package for the Social Sciences (SPSS) software. In the present study, *P* < .05 was considered as the level of significance.

### RESULTS

The mean width at 2 mm from the crest on day 0 was found to be  $3.63 \pm 0.29$  mm; on day 180, the mean width was found to be  $5.07 \pm 0.25$  mm. There was a mean increase of  $1.44 \pm 0.09$  mm, which was statistically significant (*P* = .005).

The mean width at 4 mm from the crest on day 0 was found to be  $4.10 \pm 0.18$ ; on day 180, the mean width was found to be  $5.51 \pm 0.21$ . There was a mean increase of  $1.41 \pm 0.08$  mm, which was statistically significant (*P* = .005).

The mean width at 6 mm from the crest on day 0 was found to be  $4.47 \pm 0.25$ ; on day 180, the mean width was found to be  $5.88 \pm 0.27$ . There was a mean increase of  $1.41 \pm 0.08$ , which was statistically significant (*P* = .005).

On day 0, the mean width at 6 mm from the ridge crest ( $4.47 \pm 0.25$ ) was significantly higher than the mean width at 2 mm from the ridge crest ( $3.63 \pm 0.29$ ) and the mean width at 4 mm from the ridge crest ( $4.10 \pm 0.18$ ; *P* < .05). Also, the mean width at 4 mm from the ridge crest ( $4.10 \pm 0.18$ ) was significantly higher than the mean width at 2 mm from the ridge crest ( $3.63 \pm 0.29$ ; *P* < .05).

On day 180, the mean width at 6 mm from the ridge crest ( $5.88 \pm 0.27$ ) was significantly higher than the mean width at 2 mm from the ridge crest ( $5.07 \pm 0.25$ ) and the mean width at 4 mm from the

TABLE

Comparison of mean values among various dimensions at different time points

	Dimension	Mean $\pm$ SD	Overall <i>P</i> Value*	Significant Subgroups†
Day 0	2 mm	3.63 $\pm$ 0.29	<.0001 (Sig.)	6 mm vs 2 mm, 4 mm, 4 mm vs 2 mm
	4 mm	4.10 $\pm$ 0.18		
	6 mm	4.47 $\pm$ 0.25		
Day 180	2 mm	5.07 $\pm$ 0.25	<.0001 (Sig.)	6 mm vs 2 mm, 4 mm, 4 mm vs 2 mm
	4 mm	5.51 $\pm$ 0.21		
	6 mm	5.88 $\pm$ 0.27		
Change (gain)	2 mm	1.44 $\pm$ 0.09	0.704 (NS)	NIL
	4 mm	1.41 $\pm$ 0.08		
	6 mm	1.41 $\pm$ 0.08		

\*Friedman test was used to calculate the *P* value.

†Wilcoxon signed ranks test followed by Bonferroni correction procedure was employed to identify the significant groups at the 5% level.

ridge crest (5.51  $\pm$  0.21; *P* < .05). Also, the mean width at 4 mm from the ridge crest (5.51  $\pm$  0.21) was significantly higher than the mean width at 2 mm from the ridge crest (5.07  $\pm$  0.25; *P* < .05). On comparing the mean gain after 180 days among 3 dimensions, there was no significant difference (*P* = .704; the Table; Figure 14).

## DISCUSSION

Implants should be placed with ideal location and angulation.<sup>16</sup> Several factors need to be considered during treatment planning for optimal function and esthetics of the implant-supported prosthesis. A major limitation for successful implant placement remains the inadequate alveolar ridge width. For most standard implants, a minimum of 5 mm in ridge width is necessary for favorable treatment outcomes.<sup>17</sup> Several authors have suggested that wherever dental implants are placed, a minimum thickness of 1 to 1.5 mm of bone should remain on both buccal and lingual/palatal aspects of the implants to ensure a successful outcome.<sup>18</sup>

Hence, various treatment modalities have been established to augment bone in the area of implant placement.<sup>19</sup> These include block grafts, distraction osteogenesis, and guided bone regeneration.<sup>20</sup>

Recent techniques in augmentation focus on the use of an array of regenerative materials. The combination of grafts with membranes have previously been successfully used in ridge augmentation by various authors.<sup>21,22</sup> This study focuses on the use of the composite grafting technique along with membranes, and each component of the regenerative mix counteracts the limitations of the

other, thereby providing an ideal framework for bone formation.

Patients with Seibert's Class I ridge defects and those who demonstrated adequate plaque control were chosen for this study.<sup>23</sup> Seibert's Class II and III defects were not considered, as they requires the vertical component to be augmented. Vertical ridge augmentation using guided bone regeneration is frequently compromised by a collapse of the barrier membrane, owing to the pressure of the overlying soft tissues.<sup>24</sup> The surgical protocol followed in this study was in agreement with the previous studies done on deficient ridges.<sup>19</sup>

In this study, particulate autogenous graft was procured from mandibular symphysis (donor site) because it has an excellent risk-benefit ratio.<sup>25</sup> Particulate autogenous graft was procured with an Ebner grafter, which planed ribbon-like shavings from the cortical surface. As the bone was harvested, blood from the cut bone surface was also passively collected and mixed with bone to form a moldable composite matrix. The graft volume subtended by the 3-dimensional ribbon-like elements is greatly expanded by this process in comparison to the bone volume at the donor site.<sup>21</sup> This composite matrix of ribbon-like shavings with the patient's blood occupying the interconnected porosity has several potential advantages to promote a rapid healing response<sup>26</sup> and revascularization process.

Only a thin layer of bone was planed from the surface, and the defect and subsequent morbidity at the donor site was minimized.<sup>21</sup> Successful use of chin grafts has been reported in the literature as the graft of choice.<sup>27</sup> Autogenous bone was placed as



the first layer at the recipient site over decortifications since it provides viable osteogenic cells and also enhances migration of cells from host to site.<sup>28</sup> Bio-Oss was also used because it has a good handling characteristic. The cancellous granules assumed a pastelike consistency when mixed with patient's blood, so it was easily placed and retained over the ridge. The size of the Bio-Oss inner structure is similar to that of natural cancellous bone, and it seems to undergo physiologic remodeling into host bone.<sup>29</sup>

The composite graft was prepared by mixing particulate autogenous graft with Bio-Oss to expand the volume of graft material and to further improve the handling characteristics. It also appears when a composite bone graft is used for augmentation for dental implants; with at least 50% autogenous bone in a ribbon geometry, similar implant success rates can be achieved as with 100% autogenous bone graft. It also appears that a composite bone graft consisting of 50% autogenous bone can provide excellent success rates for implant.<sup>21</sup>

The advent of CT in the assessment of periodontal regeneration has taken various treatment outcomes to another level, allowing the clinician to visualize and understand the complexities of the limited working area provided by the periodontium. Computerized tomography was employed in this study and carried out on day 0 and 180 after guided bone regeneration to provide accurate and reliable measurements of bone gain at various levels of crest height.<sup>23</sup>

The preoperative and postoperative measurements of the ridge at 6 mm and 4 mm from the crest clearly showed a greater dimension of bone when compared with 2 mm from the crest. Studies have established that the amount of new bone regenerated is directly proportional to the residual periodontium.

The final mean bone width obtained in our study was well within the limits of acceptable dimensions for successful implant placement, further demonstrating the efficacy of guided bone regeneration using particulate autogenous graft plus Bio-Oss with BioMend Extend.

### CONCLUSION

The results of the study demonstrated an increase in bone width, proving the efficacy of guided bone

regeneration using composite bone graft (autogenous bone graft and anorganic bovine bone graft [Bio-Oss]) and resorbable collagen membrane (Bio-Mend Extend) in the augmentation of Seibert's class I ridge defects in maxilla. There were, however, some limitations associated with the present study. The small sample size used in the study could have resulted in individual variations unduly influencing overall statistical results. Further studies designed on a long-term basis with a larger sample size would serve to validate the data collected.

### ABBREVIATIONS

CEJ: cemento-enamel junction  
CT: computerized tomography

### ACKNOWLEDGMENTS

I acknowledge Dr P. Pushparajan, Dean, Penang International Dental College, Malaysia, and Dr Vikraman, Professor, Department of Oral Surgery, Ragas Dental College, Chennai, India.

### REFERENCES

1. Schenk R, Buser D, Hardwick R, Dahlin C. Healing pattern of bone regeneration in membrane-protected defects: a histological study in canine mandible. *J Oral Maxillofac Implants*. 1994;9:13–29.
2. Atwood DA. Reduction of residual ridges: a major oral disease entity. *J Prosthet Dent*. 1971;26:266–267.
3. Ashman A. Ridge preservation techniques using Bioplant HTR and Biofoil: interview. *Dent Implantol Update*. 2001;12:49–53.
4. Ostler MS, Kokich VG. Alveolar ridge changes in patients congenitally missing mandibular second premolars. *J Prosthet Dent*. 1994;71:144–149.
5. Chiapasco M, Zaniboni M, Boisco M. Augmentation procedures for the rehabilitation of deficient edentulous ridges with oral implants. *Clin Oral Implants Res*. 2006;17(suppl 2):136–159.
6. Lekovic C. Preservation of alveolar bone in extraction sockets using bioabsorbable membranes. *J Periodontol*. 1998;69:1044–1049.
7. Oh TJ, Meraw SJ, Lee EJ, Giannobile WV, Wang HL. Comparative analysis of collagen membranes for the treatment of implant dehiscence defects. *Clin Oral Implants Res*. 2003;14:80–90.
8. O'Grady JE. BioMend Extend absorbable collagen membrane summary of safety and effectiveness. [http://www.accessdata.fda.gov/cdrh\\_docs/pdf/k992216.pdf](http://www.accessdata.fda.gov/cdrh_docs/pdf/k992216.pdf). Accessed November 21, 2011.
9. Bradley S, McAllister KH. Bone augmentation techniques: AAP-commissioned review. *J Periodontol*. 2007;78:377–396.
10. Banwart JC, Asher MA, Hassanein. Iliac crest bone graft harvest donor site morbidity: a statistical evaluation. *Spine*. 1995;20:1055–1060.
11. Baghban AA, Dehghani A, Ghanavati F, Zayeri F, Ghanavati F. Comparing alveolar bone regeneration using Bio-Oss and

autogenous bone grafts in humans: a systematic review and meta-analysis. *Int Endod J*. 2009;4:125–130.

12. Mellonig JT. Human histologic evaluation of a bovine-derived bone xenograft in the treatment of periodontal osseous defects. *Int J Periodontics Restorative Dent*. 2000;20:19–29.

13. Palmieri A, Pezzetti F, Brunelli G, et al. Anorganic bovine bone (Bio-Oss) regulates mRNA of osteoblast-like cells. *Int J Periodontics Restorative Dent*. 2010;30:83–87.

14. Camelo M, Nevins ML, Lynch SE, Schenk RK, Simion M, Nevins M. Periodontal regeneration with an autogenous bone—Bio-Oss composite graft and a Bio-Gide membrane. *Int J Periodontics Restorative Dent*. 2001;21:109–119.

15. Nevins ML, Camelo M, Lynch SE, Schenk RK, Nevins M. Evaluation of periodontal regeneration following grafting intrabony defects with BioOss collagen: a human histologic report. *Int J Periodontics Restorative Dent*. 2003;23:9–17.

16. Kopp KC, Koslow AH. Predictable implant placement with a diagnostic surgical template and advanced radiographic imaging. *J Prosthet Dent*. 2002;88:640–643.

17. Spiekermann H. *Implantology*. City, ST: Thieme Medical Publishers, Inc.; 1995.

18. Calvo Guirado JL, Pardo Zamora G, Saez Yuguero MR. Ridge splitting technique in atrophic anterior maxilla with immediate implants, bone regeneration and immediate temporisation: a case report. *J Ir Dent Assoc*. 2007;53:187–190.

19. Wang HL, Al-Shammari K. HVC ridge deficiency classification: a therapeutically oriented classification. *Int J Periodontics Restorative Dent*. 2002;22:335–343.

20. Buser D, Dula K, Belser U. Localized ridge augmentation using guided bone regeneration. In: Buser D, Dahlin C, Schenk RK, eds. *Guided Bone Regeneration in Implant Dentistry*. Chicago, Ill: Quintessence; 1994:189–234.

21. Peleg M, Garg AK, Misch C. Sinus and ridge augmentations using a surface-derived autogenous bone graft. *J Oral Maxillofac Surg*. 2004;62:1535–1544.

22. Proussaefs P, Lozada J. The use of resorbable collagen membrane in conjunction with autogenous bone graft and inorganic bovine mineral for buccal/labial alveolar ridge augmentation. *J Prosthet Dent*. 2003;90:530–538.

23. Pieri F, Corinaldesi G, Aldini NN, Giardino R, Marchetti C. Alveolar ridge augmentation with titanium mesh and a combination of autogenous bone and anorganic bovine bone: a 2 year study. *J Periodontol*. 2008;13:2093–2103.

24. Schliephake H. Guided bone regeneration around endosseous implants using a resorbable membrane vs a e-PTFE membrane. *Clin Oral Implant Res*. 2000;11:230–241.

25. Triplett RG, Sihow SR. Osseous regeneration with bone harvesting from the anterior mandible. In: Nevirs M, Mellonig JT, eds. *Implant Therapy*. Chicago, Ill: Quintessence; 1998:209–217.

26. Misch CM. Comparison of intraoral donor sites for ridge augmentation prior to implant placement. *Int J Periodontics Restorative Dent*. 2002;12:767–781.

27. Jensen J. Autogenous mandibular bone grafts and osseointegrated implants for reconstruction of severely atrophied maxilla: a preliminary report. *J Oral Maxillofac Surg*. 1991;48:1277–1287.

28. Wang HL, Misch C, Neiva RF. “Sandwich” bone augmentation technique: rationale and report of pilot cases. *Int J Periodontics Restorative Dent*. 2004;24:232–245.

29. Maiorana C, Beretta M, Salina S, Santoro F. Reduction of autogenous bone graft resorption by means of Bio-Oss coverage: a prospective study. *Int J Periodontics Restorative Dent*. 2005;25:19–25.