

Types of Implant Surgical Guides in Dentistry: A Review

Kathleen Manuela D'Souza, BDS*
Meena Ajay Aras, MDS

Various techniques have been proposed for the fabrication of surgical guide templates in implant dentistry. The objective of this paper is to review the associated literature and recent advancements in this field, based on design concept. An electronic and hand search of the literature revealed 3 categories, namely, nonlimiting, partially limiting, and completely limiting design. Most clinicians still adopt the partially limiting design due to its cost-effectiveness and credibility. Moreover, clinicians use cross-sectional imaging during the preimplant assessment of surgical sites.

Key Words: *implant guidance, implant placement, surgical guide, surgical template, implant dentistry*

INTRODUCTION

Recent studies on the clinical success of dental implants have indicated a high implant survival rate.¹ Nevertheless, the inadvertent association of most surgical and prosthetic complications with improper diagnosis and implant placement has also been documented.² These factors play a crucial role in the long-term predictability and success of implant prosthetics. Surgical guide templates not only assist in diagnosis and treatment planning but also facilitate proper positioning and angulation of the implants in the bone.³ Moreover, restoration-driven implant placement accomplished with a surgical guide template can decrease clinical and laboratory complications.⁴ Hence, increasing demand for dental implants has resulted in the development of newer and advanced techniques for the fabrication of these templates.

DISCUSSION

Surgical guide template fabrication involves a diagnostic tooth arrangement through one of the following ways: (1) a diagnostic waxing, (2) a trial denture teeth arrangement, or (3) the duplication of a preexisting dentition/restoration.⁵ The fabrication of the surgical guide templates is then based on one of the following design concepts⁶:

- (1) Nonlimiting design
- (2) Partially limiting design
- (3) Completely limiting design

These design concepts are classified based on the amount of surgical restriction offered by the surgical guide templates.

Nonlimiting Design

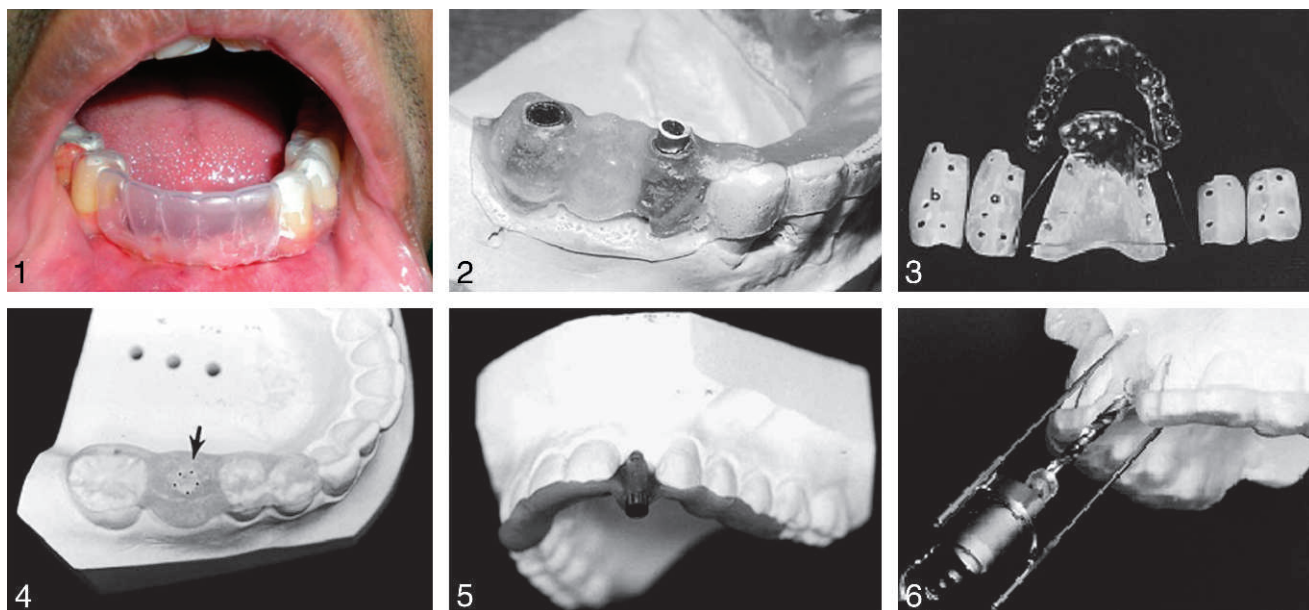
Nonlimiting designs only provide an indication to the surgeon as to where the proposed prosthesis is in relation to the selected implant site.⁶ This design indicates the ideal location of the implants without any emphasis on the angulation of the drill, thus allowing too much flexibility in the final positioning of the implant.

Blustein et al⁷ and Engelman et al⁸ described a technique in which a guide pin hole was drilled through a clear vacuum-formed matrix (Figure 1). This hole indicated the optimal position of the dental implant. However, the angulation was determined by the use of adjacent and opposing teeth. Almog et al⁹ described the circumference lead strip guide in which a lead strip was attached to the external surfaces of the diagnostic waxing. This was used to outline the tooth position over the implant site.

It has been observed that the use of these guides may result in unacceptable placement of the access hole and/or unacceptable implant angulation. Hence, these templates can serve as imaging indicators during the surgical phase of implant placement.

Department of Prosthodontics, Goa Dental College and Hospital, Bambolim, Goa, India.

* Corresponding author, e-mail: kath_dsouza@yahoo.co.in
DOI: 10.1563/AAID-JOI-D-11-00018



FIGURES 1–6. **FIGURE 1.** Vacuum-formed template. **FIGURE 2.** Brass tube incorporated into the surgical guide. Reprinted from *J Prosthet Dent* 2000;83:248–251, with permission from the corresponding author. **FIGURE 3.** Bilaminar dual-purpose surgical guide. Reprinted from *J Prosthet Dent* 2000;84:55–58, with permission from Elsevier. **FIGURE 4.** Gutta-percha guide. Reprinted from *J Prosthet Dent* 2001;85:504–508, with permission from Elsevier. **FIGURE 5.** Metal sleeve guide. Reprinted from *J Prosthet Dent* 2001;85:504–508, with permission from Elsevier. **FIGURE 6.** Surgical guide attached to the head of the contra-angle hand piece. Reprinted from *J Prosthet Dent* 2002;88:548–552, with permission from the corresponding author.

PARTIALLY LIMITING DESIGN

In such designs, the first drill used for the osteotomy is directed using the surgical guide, and the remainder of the osteotomy and implant placement is then finished freehand by the surgeon.⁶ Techniques based on this design concept involve fabrication of a radiographic template, which is then converted into a surgical guide template following radiographic evaluation. Various authors have proposed different techniques involving modifications in the following stages of fabrication, namely, material used for the fabrication of the surgical template, radiographic marker used, type of imaging system used, and the conversion process involved in converting the radiographic template into a surgical template. These various techniques are discussed in the Table. Nonetheless, all of the aforementioned techniques failed to completely restrict the angulation of the surgical drills.

COMPLETELY LIMITING DESIGN

Completely limiting design restricts all of the instruments used for the osteotomy in a buccolin-

gual and mesiodistal plane. Moreover, the addition of drill stops limits the depth of the preparation, and thus, the positioning of the prosthetic table of the implant. As the surgical guides become more restrictive, less of the decision-making and subsequent surgical execution is done intraoperatively. This includes 2 popular designs: cast-based guided surgical guide and computer-assisted design and manufacturing (CAD/CAM) based surgical guide.

Cast-based Guided Surgical Guide

The surgical guide is a combination of an analog technique done along with bone sounding and the use of periapical radiographs in a conventional flapless guided implant surgery.⁶ The periapical radiograph is modified using digital software to help in transposition of root structure onto the cast. The cast is then sectioned at the proposed implant site, and bone-sounding measurements are transferred to help in orientation of the drill bit to perform a cast osteotomy. A laboratory analog is placed in the site, and a guide sleeve consistent with the implant width is modified using wires that are used to create a framework around the teeth. Vinyl polysiloxane occlusal registration material is used to form the superstructure (Figures 13 and 14).

TABLE
Partially limiting design

Author (y)	Material Used for Fabrication of the Template	Radiographic Marker Used	Imaging System Used	Conversion Process	Indication/ Advantages
Engelman et al ⁸	Auto polymerizing acrylic resin	Metal bearings	Panoramic radiography	Remove lingual surface, leaving only facial surface of the teeth in the proposed implant site	Inexpensive, easy, improved visibility, external irrigation
Adrian et al ¹⁰	Auto polymerizing acrylic resin	Lead foil over the maxillary and mandibular incisors, left mandibular occlusal plane, intaglio surface of mandibular trial denture	Lateral cephalography	Determine implant trajectory and location using radiopaque images; use cephalometric tracing paper, protractor, and surveyor to reproduce these data in a resin plane joining maxilla and mandible	Guides implant position and trajectory, serves as a bite-block, retracts the tongue and flap, allows sterile field, lessens chance of titanium contamination
Tarlow ¹¹	Acrylic resin duplicate denture; vacuum-formed thermoplastic matrix (0.02 inch) adapted over duplicate denture			Remove anterior lingual portion of matrix; remove anterior labial portion of duplicate denture	Indicated in anterior edentulous mandible; matrix dictates implant location and angulation, with minimal interference to surgical access
Espinosa Marino et al ¹²	Heat polymerizing acrylic resin	Dual-curing composite resin mixed with colored chalk	CT	Trim buccal side of the template	Indicated in partially edentulous patient
Stellino et al ¹³	Acrylic resin provisional FPD	Gutta-percha	CT	Remove gutta-percha from channels in the pontics	Alternative for removable radiologic template where a provisional FPD bridges the implant site
Pesun and Gardner ¹⁴	Vacuum-formed thermoplastic matrix; adapt over diagnostic cast and on the duplicate cast of diagnostic wax-up; fill orthodontic resin in the space between these 2 matrices	Gutta-percha	CT	Reduce vertical height of the guide; remove gutta-percha	Indicated in severely worn dentition
Takeshita et al ¹⁵	Denture base: auto polymerizing acrylic resin; teeth: mix powder consisting of 4:1 ratio of resin polymer and barium sulfate with monomer	Stainless steel tubes	Panoramic radiography, CT	Remove tube sprues	Barium sulfate depicts outline of the predesigned superstructure; stainless steel tubes represent location and inclination of the intended implant placement

TABLE

Continued

Author (y)	Material Used for Fabrication of the Template	Radiographic Marker Used	Imaging System Used	Conversion Process	Indication/ Advantages
Sicilia et al ¹⁶	Orthodontic wires and auto polymerizing acrylic resin	Contrast blocks, gutta-percha blocks	CT	Using wire, create 2 profiles of the missing teeth – occlusal and gingival Join these to acrylic resin block to make template solid and add self-retaining feature	Profiles mark the vestibular and mesiodistal limit of the teeth; the profile replaces buccal surface of the template
Minoretti et al ¹⁷	Vacuum-formed thermoplastic matrix or auto polymerizing acrylic resin	Guide sleeve		Insert Kirschner wires through mucosa/bone using dental handpiece; fit guidance cylinders fitting trephine drill ($\emptyset = 3.5$ mm, ITI Dental Implant system) to the guide wire	Indicated in completely edentulous patient or in augmented alveolar ridges where template position after flap reflection is difficult Improves precision of implant placement – improving guidance during drilling process
Ku and Shen ¹⁸	Vacuum-formed thermoplastic matrix filled with auto polymerizing resin acrylic resin	Gutta-percha	CT	Remove marker with carbide bur	Single implant therapy or short-span implant-supported prostheses
Becker and Kaiser ¹⁹ (Figure 2)	Vacuum-formed thermoplastic matrix (0.020 inch) and orthodontic resin	$5/32$ and $3/16$ inch brass tubes		Attach $3/16$ inch tube to the template $5/32$ inch tube guides the pilot drill	Precise surgical guide resulting in a functional and esthetically pleasing restoration
Cehreli et al ²⁰ (Figure 3)	Vacuum-formed thermoplastic matrix (2.0 × 125 mm)	Pins (1 mm diameter)	CT	Fabricate 2 acrylic templates covering only residual ridges with guide channels of 2 diameters Inner lamina: remove foil covering edentulous ridges, secure bur ends bilaterally – guides insertion of removable surgical acrylic resin template; outer lamina: remove palatal portion, prepare occlusal holes	Posterior maxillary region with poor bone density; outer lamina contains radiopaque markers for radiographic evaluation and verify alignment of implants; inner lamina accepts 2 removable surgical guides bilaterally
Almog et al ⁹ Vertical lead strip guide	Custom tray material/auto polymerizing resin with vacuum-formed thermoplastic matrix (0.02 inch)	Lead strip (2 mm) vertically on the lingual/palatal wall of the buccal access groove	CT	Remove lead strip	Surgical osteotomy but more error in the buccolingual placement

TABLE
Continued

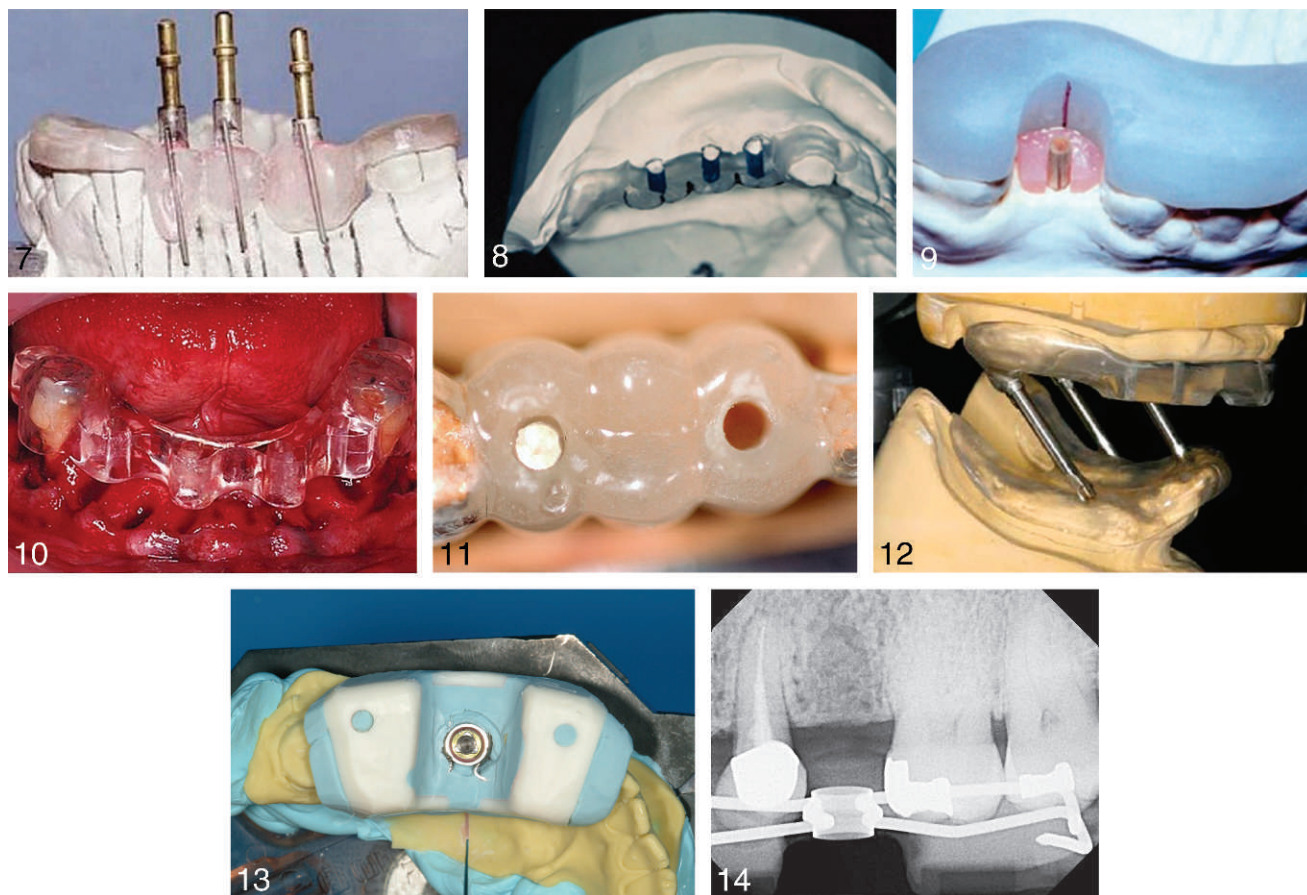
Author (y)	Material Used for Fabrication of the Template	Radiographic Marker Used	Imaging System Used	Conversion Process	Indication/ Advantages
Almog et al ⁹ Gutta-percha guide (Figure 4)	Custom tray material/auto polymerizing resin with vacuum-formed thermo-plastic matrix (0.02 inch)	Gutta-percha	CT	Remove gutta-percha	Surgical osteotomy allowing for some surgical latitude in preparation of the osteotomy sites
Almog et al ⁹ Metal sleeve guide (Figure 5)	Custom tray material or auto polymerizing resin	Metal guide sleeves	CT		Precise surgical osteotomy guide
Cehreli et al ²¹	Auto polymerizing acrylic resin	Pins (1 mm diameter)	CT	Attach internally stacked stainless steel guides	Place implants in low-density bone; dual-purpose guide incorporating 3 drill guides
Akça et al ²²	Auto polymerizing acrylic resin		Used when CT is not required for evaluation of buccolingual angulation of available bone	Construct 4-mm thick flat horizontal plane; construct perpendicular resin plane on lingual side of the flat plane; prepare guide channels; transfer mesiodistal reference axis to the perpendicular part	Indicated in posterior edentulous mandible; reference axis on the perpendicular plane guides mesiodistal implant angulation; retracts the mucoperiosteal flap lingually Improves site visualization
McArdle ²³	Vacuum-formed thermoplastic matrix, light cured restorative material			Restorative material forms guide core; prepare center guide channels	Single tooth implant-supported restorations; flexible material
Koyanagi ²⁴ (Figure 6)	Auto polymerizing acrylic resin	Orthodontic wire, stainless steel ball, gutta-percha point	Conventional tomography	Laser weld orthodontic round tube to the front cap of a latch type contra-angle handpiece	Template guides the head of the contra-angle handpiece, preventing the drill from contacting the template; allows objective assessment and determination of implant location, inclination, and depth for individual treatment cases
Kopp et al ²⁵ (Figure 7)	Auto polymerizing acrylic resin	Barium sulfate liquid coat, thin orthodontic wire (0.014–0.016 mm) glued to the buccal aspect	CT	Modify surveyor table using a protractor Secure 22-mm diameter milled cylinders in the template	Cylinders guide pilot drill Buccal guide wire guides all future drills in the buccolingual and mesiodistal direction
Tsuchida et al ²⁶ (Figure 8)	Auto polymerizing acrylic resin	Silicone impression material	CT	Remove silicone markers; remove buccal/lingual portion of the surgical template	Silicone markers: clear radiopaque markers that do not create artifacts in CT scanning

TABLE

Continued

Author (y)	Material Used for Fabrication of the Template	Radiographic Marker Used	Imaging System Used	Conversion Process	Indication/ Advantages
Windhorn ²⁷ (Figure 9)	Light polymerizing custom tray material			Use wooden stick as reference for molding resin around handpiece head	Wooden stick simulate implant location and angulation 2-piece implant placement guide
Al-Harbi and Verrett ²⁸ (Figure 10)	Auto polymerizing acrylic resin		CT of arch prior to extraction; treatment planning using SimPlant software	Transfer planning data to surgical guide using milling machine; trim occlusal surface and buccal flanges; maintain 5-mm coronal-apical thickness of resin	For immediate implant placement following complete arch odontectomy; stable guide following staged tooth extraction
Arfai and Kiat-Amnuay ²⁹ (Figure 11)	Auto polymerizing acrylic resin	Brass rod (³ / ₃₂ inch)	Periapical radiography	Remove the rods	Placement of multiple implants in adequate osseous structure; dental surveyor improves accuracy
Wat et al ³⁰ (Figure 12)	Auto polymerizing acrylic resin mixed with barium sulfate (ratio of 4:1)	Barium sulfate cylindrical channels drilled at proposed implant sites in radiographic template	CT	Remove nonsalvageable teeth to modify guide; place guide on the mounted cast; connect to the record base fabricated on the opposing arch, using embedded stainless rods and tubes	Convenient, economical, less traumatic, stable for edentulous arch opposing a partially edentulous arch, compatible with all implant systems
Oh and Saglik ³¹	Auto polymerizing acrylic resin (DRPD); attach vacuum-forming thermoplastic matrix (1 mm) to the DRPD using acrylic resin			Trim buccal and lingual denture base extensions; prepare guide channels in the middle of acrylic resin teeth with buccal windows	Thermoplastic sheet engages the remaining dentition, assists in an accurate orientation, and maintains the DRPD to serve as a surgical template; permits stable intraoral placement of denture for successful implant placement
Annibali et al ³²	Auto polymerizing acrylic resin	Stainless steel or titanium cylinders	Panoramic and periapical radiography, lateral cephalography, CT	Cylindrical marker guides the pilot drill	Uses silicone matrix that depicts the emergence profile and the ideal loading center of the proposed restoration

CT indicates computerized tomography; FPD, fixed partial denture; DRPD, duplicate interim removable partial denture.



FIGURES 7–14. **FIGURE 7.** Guide pins attached to the surgical guide to verify alignment of implants. Reprinted from *J Prosthet Dent* 2003;89:611–615, with permission from Elsevier. **FIGURE 8.** Facial portion of surgical template removed before surgery. Reprinted from *J Prosthet Dent* 2004;91:395–397, with permission from Elsevier. **FIGURE 9.** Two-piece implant placement surgical guide. Reprinted from *J Prosthet Dent* 2004;92:196–199, with permission from Elsevier. **FIGURE 10.** Surgical guide for immediate implant placement following staged tooth extraction. Reprinted from *J Prosthet Dent* 2005;94:394–397, with permission from Elsevier. **FIGURE 11.** Radiographic rod removed following radiographic analysis. Reprinted from *J Prosthet Dent* 2007;97:310–312, with permission from Elsevier. **FIGURE 12.** Surgical guide connected to mandibular record base. Reprinted from *J Prosthet Dent* 2008;100:323–325, with permission from Elsevier. **FIGURE 13.** Cast-based surgical guide. Reprinted from *J Prosthet Dent* 2008;100:61–69, with permission from the corresponding author. **FIGURE 14.** Radiographic view of the cast-based surgical guide. Reprinted from *J Prosthet Dent* 2008;100:61–69, with permission from the corresponding author.

CAD/CAM-BASED SURGICAL GUIDE

CAD/CAM technology uses data from computerized tomography scan (CT)³³ to plan implant rehabilitation. The CT images are converted into data that are recognized by a CT imaging and planning software. This software then transfers this presurgical plan to the surgery site using stereolithographic drill guides.³⁴ CAD/CAM-based surgical guides offer many advantages. For example, the virtual 3-dimensional (3D) views of the bony morphology allow the surgeon to visualize the surgical bone site prior to implant placement; risks such as inadequate osseous support or compromise of important anatomic structures are avoided; incorporation of

prosthetic planning using a scanographic template allows the treatment to be optimized from a prosthodontics and biomechanical point of view³⁵; and the technique promotes flapless surgeries, allows presurgical construction of the master cast and provisional restorations, and facilitates immediate loading.³⁶ Accuracy of CAD/CAM technology in dental implant planning and predictable transfer of the presurgical plan to the surgical site has been documented.^{37–46} However, the effectiveness has not yet become an established fact and still needs ongoing research. This technique has certain drawbacks. Special training for familiarity with the entire system and special equipment is necessary.

Also, a considerable number of technique-related complications were observed. The various complications⁴⁷ recorded were related to inaccurate planning, radiographic stent error, intrinsic errors during scanning, software planning, the rapid prototyping of the guide stent, and the transfer of information for the prosthetics. However, if the clinician recognizes these sources of inaccuracy, efforts can be made to minimize the error and optimize patient treatment.

The procedure for fabrication of CAD/CAM-based surgical guides can be divided into the following steps:

1. Fabrication of the radiographic template,
2. The computerized tomography scan,
3. Implant planning using interactive implant surgical planning software, and
4. Fabrication of the stereolithographic drill guide.

The radiographic template must be an exact replica of the desired prosthetic end result, as it allows the clinician to visualize the location of planned implants from an esthetic and biomechanical standpoint.⁴⁸ This is followed by fabrication of an interocclusal index, to allow reproducible placement of the scan template intraorally.⁴⁹

A double scanning procedure is then followed.⁴⁹ The patient is scanned wearing the radiographic scan template and radiographic index (interocclusal index) during the first scan, whereas the second scan is performed without the index. The first scan is used to visualize the bony architecture and anatomy of the site of interest, and a second scan is performed to visualize the nonradiopaque radiographic guide. The 2 resulting sets of 2D CT data (Digital Imaging and Communication in Medicine [DICOM files]) are then superimposed over each other according to the radiographic markers and are further converted into a file format compatible with the 3D planning program.⁴⁹ Resulting from this fusion is an exact representation of the patient's bone structure and scanning denture in 3D space. At this point, the virtual surgical procedure can be performed.^{49,50} A 3D implant planning software allows for simultaneous observation of both the arches and the radiographic scan template in 3 spatial planes and helps to virtually plan the location, angle, depth, and diameter of the virtual implants. It produces an axial image, a panoramic image, and a series of cross-sectional images on the

screen at the same time. Various implant planning software products are available commercially, namely, SimPlant, SurgiCase (Materialise Dental Inc, Leuven, Belgium), Procera (Nobel Biocare, Göteborg, Sweden), ImplantMaster (I-Dent Imaging Ltd, Hod Hasharon, Israel), coDiagnostiX (IVS Solutions AG, Chemnitz, Germany), and Easy Guide (Keystone Dental, Burlington, MA).

Once the computer planning is accomplished, this plan is saved as a ".sim" file and sent to the processing center for fabrication of the surgical guide, using stereolithography. Stereolithography³⁴ is a computer-guided, laser-dependent, rapid prototyping polymerization process that can duplicate the exact shape of the patient's skeletal anatomic landmarks in a sequential layer of a special polymer to produce a special 3D transparent resin model, which fits intimately with the hard and/or soft tissue surface. Once hardened, the polymeric prototype contains spaces for stainless steel or titanium drill-guiding tubes. These tubes precisely guide the osteotomy drills, precluding the need for the pilot drills.

CONCLUSION

Although the completely limiting design is considered a far superior design concept, most clinicians still adopt the partially limiting design due to its cost-effectiveness and credibility in the field. In addition, it has been observed that most clinicians use surgical guide templates that are based on cross-sectional imaging to facilitate accurate planning and guidance during the surgical phase. Evidence-based research still needs to be conducted to evaluate the applications of the completely limiting design and its effect on the treatment outcome in oral implantology.

ABBREVIATIONS

CAD/CAM: computer-aided design and manufacturing

CT: computerized tomography

FPD: fixed partial denture

DRPD: duplicate interim removable partial denture

REFERENCES

1. Torabinejad M, Anderson P, Bader J, et al. Outcomes of root canal treatment and restoration, implant-supported single

crowns, fixed partial dentures, and extraction without replacement: a systematic review. *J Prosthet Dent.* 2007;98:285–311.

2. Ganz SD. Presurgical planning with CT-derived fabrication of surgical guides. *J Oral Maxillofac Surg.* 2005;63:59–71.

3. Park C, Raigrodski AJ, Rosen J, Spiekerman C, London RM. Accuracy of implant placement using precision surgical guides with varying occlusogingival heights: an in vitro study. *J Prosthet Dent.* 2009;101:372–381.

4. Garber DA, Belser UC. Restoration-driven implant placement with restoration-generated site development. *Compend Contin Educ Dent.* 1995;16: 796, 798–802, 804.

5. Misch CE, Dietsh-Misch F. Diagnostic casts, preimplant prosthodontics, treatment prostheses, and surgical templates. In: Misch CE, ed. *Contemporary Implant Dentistry*. 2nd ed. St Louis, Mo: Mosby; 1999:135–150.

6. Stumpel LJ 3rd. Cast-based guided implant placement: a novel technique. *J Prosthet Dent.* 2008;100:61–69.

7. Blustein R, Jackson R, Rotskoff K, Coy RE, Godar D. Use of splint material in the placement of implants. *Int J Oral Maxillofac Implants.* 1986;1:47–49.

8. Engelman MJ, Sorensen JA, Moy P. Optimum placement of osseointegrated implants. *J Prosthet Dent.* 1988;59:467–473.

9. Almog DM, Torrado E, Meitner SW. Fabrication of imaging and surgical guides for dental implants. *J Prosthet Dent.* 2001;85: 504–508.

10. Adrian ED, Ivanhoe JR, Krantz WA. Trajectory surgical guide stent for implant placement. *J Prosthet Dent.* 1992;67:687–691.

11. Tarlow JL. Fabrication of an implant surgical stent for the edentulous mandible. *J Prosthet Dent.* 1992;67:217–218.

12. Espinosa Marino J, Alvarez Arenal A, Pardo Ceballos A, Fernandez Vazquez JP, Ibaseta Diaz G. Fabrication of an implant radiologic-surgical stent for the partially edentulous patient. *Quintessence Int.* 1995;26:111–114.

13. Stellino G, Morgano SM, Imbelloni A. A dual-purpose, implant stent made from a provisional fixed partial denture. *J Prosthet Dent.* 1995;74:212–214.

14. Pesun IJ, Gardner FM. Fabrication of a guide for radiographic evaluation and surgical placement of implants. *J Prosthet Dent.* 1995;73:548–552.

15. Takeshita F, Tokoshima T, Suetsugu T. A stent for presurgical evaluation of implant placement. *J Prosthet Dent.* 1997;77:36–38.

16. Sicilia A, Noguero B, Cobo J, Zabalegui I. Profile surgical template: a systematic approach to precise implant placement. A technical note. *Int J Oral Maxillofac Implants.* 1998;13:109–114.

17. Minoretti R, Merz BR, Triaca A. Predetermined implant positioning by means of a novel guide template technique. *Clin Oral Implants Res.* 2000;11:266–272.

18. Ku YC, Shen YF. Fabrication of a radiographic and surgical stent for implants with a vacuum former. *J Prosthet Dent.* 2000;83: 252–253.

19. Becker CM, Kaiser DA. Surgical guide for dental implant placement. *J Prosthet Dent.* 2000;83:248–251.

20. Cehreli MC, Aslan Y, Sahin S. Bilaminar dual-purpose stent for placement of dental implants. *J Prosthet Dent.* 2000;84:55–58.

21. Cehreli MC, Calis AC, Sahin S. A dual-purpose guide for optimum placement of dental implants. *J Prosthet Dent.* 2002;88: 640–643.

22. Akça K, Iplikcioglu H, Cehreli MC. A surgical guide for accurate mesiodistal paralleling of implants in the posterior edentulous mandible. *J Prosthet Dent.* 2002;87:233–235.

23. McArdle BF. A technique to enhance closed surgical stents for implant placement. *J Am Dent Assoc.* 2002;133:331–333.

24. Koyanagi K. Development and clinical application of a surgical guide for optimal implant placement. *J Prosthet Dent.* 2002; 88:548–552.

25. Kopp KC, Koslow AH, Abdo OS. Predictable implant placement with a diagnostic/surgical template and advanced radiographic imaging. *J Prosthet Dent.* 2003;89:611–615.

26. Tsuchida F, Hosoi T, Imanaka M, Kobayashi K. A technique for making a diagnostic and surgical template. *J Prosthet Dent.* 2004;91:395–397.

27. Windhorn RJ. Fabrication and use of a simple implant placement guide. *J Prosthet Dent.* 2004;92:196–199.

28. Al-Harbi SA, Verrett RG. Fabrication of a stable surgical template using staged tooth extraction for immediate implant placement. *J Prosthet Dent.* 2005;94:394–397.

29. Arfai NK, Kiat-Amnuay S. Radiographic and surgical guide for placement of multiple implants. *J Prosthet Dent.* 2007;97:310–312.

30. Wat PY, Pow EH, Chau FS, Leung KC. A surgical guide for dental implant placement in an edentulous jaw. *J Prosthet Dent.* 2008;100:323–325.

31. Oh WS, Saglik B. Use of a thermoplastic vacuum-formed matrix for secure engagement of an implant surgical template. *J Prosthet Dent.* 2008;100:326–327.

32. Annibaldi S, La Monaca G, Tantardini M, Cristalli MP. The role of the template in prosthetically guided implantology. *J Prosthodont.* 2009;18:177–183.

33. Marchack CB. CAD/CAM-guided implant surgery and fabrication of an immediately loaded prosthesis for a partially edentulous patient. *J Prosthet Dent.* 2007;97:389–394.

34. Nikzad S, Azari A. A novel stereolithographic surgical guide template for planning treatment involving a mandibular dental implant. *J Oral Maxillofac Surg.* 2008;66:1446–1454.

35. Holst S, Blatz MB, Eitner S. Precision for computer-guided implant placement: using 3D planning software and fixed intraoral reference points. *J Oral Maxillofac Surg.* 2007;65:393–399.

36. Spector L. Computer-aided dental implant planning. *Dent Clin North Am.* 2008;52:761–775.

37. Jabero M, Sarment DP. Advanced surgical guidance technology: a review. *Implant Dent.* 2006;15:135–142.

38. Almog DM, Benson BW, Wolfgang L, Frederiksen NL, Brooks SL. Computerized tomography-based imaging and surgical guidance in oral implantology. *J Oral Implantol.* 2006;32:14–18.

39. Valente F, Schiroli G, Sbrenna A. Accuracy of computer-aided oral implant surgery: a clinical and radiographic study. *Int J Oral Maxillofac Implants.* 2009;24:234–242.

40. Horwitz J, Zuabi O, Machtei EE. Accuracy of a computerized tomography-guided template-assisted implant placement system: an in vitro study. *Clin Oral Implants Res.* 2009;20:1156–1162.

41. Schneider D, Marquardt P, Zwahlen M, Jung RE. A systematic review on the accuracy and the clinical outcome of computer-guided template-based implant dentistry. *Clin Oral Implants Res.* 2009;20:73–86.

42. Arisan V, Karabuda ZC, Ozdemir T. Accuracy of two stereolithographic guide systems for computer-aided implant placement: a computed tomography-based clinical comparative study. *J Periodontol.* 2010;81:43–51.

43. Bill JS, Reuther JF, Dittmann W, et al. Stereolithography in oral and maxillofacial operation planning. *Int J Oral Maxillofac Surg.* 1995;24:98–103.

44. Erickson DM, Chance D, Schmitt S, Mathis J. An opinion survey of reported benefits from the use of stereolithographic models. *J Oral Maxillofac Surg.* 1999;57:1040–1043.

45. Sarment DP, Sukovic P, Clinthorne N. Accuracy of implant placement with a stereolithographic surgical guide. *Int J Oral Maxillofac Implants.* 2003;18:571–577.

46. Ersoy AE, Turkyilmaz I, Ozan O, McGlumphy EA. Reliability of implant placement with stereolithographic surgical guides generated from computed tomography: clinical data from 94 implants. *J Periodontol.* 2008;79:1339–1345.

47. Block MS, Chandler C. Computed tomography-guided

surgery: complications associated with scanning, processing, surgery, and prosthetics. *J Oral Maxillofac Surg.* 2009;67:13-22.

48. Lal K, White GS, Morea DN, Wright RF. Use of stereolithographic templates for surgical and prosthodontic implant planning and placement. Part I. The concept. *J Prosthodont.* 2006;15:51-58.

49. Sanna AM, Molly L, van Steenberghe D. Immediately

loaded CAD-CAM manufactured fixed complete dentures using flapless implant placement procedures: a cohort study of consecutive patients. *J Prosthodont.* 2007;97:331-339.

50. Komiya A, Klinge B, Hultin M. Treatment outcome of immediately loaded implants installed in edentulous jaws following computer-assisted virtual treatment planning and flapless surgery. *Clin Oral Implants Res.* 2008;19:677-685.

Submit by Email Print Form

Statement of Ownership, Management, and Circulation
(All Periodicals Publications Except Requester Publications)

1. Publication Title
Journal of Oral Implantology

2. Publication Number
0 2 5 1 6 3 2

3. Filing Date
Sep 21, 2012

4. Issue Frequency
Bimonthly

5. Number of Issues Published Annually
7

6. Annual Subscription Price
\$492.00

7. Complete Mailing Address of Known Office of Publication (Not printer) (Street, city, county, state, and ZIP+4®)
211 East Chicago Avenue #750, Chicago, IL 60611

Contact Person
Caitlin Brown
Telephone (include area code)
785-843-1234 ext.242

8. Complete Mailing Address of Headquarters or General Business Office of Publisher (Not printer)
810 East 10th Street, Lawrence, KS 66044

9. Full Names and Complete Mailing Addresses of Publisher, Editor, and Managing Editor (Do not leave blank)

Publisher (Name and complete mailing address)
Maria Preslon-Cergil, 810 East 10th Street, Lawrence, KS 66044

Editor (Name and complete mailing address)
James Rutkowski, 35 South Second Avenue, Clarion, PA 16214

Managing Editor (Name and complete mailing address)
Beverly Lindeen, 810 East 10th Street, Lawrence, KS 66044

10. Owner (Do not leave blank. If the publication is owned by a corporation, give the name and address of the corporation immediately followed by the names and addresses of all stockholders owning or holding 1 percent or more of the total amount of stock. If not owned by a corporation, give the names and addresses of the individual owners. If owned by a partnership or other unincorporated firm, give its name and address as well as those of each individual owner. If the publication is published by a nonprofit organization, give its name and address.)

Full Name	Complete Mailing Address
American Academy of Implant Dentistry	211 East Chicago Avenue #750, Chicago, IL 60611

11. Known Bondholders, Mortgagees, and Other Security Holders Owning or Holding 1 Percent or More of Total Amount of Bonds, Mortgages, or Other Securities. If none, check box None

Full Name	Complete Mailing Address

12. Tax Status (For completion by nonprofit organizations authorized to mail at nonprofit rates) (Check one)
The purpose, function, and nonprofit status of this organization and the exempt status for federal income tax purposes:
 Has Not Changed During Preceding 12 Months
 Has Changed During Preceding 12 Months (Publisher must submit explanation of change with this statement)

PS Form 3526, September 2007 (Page 1 of 3 (Instructions Page 3)) PSN 7530-01-000-9931 PRIVACY NOTICE: See our privacy policy on www.usps.com


13. Publication Title
Journal of Oral Implantology

14. Issue Date for Circulation Data Below
September 2012

15. Extent and Nature of Circulation

Dentistry, Oral Surgery		Average No. Copies Each Issue During Preceding 12 Months	No. Copies of Single Issue Published Nearest to Filing Date
a. Total Number of Copies (Not press run)		4256	4800
b. Paid Circulation (By Mail and Outside the Mail)	(1) Mailed Outside-County (First-Class Mail Subscriptions Stated on PS Form 3541) (Include paid distribution above nominal rate, advertiser's proof copies, and exchange copies)	2974	3436
	(2) Mailed In-County Paid Subscriptions Stated on PS Form 3541 (Include paid distribution above nominal rate, advertiser's proof copies, and exchange copies)	0	0
	(3) Paid Distribution Outside the Mails Including Sales Through Dealers and Carriers, Street Vendors, Counter Sales, and Other Paid Distribution Outside USPS®	186	327
	(4) Paid Distribution by Other Classes of Mail Through the USPS (e.g. First-Class Mail®)	792	816
c. Total Paid Distribution (Sum of 15b (1), (2), (3), and (4))		3962	4579
d. Free or Nominal Rate Distribution (By Mail and Outside the Mail)	(1) Free or Nominal Rate Outside-County Copies Included on PS Form 3541	20	16
	(2) Free or Nominal Rate In-County Copies Included on PS Form 3541	0	0
	(3) Free or Nominal Rate Copies Mailed at Other Classes Through the USPS (e.g. First-Class Mail)	1	1
	(4) Free or Nominal Rate Distribution Outside the Mail (Carriers or other means)	0	0
e. Total Free or Nominal Rate Distribution (Sum of 15d (1), (2), (3) and (4))		21	17
f. Total Distribution (Sum of 15c and 15e)		3983	4596
g. Copies not Distributed (See Instructions to Publishers #4 (page #3))		274	204
h. Total (Sum of 15f and g)		4257	4800
i. Percent Paid (File divided by 15f times 100)		99.5%	99.6%

16. Publication of Statement of Ownership
 If the publication is a general publication, publication of this statement is required. Will be printed in the October 2012 issue of this publication. Publication not required.

17. Signature and Title of Editor, Publisher, Business Manager, or Owner
 Date: 9-15-12

I certify that all information furnished on this form is true and complete. I understand that anyone who furnishes false or misleading information on this form or who omits material or information requested on the form may be subject to criminal sanctions (including fines and imprisonment) and/or civil sanctions (including civil penalties).

PS Form 3526, September 2007 (Page 2 of 3)

Downloaded from http://meridian.allenpress.com/joi/article-pdf/38/5/643/2057799/aaid-joi-d-11-00018.pdf by guest on 13 May 2025