

Squamous Cell Carcinoma in Association With Dental Implants: An Assessment of Previously Hypothesized Carcinogenic Mechanisms and a Case Report

Neel B. Bhatavadekar, MS, MPH*

Although dental implants have seen tremendous clinical success over the past few decades, there are some worrying reports in literature describing squamous cell carcinoma (SCC) in close association with dental implants. This article also provides a critical assessment of the published literature relating to the presence of carcinoma in association with dental implants, analyzing the previously published and hypothesized carcinogenic responses to an implant, to try and come to a conclusion regarding the plausibility and clinical risk for cancer formation in association with dental implants. An unusual case of an SCC noted in close proximity to a dental implant is also presented. A systematic search was conducted using Medline (PubMed), Cochrane Database, and Google Scholar with the search terms "cancer," "squamous cell carcinoma," "dental implant," "SCC," "peri-implantitis," "oral cancer," and "implantology" and using multiple combinations using Boolean operators "or" and "and." The search was not limited to dental literature; orthopedic and biomedical literature was also included. The results were then hand screened to pick out the relevant articles. In total, 14 previous published reports were found, where 24 dental implants were reported to be associated with SCC. Not all the reported patients had a history of cancer, but contributory factors such as smoking were found. An analysis of the biological plausibility of previously proposed carcinogenic mechanisms, such as corrosion, metallic ion release, and particulate debris, did not support the etiologic role for dental implants in cancer development, and the standardized incidence ratio was found to be extremely low (0.00017). Peri-implantitis should be assessed cautiously in patients receiving implants who have a previous history of cancer. Dental implants are a safe treatment modality based on the published data, and any change in surgical protocol is not mandated.

Key Words: *dental implant, carcinogen, carcinoma*

INTRODUCTION

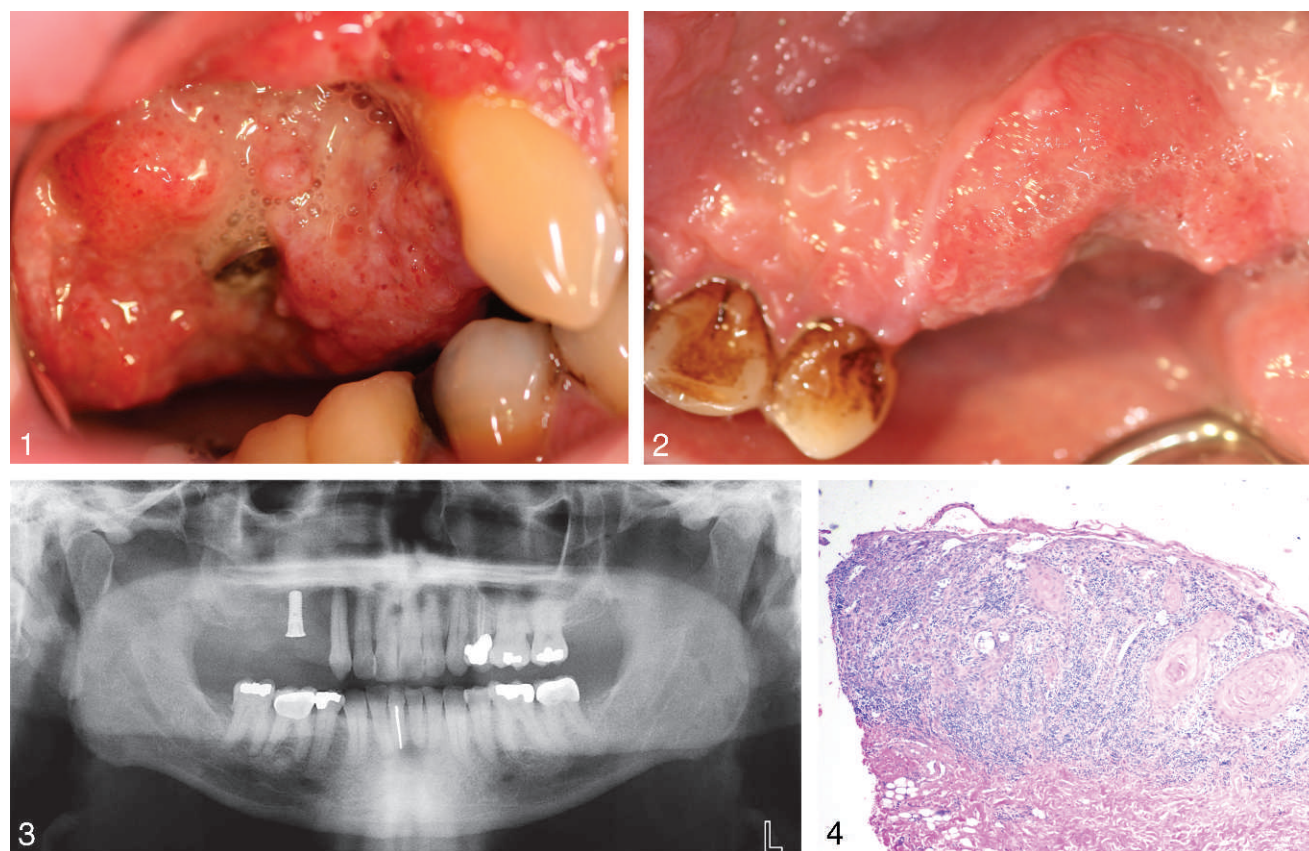
This article presents an unusual case of a squamous cell carcinoma (SCC) in close association with a dental implant. Although dental implants have seen tremendous clinical success over the past few decades, the recent literature has had some reports of SCC in close association with dental implants.¹⁻⁶ A recent report made a bold statement

that implants can be a cause of cancer by providing a "route of entry for squamous cell carcinoma,"¹ and another report stated that dental implants can lead to SCC in at-risk patients,³ perhaps by ingress of carcinogenic ionic debris. Markets for dental implants have been estimated at \$3.4 billion in 2008, and are anticipated to reach \$8.1 billion by 2015.⁷ It is estimated that in 2008, in the United States alone, 900 000 dental implants were placed.⁷ Hence, as clinicians, we need to be quite concerned about such claims of cancer formation with dental implants. Some of the previous published reports¹⁻⁶ obviously leave room for doubt regarding the possible relation between dental implants and cancer, with one report

Dental Specialty Center, Bombay Hospital Research Center, Mumbai, India.

* Corresponding author, e-mail: drneel1@gmail.com.

DOI: 10.1563/AAID-JOI-D-11-00045



FIGURES 1–4. **FIGURE 1.** Buccal view of lesion. **FIGURE 2.** Palatal view of lesion. **FIGURE 3.** Panoramic image demonstrating implant in the region of tooth #3. **FIGURE 4.** Histologic analysis of biopsy (hematoxylin eosin stain at 40× magnification).

even leading us to suspect that we might be misdiagnosing SCC as the more innocuous peri-implantitis.⁸ Thus, a review of the previously published literature is also presented here with an aim to provide the reader with a better assessment tool.

CASE PRESENTATION

Patient JE, a 54-year-old white man, presented to the University of Texas Health Science Center, Houston, reporting a dull ache in the upper right jaw lasting 2 months. The patient reported no systemic diseases, no history of alcohol consumption or smoking, and no history of cancer anywhere in the body. The patient was uncertain about a family history of cancer, however. When his previous physician was contacted, he was able to confirm that the patient was ASA 1, was not currently on any medications, and had no history of any previous illness. In addition, the patient had always been a nonsmoker, and there was no family history of any systemic illnesses.

The patient had been visiting his dentist for 5 years, and the dentist had never detected any oral lesion or pathologic condition, and his previous dental history with this dentist of treatment and restorations for tooth #18 and tooth #19. All other restorations and endodontic treatments had been completed more than 10 years ago by another dentist. One year ago, the patient had visited his dentist for implant placement in the region of tooth #3. Over the next several months, he had noticed an ulceration around the implant site, with a “slight swelling,” which he attributed to his lack of brushing in the region. The patient stated that before the dental implant placement, he had not noticed any oral ulcers, raised areas or swellings, any areas of discoloration, or any other lesions in his mouth. After he noticed the swelling around the implant, he did not self-medicate or see a dentist. He subsequently relocated and thus presented for a checkup at our outpatient dental clinic.

Upon clinical examination (Figures 1 and 2), the mucosa surrounding the dental implant showed

significant ulceration and appeared to have a raised appearance with irregular margins. The healing screw above the implant was visible from the buccal aspect, but it was covered by mucosa on the palatal aspect. The probing depth on the buccal aspect of the implant was 7 mm with bleeding on probing. Submandibular and cervical lymph nodes were nonpalpable. Oral hygiene in the region was poor, with presence of halitosis.

Radiographic examination with an orthopantomogram (Figure 3) revealed an area of bone loss around the dental implant extending from the distal aspect of the dental implant up to the distal aspect of tooth #3. As no contact could be established with the previous dentist, the implant was assessed to be a Straumann or Straumann-clone implant (Straumann, Basel, Switzerland) based on radiographic examination. Tooth #3 tested vital on electric pulp testing. The mandibular arch demonstrated evidence of previous restorative work, but no other pathologic lesion was noted.

The periodontal charting confirmed that the probing depths in other regions of the mouth were less than 4 mm, with minimal bleeding on probing. An incisional biopsy of the region was immediately performed, and the histologic examination (Figure 4) revealed well-differentiated epithelial cells, with keratin pearl formation, nuclei scattered around central mass, irregular basement membrane, and a superficially invasive nature. These classic histologic features of a low-grade SCC confirmed the diagnosis. The patient was referred to the Department of Oral and Maxillofacial Surgery for surgical excision and subsequent rehabilitation. The patient moved shortly thereafter and received subsequent treatment in another state, thus, follow-up photos and radiographs are unfortunately not available.

The etiology of this SCC could not be attributed to any known specific contributory factor. By the same token, a cause-and-effect relation between the implant placement and SCC formation cannot be proven in this unusual case. In an attempt to assess the prevalence of similar cases in published literature, a literature review was conducted, as reported in the next section.

LITERATURE SEARCH

A literature search was conducted (January 1, 1950, up to January 1, 2011) using Medline (PubMed),

Cochrane Database, and Google Scholar with the search terms "cancer," "carcinoma," "squamous cell carcinoma," "carcinogen," "dental implant," "SCC," "peri-implantitis," "oral cancer," and "implantology" and with multiple combinations using Boolean operators "or" and "and." The results were then hand screened to pick out the relevant articles. No search limits, such as language, year, or study type, were used for this systematic literature search. The search was not limited to dental literature; the orthopedic and biomedical literature was also included.

In total, 14 previously published reports were found (Table) where SCC had been noted as being associated with a total of 24 dental implants, including one in this current report. All the prior publications were case reports, except for one review article, which was in French.⁸ Also, as shown in the table, except for 4 reports (4 patients), all the rest had a history of SCC or a metastatic cancer, along with relevant contributory factors, such as smoking.

Some mention of the carcinogenic potential of metallic implants can be found in the orthopedic and biomaterials literature,¹⁵ where 20 cases have been described in which tumors were identified in proximity to metallic implants over a 34-year period. The report also states that investigators have identified a 70% increased incidence of lymphomas and hematopoietic tumors in patients who had received total hip arthroplasties over the rates seen in the general population. We need to keep in mind, however, that the surface area of a hip implant is substantially greater than that of a dental implant, and the metallic composition of the hip implant is often different from that of a dental implant. Also, many femoral implants use cement for fixation, and the composition of the alloys used differs extensively. Hence, a direct extrapolation of these orthopedic results to the dental scenario would be unfair.

The numerous carcinogenicity theories that have been proposed in the orthopedic world include the potential direct toxicity of materials, the effects of surface properties, the electromotive potential created by dissimilar metals in contact, the immunologic response to implants, and finally, the sustained presence of low-grade infection.¹⁵ Most of these theories have been hypothesized in case

TABLE
Results of a literature search for articles associating dental implants with cancer

Serial No.	Author	No. of Patients	Previous History of Cancer	No. of Implants in Association With Squamous Cell Carcinoma
1	Abu et al ⁹	1	No	2
2	Block et al ²	1	Yes	1
3	Clapp et al ⁹	3	Yes (2), No (1)	3
4	Czeminski et al ⁴	2	Yes	2
5	Eguia del Valle et al ⁶	1	No	2
6	Gallego et al ⁵	1	Yes	1
7	Gallego et al ¹⁰	1	No	1
8	Gulati et al ¹¹	1	Yes	1
9	Kwok et al ³	1	Yes	3
10	Moxley et al ¹²	1	Yes	1
11	Shaw et al ¹³	1	Yes	2
12	Verhoeven et al ¹⁴	1	Yes	1
13	De Caueleur et al ²⁸	3	Yes	3
14	Meijier et al ²⁹	1	Yes	1
15	Current article	1	No	1
	Total	20		25

reports, and although they have generated tremendous debate, they have remained largely unproven.

In the dental literature, although the direct carcinogenic role of dental implants has never been established, several carcinogenicity theories, such as corrosion products, metallic ion release, and migration of malignant cells through the sulcus around the implant, have been proposed.^{1,8} Thus, the biological plausibility of cancer formation in association with dental implants can be assessed by examining the following previously hypothesized factors^{1,8,9}: (a) dental implant corrosion, (2) the possible association between corrosion products and cancer, (3) the possible association between particulate titanium (Ti) and cancer, and (4) the hypothesized carcinogenic effect of sustained metallic ion release after implant placement.

CORROSION OF DENTAL IMPLANTS

Corrosion is the deterioration a metal undergoes as a result of the surrounding medium (electrochemical attack), which causes the release of ions into the microenvironment. Olmeda et al,¹⁶ in a review article on corrosion in dental implants, considers corrosion phenomena at the interface of dental implant and bone to be particularly important in the evolution of dental and orthopedic implants

and one of the possible causes of implant failure after initial success.

Most commercially available dental implants are made of pure Ti (CP-Ti) or a Ti alloy (Ti-6Al-4V).¹⁷ Although Ti alloys are exceptionally resistant to corrosion because of the stability of the oxide layer, when the oxide layer is broken down or removed, Ti can be as corrosive as many other base metals.¹⁷ Specifically, in cases of peri-implantitis, the attachment of microbes to the implant surface can lead to a disturbance and eventual removal of this passivating oxide layer,¹⁸ thus paving the road for possible implant corrosion. Because of the deposition of the biofilm, the area underneath and around it is exposed to differing levels of oxygen. Less aerated zones start acting as an anode, undergoing corrosion and releasing ions in the surrounding tissue.¹⁷ Thus, in a healthy osseointegrated implant, corrosion and release of metallic ions would not be a consideration, as there is intimate bone contact with the metallic surface and absence of a biofilm; on the other hand, it might be a consideration for failing implants and in cases of peri-implantitis.

PARTICULATE DEBRIS AND CANCER

It has been previously proposed that in case of implant mobility, micro-motion between the implant and surrounding tissue can lead to particulate

debris.¹⁹ The concept of "implant bursitis" has been proposed in the orthopedic literature,²⁰ wherein the particulate debris around an implant can lead to an inflammatory reaction and release of eicosanoids, collagenase, and prostaglandin E₂, leading to bone resorption. Immune reactivity has been shown to depend on the number of particles produced or the dose (ie, the concentration of phagocytosable particles per tissue volume, which can be characterized when one knows the size distribution and amount of debris).¹⁹ Elongated particles are generally more proinflammatory than round particles, and there is a growing consensus that metals particles are more proinflammatory than polymers *in vivo*.^{19,20}

In the earlier days of hydroxyapatite-coated dental implants, particulate debris was a clear problem because of the difference in shear moduli of the coating and the underlying Ti; however, even with modern Ti implants, formation of microdebris might potentially be a factor in situations where micro-motion is possible, if we extrapolate from the orthopedic literature.²⁰ Although Ti particles have been shown to lead to an increase in levels of prostaglandin E-2 and interleukin-1,²¹ a clear association between Ti particles and cancer seems to be unproven yet. If this association is proved in the future, then in those specific situations where dental implants have become mobile, another reason to expedite removal of the implant, in addition to preventing bone loss, might be to prevent formation of microparticles, which might hypothetically be carcinogenic. However, with the currently available data, the contention that microparticles alone might be a contributory factor for cancer formation does not hold up.

MIGRATION OF MALIGNANT CELLS THROUGH THE SULCUS

It has been previously proposed that the placement of the dental implant opens a portal of entry for malignant cells to reach the bone through the gingival sulcus. A recent case report¹ hypothesizes that the placement of a dental implant led to migration of malignant cancer cells through the sulcus into the mandibular bone. To assess this hypothesis, we need to bear in mind that with a completely osseointegrated implant there is a union of the implant with bone and the presence of a

physiologic biological width similar to that found around natural teeth.²² Hence, it seems unlikely that the sulcus around the dental implants would provide an easier pathway for ingress of malignant cells compared with a natural tooth, as the structural soft-tissue attachment around the dental implant is similar to that around natural teeth.²² Thus, the mere insertion of a dental implant would logically not increase any hypothesized chances of malignant cell ingress, whereby the malignant cells would preferentially invade the implant sulcus and not the adjacent tooth.

METALLIC ION RELEASE AFTER IMPLANT PLACEMENT

An interesting hypothesis that was previously proposed was the carcinogenic effect of metallic ion release. According to Galante et al,²³ the question of whether metallic implants in general cause cancer can be resolved by looking at 3 separate issues: (1) carcinogenicity of the metallic ions, (2) exposure level to the patient, and (3) incidence of cancer in patients treated with implants.

The Ti ion is known to be one of the most inert metallic ions, with a very low corrosion rate 0.003 $\mu\text{A}/\text{cm}^2$.²³ As regards the exposure level to the patient, this would logically depend on the surface area of the implant, time duration, and release of metallic ions. Because the surface area of each dental implant is typically very small, the only conceivable situation where a significant surface area would exist would be in patients with multiple implants. However, it is difficult to establish a threshold of how many implants would constitute a significant total surface area. To assess the incidence of cancer in patients treated with dental implants, we can only look at the number of reported and published cases of this nature. However, from the cases reported in the table it is evident that most of the reports relate to single implants, and if the aforementioned hypothesis were true, then most of the reports would be found relating to patients with multiple implant where the surface area would be higher, and this does not seem to be the case. Unfortunately, we have to contend with the fact that using published cases might not be the most accurate representation of the incidence.

DENTAL IMPLANTS AS A CANCER RISK

So, do metallic implants indeed lead to a higher risk for cancer? The orthopedic literature shows a great variation in opinion regarding the increased risk of cancers after joint replacements. Gillespie et al²⁴ concluded that there is an “apparent association between total hip replacement and the incidence of remote malignant tumors in the decade following implantation” but stopped short of saying that implants cause cancer. On the one hand, Black,²⁵ in addition to concluding that there is a finite risk of cancer with hip implants, which increases with exposure, also notes that for an uninformed patient, any risk is an “involuntary assumed risk.” On the other hand, Martin et al²⁶ states that, given the tremendous number of metallic devices in place, the development of any malignant lesion might be completely coincidental.

Even if we hypothetically assume that dental implants are indeed associated with a higher incidence of cancer, what might the clinical risk be? An epidemiologic approach to assess risk is to determine the standardized incidence ratio (SIR). To assess if the hypothesized risk of cancer after dental implant placement should change clinical decisions, we would need to assess the magnitude of the risk, assuming that the risk was indeed true. Multiplying the baseline risk of SCC by the SIR would yield the risk of SCC associated with dental implants.

The calculation of SIR depends on the number of expected cases, which in turn, depends on the number of patient years at risk.²³ The estimated number of dental implants placed in 2008 in the United States alone are about 900 000 with an estimated increase of 10%–15% each year.⁷ If we assume that there are only 20 reported cases of SCC (Table) associated with dental implants over a 10-year period, including this report, then there were a total of 9 000 000 implants at risk during this time period in the United States alone. The calculated SIR is thus very small at 0.00017. The SEER (Surveillance Epidemiology and End Results, National Cancer Institute) data demonstrate that the baseline risk for oral cancers is 1.04 per 1 000 000 people per year. Using these figures, the estimated risk of SCC in association with a dental implant is incredibly small at 0.00017 per 1 000 000 people per year. We need to bear in mind that the SIR for SCC associated with dental

implants will be greater if the number of actual cases is greater than the number of reported cases. Correspondingly, it will decrease if the number of patient years was underestimated. It should also be noted that the SIR will be lowered further if the number of implants placed worldwide is considered, instead of the United States alone.

To compare this with other risks, the estimated risk of developing cancer due to background radiation is 20 in 1 000 000 over a year.²⁷ In light of this comparison alone, the proposed risk of SCC in association with dental implants, if any at all, is far too low to warrant any change in surgical and treatment protocols. For the reported cases of SCC in association with dental implants, there is really no way to establish a cause-and-effect relationship, as it would be quite unfeasible to rule out other confounding factors and unknown etiologic reasons.

CLINICAL RELEVANCE AND CONCLUSION

Some case reports propose that the initial presentation of an SCC in association with a dental implant might mimic peri-implantitis.^{3–5,8} Although such cases are rarely reported, it has been previously recommended that patients at risk for oral cancer, especially those with multiple existing risk factors, who present with failing dental implants should be thoroughly evaluated to rule out the presence of malignancy disguised as peri-implant disease.⁴ Even if we hypothetically assume a cancer risk with dental implant placement, the calculated risk as per the standardized incidence ratio, in the author’s personal opinion, is far too low to warrant mandatory biopsies for every case of peri-implantitis. However, in proven cases of malignancy or a history of cancer, it would be prudent to be vigilant about peri-implantitis versus SCC, as previously recommended.^{4,5}

In conclusion, an unusual case of SCC in relation to a dental implant is presented. An assessment of the biological plausibility of the previously hypothesized carcinogenic mechanisms does not conclusively support the notion that dental implants could be a direct etiologic or contributory agent for cancer formation. Early diagnosis of cancer is crucial for successful rehabilitation. Although patient selection remains an important consideration, dental implants remain a safe treatment modality.

ABBREVIATIONS

SCC: squamous cell carcinoma

SIR: standardized incidence ratio

Ti: titanium

REFERENCES

- Schache A, Thavaraj S, Kalavrezos N. Osseointegrated implants: a potential route for squamous cell carcinoma of the mandible. *Br J Oral Maxillofac Surg*. 2008;46:397–399.
- Block MS, Scheufler E. Squamous cell carcinoma appearing as peri-implant bone loss: a case report. *J Oral Maxillofac Surg*. 2001;59:1349–1352.
- Kwok J, Eyeson J, Thompson I, McGurk M. Dental implants and squamous cell carcinoma in the at risk patient—report of 3 cases. *Br Dent J*. 2008;205:543–545.
- Czerninski R, Kaplan I, Almozni G, Maly A, Regev E. Oral squamous cell carcinoma around dental implants. *Quintessence Int*. 2006;37:707–711.
- Gallego L, Junquera L, Baladrón J, Villarreal P. Oral squamous cell carcinoma associated with symphyseal dental implants: an unusual case report. *J Am Dent Assoc*. 2008;139:1061–1065.
- Eguia del Valle A, Martínez-Conde Llamas R, López Vicente J, Uribarri Etxebarria A, Aguirre Urizar JM. Primary oral squamous cell carcinoma arising around dental osseointegrated implants mimicking peri-implantitis. *Med Oral Patol Oral Cir Bucal*. 2008;13:E489–E491.
- WinterGreen Research. Worldwide nanotechnology dental implant market shares, strategies, and forecasts, 2009 to 2015. http://www.researchandmarkets.com/reportinfo.asp?report_id=941893&t=d&cat_id=. Accessed March 10, 2011.
- Abu El-Naaj I, Trost O, Tagger-Green N, et al. Peri-implantitis or squamous cell carcinoma. *Rev Stomatol Chir Maxillofac*. 2007;108:458–460.
- Clapp C, Wheeler JC, Martof AB, Levine PA. Oral squamous cell carcinoma in association with dental osseointegrated implants. An unusual occurrence. *Arch Otolaryngol Head Neck Surg*. 1996;122:1402–1403.
- Gallego L, Junquera L, Llorente S. Oral carcinoma association with dental implant overdenture trauma. *Dent Traumatol*. 2009;25:e3–e5.
- Gulati A, Puthussery FJ, Downie IP, Flood TR. Squamous cell carcinoma presenting as peri-implantitis: a case report. *Ann Rev Coll Surg Engl*. 2009;91:8–10.
- Moxley JE, Stoelinga PJ, Blijdorp PA. Squamous cell carcinoma associated with a mandibular stable implant. *J Oral Maxillofac Surg*. 1997;55:1020–1022.
- Shaw R, Sutton D, Brown J, Cawood J. Further malignancy in field change adjacent to osseointegrated implants. *Int J Oral Maxillofac Surg*. 2004;33:353–355.
- Verhoeven JW, Cune MS, van Es RJ. An unusual case of implant failure. *Int J Prosthodont*. 2007;20:51–54.
- Vahey JW, Simonian PT, Conrad EU III. Carcinogenicity and metallic implants. *Am J Orthop*. 1995;24:319–324.
- Olmedo DG, Tasat DR, Duffó G, Guglielmotti MB, Cabrini RL. The issue of corrosion in dental implants: a review. *Acta Odontol Latinoam*. 2009;22:3–9.
- Chaturvedi TP. An overview of the corrosion aspect of dental implants. *Indian J Dent Res*. 2009;20:91–98.
- Chang JC, Oshida Y, Gregory RI, Andres CJ, Thomas M, Barco DT. Electrochemical study on microbiology related corrosion of metallic dental materials. *Biomed Mater Eng*. 2003;13:281–295.
- Hallab NJ, Jacob JJ. Biologic effects of implant debris. *Bull NYU Hosp Joint Dis*. 2009;67:182–188.
- Spector M, Shortkoff S, Hsu HP, Lane N, Sledge CB, Thornhill TS. Tissue changes around loose prosthesis: a canine model to investigate the effects of an anti-inflammatory agent. *Clin Orthop* 1990;261:139–145.
- Thornhill TS, Ozuma RM, Shortkoff S, Keller K, Sledge CB, Spector M. Biochemical and histological evaluation of the synovial-like tissue around failed total joint replacement prostheses in human subjects and a canine model. *Biomaterials*. 1990;11:69–72.
- Cochran DL, Hermann JS, Schenk RK, Higginbottom FL, Buser D. Biologic width around titanium implants. A histometric analysis of the implanto-gingival junction around unloaded and loaded nonsubmerged implants in the canine mandible. *J Periodontol*. 1997;68:186–198.
- Galante J, Lemons J, Spector M, Wilson PD, Wright TM. The biologic effects of implant materials. *J Orthop Res*. 1991;9:760–775.
- Gillespie WJ, Frampton CMA, Henderson RJ, Ryan PM. The incidence of cancer following total hip replacement. *J Bone Joint Surg*. 1998;70B:539–542.
- Black J. Metallic ion release and its relationship to oncogenesis. In: Fitzgerald, RH, ed. *The Hip*. St Louis, MO: CV Mosby; 1985:199–213.
- Martin A, Bauer TW, Manley MT, Marks KE. Osteosarcoma at the site of total hip replacement. *J Bone Joint Surg*. 1988;70A:1561–1567.
- Tierney J. Not to worry. *Hippocrates*. 1988; Jan/Feb:29.
- De Ceulaer J, Magremanne M, van Veen A, Scheerlinck J. Squamous cell carcinoma recurrence around dental implants. *J Oral Maxillofac Surg*. 2010;68:2507–2512.
- Meijer GJ, Dieleman FJ, Bergé SJ, Merx MA. Removal of an oral squamous cell carcinoma including parts of osseointegrated implants in the marginal mandibulectomy. A case report. *Oral Maxillofac Surg*. 2010;14:253–256.