

# Zygomatic Implants/Fixture: A Systematic Review

Ashu Sharma, MDS\*

G. R. Rahul, MDS

Patients with moderate to severe atrophy challenge the surgeon to discover alternative ways to use existing bone or resort to augmenting the patient with autogenous or alloplastic bone materials. Many procedures have been suggested for these atrophied maxillae before implant placement, which include Le Fort I maxillary downfracture, onlay bone grafts and maxillary sinus graft procedures. A zygomatic implant can be an effective device for rehabilitation of the severely resorbed maxilla. If zygomatic implants are used, onlay bone grafting or sinus augmentation would likely not be necessary. The purpose of this article is to review the developments that have taken place in zygomatic implant treatment over years, including anatomic information for installing the zygomatic implants, implant placement techniques, stabilization, and prosthodontic procedures.

**Key Words:** *zygomatic bone, zygomatic implants, severely resorbed maxilla, zygomatic fixtures, maxillary sinus*

## INTRODUCTION

Endosseous implants have become a very common mode of treatment for partially and completely edentulous patients, thanks to the process of osseointegration of endosseous implants with the surrounding bone. Unfortunately, restrictions have appeared in the use of oral implants. One of them is the lack of sufficient bone volume, especially in the posterior maxilla. This insufficient bone volume can be due to bone resorption as well as to pneumatization of the sinus or to a combination of both.<sup>1</sup>

According to some clinical reports, the minimal bone height for a standard implant in the posterior region should be at least 10 mm to ensure acceptable success rate.<sup>2</sup> With the introduction of wide implants, 5 and 6 mm in diameter,<sup>3,4</sup> the contact surface between implant and bone is increased and assumes a cortical anchorage with an initial stability in type IV bone even if the bone height is no greater than 6 mm. Implants of wide diameter limit the biomechanical complications in

the treatment of the posterior maxillae. Pterygo-maxillary implants have also been proposed for posterior anchorage in totally edentulous patients.<sup>5</sup>

Many alternative procedures have then been studied to treat atrophic maxilla, such as the use of composite grafts,<sup>6</sup> Le Fort I osteotomy,<sup>7</sup> iliac crest grafts,<sup>8,9</sup> and maxillary sinus grafts.<sup>10</sup> Distraction osteogenesis is a quite new procedure for bone augmentation. However, no publication concerning bone lengthening in the posterior severely resorbed maxilla could be found related to this new procedure.<sup>1</sup>

From experience based on animal research and human experiments, Branemark et al,<sup>11</sup> knowing that the introduction of an implant in the sinus would not necessarily jeopardize sinus health, considered using the zygoma bone as an anchorage for prosthetic rehabilitation in hemimaxillectomy patients as well as for other defects. As these reconstructions<sup>12</sup> were successful and long-term stability of these implants was established, in 1997 Branemark developed a specific implant called the zygomaticus fixture to provide fixed solutions even when the conditions for implant insertion were poor in the posterior maxilla. This new technologic development offers alternatives to bone grafting or sinus-lifting procedures, which involve rather invasive surgery.<sup>1</sup>

Department of Prosthodontics, Bangalore Institute of Dental Sciences and Research Center, Bangalore, Karnataka, India.

\* Corresponding author: drashu\_sharma@yahoo.com

DOI: 10.1563/AAID-JOI-D-11-00055

## SEARCH STRATEGY

A PubMed search of English literature was conducted up to January 2010 using the terms: zygoma, severely resorbed maxilla, zygomatic implants, remote implant anchorage, and zygomatic fixtures. Additionally, the bibliographies of 7 previous reviews, their cross references, as well as articles published in *Periodontology 2000*, *The International Journal of Oral & Maxillofacial Implants*, *The International Journal of Prosthodontics*, *Journal of Periodontology*, *Journal of Oral and Maxillofacial Surgery*, *Journal of Dental Research*, *The Journal of Prosthetic Dentistry*, and *Clinical Implant Dentistry and Related Research* were manually searched.

## ZYGOMATIC IMPLANT DESIGN

In their study, Malevez et al<sup>1</sup> described zygomatic implants as self-tapping screws in commercially pure titanium with a well-defined machined surface. They are available in 8 different lengths, ranging from 30 to 52.5 mm. They present a unique 45° angulated head to compensate for the angulation between the zygoma and the maxilla. The portion that engages the zygoma, the apical two thirds, has a diameter of 4.0 mm,<sup>1,13</sup> and the portion that engages the residual maxillary alveolar process, alveolar one third, has a diameter of 4.5 mm<sup>1</sup> to 5 mm.<sup>13</sup> At the maxillary level, the angulated implant platform extremity offers the possibility to screw any kind of abutment from the Branemark system. However, for the newest generation of abutments, a separate, slightly shorter abutment screw must be utilized for the construction of conventional screwed prosthesis (Figure 1).<sup>1</sup>

Bedrossian et al<sup>13</sup> in their study placed a total of 44 zygomatic implants and 80 premaxillary implants in 22 patients. Zygomatic implants were placed in the second premolar area, traversing the maxillary sinus, and fixated into the body of the zygomatic bone. During placement of premaxillary implants, a minimum of 2 premaxillary implants were placed in the canine position, out of ideal total 4 premaxillary implants (canine and the central incisor positions), which allows for the fabrication of hybrid prostheses.<sup>13</sup>

## Contraindications

General contraindications are the same as for conventional implants and sinus lift procedures, such as local infection in sinus, Caldwell Luc operations, Underwood septa, severe sinus floor convolutions, and narrow sinuses (Table).

### Treatment concept recommendations

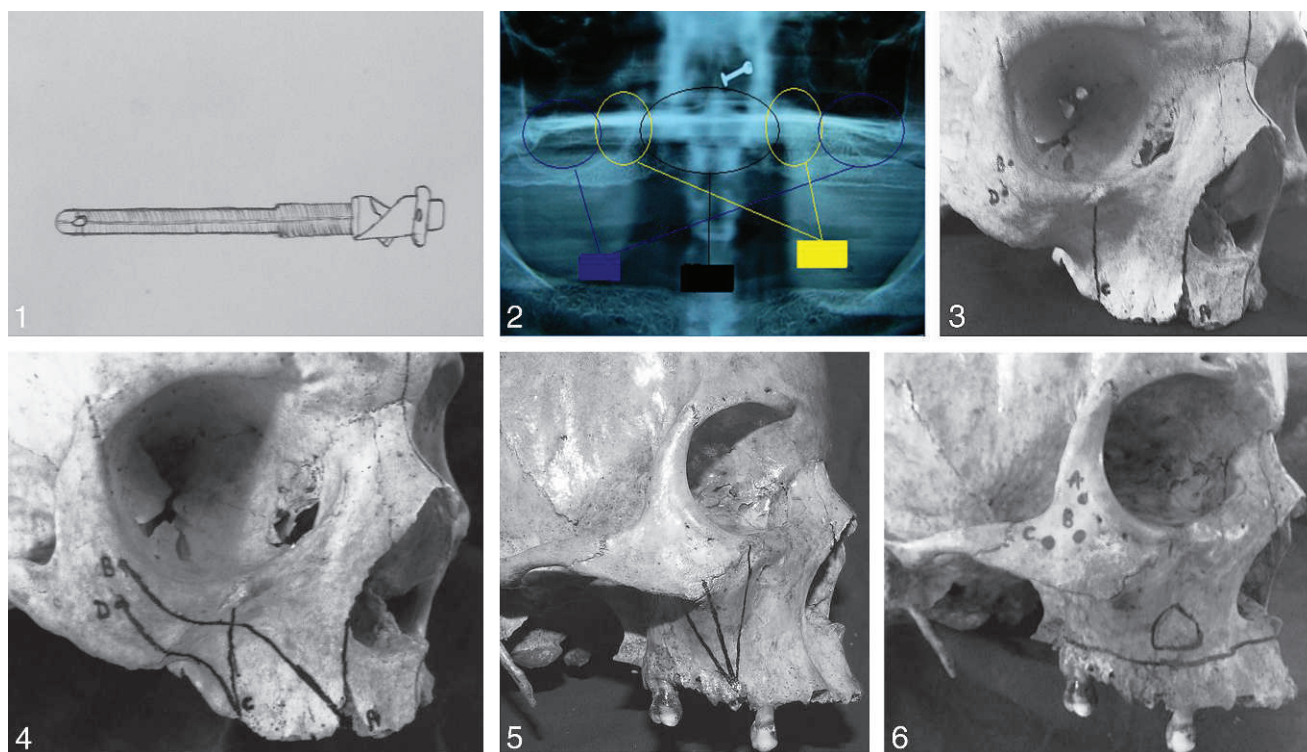
Bedrossian's surgical approaches<sup>14</sup> based on the zones of the maxilla (Figure 2) are as follows:

- traditional (axial) for zones I, II, and III;
- All-on-Four for zones I and II;
- zygomatic implants for zone I only; and
- 4 zygomatic implants for insufficient bone.

### Presurgical evaluation

Bothur et al<sup>15</sup> published a technical note on a modified technique for zygomatic implant placement in 2003 in which they said that preoperative considerations should involve shape of the face, degree of resorption, sinus status, maxillomandibular jaw relationship, and patient expectations. A narrow face will be unfavorable as far as intraoperative access and implant inclination are concerned. An edentulous mandible will facilitate access. An alveolar crest that is very thin but vertically sufficient tends to encourage implant entrance palatally, and thus buccal onlay bone grafting might be considered as an alternative treatment approach.<sup>15</sup>

Bedrossian et al<sup>13</sup> in their study on zygomatic and premaxillary implants used panoramic radiographs, which generally depict the size and configuration of the maxillary sinuses, the height of the residual ridge, and the position of the nasal floor. The body of the zygoma can usually be visualized. Although computerized tomography (CT) scans may be useful, the authors have not routinely used CT scans in the preoperative evaluation of this group of patients. If the patient's denture is well fitting, it is duplicated and adapted to be used as the surgical guide.<sup>13</sup> Oral pantography can give distorted information; therefore, the choice of examination should be CT scan. CT scan also gives the opportunity to visualize the health of the maxilla and the sinus. The implants can be placed via virtual images and with the help of implant planning software.



**FIGURES 1–6.** **FIGURE 1.** Diagrammatic representation of zygomatic implant with a hole for the abutment screw (machined surface). It has been suggested that the presence of this hole could lead to oral-sinus communication and an increased risk of sinusitis. **FIGURE 2.** Oral pantography showing zones of the maxilla. Blue indicates zone 3; black, zone 1; yellow, zone 2. **FIGURE 3.** Frontal view. **FIGURE 4.** Lateral view. **FIGURE 5.** Photograph represents the proper trajectory for the zygomatic implant. **FIGURE 6.** Dry skull showing multiple implant positions A,B,C in zygomatic bone and window in lateral sinus wall.

#### ANATOMIC CONSIDERATIONS/MEASUREMENTS FOR ZYGOMATIC IMPLANT PLACEMENT

Uchida et al<sup>20</sup> said that a zygoma bone can be compared to a pyramid, offering an interesting anatomy for the insertion of implants. Based upon various studies on zygomatic bone by Gosain et al,<sup>21</sup> Champy et al,<sup>22</sup> Melson et al,<sup>23</sup> Parel S et al,<sup>12</sup> and Van Steenberghe,<sup>24</sup> the following conclusions can be made: (1) zygoma shows regular trabeculae and compact bone with an osseous density of up to 98%, (2) zygomatic bone can be used for the insertion of miniplates in maxillofacial fractures, (3) zygoma can be used for fixed anchorage to allow dental arch retractions and to anchor a screwed prosthesis, and (4) surgical drilling guides should be encouraged for zygomatic implant placement. Based on the results of the above-mentioned studies, it was clear that zygomatic implants developed by Branemark are seen as an alternative for patients presenting severe atrophy of the maxilla.<sup>25</sup> With a length of 35 to 52.5 mm, this implant must be inserted from the palatal aspect of

the resorbed maxilla in the region of the second premolar, through the maxillary sinus into the compact bone of the zygoma, as mentioned by Bedrossian et al<sup>13</sup> and Rossi et al<sup>25</sup> in their respective studies.

Modifications to the technique originally proposed have also been presented in the literature, such as the insertion of multiple zygomatic implants by Bedrossian et al,<sup>13</sup> or 4 implants, 2 on either side. In the 4-implant protocol, 2 zygomatic implants are inserted using the original technique and 2 additional zygomatic implants are inserted emerging in the region of the canines or lateral incisors. This treatment alternative is based on the immediate loading concept.<sup>25</sup>

A study was done in 2008 by Rossi et al<sup>25</sup> to obtain anatomic information by measuring the angular and linear dimensions of the maxilla and the zygoma in dry skulls in order to guarantee the safe insertion of 4 zygomatic implants. The following measurement points and lines were defined:

TABLE  
 Indications, advantages, and disadvantages of zygomatic implants

Indications <sup>1</sup>	Advantages <sup>13</sup>	Disadvantages <sup>15</sup>
Severe resorption of maxilla.	When placed in conjunction with premaxillary implants, they facilitate the surgical rehabilitation of patients presenting with severe maxillary resorption in the office setting.	More invasive procedure compared to sinus lift and requires more experienced operator.
Free-end situations in maxilla with insufficient bone height.	Existing dentures can be immediately utilized, unlike in cases of sinus lift grafting procedures.	There is risk of oro-antral fistulae formation with the placement of these implants.
Total edentulism together with reduced bone height.	Lack of need of hospitalization and bone grafting.	Leads to initial phonetic problems and maxillary sinusitis.
Pneumatization of maxillary sinus.	Decreased cost of treatment.	More technique sensitive and difficult to place in patients with limited mouth opening.
In cases with very severe resorption of anterior maxilla in totally edentulous patients, these are used along with grafts to reduce the dimensions of bone graft.	Use of remote bone anchorage, either through the residual maxilla or in defect areas helps in reducing cantilever stress and enhancing the cross-arch effect. <sup>12</sup>	These implants project in divergent angles, which complicate impression and prosthesis construction procedures. <sup>12</sup>
	Zygomatic implants use 4 cortical portions compared to 1 or 2 cortical portions with conventional implants in the maxilla (multicortex stabilization), which defeats the unfavorable microarchitecture of zygoma bone. <sup>16</sup>	Zygomatic bone has unfavorable microarchitecture for implant placement.
	Recently, implant placement simulation software SIM/Plant (Materialise, Leuven, Belgium) has been used to assess a pathologically altered residual ridge for possible implant therapy. With SIM there were fewer articulation difficulties caused by the palatal location of an implant platform than. <sup>17</sup>	There is possibility of an impediment in articulation and difficulty in cleaning related to the palatal location of the implant platform. <sup>17</sup>
	Sinus reactions to zygomatic implants seem to lead to the adaptation and maintenance of normal physiology. <sup>18</sup>	
	Eliminated donor site morbidity and reduced treatment time favors zygoma protocol. <sup>19</sup>	
	Zygoma fixtures reduce preoperative risk, which suggests that older patients and patients with more severe general health problems can be rehabilitated compared with traditional methods of bone grafts. <sup>19</sup>	
	A success rate of 65% to 75% seen for implants placed solely in the zygomatic bone after ablative tumor surgery, which increases more when placed in atrophic maxilla. <sup>16</sup>	
	The engagement of maximum possible cortical bone has been advocated as a decisive factor for the success of dental implants. <sup>16</sup>	

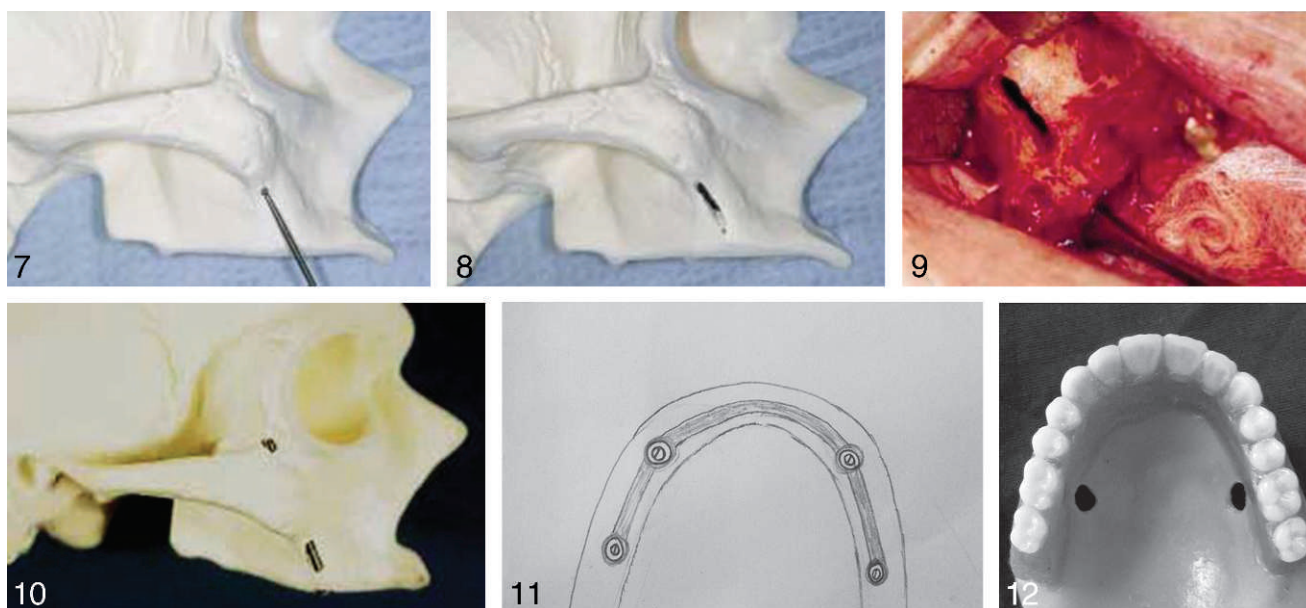
Downloaded from <http://meridian.allenpress.com/joi/article-pdf/39/2/215/2039853/aaid-foi-d-11-00055.pdf> by guest on 01 October 2023

1. Point A: the lowermost point of the alveolar crest, taking a line from the lateral margin of the nasal incisures (the fossa between the zygomatic bone and the lateral and medial surface of the frontal process of the zygomatic bone) shifted 5 mm to the palatal side, corresponding to the starting point of the perforation for an additional

zygomatic implant in the all on 4 zygoma technique;

2. Point B: the lowermost point on the lateral margin of the orbital socket, corresponding approximately to the end point of an additional zygomatic implant in the all on 4 zygoma technique;





**FIGURES 7–12.** **FIGURE 7.** The end of the zygomatic implant depth gauge is inserted into a bur hole at the superior aspect of the height of contour of the zygomatic buttress. The angle of approach of the implant twist drill can then be simulated with the depth gauge. **FIGURE 8.** Sinus slot technique on a dry skull. **FIGURE 9.** Sinus slot technique in an actual patient. **FIGURE 10.** Operative sight preparation is completed with the implant placed using the sinus slot technique. **FIGURE 11.** Diagrammatic representation of cast rigid bar connecting premaxillary and zygomatic implants. **FIGURE 12.** Photograph showing denture relieved to accommodate the implants.

3. Point C: the lowermost point of the alveolar crest, taking a line at a tangent to the lateral margin of the infraorbital foramen shifted 5 mm to the palatal side, corresponding to the starting point of the perforation for a conventional zygomatic implant;
4. Point D: located one third of the distance between the lowermost point of the lateral margin of the orbital socket and the lowermost point of the zygomatico-maxillary suture, corresponding approximately to the end-point of a conventional zygomatic implant; and
5. Line Z: line passing through the infraorbital foramen.

The linear measurements were recorded in millimeters, and the angular measurements in degrees.

- Linear measurements: The length of line AB refers to the length of an additional zygomatic implant in the all on 4 zygoma technique. Length of line CD refers to the length of a conventional zygomatic implant.
- Angular measurements: Angle X is the angle between lines AB and Z, corresponding to the angle of insertion of an additional zygomatic

implant in the all on 4 zygoma technique. Angle P is the angle between lines CD and Z, corresponding to the angle of insertion of a conventional zygomatic implant (Figures 3 and 4).<sup>25</sup>

#### ZYGOMATIC IMPLANT PLACEMENT

Different authors have mentioned different techniques for zygomatic implant placement. However, the original and most commonly used technique is the conventional technique. There are 2 other modified techniques that have been used, which are the modified zygomatic implant placement technique and the extra-sinus zygomatic implant placement technique.

#### *Conventional zygomatic implant placement technique*

Although the operation can be carried out under local anesthesia, for the patient's comfort it can be carried out under total anesthesia or neuroleptic deconnection as mentioned by Higuchi<sup>26</sup> in his paper on indications and clinical applications of zygomatic fixtures. According to Malevez et al,<sup>1</sup> after a palatal 45° incision of the soft tissue along

the entire maxillary crest, the soft tissue is completely reflected from the maxillary crest to the zygomatic buttress, and the suborbital nerve is identified. A window is then made by drilling (fissure bur<sup>13</sup>) at the upper limit between the zygoma and the sinus to determine the orientation of the zygoma and to reflect the Schneiderian membrane. At this point, direct visualization of the path of the implant from the premolar area to the base of the zygoma is possible. This window will also be helpful during the surgical procedure for cooling the drills to avoid overheating.<sup>1</sup>

The proper axis is a path that extends from the premolar region through the maxillary sinus, entering the midportion of the zygomatic body. If the entry point in the zygomatic body is anterior to this path, potential for penetration into the orbit exists. However, if the axis is posterior to this path, the implant may be at risk of entering the infratemporal fossa, leading to soft tissue embedment and a subsequent lack of osseointegration (Figure 5); an increased potential for unexpected hemorrhage also exists.<sup>14</sup>

Different drills are used with increasing diameters, ending with the insertion at low speed of the self-tapping zygomatic implant. The length of this is carefully chosen by means of a special gauge.<sup>1</sup> To begin the osteotomy, a round bur is used, followed by twist drills. A pilot drill is used to allow stabilization of the twist drill, which completes the zygoma osteotomy. The alveolar portion of the implant osteotomy is completed, which prepares the crestal bone to its final diameter. As recommended by Bedrossian et al<sup>13</sup> prior to implant placement and at all times during preparation of the osteotomy, the entire surgical path of the drills is visualized. The zygomatic implant has an angulated head. This 45° angulation allows for the platform of the implant to be in the same plane as the conventional implants in the premaxilla. To facilitate implant placement, premounted implant carriers allow for easy handling of the implant with a straight handpiece. The implant is placed into the osteotomy with copious irrigation. Once the apical portion of the implant engages 1 to 2 mm of the dense zygomatic bone, the handpiece stalls. Then, with the manual driver, "the onion," the remaining portion of the implant, is seated. To ensure proper orientation of the angulated implant head, a screwdriver is placed onto the implant carrier screw

head. The long axis of the screwdriver shaft must be at right angles to the edentulous ridge to ensure proper orientation of the implant platform.<sup>13</sup> The apical portion of the implant is embedded in approximately 8 to 10 mm of bone in the zygomatic bone.

### **Modified zygomatic implant placement technique**

The original concept featured a single implant in the zygoma bilaterally, combined with at least 2 conventional implants in the anterior maxilla. Sometimes, bone grafting is required along with the conventional technique as mentioned by Vrielinck et al.<sup>27</sup> In an effort to provide a graft-free procedure for patients with atrophic maxillae and severe bone resorption in the anterior maxilla, a modified technique utilizing multiple implants anchored in the zygoma is presented by Kahnberg et al<sup>28</sup> and Keller et al<sup>29</sup> in their respective studies. Three possible positions for implant location on one side have been described in this technique (Figure 6), but the placement of 2 zygomatic implants bilaterally is sufficient for reconstruction as suggested by Parel et al.<sup>12</sup>

After incision and retraction of the overlying soft tissues, a window is made in the lateral sinus wall along the infrazygomatic crest and the alveolar crest. Sinus mucosa is removed from the area where the implants will pass, ensuring a cleared entrance at the crestal site as well as the zygomatic site. It is essential to use a kit with extended drills for better access. These drills are 50 mm longer than the standard drills, making it possible to maneuver the handpiece outside the mouth. Placement of implants in 3 possible locations is described below:

1. The most posterior implant is placed first. The palatal entrance is made in the second molar region, with the implant running slightly posterior to the buttress and perforating the zygoma from the medial side. The entrance in the zygoma should be low and posterior. It is important to use sharp twist drills, otherwise the drill will bend and slide along the medial side of the zygoma, or it may cause a fracture of the arch.
2. The second implant is placed in the premolar region, running along the infrazygomatic crest inside the sinus and perforating the middle aspect of the zygoma.

- The third implant is placed in the lateral incisor region, running along the lateral nasal wall initially and perforating the zygoma high, close to the lateral orbital rim. Removal of any interfering crestal bone is suggested.

### ***Sinus slot technique for simplification and improved orientation of zygomatic implants***

The sinus slot technique described by Stella and Warner<sup>30</sup> makes sinus window formation, as described in conventional placement of zygomatic implants, unnecessary. A crestal incision is made extending from one maxillary tuberosity to the contralateral tuberosity. With a periosteal elevator, a traditional LeFort I exposure is accomplished, extending around the base of the piriform rim, up to the inferior aspect of the infraorbital nerves, and around the inferior one half of the body of the zygoma bilaterally. The palatal mucosa is reflected only to expose the crest of the ridge.

A fissure bur is used to make a hole through the bone and into the sinus cavity at the superior extent of the contour of the zygomatic buttress. The zygomaticus implant depth gauge, which has a small "hook" at the end, is placed in the bur hole and positioned to simulate the angle of approach of the implant twist drill. A second bur hole is made on this line 5 mm above the crest of the ridge. A slot is then made that connects the 2 bur holes. The superior aspect of the slot extends to the base of the zygoma, where solid zygomatic bone is encountered. The inferior extent of the slot approximates the floor of the maxillary sinus. This slot is made directly through the buttress wall without concern of compromise to the sinus membrane. In extremely atrophic maxillary ridges, the authors recommend leaving approximately 5 mm of intact lateral maxillary wall at the inferior aspect of the slot. The slot results in a smaller anastomy that will serve to orient the twist drills for implant placement. With a round bur, a small purchase point is marked at the ideal location on the crest of the maxillary ridge, which lines up with the sinus slot. This places the implant abutment in the first molar region.

The zygomatic twist drill is used to initiate the first preparation. The tip of the drill is placed in the purchase point with a straight handpiece, directly over the crest of the ridge, and the drill is directed

such that it extends directly through the sinus slot that was previously fabricated. The drill is advanced superiorly toward the junction of the lateral orbital rim and zygomatic arch. In the same fashion, the larger pilot drill and following twist drills are also used, being directed through the center of the sinus slot (Figures 7 through 10). The depth of the preparation is reconfirmed with the zygomaticus implant depth gauge, and the appropriate length implant is chosen for placement.<sup>30</sup>

### ***Extra-sinus zygomatic implant placement technique***

The conventional surgical protocol for zygomatic fixtures prescribes an intrasinus approach ideally maintaining the sinus membrane intact and the implant body inside the sinus while gaining access to the zygomatic bone. However, in the presence of a pronounced buccal concavity, the implant head has to be placed far from the alveolar crest in a palatal direction, which results in a bulky bridge construction. In 2010, Aparicio et al<sup>31</sup> published their preliminary experiences with zygomatic implant placement in patients with pronounced buccal concavities in edentulous maxilla with a new extra-sinus technique in order to have the implant head emerging at or near the top of the alveolar crest. No implants were lost during the study period. No pain, discomfort, or complications related to the extra-sinus path of the zygomatic implants were recorded after the initial healing period and up to the 36-month check-up.

The zygomatic implant site is planned by striving to place the implant head at or near the top of the crest, usually in the second premolar/first molar regions. Moreover, the implant body should preferably engage the lateral bone wall of the maxillary sinus, while entering the zygomatic bone.<sup>32</sup> The implant site is prepared, drilling from the palatal crest pointing the zygomatic arch without making a previous opening to the maxillary sinus nor taking into account the sinus membrane integrity, and following the standard drilling steps for zygomatic implants as described.<sup>32</sup> As a result, the zygoma implant enters the crestal bone or sinus cavity from the palate crest of the premolar/molar area, then comes out through the lateral maxillary sinus wall close to the sinus ground/maxillary basal bone. Then, the implant goes in an extra-sinus path and sometimes engages the lateral sinus wall. Finally,

the implant head penetrates the zygoma arch, and it appears in the superior part of the zygomatic arch. Later, additional conventional implants are placed.<sup>31</sup>

### IMMEDIATE STABILIZATION OF ZYGOMATIC IMPLANTS AT STAGE II

#### *Rationale*

It is assumed that the only stability of the zygomatic implant is derived from the zygomatic bone. The remainder of the implant and the prosthetic components constitute a considerable cantilever. However, because these implants were never intended to be free-standing pillars, immediate, rigid, cross arch stabilization is recommended at stage II to prevent micromovement, and thus microfractures around the osseointegrated structures. Achieving such stabilization requires that the zygomatic implants be splinted to the other implants by a provisional rigid bar. Brunski<sup>34,35</sup> and Meredith<sup>36</sup> suggested in their studies that this type of cross arch stabilization (splinting) appears to effectively reduce mechanical stress on the implants by reducing their movement.

Fabricating a passive bar to connect the implants at phase II surgery may require 1 to 2 days. With the adhesive abutment cylinder luting technique, a rigid framework can be delivered within 1 hour of uncovering the implants. This approach saves considerable time over conventional techniques and allows for the restoration of severely resorbed maxillae in an efficient and routine manner. The technique also eliminates the necessity for a technician to be available on-site for the procedure.

#### *Technique*

The steps of the stabilization technique are as follows:

1. Make an implant-level impression by using a disposable stock tray.
2. Fabricate a soft tissue cast from the implant level impression.
3. Select standard abutments, and place them onto the lab analogs of the soft tissue cast.
4. Transfer previously fabricated diagnostic wax setup for desired prosthesis to soft tissue cast.

5. Guide the design of the metal substructure with a labial occlusal silicon matrix fabricated from the diagnostic setup. Connect prefabricated machined titanium cylinders to the implant laboratory analogs on the mounted cast. Place shim spacer and burnout plastic over shims.
6. Cast the substructure in 1 piece and finish it. Abrade the titanium cylinders with air particles and the inner surfaces of the substructure with 250- $\mu$ m aluminum silicoated oxide; cover them with an activated adhesive silane coupling agent and seal them with light-polymerized opaque (Figure 11). This intermediate layer will promote a gap-free resin-to-metal interface.<sup>37,38</sup>
7. Six months after implant installation, surgeon sees the patient for stage II.
8. Lute the cylinders individually to the framework. Clean the silicoated interface of the framework and each cylinder with acetone. Place each cylinder onto the standard abutment. Apply a bonding agent intraorally to the cylinder and extraorally to the framework. With the remainder of the cylinders loosely placed in their respective positions, guide the framework onto the connected cylinder and into its final position.
9. Place digital pressure on the framework, and light polymerize the composite for 2 minutes. This will rigidly connect the framework to the connected cylinder. After this time, loosen the connected cylinder by unscrewing its connecting screw.
10. Place the next cylinder intraorally. Place the framework (now with 1 rigidly connected cylinder) over this cylinder and repeat steps 9 and 10. Repeat this procedure until all cylinders are connected to the framework.
11. Place the bar into the abutments and tighten the screws. All cylinders now are passively connected to the framework.
12. Hollow out the existing denture so that it passively fits over the connected bar. Mix a soft tissue conditioning material to a doughy stage, place it in the denture, and position the denture.

#### PROSTHODONTIC PROCEDURES

Hirsch et al<sup>18</sup> in their 1-year follow-up study on treatment of 76 patients with zygomatic fixtures



suggests that common prosthetic guidelines should be followed, which dictate that the occlusal design should minimize torque and bending moments, with adequate access at the mucosal interface to fulfill hygienic demands and facilitate home care maintenance. The prosthetic treatment plan should aim for an optimal balance between functional, esthetic, and hygienic requirements. Following initial healing and suture removal, the preoperative denture should be relined as necessary during the interval between stage 1 and stage 2 surgery, in accordance with standard protocol for implant treatment of the edentulous jaw. Following abutment connection, a transfer registration should be taken, if indicated, to fabricate a rigid bar system designed to prevent adverse forces on individual implants. The denture should be generously relieved around the abutment areas and relined with a soft tissue conditioner ensuring minimization of transverse and torque-like forces (Figure 12).<sup>19</sup>

Considering the biomechanical aspects of the prosthetic reconstructions on zygomatic implants as mentioned by Malevez et al,<sup>1</sup> it is well known that when masticatory load is applied to a rigid semicircular arch connecting anterior implants and zygomatic implants, the masticatory load in the posterior region is transferred to the bony support situated in the zygoma. The design of the final prosthetic bridge construction should be rigid to provide stabilization. The fit of the bridge is to be absolutely passive to prevent load transfer to individual implants, and the final reconstruction should be completed as soon as possible. After prosthetic insertion, the patient is scheduled for review after 1 and 2 weeks, and is followed on a regular basis thereafter.<sup>19</sup>

### CONCLUSION

The evolution of osseointegrated implant concepts, as they apply to rehabilitation of maxillary defects, has been significantly enhanced with the use of implant support gained from osseous sites in remote locations like zygomatic bone.<sup>12</sup> The zygomatic implant—the zygomaticus fixture—appears to be a promising development in implant technology. It offers an interesting alternative solution to heavy bone grafting in the severely resorbed posterior maxilla. It has been in use for more than 10 years and gives a predictable outcome in the

rehabilitation of totally, as well as partially, edentulous patients.<sup>1</sup>

The functional and esthetic results are considered excellent, considering the number of difficulties involved in these rehabilitations, converting, in fact, oral invalids into well-functioning persons. The problems reported so far that are related to the zygoma procedure are not severe and are within the magnitude of what is experienced with other methods.<sup>19</sup> Although continuing documentation of this concept with multicenter experience is still important in determining the specific applications and limitations of the zygoma implant, experience to-date supports its effectiveness in the rehabilitation of this complex and challenging patient population.<sup>12</sup> More published reports are needed and more follow-up has to be provided to assess its final goal and predictability.<sup>1</sup>

### ABBREVIATION

CT: computerized tomography

### REFERENCES

1. Malevez C, Daelemans P, Adriaenssens P, Durdu F. Use of zygomatic implants to deal with resorbed posterior maxillae. *Periodontol* 2000; 2003;33:82–89.
2. Ten Bruggenkate CM, Van den Bergh JP. Maxillary sinus floor elevation: a valuable preprosthetic procedure. *Periodontol* 2000; 1998;17:176–182.
3. English C, Bahat O, Langer B, Sheets CG. What are the clinical limitations of wide-diameter (4 mm or greater) root-form endosseous implants? *Int J Oral Maxillofac Implants*. 2000;15:293–296.
4. Langer B, Langer L, Herrmann I, Jorneus L. The wide fixture: a solution for special bone situations and rescue for the compromised implant. Part I. *Int J Oral Maxillofac Implants*. 1993; 8:400–408.
5. Balshi TJ, Wolfinger GJ, Balshi SF II. Analysis of 356 pterygomaxillary implants in edentulous arches for fixed prosthesis anchorage. *Int J Oral Maxillofac Implants*. 1999;14:398–406.
6. Breine U, Branemark PI. Reconstruction of alveolar jawbone. An experimental and clinical study of immediate and preformed autologous bone grafts in combination with osseointegrated implants. *Scand J Plast Reconstr Surg*. 1980;14:23–48.
7. Isaksson S, Ekfeldt A, Alberius P, Blomqvist JE. Early results from reconstruction of severely atrophic (class VI) maxillas by immediate endosseous implants in conjunction with bone grafting and Le Fort I osteotomy. *Int J Oral Maxillofac Surg*. 1993;22:144–148.
8. Adell R, Lekholm U, Gröndahl K, Branemark PI, Lindstrom L, Jacobsson M. Reconstruction of severely resorbed edentulous maxillae using osseointegrated fixtures in immediate autogenous grafts. *Int J Oral Maxillofac Implants*. 1990;5:233–246.
9. Isaksson S, Alberius P. Maxillary alveolar ridge augmentation with onlay bone grafts and immediate endosseous implants. *J Craniomaxillofac Surg*. 1992;20:2–7.

10. Boyne PJ, James RA. Grafting of the maxillary sinus floor with autogenous marrow and bone. *J Oral Surg.* 1980;38:613–616.
11. Branemark PI, Adell R, Albrektsson T, Lekholm U, Lindström J, Rockler B. An experimental and clinical study of osseointegrated implants penetrating the nasal cavity and maxillary sinus. *J Oral Maxillofac Surg.* 1984;42:497–505.
12. Parel S, Branemark PI, Ohnell LO, Svensson B. Remote implant anchorage for the rehabilitation of maxillary defects. *J Prosthet Dent.* 2001;86:377–381.
13. Bedrossian E, Stumpel L III, Beckely ML, Indresano T. The zygomatic implant: preliminary data on treatment of severely resorbed maxillae. A clinical report. *Int J Oral Maxillofac Implants.* 2002;17:861–865.
14. Bedrossian E. Rehabilitation of the edentulous maxilla with the zygoma concept: a 7-year prospective study. *Int J Oral Maxillofac Implants.* 2010;25:1213–1221.
15. Bothur S, Jonsson G, Sandahl L. Modified technique using multiple zygomatic implants in reconstruction of the atrophic maxilla: a technical note. *Int J Oral Maxillofac Implants.* 2003;18:902–904.
16. Nkenke E, Hahn M, Lell M, et al. Anatomic site evaluation of the zygomatic bone for dental implant placement. *Clin Oral Implants Res.* 2003;14:72–79.
17. Nakai H, Okazaki Y, Ueda M. Clinical application of zygomatic implants for rehabilitation of the severely resorbed maxilla: a clinical report. *Int J Oral Maxillofac Implants.* 2003;18:566–570.
18. Davó R, Malevez C, López-Orellana C, Pastor-Bevia F, Rojas J. Sinus reactions to immediately loaded zygomatic implants: a clinical and radiological study. *Eur J Oral Implantol.* 2008;1:53–60.
19. Hirsch JM, Ohnell LO, Henry PJ, et al. A clinical evaluation of the zygoma fixture: one year of follow-up at 16 clinics. *J Oral Maxillofac Surg.* 2004;62:22–29.
20. Uchida Y, Goto M, Katsuki T, Akiyoshi T. Measurement of the maxilla and zygoma as an aid in installing zygomatic implants. *J Oral Maxillofac Surg.* 2001;59:1193–1198.
21. Gosain AK, Song L, Capel CC, Corrao MA, Lim TH. Biomechanical and histologic alteration of facial recipient bone after reconstruction with autogenous bone grafts and alloplastic implants: a 1-year study. *Plast Reconstr Surg.* 1998;101:1561–1571.
22. Champy M, Lodde JP, Kahn JL, Kielwasser P. Attempt at systematization in the treatment of isolated fractures of the zygomatic bone: techniques and results. *J Otolaryngol.* 1986;15:39–43.
23. Melsen B, Petersen JK, Costa A. Zygoma ligatures: an alternative form of maxillary anchorage. *J Clin Orthod.* 1998;32:154–158.
24. Van Steenberghe D, Malevez C, Van Cleynenbreugel J, et al. Accuracy of drilling guides for the transfer from 3-D CT based planning to placement of zygomatic implants in human cadavers. *Clin Oral Implants Res.* 2003;14:131–136.
25. Rossi M, Duarte LR, Mendonça R, Fernandes A. Anatomical bases for the insertion of zygomatic implants. *Clin Implant Dent Relat Res.* 2008;10:271–275.
26. Higuchi KW. The zygomaticus fixture: an alternative approach for implant anchorage in the posterior maxilla. *Ann R Australas Coll Dent Surg.* 2000;15:28–33.
27. Vrielinck L, Politis C, Schepers S, Pavwels M, Naert I. Image-based planning and clinical validation of zygoma and pterygoid implant placement in patients with severe bone atrophy using customized drill guides. Preliminary results from a prospective clinical follow-up study. *Int J Oral Maxillofac Surg.* 2003;32:7–14.
28. Kahnberg KE, Nilsson P, Rasmusson L. Le Fort I osteotomy with interpositional bone grafts and implants for rehabilitation of the severely resorbed maxilla: a 2-stage procedure. *Int J Oral Maxillofac Implants.* 1999;14:571–678.
29. Keller EE, Tolman DE, Eckert S. Surgical-prosthetic reconstruction of advanced maxillary bone compromise with autogenous onlay block bone grafts and osseointegrated endosseous implants: a 12-year study of 32 consecutive patients. *Int J Oral Maxillofac Implants.* 1999;14:197–209.
30. Stella JP, Warner MR. Sinus slot technique for simplification and improved orientation of zygomaticus dental implants: a technical note. *Int J Oral Maxillofac Implants.* 2000;15:889–893.
31. Aparicio C, Ouazzani W, Aparicio A, et al. Extrasinus zygomatic implants: three year experience from a new surgical approach for patients with pronounced buccal concavities in the edentulous maxilla. *Clin Implant Dent Relat Res.* 2010;12:55–61.
32. Aparicio C, Ouazzani W, Garcia R, Arevalo X, Muela R, Fortes V. A prospective clinical study on titanium implants in the zygomatic arch for prosthetic rehabilitation of the atrophic edentulous maxilla with a follow-up of 6 months to 5 years. *Clin Implant Dent Relat Res.* 2006;8:114–122.
33. Bedrossian E, Stumpel LJ III. Immediate stabilization at stage II of zygomatic implants: rationale and technique. *J Prosthet Dent.* 2001;86:10–14.
34. Brunski JB. Biomechanics of oral implants: future research directions. *J Dent Educ.* 1988;52:775–787.
35. Brunski JB. Biomaterials and biomechanics in dental implant design. *Int J Oral Maxillofac Implants.* 1988;3:85–97.
36. Meredith N. Assessment of implant stability as a prognostic determinant. *Int J Prosthodont.* 1998;11:491–501.
37. Sella GC. Direct assembly framework for osseointegrated implant prosthesis. *J Prosthet Dent.* 1989;62:662–668.
38. Laufer BZ, Nicholls JI, Townsend JD. SiO<sub>2</sub>-C-coating: a composite-to-metal bonding mechanism. *J Prosthet Dent.* 1988;60:320–327.