

# Esthetic Evaluation of Single-Tooth Morse Taper Connection Implants Placed in Fresh Extraction Sockets or Healed Sites

Francesco G. Mangano, DDS<sup>1\*</sup>

Carlo Mangano, MD, DDS<sup>2</sup>

Massimiliano Ricci, DDS<sup>3</sup>

Rachel L. Sammons, PhD<sup>4</sup>

Jamil A. Shibli, DDS, MS, PhD<sup>5</sup>

Adriano Piattelli, MD, DDS<sup>6</sup>

The aim of this study was to compare the esthetic outcome of single implants placed in fresh extraction sockets with those placed in fully healed sites of the anterior maxilla. This retrospective study was based on data from patients treated with single-tooth Morse taper connection implants placed in fresh extraction sockets and in fully healed sites of the anterior maxilla. Only single implant treatments were considered with both neighboring teeth present. Additional prerequisites for immediate implant treatment were intact socket walls and a thick gingival biotype. The esthetic outcome was objectively rated using the pink esthetic/white esthetic score (PES/WES). The Mann-Whitney *U* test was used to compare the PES and the WES between the 2 groups. Twenty-two patients received an immediate implant, and 18 patients had conventional implant surgery. The mean follow-up was 31.09 months (SD 5.57; range 24–46) and 34.44 months (SD 7.10; range 24–48) for immediately and conventionally inserted implants, respectively. No implants were lost. All implants fulfilled the success criteria. The mean PES/WES was 14.50 (SD 2.52; range 9–19) and 15.61 (SD 3.20; range 8–20) for immediately and conventionally placed implants, respectively. Immediate implants had a mean PES of 7.45 (SD 1.62; range 4–10) and a mean WES of 7.04 (SD 1.29; range 5–10). Conventional implants had a mean PES of 7.83 (SD 1.58; range 4–10) and a mean WES of 7.77 (SD 1.66; range 4–10). The difference between the 2 groups was not significant. Immediate and conventional single implant treatment yielded comparable esthetic outcomes.

**Key Words:** *immediate implant placement, esthetics, pink esthetic/white esthetic score (PES/WES), Morse taper connection implants*

## INTRODUCTION

Immediate implant placement is defined as placement of a dental implant at the time of tooth extraction into the extraction socket. Immediate implant placement has several advantages, such as reduced number of surgeries and treatment time, as well as better patient acceptance, with the psychologic benefit of simultaneously replacing a lost tooth with an implant.<sup>1</sup> Other potential benefits are the ability to place the fixture in an ideal axial position and the

<sup>1</sup> Private practice, Gravedona, Italy.

<sup>2</sup> Dental School, University of Varese, Varese, Italy.

<sup>3</sup> Nanoworld Institute, University of Genoa, Genoa, Italy.

<sup>4</sup> Dental School, University of Birmingham, Birmingham, UK.

<sup>5</sup> Department of Periodontology, Dental Research Division, Guarulhos University, Guarulhos, São Paulo, Brazil.

<sup>6</sup> Department of Oral Pathology and Oral Medicine, Dental School, University of Chieti-Pescara, Chieti, Italy.

\* Corresponding author, e-mail: camangan@gmail.com

DOI: 10.1563/AAID-JOI-D-11-00112

preservation of the alveolar ridge in terms of height and width, which in turn has esthetic benefits.<sup>1</sup> In fact, after tooth extraction, a cascade of physiologic events takes place as the body starts to repair the extraction socket.<sup>1,2</sup> These physiologic events can be detrimental to the definitive esthetic results, since a significant loss of both vertical and horizontal volume of the buccal bone crest is expected.<sup>1-3</sup> Immediate implant placement into an extraction socket has been proposed as a method to preserve bone at the surgical site.<sup>1-3</sup> Some authors, in fact, have suggested that immediate placement of dental implants into fresh extraction sockets may facilitate morphologic ridge contour preservation.<sup>3-5</sup> Bone volume might be partially maintained, thus possibly providing for optimal soft tissue esthetic outcome.<sup>3-5</sup>

In contrast, some preclinical<sup>6</sup> and clinical<sup>7</sup> studies have reported bone resorption even after immediate placement and restoration of implants. In animal studies, Araujo et al<sup>6</sup> showed that immediate implants were not able to prevent bone remodeling that occurred in the walls of the postextraction socket. These findings were confirmed by Botticelli et al<sup>7</sup> who observed that, during a reentry procedure at 4 months of healing, immediate implant placement could not prevent resorption of the alveolar process, with the buccal-lingual dimensions of the ridge being markedly reduced (buccal >50%). These reported ridge alterations, mostly affecting the buccal bone wall, may have significant adverse effects on the final esthetic result, especially in the maxillary anterior region, where esthetic outcome is of great importance.<sup>7</sup>

The immediate placement of dental implants into fresh extraction sites has been shown to be a predictable and successful procedure, and the literature has demonstrated that it is no longer necessary to wait for complete healing of the extraction socket before implant placement.<sup>3,8,9</sup> The criteria of Albrektsson and Zarb<sup>10</sup> for success are considered to be well-established and are widely used in clinical studies as a "rule" for analyzing the success rate. These success criteria, however, may not apply to evaluate esthetics. Although implant success, as measured through fixture osseointegration and restoration of function, is high, the outcome of procedures available to create esthetic implant "success" is not always predictable.<sup>11</sup>

The current literature is scarce when it comes to objective outcome evaluation from an esthetic point of view. Some studies have paid particular attention to the influence of the presence or absence of interproximal gingival papilla after implant therapy.<sup>11,12</sup> In 1997, Jemt<sup>12</sup> proposed an index (papilla filled index) for assessing the size of the interproximal gingival papilla. Fürhauser et al<sup>13</sup> proposed an excellent index termed the pink esthetic score (PES), for an objective evaluation of peri-implant soft tissue esthetics. The PES concept focused essentially on the soft tissue aspects of an anterior implant restoration.<sup>13</sup> However, more variables are responsible for the esthetic outcome of implant-supported single-tooth replacement, such as crown-related variables; an esthetic implant restoration should be one that resembles a natural tooth in all aspects. For this purpose, Meijer et al<sup>14</sup> published the esthetic implant-crown index, consisting of criteria related to the implant restoration itself and those associated with the surrounding soft tissues. More recently, the pink esthetic/white esthetic score (PES/WES) was introduced by Belser et al.<sup>15</sup> The PES/WES by Belser et al<sup>15</sup> focused not only on the soft tissue aspects of an anterior implant restoration, but also on the visible part of the implant restoration itself. The PES/WES comprises 10 variables: mesial papilla, distal papilla, curvature of the facial mucosa, level of the facial mucosa, and root convexity/soft tissue color and texture at the facial aspect of the implant site, tooth form, volume, color, surface texture, and translucency. A score of 2, 1, or 0 is assigned to all parameters. All parameters are assessed by direct comparison with the natural, contralateral reference tooth, estimating the degree of match or eventual mismatch.<sup>15</sup>

The suitability of the PES/WES index for the objective outcome assessment of the esthetic dimension of anterior single-tooth implants has been confirmed recently.<sup>16</sup> Given the lack of comparative studies with thorough esthetic evaluation, as pointed out in a recent systematic review,<sup>5</sup> it remains unclear whether single implant placement in healing sites of the anterior maxilla yields superior esthetic outcome when compared with healed sites. The aim of this study was to compare the esthetic outcome of single implant treatment in healing (immediate implant placement) with healed

TABLE 1

## Implant Positions by Treatment Strategy

Treatment Strategy	Implant Positions				Total
	Central Incisor	Lateral Incisor	Cuspid	Premolar	
Immediate implant treatment	6	7	6	3	22
Conventional implant treatment	6	5	5	2	18
Total	12	12	11	5	40

sites (conventional implant placement) of the anterior maxilla, by means of the PES/WES index.

## MATERIALS AND METHODS

### Patient selection

This retrospective study was based on data from 40 patients who had been treated with an immediate (22 patients; 16 men, 6 women; aged between 20 and 56 years, mean 44.9 years) or conventional (18 patients; 10 men, 8 women; aged between 18 and 62 years, mean 46.7 years) single implant in the esthetic zone of the anterior maxilla (central and lateral incisors, canines, first premolars), between December 2006 and December 2008, in one single clinical center (private practice). The distribution of implant regions is shown in Table 1. The reasons for extraction of natural teeth are summarized in Table 2.

For inclusion, the patients should have natural teeth present both mesial and distal to the implant. Exclusion criteria were active periodontal infections, implant treatments including hard/soft tissue grafting before implant placement, uncontrolled diabetes, and heavy smoking habit (more than 15 cigarettes per day). Additional exclusion criteria for patients treated with immediate implants were the presence of fewer than 4 bony walls of the alveolus, the presence of dehiscence or fenestration of the residual bony walls, and the presence of a thin-scalloped gingival biotype (determined by the

transparency of a periodontal probe through the gingival margin while probing the buccal sulcus of the upper central incisor).<sup>17</sup>

All patients read and signed a written consent form. The study protocol was approved by the Ethical Committee for Human Studies of the University of Varese and was conducted in accordance with the Helsinki Declaration of 1975, as revised in 2000.

### Surgical and prosthetic procedures

A complete examination of the oral hard and soft tissues was carried out for each patient, and the implant placement was planned based on clinical and radiographic evaluation. Immediate implants were placed at the time of tooth extraction, while conventional implants were placed at least 6 months after tooth removal. After local anesthesia obtained by infiltrating articaine 4% containing 1:100 000 adrenaline (Ubistesin, 3M ESPE, St Paul, Minn), a mesiodistal crestal incision was made, and a full-thickness flap was reflected exposing the alveolar ridge.

In extraction sockets, care was taken to perform an atraumatic extraction, and the surgical procedure was performed as follows. The hopeless tooth was carefully luxated and extracted avoiding any lateral movement that might damage both buccal and palatal bone plates. Once the tooth was removed, the socket was debrided with curettes and irrigated with sterile saline. A periodontal probe

TABLE 2

## Reasons for Tooth Loss by Treatment Strategy

Treatment Strategy	Reasons for Tooth Loss					Total
	Agensis	Root Fracture	Caries/Nontreatable Endodontic Lesions	Periodontal Bone Loss	Root Resorption	
Immediate implant treatment	N/A	4	15	-	3	22
Conventional implant treatment	8	3	6	-	1	18
Total	8	7	21	-	4	40

was used to scan the internal surface of the alveolus for dehiscences and fenestrations before implant placement. For both immediate and conventional implant placement, a correct 3-dimensional implant positioning was considered of pivotal importance. Preparation of implant sites was carried out with spiral drills of increasing diameter (2.8 mm to place an implant with 3.3-mm diameter; 2.8 and 3.5 mm to place an implant with 4.1-mm diameter; and an additional 4.2-mm drill was used to prepare the site for 4.8-mm diameter implants), under constant irrigation. Implants were positioned at the bone crest level.

The implant system used in this study (Sistema Implantare Leone, Sesto Fiorentino, Italy) is characterized by a cone Morse taper interference-fit (TIF) locking-taper<sup>18</sup> combined with an internal hexagon. The Morse taper presents a taper angle of 1.5°. All implants were immediately provisionalized by means of a titanium temporary abutment and an acrylic resin crown cemented with a temporary cement (Temp-Bond, Kerr, Orange, Calif). All temporary crowns were in full contact in centric occlusion. The flaps were properly mobilized and repositioned to cover the implants completely and were secured in position by interrupted sutures.

Following provisionalization, postoperative instructions were given. All patients received oral antibiotics (Augmentin, GlaxoSmithKline Beecham, Brentford, UK), 2 g per day for 6 days. Postoperative pain was controlled by administering 100 mg nimesulide (Aulin, Roche Pharmaceutical, Basel, Switzerland), every 12 hours for 2 days, and detailed instructions about oral hygiene were given, including mouth rinses with 0.12% chlorhexidine (Chlorhexidine, Oral-B, Boston, Mass) administered for 7 days. Suture removal was performed at 8–10 days. The temporary restorations remained in situ for 3 months, and after this period definitive restorations were placed. All single crowns were ceramometallic and were cemented with a temporary cement.

### **Clinical follow-up examination**

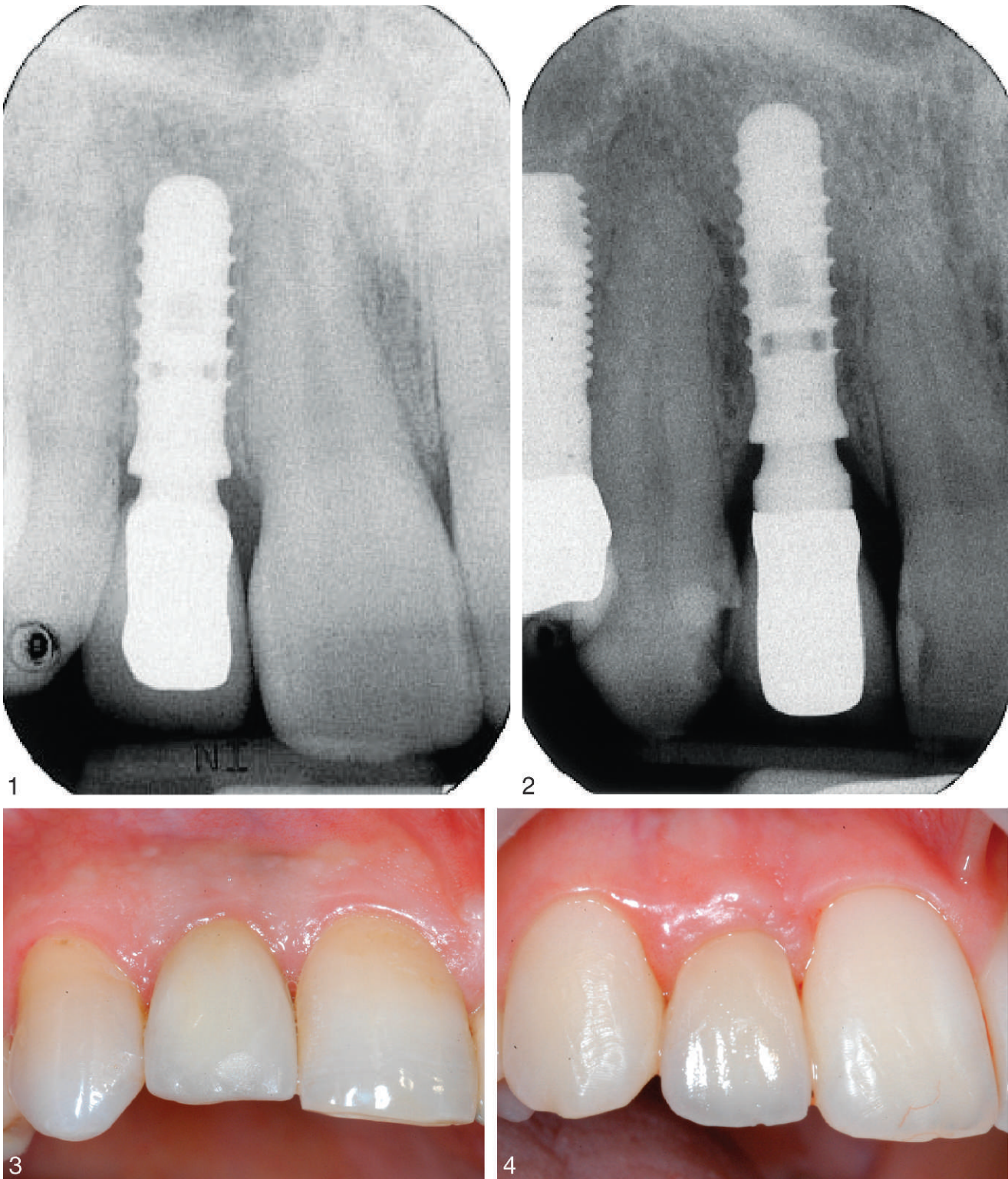
All patients were enrolled in an annual recall program. At each annual recall, a standard clinical examination was performed, and the following clinical parameters were assessed: presence/absence of pain or suppuration, presence/absence of clinically detectable implant mobility, and presence/absence of prosthetic complications at the implant-

abutment interface. Moreover, intraoral periapical radiographs were taken at the baseline (immediately after implant insertion) and at the 1- and 2-year follow-up sessions (Figures 1 and 2). Radiographs were taken using a Rinn alignment system with a rigid film-object x-ray source coupled to a beam-aiming device to achieve reproducible exposure geometry. Customized positioners, made of polyvinyl siloxane, were used for precise repositioning and stabilization of the radiographic template. Intraoral periapical radiographs were taken for 2 purposes: to evaluate the presence or absence of continuous peri-implant radiolucencies and to measure the distance between the implant shoulder and the first visible bone-to-implant contact (DIB) in millimeters at the mesial and distal implant site, by means of an ocular grid. For the second measurement, crestal bone level changes were recorded as changes in the vertical dimension of the bone around the implant, so that an evaluation of peri-implant crestal bone stability was gained with time. To correct for dimensional distortion in the radiograph, the apparent dimension of each implant (directly measured on the radiograph) was compared to the true implant length, to establish, with adequate precision, the eventual amount of vertical bone loss at the mesial and distal site of the implant.

The established criteria for implant-crown success were as follows: absence of pain or suppuration, absence of clinically detectable implant mobility; absence of peri-implant radiolucency, DIB < 1.5 mm after 12 months of functional loading, and not exceeding 0.2 mm for each following year<sup>10</sup>; and absence of prosthetic complications at the implant-abutment interface.<sup>18</sup>

### **Esthetic follow-up examination**

To objectively examine the esthetic outcome of the implants, intraoral photographs were critically analyzed by means of the PES/WES index.<sup>15</sup> All implant crowns (central, lateral incisors, canines, and first premolars) were photographed with a digital camera (Nikon D100, Nikon, Tokyo, Japan) and a 105-mm lens (AF micro Nikkor 105 mm 1:2.8 D, Nikon) with a ring flash (Nikon Macro Speedlight SB-29S, Nikon). For assessing anterior tooth replacements, the reference contralateral tooth had to be completely and symmetrically represented in order to ensure comparability. For this purpose, the



**FIGURES 1–4.** **FIGURE 1.** Immediate implant treatment: radiographic control of the implant after 2 years. **FIGURE 2.** Conventional implant treatment: radiographic control of the implant after 2 years. **FIGURE 3.** Immediate implant treatment: the crown in situ after 2 years. **FIGURE 4.** Conventional implant treatment: the crown in situ after 2 years.

TABLE 3

Assessment Criteria for Pink Esthetic Score (PES)			
Parameter	Absent	Incomplete	Complete
Mesial papilla	0	1	2
Distal papilla	0	1	2
Curvature of facial mucosa	0	1	2
Level of facial mucosa	0	1	2
Root convexity, soft tissue color, and texture	0	1	2
Maximum total PES			10

TABLE 4

Assessment Criteria for White Esthetic Score (WES)			
Parameter	Absent	Incomplete	Complete
Tooth form	0	1	2
Tooth volume/outline	0	1	2
Color (hue/value)	0	1	2
Surface texture	0	1	2
Translucency	0	1	2
Maximum total WES			10

photographs were centered at the midline to facilitate the subsequent analysis, which was primarily based on symmetry. In addition, standardized clinical photographs were taken of each implant site (Figures 3 and 4) and of the contralateral tooth. These additional photographs were used as tools for a more detailed evaluation. For the first premolars involved in the study, however, the photographs could not be taken at the midline; for this reason, the approach was modified, and a picture including the second premolars and the canine was taken, with these teeth serving as references. All photographs were taken slightly superior to the occlusal plane, centered at the contact region. Photographs were then viewed on a 42-inch monitor screen (Samsung PPM-42S3Q Flat Panel Plasma Monitor, Samsung, Seoul, South Korea). Study casts, produced in type IV stone, were finally fabricated for each of the 40 patients involved in the study. Study casts were fabricated to facilitate a direct and objective assessment related to the PES/WES index.

The clinical photographs and the study casts were used to perform the esthetic evaluations, and evaluations were performed by an independent calibrated observer who was not directly involved in the study, by means of the PES/WES index. To reduce bias and to achieve good reproducibility, the evaluation was carried out twice, on different days; in cases of diverging scores, the observer carefully reevaluated the photographs prior to making the final decision. A score of 2, 1, or 0 was assigned to each PES/WES parameter (Tables 3 and 4). The highest possible combined PES/WES was 20, which represented a close match of the peri-implant soft tissue conditions and the clinical single-tooth crown compared to the respective features present at the contralateral natural tooth site. A PES/WES  $\geq 12$  was

considered the limit for an acceptable esthetic outcome of implant treatment.

### Statistical analysis

The patient was used as the statistical unit in all analyses. The Mann-Whitney *U* test was used to compare the overall PES/WES, PES, and WES between immediate and conventional implant placement. The level of significance was set at .05.

## RESULTS

### Implant survival and implant-crown success

The mean time from surgery to evaluation was 31.09 months (SD 5.57; range 24–46) and 34.44 months (SD 7.10; range 24–48) for immediately and conventionally inserted implants, respectively. No implants were lost. With regard to osseointegration, all 40 anterior maxillary single-tooth Morse taper connection implants fulfilled the success criteria, with an implant-crown success rate of 100.0%. In fact, all implants showed stable osseointegration, with absence of pain or suppuration, absence of clinically detectable implant mobility, absence of peri-implant radiolucency, DIB  $< 1.5$  mm during the first year of function, and absence of prosthetic complications at the implant-abutment interface.

The mean DIB was  $0.42 \pm 0.14$  mm (CI 95%: 0.36–0.48) and  $0.45 \pm 0.15$  mm (CI 95%: 0.39–0.52) for immediate implants, while a mean DIB of  $0.49 \pm 0.18$  mm (CI 95%: 0.41–0.57) and  $0.55 \pm 0.17$  mm (CI 95%: 0.47–0.63) was found for conventional implants at the 1- and 2-year examinations, respectively.

### Esthetic outcome

The esthetic outcome for immediately vs conventionally placed implants is shown in Table 5. The

TABLE 5  
 Esthetic Outcome of Single Implant Treatment\*

	Immediate Placement (n = 22)			Conventional Placement (n = 18)			P	Overall (n = 40)		
	0	1	2	0	1	2		0	1	2
Mesial papilla	0	8	14	0	7	11	.905	0	15	25
Distal papilla	0	9	13	0	6	12	.697	0	15	25
Curvature of facial mucosa	0	10	12	0	8	10	.967	0	18	22
Level of facial mucosa	0	10	12	0	6	12	.527	0	16	24
Root convexity/soft tissue color/texture	1	17	4	2	8	8	.297	3	25	12
PES† (mean ± SD)	7.45 ± 1.62			7.83 ± 1.58			.543	7.62 ± 1.59		
Tooth form	0	9	13	0	8	10	.862	0	17	23
Tooth volume/outline	0	11	11	0	8	10	.777	0	19	21
Tooth color (hue/value)	2	9	11	1	7	10	.718	3	16	21
Surface texture	0	16	6	0	5	13	.014*	0	21	19
Translucency	3	10	9	1	8	9	.509	4	18	18
WES† (mean ± SD)	7.04 ± 1.29			7.77 ± 1.66			.094	7.37 ± 1.49		

\*The difference between the 2 samples is marginally significant ( $P < .05$ ).

†PES indicates pink esthetic score; WES, white esthetic score.

mean PES/WES was 14.50 (SD 2.52; range 9–19) and 15.61 (SD 3.20; range 8–20) for immediately and conventionally placed implants, respectively. Nine (22.5%) of 40 single implant treatments (3 immediate, 13.7%; 6 conventional, 33.4%) showed an almost perfect result (PES/WES  $\geq 18$ ). An acceptable result was found for 27 of 40 (67.5%) single implant cases (17 immediate, 77.3%; 10 conventional, 55.6%). The esthetic outcome was unfavorable for 4 of 40 (10.0%) single implant treatments (2 immediate, 9.0%; 2 conventional, 11.0%).

With respect to the PES/WES index, there were no significant differences between the 2 treatment modalities ( $P = .199$ ). The mean PES was 7.45 (SD 1.62; range 4–10) and 7.83 (SD 1.58; range 4–10) for immediately and conventionally inserted implants, respectively. With respect to the PES index, there were no significant differences between the 2 treatment options ( $P = .543$ ). The mean WES was 7.04 (SD 1.29; range 5–10) and 7.77 (SD 1.66; range 4–10) for immediately and conventionally inserted implants, respectively. With regard to the WES index, the difference between the 2 samples was not statistically significant ( $P = .095$ ).

## DISCUSSION

The placement of implants in fresh extraction sockets has been discussed increasingly frequently

in the literature and performed by clinicians in daily practice.<sup>3,8,9</sup> Comparable data regarding placement of immediately loaded implants in extraction sites vs implants placed and loaded in healed edentulous sites, however, are still inadequate.<sup>5</sup> Some studies compared immediate and delayed implant placement, and no definitive conclusions could be drawn regarding which had a higher survival rate.<sup>5,8,19–21</sup> Although some studies have suggested that the esthetic outcome might be better when placing implants just after tooth extraction,<sup>3,19</sup> there is still no reliable evidence to support the advantages of immediate implant placement in the esthetic area of the maxilla.<sup>5</sup>

Today, esthetics is becoming the key for success in daily practice. The novel PES/WES index has been recently reported as an objective tool in rating the esthetics of implant-supported single crowns and adjacent soft tissues.<sup>15,16</sup> Unfortunately, there are only 2 studies<sup>22,23</sup> comparing the esthetic outcome of single implant treatment in healing with that in fully healed sites of the anterior maxilla. In a comparative clinical study on 44 patients, Cosyn et al<sup>22</sup> compared the esthetic outcome of early (22) vs conventionally (25) placed implants in the anterior maxilla. In this study, the esthetic outcome was objectively rated using the PES and WES by a blinded clinician who had not been involved in the study. After an average period of 2.5 years of function, no significant differences were found for any of the criteria between early (PES:  $9.90 \pm 1.92$ ;

WES:  $7.86 \pm 1.91$ ) and conventional (PES:  $10.40 \pm 2.16$ ; WES:  $7.96 \pm 1.99$ ) implant placement, which yielded comparable esthetic outcomes.<sup>22</sup> In a more recent study on 39 patients, Raes et al<sup>23</sup> compared the esthetic outcome of immediate (16) vs delayed (23) single implants in the anterior maxilla. In this study, the mean PES was 10.33 (SD 2.29; range 6–14) and 10.35 (SD 1.58; range 7–13) for immediate and conventional implant treatment, respectively.<sup>23</sup> Immediate implants demonstrated stable midfacial soft tissue levels with only a minority of cases (7%) showing advanced recession ( $>1$  mm). Irrespective of the timing of implant placement, however, esthetic failures (PES  $< 8$ ; WES  $< 6$ ) seem to be rather common (24%), with only a strict minority of cases (8%) showing perfection (PES  $\geq 12$ ; WES  $\geq 9$ ). The remainder (68%) demonstrated acceptable esthetics.<sup>23</sup>

In our present study, the mean PES/WES was 14.50 (SD 2.52; range 9–19) and 15.61 (SD 3.20; range 8–20) for immediately and conventionally placed implants, respectively. No significant differences were found between the 2 groups. The only difference evidenced between the 2 groups was related to the surface texture; this parameter, however, is strongly related to the quality and design of prosthetic work, and seems not to be related to peri-implant tissue dynamics.

Kois<sup>24</sup> addressed 5 diagnostic factors for predictable single tooth peri-implant esthetics when immediately placing implants in extraction sockets. These are position of the osseous crest before tooth extraction, form and biotype of the periodontium, and tooth shape and tooth position relative to the free gingival margin.<sup>24</sup> The level of bone support and the soft tissue dimensions around the implant-supported single-tooth restoration are factors suggested to be important for the esthetic outcome of implant therapy.<sup>24,25</sup> The height of peri-implant papillae depends on the bone level at adjacent root surfaces, and the interproximal crest height determines the presence or absence of peri-implant papillae.<sup>25</sup> The absence of the interproximal papilla can lead to cosmetic deformities, phonetic difficulty, and food impaction.<sup>25</sup>

In our present study, an important criterion for patient inclusion was the dimension of the available alveolar bone, and for sockets, the presence of intact bone walls; periodontally compromised patients were excluded from the study. The level

of the peri-implant soft tissue, which influences the crown length, and its color and texture, are decisive for the natural appearance of implant-supported single-tooth replacements.<sup>25</sup> When placing an implant immediately, the form and biotype of the periodontium are considered essential to achieve an optimal esthetic outcome.<sup>11,24,25</sup> When a thick periodontal biotype is presented, there is a greater peri-implant mucosal dimension.<sup>12</sup> Such soft tissue is more resistant to gingival recession<sup>12</sup>; for this reason, patients with thick biotypes are better candidates for immediate implant placement because there is less chance that the tissues will recede postplacement, thus resulting in stable esthetics.<sup>24,25</sup> If immediate placement is done in patients with a thin biotype, there is a higher risk of soft tissue recession and underlying resorptive osseous remodeling, exposing the metal margin of the implant.<sup>11,25</sup> For all these reasons, in our present study, patients with a thin-scalloped biotype were not included in the immediate implant treatment group. Implants must be placed in an optimal 3-dimensional position (mesiodistal, apicocoronal, buccolingual) and inclination.<sup>25,26</sup> When an implant is placed in a fresh extraction socket, it seems prudent to place it in the palatal portion of the socket, with its marginal border well below the ridge of the fresh socket to compensate for the expected resorption.

Finally, it is essential to maintain as much of the circumferential bone height around the implant neck as possible.<sup>27</sup> However, when an abutment is connected to a dental implant at the crestal level, bone loss around the implant always occurs.<sup>27</sup> It is perceived that initial bone turnover around an implant after establishment of biologic contact with bone results in a certain amount of bone loss.<sup>27</sup> Some authors have advocated, however, that the presence of a microgap of variable dimension at the implant abutment interface, determining a chronic bacterial inflammation of implant-abutment connection,<sup>28,29</sup> could have a direct effect on bone loss. Additional bone resorption seems to be correlated with micromovements at the implant abutment interface,<sup>30</sup> since a higher bacterial contamination may be related to a misfit at the implant-abutment interface caused by screw loosening.<sup>28,29</sup> Screw loosening can damage interfaces in implant components, favoring contamination of its internal parts by microorganisms.



In our present study, Morse taper connection implants were used to restore single-tooth gaps in the esthetic area of the anterior maxilla. The Morse TIF locking-taper can avoid micromovements at the implant-abutment interface, removing one reason for crestal bone loss around implants.<sup>31,32</sup> Moreover, with Morse taper connection implants, the gap is closed so tightly that the abutment and the fixture behave as a single piece; there is effectively no microgap and therefore no bacterial leakage, reducing the level of peri-implant tissue inflammation to a minimum.<sup>31,32</sup> In addition, with a tapered interference fit, the abutment emergence geometry provides “platform switching” advantages.<sup>33,34</sup> Platform switching refers to the use of a small-diameter abutment on a large-diameter implant collar. Lazzara and Porter<sup>33</sup> were the first authors to report that the placement of platform switched implants resulted in a smaller vertical change in the crestal bone level than was typically seen when restoring conventional implants with abutments of matching diameter. The success of the platform switching design or horizontal off-set at the implant abutment interface is believed to be a consequence of the horizontal repositioning of the microgap, and any toxin-producing bacteria within it, as far away from the bone as possible to minimize bone loss.<sup>33,34</sup> With this ideal emergence profile, moreover, an increased space for excellent soft tissue healing connective tissue is provided, thus improving the biologic seal constituted by a thicker, larger, well-organized volume of peri-implant soft tissues, protecting the bone crest from resorption.<sup>33,34</sup>

### CONCLUSIONS

In our present study, immediate and conventional single implant treatment yielded comparable esthetic outcomes. Immediate implant placement may not show an increased risk for esthetic failure when treatment is performed by experienced clinicians in well-selected cases.

### ABBREVIATIONS

DIB: distance between the implant shoulder and the first visible bone-to-implant contact  
 PES: pink esthetic score  
 TIF: taper interference-fit  
 WES: white esthetic score

### REFERENCES

1. Koh RU, Rudek I, Wang HL. Immediate implant placement: positives and negatives. *Implant Dent.* 2010;19:98–108.
2. Lee CY, Hasegawa H. Immediate load and esthetic zone considerations to replace maxillary incisor teeth using a new zirconia implant abutment in the bone grafted anterior maxilla. *J Oral Implantol.* 2008;34:259–267.
3. Tortamano P, Camargo LO, Bello Silva MS, Kanashiro LH. Immediate implant placement and restoration in the esthetic zone: a prospective study with 18 months of follow-up. *Int J Oral Maxillofac Implants.* 2010;25:345–350.
4. Chen ST, Wilson TG, Hammerle CH. Immediate or early placement of implants following tooth extraction: review of biologic basis, clinical procedures and outcomes. *Int J Oral Maxillofac Implants.* 2004;19(suppl):12–25.
5. Esposito M, Grusovin MG, Polyzos IP, Felice P, Worthington HV. Timing of implant placement after tooth extraction: immediate, immediate-delayed or delayed implants? A Cochrane systematic review. *Eur J Oral Implantol.* 2010;3:189–205.
6. Araujo MG, Wennstrom JL, Lindhe J. Modeling of the buccal and lingual bone walls of fresh extraction sites following implant installation. *Clin Oral Implants Res.* 2006;17:606–614.
7. Botticelli D, Berglundh T, Lindhe J. Hard tissue alterations following immediate implant placement in extraction sites. *J Clin Periodontol.* 2004;31:820–828.
8. Cooper L, Raes F, Reside G, et al. Comparison of radiographic and clinical outcomes following immediate provision-alization of single-tooth dental implants placed in healed alveolar ridge and extraction sockets. *Int J Oral Maxillofac Implants.* 2010;25:1222–1232.
9. West JD, Oates TW. Identification of stability changes for immediately placed dental implants. *Int J Oral Maxillofac Implants.* 2007;22:623–630.
10. Albrektsson T, Zarb G. Determinants of correct clinical reporting. *Int J Prosthodont.* 1998;11:517.
11. Lops D, Chiapasco M, Rossi A, Bressan E, Romeo E. Incidence of interproximal papilla between a tooth and an adjacent immediate implant placed into a fresh extraction socket: 1-year prospective study. *Clin Oral Implants Res.* 2008;19:1135–1140.
12. Jemt T. Regeneration of gingival papillae after single-implant treatment. *Int J Periodontics Restorative Dent.* 1997;17:326–333.
13. Fürhauser R, Florescu D, Benesch T, Haas R, Mailath G, Watzek G. Evaluation of soft tissue around single-tooth implant crowns: the pink esthetic score. *Clin Oral Implants Res.* 2005;16:639–644.
14. Meijer HJ, Stellingsma K, Meijndert L, Raghoobar GM. A new index for rating aesthetics of implant supported single crowns and adjacent soft tissues: the Implant Crown Aesthetic Index. *Clin Oral Implants Res.* 2005;16:645–649.
15. Belser U, Grutter L, Vailati F, Bornstein M, Weber H, Buser D. Outcome evaluation of early placed maxillary anterior single-tooth implants using objective esthetic criteria: a cross-sectional, retrospective study in 45 patients with a 2- to 4-year follow-up using pink and white esthetic scores. *J Periodontol.* 2009;80:140–151.
16. Cho H, Lee J, Um H, Chang B. Esthetic evaluation of maxillary single-tooth implants in the esthetic zone. *J Periodontol Implant Sci.* 2010;40:188–193.
17. De Rouck T, Eghbali A, Collys K, De Bruyn H, Cosyn J. The gingival biotype revisited: transparency of the periodontal probe through the gingival margin as a method to discriminate thin from thick gingival. *J Clin Periodontol.* 2009;36:428–433.
18. Mangano C, Mangano F, Shibli JA, et al. Prospective evaluation of 2549 Morse taper connection implants: 1- to 6-year data. *J Periodontol.* 2011;82:52–61.

19. Artzi Z, Kohen J, Carmeli G, Karmon B, Lor A, Ormianer Z. The efficacy of full arch immediately restored implant supported reconstructions in extraction and healed sites: a 36-month retrospective evaluation. *Int J Oral Maxillofac Implants*. 2010;25:329–335.
20. Lindeboom J, Tjiook Y, Kroon F. Immediate placement of implants in periapical infected sites: a prospective randomized study in 50 patients. *Oral Surg Oral Med Oral Pathol Oral Radiol Endod*. 2006;101:705–710.
21. Block M, Mercante D, Lirette D, Mohamed W, Ryser M, Castellon P. Prospective evaluation of immediate and delayed provisional single tooth restorations. *J Oral Maxillofac Surg*. 2009;67:89–107.
22. Cosyn J, Eghbali A, De Bruyn H, Dierens M, De Rouck T. Single implant treatment in healing versus healed sites of the anterior maxilla: an aesthetic evaluation. *Clin Implant Dent Relat Res*. 2012;14:336–346.
23. Raes F, Cosyn J, Crommelinck E, Coessens P, De Bruyn H. Immediate and conventional single implant treatment in the anterior maxilla: 1-year results of a case series on hard and soft tissue response and aesthetics. *J Clin Periodontol*. 2011;38:385–394.
24. Kois J. Predictable single tooth peri implant esthetics: five diagnostic keys. *Compend Contin Educ Dent*. 2004;25:895–900.
25. Kazor CE, Al Shamari K, Sarment DP, Misch CE, Wang HL. Implant plastic surgery: a review and rationale. *J Oral Implantol*. 2004;30:240–254.
26. Avvanzo P, Ciavarella D, Avvanzo A, Giannone N, Carella M, Lo Muzio L. Immediate placement and temporization of implants: three- to five-year retrospective results. *J Oral Implantol*. 2009;35:136–142.
27. Calvo Guirado J, Ortiz-Ruiz A, Lopez-Mari L, Delgado-Ruiz R, Matè-Sanchez J, Gonzalez L. Immediate maxillary restoration of single-tooth implants using platform switching for crestal bone preservation: a 12-month study. *Int J Oral Maxillofac Implants*. 2009;24:275–281.
28. Broggini N, McManus L, Hermann J, et al. Persistent acute inflammation at the implant-abutment interface. *J Dent Res*. 2003;82:232–237.
29. Piattelli A, Vrespa G, Petrone G, Iezzi G, Annibali S, Scarano A. Role of the microgap between implant and abutment: a retrospective histologic evaluation in monkeys. *J Periodontol*. 2003;74:346–352.
30. Heckmann S, Linke J, Graef F, Foitzik C, Wichmann M, Weber H. Stress and inflammation as a detrimental combination for peri-implant bone loss. *J Dent Res*. 2006;85:711–716.
31. Hansson S. A conical implant-abutment interface at the level of the marginal bone improves the distribution of stresses in the supporting bone. An axisymmetric finite element analysis. *Clin Oral Implants Res*. 2003;14:286–293.
32. Dibart S, Warbington M, Su M, Skobe Z. In vitro evaluation of the implant-abutment bacterial seal: the locking taper system. *Int J Oral Maxillofac Implants*. 2005;20:732–737.
33. Lazzara RJ, Porter SS. Platform switching: a new concept in implant dentistry for controlling post-restorative crestal bone levels. *Int J Periodontics Restorative Dent*. 2006;26:9–17.
34. Prosper L, Redaelli S, Pasi M, Zarone F, Radaelli G, Gherlone EF. A randomized prospective multicenter trial evaluating the platform switching technique for the prevention of post-restorative crestal bone loss. *Int J Oral Maxillofac Implants*. 2009;24:299–308.