

Ultrasonic Oscillations for Conservative Retrieval of a Rare Fracture of Implant Healing Abutment

Sudhir Bhandari, MDS*
Narinder Aggarwal, BDS
Sonika Bakshi, MBA, BDS

Dental implants can be rendered useless because of complications related to implant components such as the fracture of abutment screw and prosthetic retaining screw. Removal of such fractured fragments is therefore deemed necessary for the sake of prosthetic restoration. This case report presents a rare incident of healing abutment fracture and details the stepwise and probably the most conservative clinical technique using ultrasonic oscillations for retrieval of fractured screw fragment without affecting the internal surface of the implant. The management was based on the fact that the screw, being an inclined plane, will unthread when subjected to continuous vibrations.

Key Words: *healing abutment, screw fracture, ultrasonic oscillations*

INTRODUCTION

Despite being predictable and with a documented high success rate, mechanical, biological, and technical complications do occur in dental implant-related treatments.^{1,2} Implant components, especially abutment screws and prosthetic retaining screws, fracture in response to myriad factors (alone or in combination), ranging from fatigue due to biomechanical overload, repeated screw loosening and tightening, improper placement techniques, nonpassive fit or improper use of the prosthesis, and manufacturing errors.³⁻⁸

Retrieval of fractured screws is considered difficult and generally poses a challenge for the clinician to remove them without damaging the internal surface of implants. An abutment screw fractured above the head of the implant can be removed by holding it with hemostats. Screw fracture within the body of implant can be retrieved either by the use of a self-made screwdriver⁶ or using the special service set available for the

specific implant system (IMZ TwinPlus Repair Set K 3.3, Dentsply Friadent, Mannheim, Germany).⁷ The objective of these systems is to use a removal wedge to engage the broken screw via a slot drilled into the top surface of the broken screw and then applying a reverse torque. Use of endodontic instruments has also been reported to retrieve the thread that had fractured away from the body of the screw.⁸ When the fractured screw fragment is not retrievable, the implant could be salvaged by modifying the screw hole and fabricating a post-supported crown.⁹

Following is a case report describing a rare incident of healing abutment fracture (3.4 mm/GH 2, Friadent GMBH, Mannheim, Germany) and the utility of a piezoelectric ultrasonic scaler (EMS Minipiezon, Electromedical Systems SA, Nyon, Switzerland) in conservatively retrieving the fractured screw fragment.

CASE REPORT

A 64-year-old woman in good general health sought care for a dislodged healing abutment with respect to an implant placed in the right maxillary second premolar for 2 days. Intraoral examination showed that the right maxillary first and second

Post Graduate Institute of Medical Education and Research, Chandigarh, India.

* Corresponding author, drsudhirbhandari@yahoo.co.in

DOI: 10.1563/AAID-JOI-D-11-00126

molars restored with porcelain fused to metal crowns were the only natural teeth present in the maxillary arch, and it showed the presence of dental implants (Xive, Friadent GMBH, Mannheim, Germany) in Nos. 4, 5, 6, 10, and 11 regions. She was wearing a removable partial denture for the missing maxillary teeth (No. 4 to 15) and had a full complement of teeth in the mandibular arch. On further evaluation, the implant of concern was found to be in close proximity to No. 3, and the healing abutment was seen to be fractured within the body of the implant (Figure 1). The implant head was covered over by the soft tissue as she visited the department after 2 days of reported dislodgement of the healing abutment. After locating the site of the screw fracture on radiograph (Figure 1), the following steps were followed to retrieve the broken fragment.

1. The implant body was thoroughly cleaned using an air/water spray from the 3-way syringe and then dried with air.
2. The piezoelectric ultrasonic scaler tip (EMS-Tip P, Electromedical Systems SA) was placed in relation to the top surface of the fractured screw, and a radiograph was taken to finalize the tip's position (Figure 2).
3. Once the scaler tip was made stable on the top surface of the fractured fragment, the oscillations were started with minimal power and copious irrigation. A gentle reverse torque was applied intermittently while the vibrating scaler tip contacted the top surface of the screw so that the fractured screw should spin out of the screw hole.
4. The tip's contact with the screw fragment was progressively decreased as the fractured fragment started loosening.
5. The loosened screw was then picked up with a tweezer (DPU 17, Pliers, utility pick up, Hu-Friedy, Chicago, Ill; Figure 3).
6. The internal surface of the implant was again cleaned using the air/water spray and evaluated radiographically (Figure 4).
7. The new healing abutment was placed after reducing the proximal contour of porcelain fused to metal crown on No. 3.
8. Chairside relining of the removable partial denture was done in the region of the new healing abutment using an additional silicon-

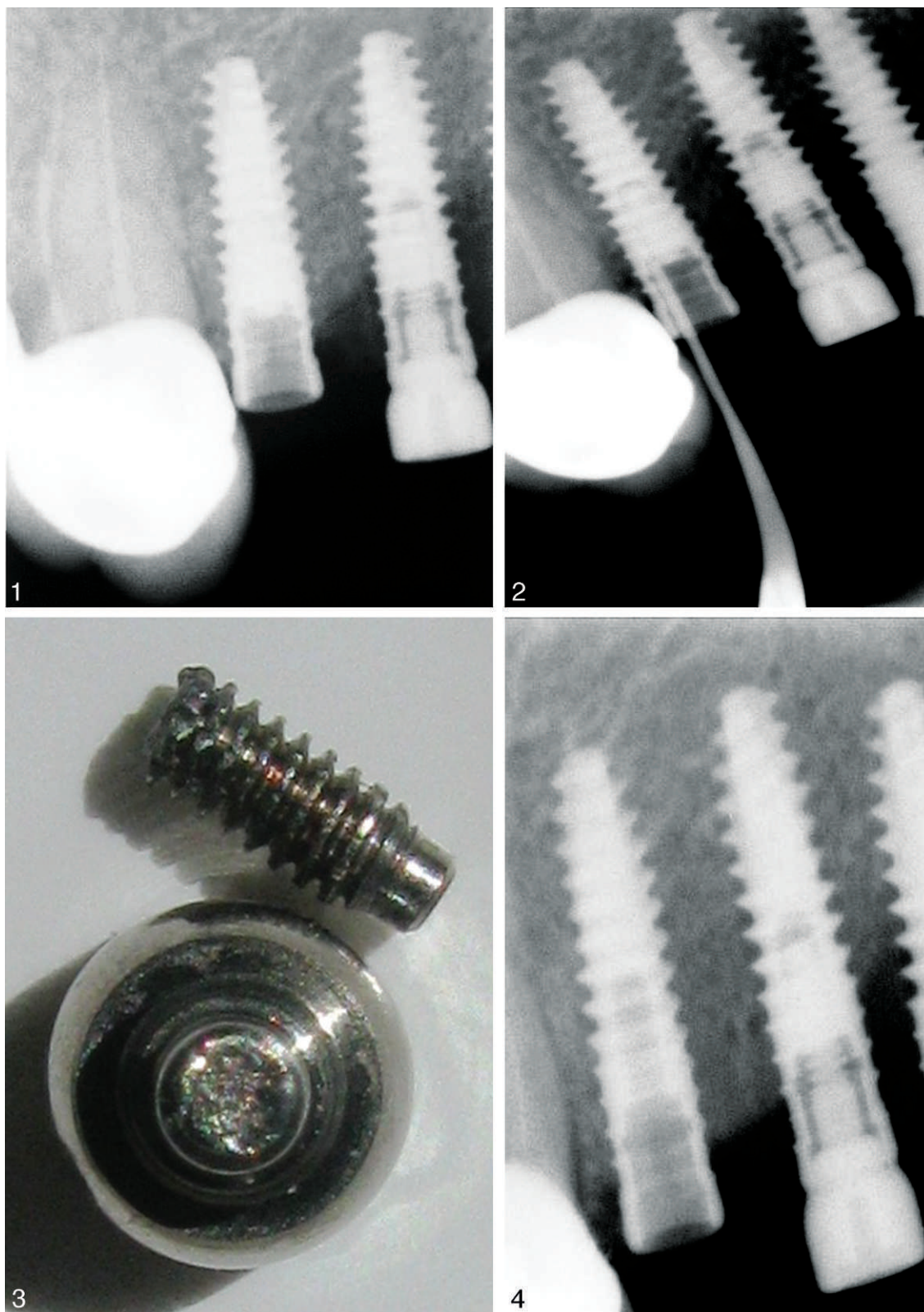
based long-term soft reliner (Mollosil, Detax, Ettlinger, Germany).

DISCUSSION

Screws are a weak link in the implant-prosthesis assembly, and their breakage constitutes an ongoing problem, which leads to a difficult situation of retrieval and can complicate further prosthodontic treatment.^{9,10} The triggering and probably the predominant factor for screw fracture is its undetected loosening. Repeated screw loosening and tightening may lead to fracture of abutment screws or prosthetic retaining screws, inflicting needless suffering to the patient.^{4-8,11,12}

Prevention of fractured screws is the best treatment and can be achieved by following precautionary measures, such as having an adequate number of implants in the optimal position to bear the occlusal load. In addition to preloading the screw, it is of utmost importance to use the correct fixation screw and apply the recommended screw-tightening torque with the manufacturer-specified torque wrench. Confirming the precise fit of the implant components, passive seating of the prosthesis, and a restoration design favoring axial load, avoiding lateral and occlusal overload surely preserves the integrity of the components. It is prudent to replace loose screws with new ones instead of retightening them. In addition, reinforcing regular follow-up, encouraging periodic maintenance, and scheduling an immediate dental visit if the patient detects looseness of the prosthesis may avert such an inconvenient complication.^{11,12}

Implant components are known to fracture more frequently in the posterior region and in partially dentate patients compared with completely edentulous patients.^{13,14} In the conventional 2-stage implant protocol, the healing abutments have a relatively short duration of stay in the oral cavity and are not under functional load; thus, the incidence of their fracture is not common. Although rare, the fracture of healing abutment in this reported case may be related to fatigue caused by its repeated loosening and tightening due to close proximity of the implant to the adjacent tooth. Another probable factor could have been the nonaxial load due to the continued use of a removable partial denture over the undetected loose abutment, subsequently leading to fracture.



FIGURES 1–4. **FIGURE 1.** Radiograph showing close proximity of the implant and the adjacent tooth. Also visible is the fractured fragment within the implant body. **FIGURE 2.** Radiograph showing the position of the scaler tip in relation to the fractured screw. Also showing is its narrow and long form. **FIGURE 3.** Fractured components of the healing abutment. **FIGURE 4.** Radiograph showing the implant body cleared of fractured fragment.

Modification of the proximal contours of the adjacent restoration created adequate distance between the abutment and the adjacent tooth. Furthermore, relining the removable partial denture and minor occlusal corrections over an appropriately tightened new healing abutment ensured forces along the long axis of the implant.

Applying a gentle reverse torque concomitant with ultrasonic vibrations is important, as it prevents the screw from winding further into the implant and allows for its easy retrieval. In addition to being painless and time saving, the procedure adopted in this case also has the advantage of having a familiar armamentarium, and it completely eliminates the need for drilling to create a slot on the top surface of the broken fragment. The noncutting scaler tip and its long and narrow make (Figure 2) allow for the procedure to be carried out more predictably, irrespective of the location of the fractured fragment within the body of the implant. In contrast to the methods of fragment retrieval, which create a slot on the top surface of the broken fragment, the potential to protect the threads of internal surface of implants understandably becomes increasingly difficult and unpredictable as the fragment location moves more apically within the implant body.

The integrity of the internal surface of the implant was completely preserved because of the precise positioning of the noncutting scaler tip, using oscillations at minimal power coupled with intermittent gentle reverse torque and progressively decreasing the tip's contact with the loosening screw.

CONCLUSION

The piezoelectric ultrasonic scaler, which is a part of the routine dental armamentarium, is surely viable for conservative retrieval of a fractured screw fragment. Multiple factors are responsible for screw

fracture, and their prevention is the best treatment. Regular recall and maintenance appointments should be part of the treatment protocol and should be regularly reinforced, beginning as early as the treatment-planning phase. This will ensure early detection of warning signs of future complications and would allow for appropriate measures to correct them.

REFERENCES

1. Ekelund JA, Lindquist LW, Carlsson GE, Jemt T. Implant treatment in the edentulous mandible: a prospective study on Branemark system implants over more than 20 years. *Int J Prosthodont.* 2003;16:602–608.
2. Goodacre CJ, Kan JY, Rungcharassaeng K. Clinical complications of osseointegrated implants. *J Prosthet Dent.* 1999;81:537–552.
3. Luterbacher S, Fourmousis I, Lang NP, Bragger U. Fractured prosthetic abutments in osseointegrated implants: a technical complication to cope with. *Clin Oral Implants Res.* 2000;11:163–170.
4. Yilmaz B, McGlumphy E. A technique to retrieve fractured implant screws. *J Prosthet Dent.* 2011;105:137–138.
5. Fard AM, Jacobs LC. Retrieval of a stripped abutment screw: a clinical report. *J Prosthet Dent.* 2010;104:212–215.
6. Williamson RT, Robinson FG. Retrieval technique for fractured implant screws. *J Prosthet Dent.* 2001;86:549–550.
7. Nergiz I, Schmage P, Shahin R. Removal of a fractured implant screw: a clinical report. *J Prosthet Dent.* 2004;91:513–517.
8. Satterthwaite J, Rickman L. Retrieval of a fractured abutment screw thread from an implant: a case report. *Br Dent J.* 2008;204:177–180.
9. Pow EHN, Wat PYP. A technique for salvaging an implant-supported crown with a fractured abutment screw. *J Prosthet Dent.* 2006;95:169–170.
10. Rangert B, Eng M, Jemt T, Jorneus L. Forces and moments on Branemark implants. *Int J Oral Maxillofac Implants.* 1989;4:241–247.
11. Misch CE. Principles of screw retained prosthesis. In: Rudolph P, ed. *Contemporary Implant Dentistry.* St Louis, Mo; Mosby; 1999:580–582.
12. Schwarz MS. Mechanical complications of dental implants. *Clin Oral Implants Res.* 2000;11(suppl 1):156–158.
13. Goodacre CJ, Kan YKJ, Rungcharassaeng K. Clinical complications of osseointegrated implants. *Prosthet Dent.* 1999;81:537–552.
14. Bragger U, Aeschlimann S, Bürgin W, Hammele CH, Lang NP. Biological and technical complications and failures with fixed partial dentures (FDP) on implants and teeth after four to five years of function. *Clin Oral Implants Res.* 2001;12:26–34.