

# Altered Position of the Medial Lingual Nutritional Foramina at Different Stages of Alveolar Ridge Atrophy

Nora Valerie Lautner, MD<sup>1\*</sup>  
 Erwin Bernauer, MD, DMD<sup>2</sup>  
 Christian Krenkel, MD, DMD<sup>3</sup>  
 Alexander Gaggl, MD, DMD<sup>3</sup>

To determine the altered location of the medial lingual nutritional foramina in different stages of bone resorption, 55 cadaveric mandibles were selected for this study from a total of 1532. Prevalence, location of the foramen (lingual, cranial, labial), application of Atwood classification (grades 1–6), and macroanatomic dissections were tools of this examination. An increasing grade of atrophy leads to a shift in position of the medial lingual nutritional foramen.

**Key Words:** *implants, hemorrhage, bone resorption*

## INTRODUCTION

**A**trophy of the jawbone after tooth loss is a very common oral disease.<sup>1</sup> Oral implantology or distraction osteogenesis are basic surgical procedures in oral and maxillofacial surgery but are not without their complications. The lingual side of the mandibular midline, in particular, is an anatomic area where hemorrhagic accidents often occur when using surgical techniques, such as implant insertion.<sup>2</sup> The small bony foramina on the lingual side are named differently by several authors: interalveolar foramina by Tsusaki et al,<sup>3</sup> medial lingual foramen by Tagaya et al<sup>4</sup> and McDonnell et al,<sup>5</sup> superior genial spinal foramen by Vandewalle et al,<sup>6</sup> or lingual foramen by Liang et al.<sup>7</sup>

Various studies were performed on the frequency,<sup>4,6,7</sup> positions,<sup>6,7</sup> diameters,<sup>7</sup> and content of the foramina,<sup>4,6,7</sup> but in the overall patient population different grades of dentitions exist. In preoperative planning the operator has to consider the degree of

osseous atrophy, and care should be taken to recognize the mandibular situations. Therefore, the question arises as to whether or not severe atrophy of alveolar bone creates an increased risk of bleeding in the lingual mandibular midline region due to changes in anatomic conditions.

## MATERIAL AND METHODS

In the first instance, 3 wet specimens with strong atrophy of the alveolar crest near the medial lingual nutritional foramina region were selected from an anatomic collection. The superficial layers of the floor of the mouth were dissected, fat tissue was removed, and the sublingual artery was prepared on the left and right sides of the mandible. The branches of the medial and lateral interalveolar artery were also demonstrated with their bony entrance (Figure 1). The nerves and veins were removed. Injecting red latex into the femoral artery displayed the course of the arteries in the specimens, especially in the mandible, namely the suprascapular artery, medial interalveolar artery, and sublingual artery.

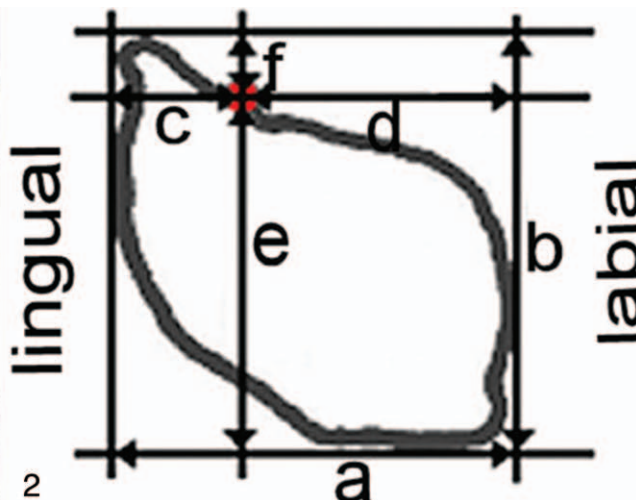
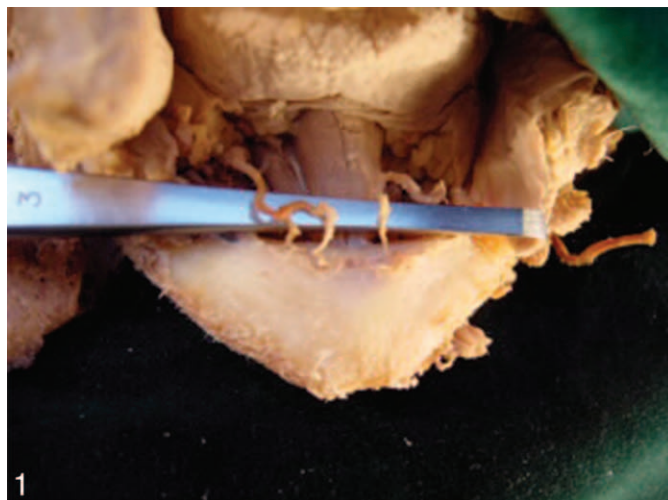
In the next step, 1532 dry specimens from the University of Innsbruck were examined. The first criterion was the existence of the medial lingual nutritional foramen of the medial interalveolar

<sup>1</sup> Paracelsus Medical University, Salzburg, Austria, and Eberhard Karls University Tuebingen, Germany.

<sup>2</sup> Paracelsus Medical School Salzburg, Landeskrankenhaus, Austria.

<sup>3</sup> Department of Oral & Maxillofacial Surgery, Paracelsus Medical School Salzburg, Landeskrankenhaus, Austria.

\* Corresponding author, e-mail: nora.lautner@pmu.ac.at  
 DOI: 10.1563/AAID-JOI-D-11-00175



**FIGURES 1 AND 2.** **FIGURE 1.** Branches of the medial and lateral interalveolar arteries demonstrated with their bony entrance on a wet specimen. **FIGURE 2.** Cross sectional view representing the investigated variables a–f.

artery. Of the specimens, 373 (24.4%) were excluded because they were damaged ( $n = 349$ , 22.8%) or juvenile ( $n = 24$ , 1.6%). Juvenile specimens were not included in the study because the growth of the remaining incisors leads to resorption of the lingual alveolar bone due to its large crown diameter. In all, 1159 (75.6%) specimens remained in the study sample.

Atrophy was attested in accordance with the Atwood<sup>8</sup> classification of the anterior mandible on each specimen (6 classes). For each Atwood classification class, 10 specimens were selected. A clear apparent medial lingual nutritional foramen of the right medial interalveolar artery was vital.

A small metal pellet (diameter 0.7–1.0 mm; CCI, Würzburg, Germany) was positioned and fixed on the foramen. A silicone impression (thickness 10–15 mm) was taken in the region of the incisor teeth and a plaster cast was produced. Plaster models of the silicone impressions were ground (thickness 10–15 mm). This produced plane cross sections of the investigated mandibular area. The contour and foramen of the medial interalveolar artery (marked by the pellet) of each single plaster cast were transferred manually for measurement. A reference line enabled unified transcription. This reference line was already given by the silicone impressions, which were previously made on a plane surface.

For each mandible, 6 parameters were investigated more closely (Figure 2): total width (a), total height (b), distance from the lingual border to the medial lingual nutritional foramen (c), distance from

the medial lingual nutritional foramen to the labial border (d), distance from the medial lingual nutritional foramen to the caudal border (e), and distance from the medial lingual nutritional foramen to the cranial border (f).

All measurements were taken using a caliper of accuracy and reported in millimeters (mm). After data collection and entry in an Excel database, the data were checked and analysis was performed with IBM SPSS Statistics for Windows, version 19 (Armonk, NY). Descriptive statistics were used to describe the main features of the data collection. Stengel-Blatt diagrams and histograms were applied to illustrate distribution of the variables. Normal distribution was tested. Variance analysis was applied to investigate 2 variables more closely related to the classes of atrophy. Finally, the measurements were examined and evaluated by variance analysis.

### RESULTS

The results of applying the Atwood classification on the 1159 mandibles are shown in the Table. As the frequency distribution shows, class 2 ( $n = 835$ ) represents the largest proportion of the population at 54.5%; the extremely low incidence of class 6 stands out at only 0.3% ( $n = 5$ ).

Applying the Atwood classification class of the anterior mandible to the 55 selected specimens, we found that the position of the medial lingual nutritional foramen changed as follows:

TABLE

Distribution of study samples according to the Atwood classification (class 1–6), n (%)

Class 1	Class 2	Class 3	Class 4	Class 5	Class 6
16 (1)	835 (54.5)	134 (8.8)	113 (7.4)	56 (3.6)	5 (0.3)

In class 1, the foramen was positioned lingually in all samples ( $n = 10$ ; below the alveolar limbus). In class 2, the foramen was also on the lingual side in all 10 samples (100% lingual), only a few millimeters below the alveolar limbus.

The position of the foramen started to change in class 3, whereby the total height of the alveolar crest was not significantly different, but the entrance of the artery was on top of it. Forty percent ( $n = 4$ ) of the foramina entered lingually and 60% ( $n = 6$ ) cranially. Therefore, the vessel entered top down into the mandible compared with classes 1 and 2.

In class 4, this trend continued as the alveolar crest gained its knife-edge form. The position of the medial lingual nutritional foramen remained on top of the mandibular bone in 80% ( $n = 8$ ) of samples, but in 20% ( $n = 2$ ) of the samples, the entrance of the vessel was labial.

The medial lingual nutritional foramen was labial in only 10% of the samples ( $n = 1$ ), whereas 90% ( $n = 9$ ) presented a cranial foramen. When comparing classes 3, 4, and 5, a strong contrast was recognizable in the height of the alveolar crest and the position of the foramen.

Class 6 showed the most severe atrophy. The position of the medial lingual nutritional foramen was on top of the remaining alveolar crest and was labial in all samples ( $n = 5$ ).

The changing position of the medial lingual nutritional foramen in regard to the Atwood classification class is shown in Figure 3. Overall distribution ( $n = 55$ ) of the position of the foramen was lingual in 47.3% of the samples, cranial in 38.2%, and labial in 14.5%.

Two variables were of special interest for this investigation to prove the changing position of the medial lingual nutritional foramen: the distance from the lingual border to the medial lingual nutritional foramen ( $c$ ) and the distance from the medial lingual nutritional foramen to the caudal border ( $e$ ).

First, both variables were analyzed exploratively regarding the position of the foramen (lingual,

cranial, labial). After this, an analysis of variance was applied. In its simplest form analysis of variance indicates whether or not the means of several groups are equal. It generalizes a  $t$  test to more than 2 groups. Doing multiple 2-sample  $t$  tests would result in an increased chance of a type I error.

The results showed that variable  $c$  increased from lingual to labial (mean lingual = 1.59 mm; mean cranial = 3.71 mm; mean labial = 5.5 mm; Figure 4). Factor of the variance analysis for variable  $c$  was the Atwood class (1–6). Mean values increased from Atwood class 1 (lowest; mean = 1.66 mm) to class 6 (highest; mean = 5.7 mm). Variable  $c$  showed a significance of 0.00 between the 6 groups of atrophy, which proved the hypothesis to be wrong in that this variable would be equal in all 6 classes. The mean values for each single Atwood class for variable  $c$  are shown in Figure 6.

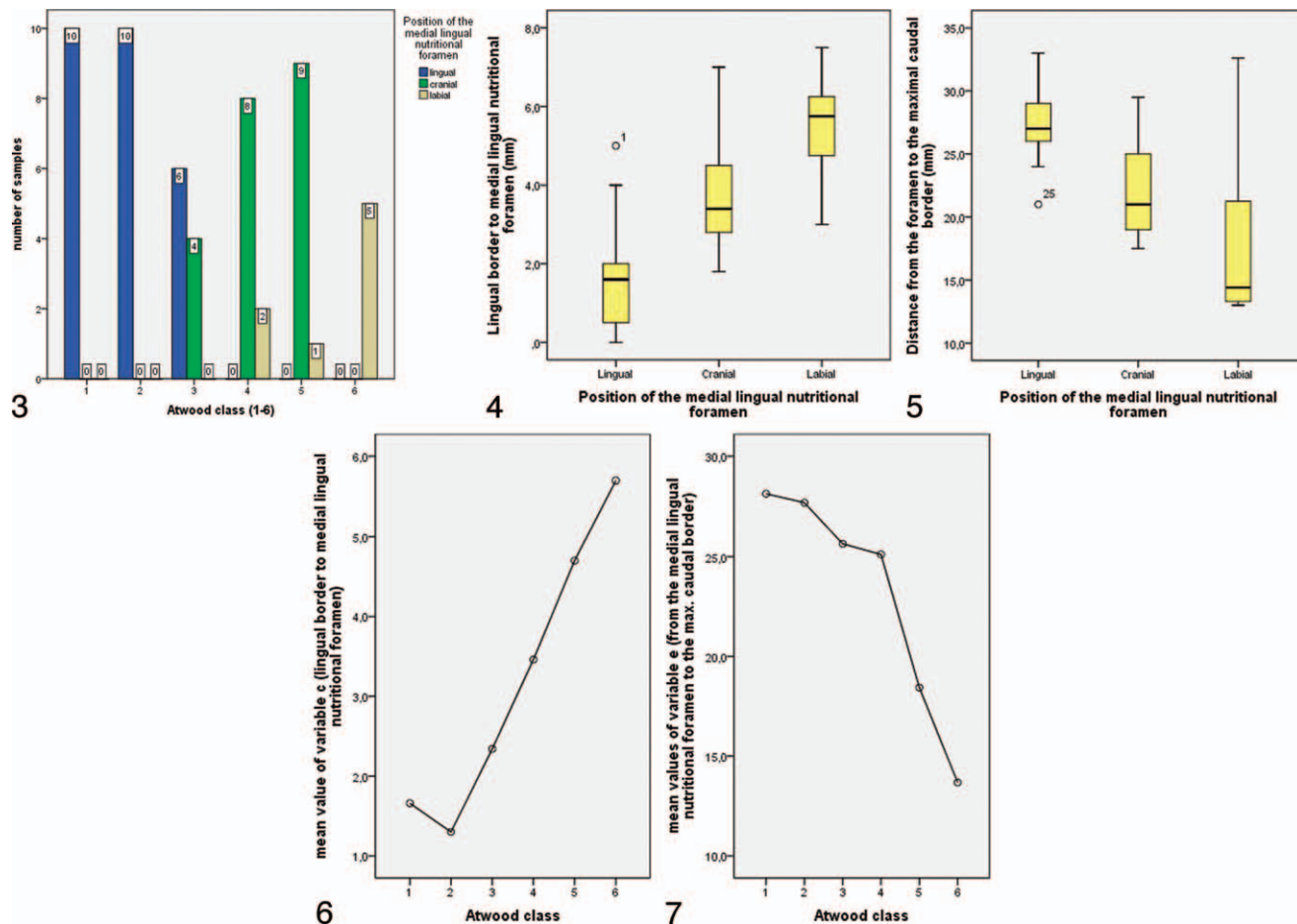
Variable  $e$  decreases in height from lingual to labial (mean lingual = 27.32 mm; mean cranial = 22.14 mm; mean labial = 17.94 mm; Figure 5). Factor of the variance analysis for variable  $e$  was the Atwood class. It showed a decrease in mean values from class 1 (highest; mean = 28.15 mm) to class 6 (lowest; 13.68 mm). Variable  $e$  also presented with a significance of 0.00 for the 6 Atwood classes. The mean values of variable  $e$  for each single Atwood class are presented in Figure 7.

Therefore, neither variable  $c$  nor variable  $e$  had a similar mean value in all 6 classes of atrophy. This implies that each single Atwood class has a unique mean value.

Both variables were tested for normal distribution with the Shapiro-Wilk tests and presented in Q-Q diagrams. Neither variable  $c$  (significance 0.026) nor variable  $e$  (significance 0.007) presented with a normal distribution.

## DISCUSSION

In the current study, the presence of the medial lingual nutritional foramen was shown in all 1532 cadaveric mandibles. Those mandibles allowed no



**FIGURES 3–7. FIGURE 3.** Changing position of the medial lingual nutritional foramen (lingual/cranial/labial) in regard to the Atwood classification class 1–6. **FIGURE 4.** The distance from the labial border to the medial lingual nutritional foramen increases from lingual to labial. **FIGURE 5.** The height decreases from the caudal border to the medial lingual nutritional foramen from lingual to labial. **FIGURE 6.** Mean values for each single Atwood class for the distance between the lingual border and the medial lingual nutritional foramen. **FIGURE 7.** Mean values for each single Atwood class for the distance between the caudal border and medial lingual nutritional foramen.

differentiation in gender or races, although such might occur. The presence of the foramen is in agreement with the reports of Rosano et al<sup>9</sup> (100% of the mandibles investigated), Liang et al<sup>7</sup> (98%), and Suzuki and Sakai.<sup>10</sup> Therefore, it is demonstrated that this anatomic structure should be considered during surgery to avoid injury of vessels in the mandibular midline region, especially during implant placement. Preventing a complication requires preoperative planning of the surgical procedures concerning the median mandible, consideration of the degree of osseous atrophy and radiographic identification of those foramina, adequate surgical training, precise knowledge of loco-regional anatomy, and careful positioning of the implants at the mandibular midline.<sup>9</sup>

The blood supply to the interforaminal region of

the mandible is provided by the inferior alveolar artery (a branch of the maxillary artery) and the sublingual artery (a branch of the lingual artery). The medial and lateral interalveolar arteries are branches of the sublingual artery.

The inferior alveolar artery enters at the mandibular foramen and supplies the teeth, mucosa, bone, and soft tissue. The interalveolar arteries enter the mandible via small bony foramina.

The sublingual artery supplies the sublingual gland, mucosa, muscles, and gingival. It divides into 2 branches: a descending branch and an ascending branch. The ascending branch divides into a medial branch, which enters the bone between the incisors via the medial lingual nutritional foramen, and a lateral one, which enters the mandible between the lateral incisor and canine via the lateral lingual

nutritional foramen (also called the interalveolar foramen by Krenkel et al<sup>11</sup> and Tsusaki et al<sup>3</sup>). The medial lingual nutritional foramina and the supra-, inter- and subspinal foramina were first described by Tsusaki et al<sup>3</sup> in 1935. Suzuki and Sakai<sup>10</sup> described how the medial and lateral interalveolar arteries move in a cranial direction and reach the alveolar crest 4.0 mm above the alveolar limbus. Kamijo<sup>12</sup> confirmed the existence of the medial lingual nutritional foramina with anatomic studies. Krenkel et al<sup>11</sup> described the common sites of bony foramen on the lingual mandible in an investigation of 100 dry specimens. The medial interalveolar artery was found on the right side of the mandible in 81% of specimens and on the left side in 83%. The lateral interalveolar artery was only found on the right side in 6% of specimens and on the left side in 14%. All of these investigations were carried out on mandibles with teeth or partial loss of teeth rather than on mandibles with different grades of atrophy.

Different classifications exist to categorize the grade of mandibular atrophy. In this investigation, the Atwood<sup>8</sup> classification for the anterior mandible was applied to assess the grade of atrophy, although Cawood and Howell<sup>13</sup> differentiate between the anterior and posterior mandible. It was striking that only 5 (0.3%) mandibles belonged to Atwood class 6, although the overall population contained 1532 mandibles. The number of mandibles in Atwood class 1 was also very small at only 16 (1%). Teeth were most likely lost over time, during transport, or due to rearrangements in the charnel house, particularly as some of the samples were more than 100 years old. In contrast, class 2 counted for more than half of the samples (n = 835; 54.5%).

The position of the medial lingual nutritional foramen varied with the grade of Atwood class (Figure 3): class 1 (dentate mandible) and class 2 (immediately after extraction) presented a lingual foramen (n = 20, 100% lingual). Conditions changed with class 3 (high, well-rounded ridge form): 60% (n = 6) of the foramina entered the mandible cranially and only 40% (n = 4) lingually. In class 4 (knife-edge ridge form) the lingual position of the foramen had disappeared: 80% (n = 8) of the foramina were cranial and already 20% (n = 2) were labial. Class 5 (low, well-rounded ridge form) had the most cranial foramina at 90% (n = 9);

only 1 foramen was labial. All specimens in class 6 (depressed ridge form) presented with a labial foramen (n = 5, 100%).

As mentioned earlier, 2 variables were used to describe the altering position of the medial lingual nutritional foramen statistically: the distance from the lingual border to the medial lingual nutritional foramen (c) and the distance from the medial lingual nutritional foramen to the caudal border (e). Investigations showed that the distance from the lingual border to the foramen increased with the increasing class of atrophy with means of 1.59 mm (lingual), 3.71 mm (cranial), and 5.5 mm (labial). Atwood class 1 presented the smallest mean value, whereas class 6 presented the largest mean value. This suggests that the foramen shifts from its lingual position to a cranial one and finally lies labially.

Variable e presented the altering position of the foramen in height with means of 27.32 mm (lingual), 22.14 mm (cranial), and 17.94 mm (labial). Rosano et al<sup>9</sup> found that the mean distance of the foramina from the base of the mandible was  $12.5 \pm 2.1$  mm. Vandewalle et al<sup>6</sup> and Liang et al<sup>7</sup> presented an identical mean value of 10.6 mm above the inferior mandibular border. Suzuki and Sakai<sup>10</sup> reported an average distance of 5 mm. A comparison of all 6 Atwood classes showed that class 1 had the largest mean value, whereas class 6 presented the smallest mean value. This shows that the height of the foramen decreases with the increasing class of atrophy.

An issue caused by the plaster models was that the diameter of the metal pellet was too small at 0.7–1.0 mm. Additionally, the surface tension of the plaster was too high, causing the small cavities of silicone to be completely (100%) filled with plaster. Therefore, precision was possibly slightly reduced due to plaster expansion.

The wet specimen showed a clear medial and lateral interalveolar artery, the arteries presenting with a sudden change of caliber at this short distance. The left medial interalveolar artery attracted attention because of its meandering course, which has been described in the literature for various vessels, such as the mesenteric artery (Moskowitz artery)<sup>14</sup> or the laryngeal arteries.<sup>15</sup> But those vessels do not affect the condition of changing bone, like the mandible does when teeth are lost.

To start, vessels run in the mandibular bone, but bone height is reduced in the edentulous mandible and there is no possibility for the load-bearing skeletal organs to adapt to the voluntary mechanical loads on them.<sup>16</sup> This causes the mandibular bone to degrade and leads to variation in the position of the medial lingual nutritional foramen from lingual to cranial and finally labial, depending on the Atwood grade.

Interalveolar vessels can be easily damaged during surgical procedures because they are difficult to prepare due to the fibrous connective tissue surrounding them and their fine structure. Intraoperative complications related to surgery include hemorrhages, neurosensory alterations, damaged teeth adjacent to the implant, and mandibular fractures.<sup>17-21</sup> A hematoma of the floor of the mouth is a rare but potentially life-threatening condition that requires immediate treatment. It can even lead to a very serious airway obstruction.<sup>11,18,20,21</sup> An acute hemorrhage is controlled by strong finger pressure at the point of bleeding, infiltration by a vasoconstrictor, or ligation.<sup>11,17-21</sup> Aspiration or drainage is not recommended as it can increase the bleeding and limit the self-tamponading action by the hematoma itself.<sup>17</sup>

Besides sufficient surgical training and anatomic knowledge, preventive measures to avoid such hemorrhages include preoperative assessment of osseous morphology on imaging and physical examination, with a special focus on the grade of atrophy. Thus, surgeons should keep in mind that the grade of atrophy correlates with the position of the medial lingual nutritional foramina.

## REFERENCES

1. Reich KM, Huber CD, Lippnig WR, Ulm C, Watzek G, Tangl S. Atrophy of the residual alveolar ridge following tooth loss in an historical population. *Oral Dis*. 2011;17:33-44.
2. Sakka S, Krenkel C. Hemorrhage secondary to interforaminal implant surgery: anatomical considerations and report of a case. *J Oral Implantol*. 2011;39:603-607.
3. Tsusaki T, Nishiyama Y, Kuwayama K. *Zahnärztliche Anatomie*. Tokyo, Japan: Kanehara-Shoten; 1935.
4. Tagaya A, Matsuda Y, Nakajima K, Seki K, Okano T. Assessment of the blood supply to the lingual surface of the mandible for reduction of bleeding during implant surgery. *Clin Oral Implants Res*. 2009;20:351-355.
5. McDonnell D, Reza NM, Todd ME. The mandibular lingual foramen: a consistent arterial foramen in the middle of the mandible. *J Anat*. 1994;184(pt 2):363-369.
6. Vandewalle G, Liang X, Jacobs R, Lambrichts I. Macroanatomic and radiologic characteristics of the superior genial spinal foramen and its bony canal. *Int J Oral Maxillofac Implants*. 2006;21(4):581-586.
7. Liang X, Jacobs R, Lambrichts I, Vandewalle G. Lingual foramina on the mandibular midline revisited: a macroanatomical study. *Clin Anat*. 2007;20:246-251.
8. Atwood DA. Reduction of residual ridges: a major oral disease entity. *J Prosthet Dent*. 1971;26:266-279.
9. Rosano G, Taschieri S, Gaudy JF, Testori T, Del FM. Anatomic assessment of the anterior mandible and relative hemorrhage risk in implant dentistry: a cadaveric study. *Clin Oral Implants Res*. 2009;20:791-795.
10. Suzuki M, Sakai T. The foramina of the lingual surface of the mandible in the Japanese. *Med J Shinshu Univ*. 1957;2:1-10.
11. Krenkel C, Holzner K, Poisel S. Hematoma of the mouth floor following oral surgery and its anatomical characteristics [in German]. *Dtsch Z Mund Kiefer Gesichtschir*. 1985;9:448-451.
12. Kamijo Y. The foramina on the lingual incisive region of the mandible in the Japanese in the Kyushu District. *Shikagaku Zasshi*. 1950;7:52-55.
13. Cawood JI, Howell RA. A classification of the edentulous jaws. *Int J Oral Maxillofac Surg*. 1988;17:232-236.
14. Gourley EJ, Gering SA. The meandering mesenteric artery: a historic review and surgical implications. *Dis Colon Rectum*. 2005;48:996-1000.
15. Iimura A, Itoh M, Terayama H, et al. Anatomical study of meandering and functions of human intralaryngeal artery. *Okajimas Folia Anat Jpn*. 2004;81(5):85-92.
16. Frost HM. From Wolff's law to the Utah paradigm: insights about bone physiology and its clinical applications. *Anat Rec*. 2001;262:398-419.
17. Del Castillo-Pardo de Vera JL, Lopez-Arcas Calleja JM, Burgueno-Garcia M. Hematoma of the floor of the mouth and airway obstruction during mandibular dental implant placement: a case report. *Oral Maxillofac Surg*. 2008;12:223-226.
18. Isaacson TJ. Sublingual hematoma formation during immediate placement of mandibular endosseous implants. *J Am Dent Assoc*. 2004;135:168-172.
19. Kalpidis CD, Konstantinidis AB. Critical hemorrhage in the floor of the mouth during implant placement in the first mandibular premolar position: a case report. *Implant Dent*. 2005;14:117-124.
20. Weibrich G, Foitzik C, Kuffner H. Life threatening oral hemorrhage after implantation into the distal right mandible [in German]. *Mund Kiefer Gesichtschir*. 2002;6:442-445.
21. Lamas PJ, Penarrocha DM, Marti BE, Penarrocha DM. Intraoperative complications during oral implantology. *Med Oral Patol Oral Cir Bucal*. 2008;13:E239-E243.