

Active Implant Peri-Apical Lesion: A Case Report Treated Via Guided Bone Regeneration With a 5-Year Clinical and Radiographic Follow-Up

Alessandro Quaranta, DDS, PhD^{1*}

Sebastiano Andreana, DDS, MS²

Giorgio Pompa, MD, DDS³

Maurizio Procaccini, MD, DDS⁴

Implant peri-apical lesion (IPL) is a periapical lesion, usually asymptomatic, in which the coronal portion of the implant achieves a normal bone to implant interface. A case of IPL following immediate implant placement and treated with guided bone regeneration (GBR) principles is described. Five-year clinical and radiographic follow-up with cone-beam assessment showed complete healing of the bone. GBR principles applied to IPL could completely solve the lesion.

Key Words: dental implant, implant peri-apical lesion, retrograde peri-implantitis, GBR

INTRODUCTION

Implant peri-apical lesion (IPL) or retrograde peri-implantitis is defined as a rapid infective, clinically asymptomatic periapical lesion radiographically diagnosed as a radiolucency in which the coronal portion of the implant achieves a normal bone to implant interface.¹ This condition was first described by McAllister et al² who suggested that microbial involvement from the implant site, the extracted teeth or adjacent teeth, generation of excess bone heat during implant placement and premature loading from inadequate relief of interim prostheses are probable causes for the development of such condition. It has been

reported that maxillary premolars are usually more prone to periapical lesions.^{1,3}

IPL usually develops shortly after implant placement and it is further classified into inactive (noninfected) or active (infected) condition, depending on the presence or absence of symptoms.

Infected IPL has been linked to fistula formation, persistent local inflammation, and tenderness, whereas inactive IPL resembles a radiographic dense collagen apical scar.²

Information on the incidence as well as clinical decision-making guidelines regarding treatment of retrograde peri-implantitis are scarce in the literature, and mostly collected from clinical reports.²⁻⁷

In fact, several surgical treatment options have been proposed as different approaches for its treatment.

In a study by Quirynen et al,³ among single implants placed at the university facilities those affected by retrograde peri-implantitis were diagnosed with radiographic evaluation and subsequently treated with a surgical approach.

The implants under evaluation showed different surface features (machined or Ti-Unite) and were followed prospectively via intra-oral parallel tech-

¹ School of Dentistry, Università Politecnica delle Marche, Ancona, Italy; previously with Department of Prosthodontics and Implant Dentistry, University of Rome "La Sapienza," Rome, Italy.

² School of Dental Medicine, University at Buffalo, Buffalo, NY.

³ Department of Prosthodontics and Implant Dentistry, University of Rome "La Sapienza," Rome, Italy.

⁴ School of Dentistry, Università Politecnica delle Marche, Ancona, Italy.

* Corresponding author, e-mail: s40ale@gmail.com

DOI: 10.1563/AAID-JOI-D-11-00214

nique radiographs. The incidence of retrograde peri-implantitis was significantly higher ($P < 0.0001$) for rough surface implants when compared to the machined implants (8/80 vs 2/459). Changes in the marginal bone level and progression of the extension of the apical lesion were considered. Implant threads were used as a reference to monitor bone lesion; the biomechanical stability was scored by means of the Periotests device. The surgical treatment for retrograde lesions in the upper jaw consisted in elevation of a full-thickness flap, complete removal of all accessible granulation tissue with hand instruments and curettage of the bony cavity walls. In half of the defects, deproteinized bovine bone mineral was used as a bone substitute (at the decision of the surgeon), while the other defects were left empty. In the lower jaw, an explorative flap mostly revealed an absence of cortical perforation so that trepanation of the bone had to be performed in order to reach the lesion. Most of these interventions were performed on patients under antibiotic coverage (b-lactamase-resistant penicillin).

Most lesions healed uneventfully and changes in marginal bone height were minimal. When the treatment did not arrest the progression of the lesion, the implant was lost.

Park et al⁵ described two case reports regarding the successful management of rapidly developing periapical lesions related to retained root tips.

In the first case, the lesion was the result of an undetected retained root tip. Initially, systemic antibiotics failed to subdue the infection. A retained root fragment was retrieved surgically, together with the implant, and a new wide-body implant was placed with demineralized freeze-dried bone allograft mixed with tetracycline. A 5-month follow-up evaluation showed increased radiographic density and clinical re-entry revealed the formation of bone with a hard consistency. The second case demonstrated the management of a retained root tip via guided bone regeneration.

A recent case report by Lin and Mayer⁶ described the healing of a large periradicular lesion involving an adjacent implant. Endodontic surgery including root end resection at a 90° angle was performed in combination with placement of an enamel matrix protein derivative.

Ultrasonic tips were used for retrograde prepara-

tion, and the retrograde cavity was sealed with zinc oxide–eugenol. The area was filled carefully with enamel matrix proteins. At 18 months post-surgery evaluation, patient did not report symptoms of pain, or discomfort; absence of inflammation was reported and the radiographs showed complete healing of the periradicular lesion.

Ayangco et al presented a series of reports describing the occurrence and management of retrograde peri-implantitis for implants that replaced teeth with histories of failed endodontic and apicectomy procedures.⁷ A combination of systemic and/or local antibiotics with surgical debridement appeared to be a successful approach in the treatment of these cases.

Flanagan⁸ treated a case of IPL with surgical debridement and a paste of calcium hydroxide mixed with water and without implant surface detoxification. This intervention resulted in resolution of the associated signs and symptoms of infection. A periapical radiograph 11 months after the apical procedure showed radiographic resolution of the apical lesion; however, the presence of barium sulfate used in the preparation was radiographically noted.

In summary, the literature supports a surgical approach that may include debridement only or autologous bone grafts, xenografts, or alloplastic material with or without the use of membrane barriers.^{2,3–9} The concept of guided bone regeneration (GBR) based on Dahlin's original article utilizes barrier membranes in order to differentiate cell growth.^{10,11} This procedure advocates that regeneration of osseous defects is predictably attainable through the application of occlusive membranes, which mechanically exclude nonosteogenic cell populations from the surrounding soft tissues, thereby allowing osteogenic cell populations originating from the parent bone to inhabit osseous wound.¹²

When GBR principles are applied in periapical surgeries, it has been demonstrated to yield good results in terms of shortening the healing time as well as increasing the amount of bone fill.^{13,14} Since healing is less favorable in large periapical defects,^{15,16} the adoption of a membrane might be beneficial in these situations. The present case report describes the treatment of an active implant peri-apical lesion following GBR principles.

CASE REPORT

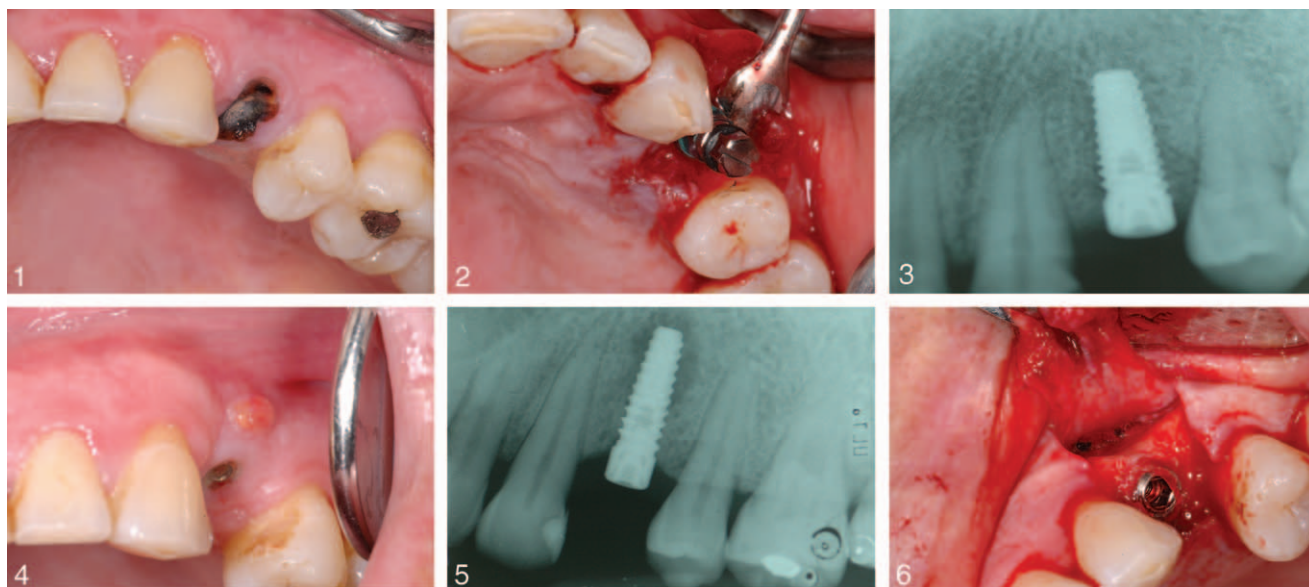
A 43-year-old woman presented to our attention with a symptomatic maxillary left first premolar (tooth #12). She had a history of type II diabetes and was being treated for chronic periodontitis. She had been following a hypoglycemic agent's therapy for 8 years. At the time of our initial assessment, glycemic and HBA1c values were considered compatible with well-controlled diabetes. At her last medical exam, a month prior to our evaluation her physician deemed her medical condition stable, thus making her a candidate for dental implant treatment. She denied any allergies to medications or foods. An immediate post-extractive implant was planned (Figure 1). Intrасulcular and vertical incisions were made to raise a mucoperiosteal flap extending over the mucogingival junction. The premolar was gently extracted and the socket carefully curetted. The surgical site was prepared according to standard procedures using drills in the center of the socket with maximum use of bone apical to the removed tooth. The implant osteotomy was completed under copious saline irrigation at 400; a 3.75 × 11 mm implant (Kohno Sweden and Martina, Italy) was placed according to the manufacturer indications (Figure 2).

The flap was then repositioned to obtain a primary wound closure and sutured with mattress and interrupted resorbable sutures (Vicryl 4.0, Ethicon, Cincinnati, Ohio). An immediate post-operative radiograph was taken (Figure 3). The patient was prescribed penicillin, 1000 mg, three times a day for 7 days, and nimesulide for postsurgical management. Three months following implant placement the patient was seen for pain at the implant site. Following our assessment, it was observed the formation of a sinus tract on the facial aspect of the implant (Figure 4). The sinus tract was associated with localized mild pain and tenderness. A radiograph also revealed a periapical radiolucency on the implant (Figure 5). The patient was prescribed penicillin, 1000 mg, three times a day for 7 days, and nimesulide and 4 days later, returned for definitive treatment. A full-thickness flap was elevated buccally. Vertical releasing incisions were made and a large formation of granulation tissue was noted at the apex of the implant (Figure 6). The granulation tissue was removed with plastic and stainless steel hand instruments (Figure 7). A tetracycline paste (250 mg powder mixed with

sterile water to form a paste) was placed into the defect and around the implant and left for approximately 3 minutes. The area was then rinsed and irrigated copiously with sterile saline solution. A bioabsorbable pericardium membrane (AudioMesh Neuro, Audio Technologies Srl, Piacenza, Italy) was placed over the defect (Figure 8). After final rinsing of the defect, the flap was repositioned and sutured with resorbable sutures (Vicryl 5.0, Ethicon). A 1-month follow-up visit revealed absence of signs of infection and the patient did not report any pain or discomfort at the treated site. A provisional cement-retained single crown was delivered after an additional one month of follow-up and the final restoration was placed on the abutment 6 months following the implant placement. At 1-year follow-up, the patient reported an uneventful healing with no new or further symptoms. A periapical radiograph of the area showed new bone formation at the apical region of the implant. The patient was seen periodically to monitor the area. Peri-apical radiographs, cone-beam exam and clinical assessment performed 5 years after the implant placement revealed complete bone fill into the previous lesion area and continuous stable bone levels around the implant (Figures 9–11). Mobility was not detected at any time.

DISCUSSION

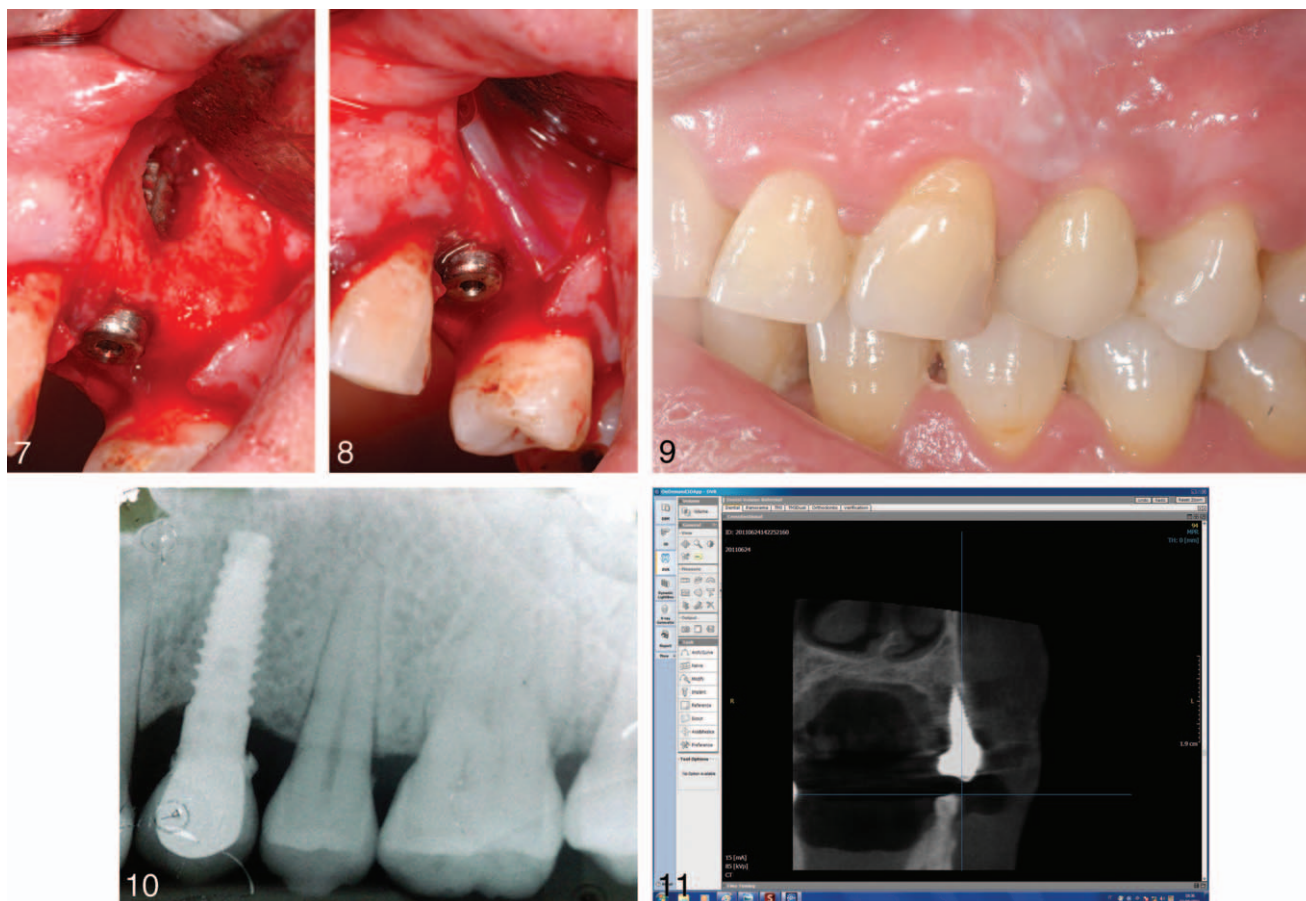
IPL appears to be a rare disorder; in fact, Reiser and Nevins⁴ reported 10 cases among 3800 implants placed (0.26%). Retrograde peri-implantitis should be differentiated from a clinically asymptomatic peri-apical radiolucency, in that the latter could be the result of placing implants that are shorter than the drilled cavity or by a heat-induced aseptic bone necrosis.^{2,4,7} Retrograde peri-implantitis should also be distinguished from nonintegration which occurs when the apex of the implant touches an adjacent root and/or when the implant is inserted in an active endodontic lesion of an adjacent tooth. Under the latter conditions, the implant often exfoliates spontaneously or becomes mobile, resulting in nonintegration.⁴ IPL can develop as result of bacterial contamination during insertion, premature loading leading to bone microfractures, or presence of a pre-existing inflammation (bacteria, inflammatory cells, and/or remaining cells from a cyst, granuloma).² Such lesions start at the implant



FIGURES 1–6. **FIGURE 1.** Pre-operative clinical view. **FIGURE 2.** Implant immediately placed in the postextraction socket. **FIGURE 3.** Peri-apical radiograph immediately after implant placement. **FIGURE 4.** Clinical view three months following the implant placement. It is possible to observe the formation of a sinus tract on the facial aspect of the implant. **FIGURE 5.** A peri-apical radiolucency on the implant was evident. **FIGURE 6.** Full thickness flap was raised and granulation tissue was noted at the apex of the implant.

apex but exhibit the ability of spreading coronally, proximally, and facially. Implants with enhanced surface characteristics have been introduced to accelerate the osseointegration process. Several studies have indeed confirmed a more rapid bone formation and implant surface contact as well as a high implant survival rate.^{17–20} Although these types of implants clearly demonstrated a higher success rate, a higher incidence of retrograde peri-implantitis has also been reported when compared to the machined titanium surface.⁹ Furthermore, some authors suggested that IPL could also develop from a latent onset of endodontic lesion from the adjacent teeth. This has been attributed to either violation of the biologic width, thus devitalizing the adjacent tooth, or the approximation of the implant within 2 mm of the developing endodontic plaque front.⁵ Therefore, if this is the case, immediate root canal treatment of the adjacent tooth is recommended to prevent the diffusion of the latent endodontic infection onto the implant. However, when the IPL appears to occur independently from the adjacent tooth, as presented in our case, the management of the infection around the implant alone would suffice. It has been suggested that IPL resembles peri-implantitis in that both are site-specific infective processes.⁵ The main differences,

however, lie in the microbial composition, rate of expansion, and pathway of the infection. Microorganisms found in peri-implantitis are closely associated with periodontal pathogens, whereas those found in IPL resemble the composition of endodontic pathogens.⁷ Once diagnosis of the IPL has been confirmed, early surgical (within 1 month of IPL onset) intervention, preferably within 1 month of IPL onset, could limit the extent of disease progression and thus resulting in possibly saving the implant.⁵ Aggressive and prompt management of the affected site is necessary if resolution of the pathologic process and salvage of the implant are to be achieved.⁶ Surgical approach is aimed at the removal of inflamed granulation tissue and cleaning the implant surfaces from bacteria colonization. The bone housing the defect should be thoroughly debrided to completely eliminate the necrotic tissues. Debridement is accomplished using conventional stainless steel surgical instruments, which have been shown not to raise concern about scratching or roughening of the titanium at the apical portion of the implant.⁶ The affected area should also be detoxified by chemical means to further remove endotoxins and other surface contaminants. Several chemical techniques using citric acid, chlorhexidine gel, tetracycline, and/or



FIGURES 7–11. **FIGURE 7.** The granulation tissue was completely removed. **FIGURE 8.** A bioabsorbable membrane was placed over the defect. **FIGURE 9.** Peri-apical radiograph after 5 years the implant placement showed new bone formation at the apical region of the implant. **FIGURE 10.** Clinical view 5 years after the implant placement. **FIGURE 11.** Cone-beam assessment confirmed new bone formation at the apical region of the implant.

hydrogen peroxide have been proposed to disinfect the implant surfaces. Tetracycline has been suggested to be effective in the detoxification of infected implant surfaces.⁷ Following surgical treatment, the patient should be treated with systemic antibiotics for 7 to 10 days. The GBR therapeutic protocol involves surgical placement of a cell occlusive membrane facing the bone surface in order to physically seal off the skeletal site in need of regeneration.⁸ Furthermore, the membrane creates and maintains a secluded space thus providing an environment for the osteoprogenitor cells; this environment is permissive for recruitment and proliferation of osteoprogenitor cells, differentiation along the osteoblastic lineage and expression of osteogenic activity.^{23,24} A plethora of non-resorbable and resorbable membrane materials have been used in experimental and clinical studies in the context of GBR treatment. The desirable

characteristics of barrier membranes utilized for GBR therapy include biocompatibility, cell occlusion properties, integration by the host tissues, clinical manageability and space making ability.¹² However, controversy about the use of membrane and bone substitutes in the treatment of IPL still exists. Some authors stated that there is no need for grafting or placing a membrane.^{7,8} Most case reports describe the use of either bone graft alone or in conjunction with absorbable membranes, as fibrous connective tissue may form in the defect. Park used a bone substitute to prevent membrane collapse and create the space needed for bone ingrowth.⁵ However, in the present case report the morphology of the defect looked retentive and, based on the principles of GBR, we decided not to use any graft. Our experience on GBR application in both implant and endodontic surgery suggests that the use of biodegradable membranes may provide

dramatic advantages. In fact, the membrane can maintain the space and prevent soft tissue from repopulating the defect. Furthermore, it has been demonstrated that the use of bone regeneration materials for apicectomy surgeries improves the predictability of clinical, radiographic and histological healing.¹⁶

Osseointegration is defined as the histologic observation of direct contact between bone and implant material.²⁵ On a daily clinical basis it is not possible to subject a patient to histological analysis in order to confirm osseointegration. Therefore, from the clinical point of view, an implant can be considered osseointegrated if deemed to be a nonmobile implant that features an ankylosis in the bone.²⁶

In this case report, the radiographic exams (periapical and cone beam evaluation) at 5-year follow-up showed a complete resolution of the peri-apical lesion.

Moreover, the clinical parameters assessed included implant mobility evaluation, completely fulfilled the criteria for implant success.²⁷ Consequently, it may be speculated that, in the present report, an intimate contact between the bone and the implant surface in the area of a previous periapical lesion has been developed. However, these clinical and radiographic observations cannot be considered as signs of some degree of osseointegration which may only be confirmed through an invasive histological analysis.

CONCLUSIONS

To the best of our knowledge this is the only clinical case reported in literature of treated IPL with 5-year clinical and radiographic follow-up. IPL is a preventable disease provided that a careful planning, including a proper history of the edentulous site, multiple radiographic assessments and evaluation of the adjacent teeth, is performed. However, once IPL is initiated, early surgical intervention should take place within 1 month of onset to limit the extent of disease progression. A case of IPL that was successfully treated with surgical debridement and GBR principles has been presented. Five years' clinical and radiographic controls, including cone-beam analysis, showed complete healing of the bone defect.

ABBREVIATIONS

GBR: guided bone regeneration

IPL: implant periapical lesion

REFERENCES

1. Quirynen M, Gijbels F, Jacobs R. An infected jawbone site compromising successful osseointegration. *Periodontol* 2000. 2003; 33:129–144.
2. McAllister BS, Masters D, Meffert RM. Treatment of implants demonstrating periapical radiolucencies. *Pract Periodontics Aesthet Dent*. 1992;4:37–41.
3. Eriksson AT, Albrektsson B, Crane B, et al. Thermal injury to bone. *Int J Oral Surg*. 1982;11:115–121.
4. Reiser GM, Nevins M. The implant periapical lesion: Etiology, prevention, and treatment. *Compend Contin Educ Dent*. 1995;16:768–772.
5. Park SH, Sorensen WP, Wang HL. Management and prevention of retrograde peri-implant infection from retained root tips: two case reports. *Int J Periodontics Restorative Dent*. 2004;24: 422–33.
6. Lin S, Mayer Y. Treatment of a large periradicular lesion of endodontic origin around a dental implant with enamel matrix protein derivative. *J Periodontol*. 2007;78:2385–2388.
7. Ayangco L, Sheridan PJ. Development and treatment of retrograde peri-implantitis involving a site with a history of failed endodontic and apicoectomy procedures: a series of reports. *Int J Oral Maxillofac Implants*. 2001;16:412–417.
8. Flanagan D. Apical (retrograde) peri-implantitis: a case report of an active lesion. *J Oral Implantol*. 2002;28:92–96.
9. Quirynen M, Vogels R, Alsaadi G, Naert I, Jacobs R, van Steenberghe D. Predisposing conditions for retrograde peri-implantitis, and treatment suggestions. *Clin Oral Implants Res*. 2005;16:599–608.
10. Dahlin C, Linde A, Gottlow J, Nyman S. Healing of bone defects by guided tissue regeneration. *Plast Reconstr Surg*. 1988; 81: 672–676.
11. Dahlin C, Sennerby L, Lekholm U, Linde A, Nyman S. Generation of new bone around titanium implants using a membrane technique an experimental study in rabbits. *Int J Oral Maxillofac Implants*. 1989;4:19–25.
12. Retzepi M, Donos N. Guided bone regeneration: biological principle and therapeutic applications. *Clin Oral Implants Res*. 2010; 21:567–576.
13. Pecora G, Kim S, Celletti R, Davarpanah M. The guided tissue regeneration principle in endodontic surgery: one-year postoperative results of large periapical lesions. *Int Endod J*. 1995; 28:41–46.
14. Hirsch JM, Ahlstrom U, Henrikson PA, Heyden G, Peterson LE. Periapical surgery. *Int J Oral Surg*. 1979;8:173–185.
15. Rud J, Andreasen JO, Jensen JF. A multivariate analysis of the influence of various factors upon healing after endodontic surgery. *Int J Oral Surg*. 1972;1:258–271.
16. Dietrich T, Zunker P, Dietrich D, Bernimoulin JP. Periapical and periodontal healing after osseous grafting and guided tissue regeneration treatment of apico-marginal defects in periradicular surgery: results after 12 months. *Oral Surg Oral Med Oral Pathol Oral Radiol Endod*. 2003;95:474–482.
17. Lazzara RJ, Testori T, Trisi P, Porter SS, Weinstein RL. A human histologic analysis of osseotite and machined surfaces using implants with 2 opposing surfaces. *Int J Periodontics Restorative Dent*. 1999;19:117–129.
18. Khang W, Feldman S, Hawley CE, Gunsolley J. A multi-center study comparing dual acid-etched and machined-surfaced

implants in various bone qualities. *J Periodontol*. 2001;72:1384–1390.

19. Coelho PG, Cardaropoli G, Suzuki M, Lemons JE. Early healing of nanothickness bioceramic coatings on dental implants. An experimental study in dogs. *J Biomed Mater Res B Appl Biomater*. 2009;88:387–393.

20. Albrektsson T, Wennerberg A. Oral implant surfaces: Part 2—review focusing on clinical knowledge of different surfaces. *Int J Prosthodont*. 2004;17:544–564.

21. Schaffer MD, Junuaz DA, Haggerty PC. The effect of periradicular endodontic pathosis on the apical region of adjacent implants. *Oral Surg Oral Med Oral Pathol Oral Radiol Endod*. 1998;86:578–581.

22. Shabang S, Bohsali K, Caplanis N, Torabinejad M. Effects of periradicular lesions on osseointegration of dental implants. *Endod*. 2001;27:220–227.

23. Linde A, Thorén C, Dahlin C, Sandberg E. Creation of new bone by an osteopromotive membrane technique: an experimental study in rats. *J Oral Maxillofac Surg*. 1993;51:892–897.

24. Karring T, Nyman S, Gottlow J, Laurell L. Development of the biological concept of guided tissue regeneration—animal and human studies. *Periodontol*. 2000. 1993;1:26–35.

25. Brånemark PI, Adell R, Breine U, Hansson BO, Lindström J, Ohlsson A. Intra-osseous anchorage of dental prostheses. I. Experimental studies. *Scand J Plast Reconstr Surg*. 1969;3:81–100.

26. Albrektsson T, Zarb GA. Current interpretations of the osseointegrated response: clinical significance. *Int J Prosthodont*. 1993;6:95–105.

27. Albrektsson T, Zarb G, Worthington P, Eriksson AR. The long-term efficacy of currently used dental implants: a review and proposed criteria of success. *Int J Oral Maxillofac Implants*. 1986;1:11–25.