

# Osseointegration of Dental Implants and Osteonecrosis of the Jaw in Patients Treated With Bisphosphonate Therapy: A Systematic Review

Gurpreet K. Chadha, BDS  
Azadeh Ahmadi, DDS, MS  
Satish Kumar, DDS, MDSc  
Parish P. Sedghizadeh, DDS, MS\*

Bisphosphonate (BP) drugs are a commonly prescribed group of medications used in the treatment of metabolic and oncologic bone disorders. The aim of this study was to conduct a systematic review in order to evaluate whether patients on BP therapy are appropriate candidates for dental implants as compared to patients not taking BP drugs with respect to successful implant osseointegration and the risk of developing bisphosphonate-related osteonecrosis of the jaw. Based on the current literature, a history of oral or intravenous BP use is not an absolute contraindication for dental implant placement, and dental implants can osseointegrate successfully in this patient population. Importantly, the studies currently available on this topic are of moderate to weak strength of evidence with inherent bias and limitations, and hence results must be interpreted in this context. Well-controlled studies with higher strength of evidence and larger population sizes are required to address this topic more accurately in the future.

**Key Words:** *bisphosphonates, diphosphonates, osteonecrosis, jaw, oral, dental implants*

## INTRODUCTION

**B**isphosphonate (BP) drugs are a group of medications with many therapeutic applications in the treatment of bone-related disorders such as osteoporosis, multiple myeloma, or cancer metastasis to bone because of their ability to affect bone remodeling and increase bone mineral density.<sup>1</sup> BP drugs promote osteoclast apoptosis and can also impair osseous blood supply.<sup>2</sup> BP drugs exert their actions by selective deposition in bones due to their high affinity for hydroxyapatite crystals.<sup>3</sup> As very small amounts are released into the circulation during bone turnover, BP half-life is estimated in

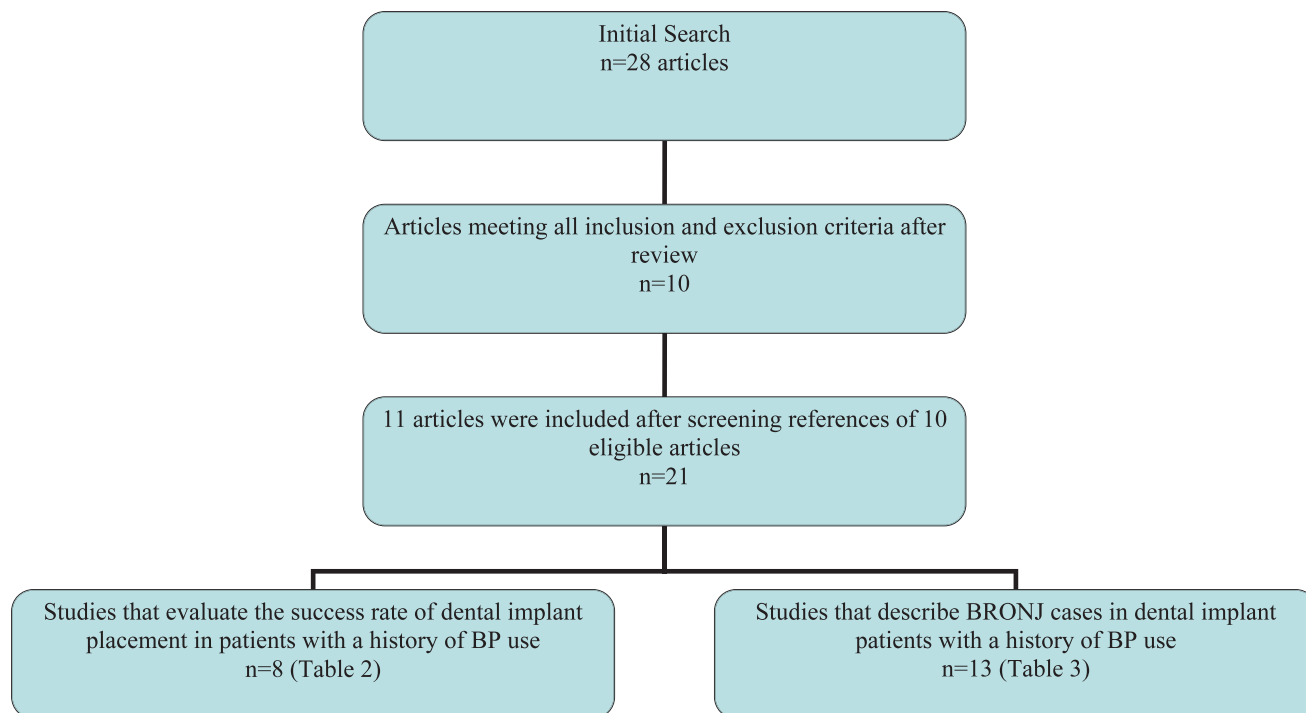
years.<sup>4</sup> There are 2 main classifications of BP drugs in the literature based according to mode of use (oral vs intravenous) or chemical composition (nitrogen vs non-nitrogen-containing). Common oral BP drugs such as alendronate, risedronate, ibandronate, or etidronate are used to treat osteoporosis. Common intravenous forms such as pamidronate and zoledronic acid are utilized for treatment of oncologic patients where these drugs may help prevent progressive bone resorption, reduce the extension of bony metastasis and tumor burden, and decrease pain.<sup>5</sup>

A significant adverse effect observed in patients using either oral or intravenous BP is osteonecrosis of the jaw, termed bisphosphonate-related osteonecrosis of the jaw (BRONJ). The frequency of BRONJ for patients on intravenous BP is estimated to range from 0.8%–12.0% as compared to patients taking oral BP which is estimated to be extremely low.<sup>6–9</sup> Most cases of BRONJ occur after invasive

Division of Periodontology, Diagnostic Sciences and Dental Hygiene, Herman Ostrow School of Dentistry, University of Southern California, Los Angeles, Calif.

\* Corresponding author, e-mail: sedghiza@usc.edu

DOI: 10.1563/AAID-JOI-D-11-00234



**FIGURE 1.** Flow diagram for systematic review.

dental procedures such as tooth extraction. Since dental implant therapy is an invasive dental procedure and may be a common treatment option in patients taking BP medications, given the average older age and edentate potential of this population, it has been questioned whether these patients are at risk for BRONJ. Currently, limited data are available in the literature regarding the outcome of placing dental implants or the risk of developing BRONJ in patients taking BP. There is also limited evidence on the development of BRONJ regarding the effect of other risk factors such as potency of the drug used, the duration of therapy, older age,

odontogenic and periodontal status, concurrent corticosteroid therapy, and systemic disorders such as diabetes and smoking.<sup>10–15</sup>

The only systematic review done on this topic, by Madrid and Sanz<sup>16</sup> in 2009, addressed this issue of BRONJ risk in dental implant patients. Because additional research articles have been published since the review by Madrid and Sanz, another systematic review to address this topic is warranted. In addition, BRONJ reports on implants were mainly reported as case reports and case series that were not included in the previous systematic review, and a quality assessment was not performed for selected

Type of Study	Level of Evidence	Strength of Evidence	Grade of Recommendation
Meta-analysis and randomized, controlled trials	1	Strong	A
Cohort studies	2	Moderate†	B
Case control studies	3		
Case reports	4	Limited/weak‡	C
Ideas, editorials, opinions, animal research and in vitro (test tube) research	5	Incomplete or insufficient	D

\*Adapted from *Evidence Based Decision Making: A Translational Guide for Dental Professionals*. Chapter 4. Edited by Jane L. Forrest.

†Extrapolations from level 1 studies have moderate strength of evidence.

‡Extrapolations from level 2 or 3 studies have limited/weak strength of evidence.

TABLE 2  
 Studies that evaluate the success rate of dental implant placement in patients with a history of bisphosphonate (BP) use\*

Author	Year	Type of Study	Number of Cases/Controls	Average Age or Age Range (y)	Number of Implants in BP Cases/Controls	BP Drug/Route of Administration
Zahid et al <sup>17</sup>	2011	Retrospective	26/300	56	51/661	NA
Koka et al <sup>18</sup>	2010	Retrospective	55/82	71	121/166	Oral
Martin et al <sup>19</sup>	2010	Case series	16/589 Female patients	70	44/No controls	Alendronate/oral
Kasai et al <sup>20</sup>	2009	Retrospective	11/40 Female patients	>36	35/161	Alendronate/oral
Grant et al <sup>21</sup>	2008	Retrospective	115 Female patients (89 patients under BP before implant surgery)	>40	468/1450	Alendronate, risedronate, ibandronate
Bell and Bell <sup>22</sup>	2008	Retrospective	42 Patients/NA (95% female)	67.4	100/734	Alendronate, risedronate, ibandronate/oral
Fugazzotto et al <sup>23</sup>	2007	Case series	61 Female patients/no controls	51–83	169/No controls	Alendronate or risedronate/oral
Jeffcoat <sup>24</sup>	2006	Prospective	25/25	30–79	102/108	Alendronate, risedronate/oral

\*BRONJ indicates bisphosphonate-related osteonecrosis of the jaw; NA, not applicable.

articles. Therefore, we conducted a systematic review to evaluate the osseointegration of dental implants and risk of osteonecrosis of the jaw associated with BP therapy. The clinical questions in “PICO” format (P = patient problem/population, I = intervention, C = comparison, O = outcome) in our study were:

(1) Compared with patients with no history of BP use, are patients with a history of oral or intravenous BP use appropriate candidates for dental implants with respect to successful osseointegration?

(2) Compared with patients with no history of BP use, are patients with a history of oral or intravenous BP use as a higher risk of developing BRONJ following dental implant placement?

**MATERIALS AND METHODS**

**Literature search**

Two investigators (G.K.C. and A.A.) independently queried the literature using these databases: PubMed/Medline and Cochrane Central Register of

TABLE 2  
Extended

Duration of BP Intake Before Dental Implant Insertion (mo)	Follow-up Period (mo)	Success Rate Cases (Controls)	BRONJ Outcome	Level of Clinical Evidence	Strength of Evidence	Grade of Recommendation	Notes
14–192	26	94.1% (97.1%)	0	3	Moderate	B	Statistically significant association between BP use and implant thread exposure was found; therefore, patients taking BP might be at higher risk for implant thread exposure.
Equal in 3 groups: <36, 36–60, >60	18	99.2% (98.2%)	0	3	Moderate	B	BP users who undergo dental implant surgery are at low risk for BRONJ, and BP “drug holiday” is not indicated in these patients.
38	NA	26 Failed implants	0	4	Limited/weak	C	Late failure (more than 1 year after placement) occurred more than early failure (less than 1 year after placement). There was a slightly higher proportion of failure in the mandible vs the maxilla.
>36	84.3	86% (96%)	0	3	Moderate	B	Oral BPs might decrease the integration of dental implants and increase their failure rate but not lead to osteonecrosis.
38	48	99.5% (99%)	0	3	Moderate	B	All of the implants except 2 integrated completely and met the criteria for establishing implant success.
6–132	4–89	95% (96.5%)	0	3	Moderate	B	Five implants failed. No evidence of BRONJ or any other complication was seen in these patients.
40	12–24	100% (No controls)	0	4	Limited/weak	C	History of BP usage for a mean period of 3 years was not associated with the occurrence of BRONJ after placement of immediately loaded dental implants.
12–48	36	100% (99.2%)	0	2	Moderate	B	No contraindication for dental implant placement in BP users.

Controlled Trials. English language articles were searched dating from January 1, 1995 to March 31, 2011 with the following search criteria using MEDLINE Medical Subject Heading (MeSH) terms: “dental implants” OR “immediate dental implant loading” OR “dental prosthesis, implant-supported” OR “dental implants, single-tooth) AND “diphosphonates” AND “osteonecrosis”.

It should be noted that the term “diphosphonates” is the umbrella term that also includes all “bisphosphonates.” The search results were screened

according to specific inclusion and exclusion criteria given below. Relevant studies in the references of the selected articles that met the inclusion and exclusion criteria were also considered for this systematic review as outlined in Figure 1.

### ***Inclusion criteria***

Studies that included subjects with a history of treatment with BP (whether diagnosed as BRONJ or not) and dental implants that must have been

TABLE 3

Studies that describe cases of bisphosphonate-related osteonecrosis of the jaw (BRONJ) in dental implant (DI) patients with a history of bisphosphonate (BP) use\*

Author	Year	Type of Study	Number of Cases/Controls; Age or Average Age (y)	Number of Implants	BP/Route
Favia et al <sup>25</sup>	2011	Case report	1 Female; 65	2	Clodronate/IV
Manfredi et al <sup>26</sup>	2011	Case series	3 Female; 70.4 (range 52–89)	3	Alendronate/oral Ibandronate/oral
Bedogni et al <sup>14</sup>	2010	Case report	1 Female; 63	2	Alendronate/oral
Goss et al <sup>13</sup>	2010	Case series	7/16 000; 62	19/28 000	Alendronate and risedronate/oral
Narongroeknawin et al <sup>27</sup>	2010	Case report	1 Male; 63	2	Alendronate/oral
Lazarovici et al <sup>15</sup>	2010	Case series	27 Patients were diagnosed with BRONJ (23 patients used BP before DI and 4 patients had DI before BP); 70	NA	Alendronate/oral (41%); pamidronate and zoledronic acid/IV (59%)
Shin et al <sup>28</sup>	2010	Case report	1 Female; 67	2	Alendronate/oral
Park et al <sup>29</sup>	2010	Case report	1 Female; 68	2	Alendronate/oral
Shirota et al <sup>30</sup>	2009	Case report	1 Female; 54	2	Pamidronate and zoledronate/IV
Alons et al <sup>31</sup>	2009	Case report	1 Female; 74	1	Pamidronate/IV
Brooks et al <sup>32</sup>	2007	Case report	1 Female; 62	10/No controls	Risedronate/oral
Wang et al <sup>33</sup>	2007	Case report	1 Female; 65	5	Alendronate/oral
Starck et al <sup>12</sup>	1995	Case report	1 Female; 75	5	Etidronate/NA

\*IV indicates intravenous; NA, not applicable.

placed for these patients either before or after BP therapy were incorporated in this review.

**Exclusion criteria**

Excluded were:

- (1) studies with subjects having osteonecrosis of the jaw secondary to radiation therapy or osteoradionecrosis;
- (2) studies with BRONJ cases related to dental therapy other than dental implants; and

TABLE 3  
Extended

Duration of BP Intake Before DI Placement (mo)	BRONJ Number/ Location	Time to BRONJ From DI Placement (mo)	Level of Clinical Evidence	Strength of Study
60 (suspension of treatment for 3 mo)	2/Mandibular molar region	4	4	Limited/weak
36–48 (the exact time during BP therapy that implants were placed is unclear)	2/Mandible	36–48 (just mentioned after implant placement, which was during BP therapy)	4	Limited/weak
72	1/Mandible	24	4	Weak
3–120	5/Maxilla, mandible	NA	4	Weak
75	2/Maxilla (at the site of the extracted teeth)	1	4	Weak
In 23 cases: 56.7; in 4 cases: 80 from DI to start of BP	27/Maxilla, mandible	12.86	4	Weak
12	2/Maxilla	12	4	Weak
60	2/Mandible	12	4	Weak
16	2/Maxilla	DI to BRONJ: 72; BP to BRONJ: 24	4	Weak
12; shorter than duration of pamidronate use in other BRONJ cases that had responded to the treatment protocol	1/Mandible	NA	4	Weak
30	1/Maxilla	2	4	Weak
>120	2/Mandible	1.5	4	Weak
0 (BP starts 28 mo after DI)	5/Mandible	4 after starting BP; 32 after DI	4	Weak

(3) narrative reports or literature reviews (case reports with literature reviews were included).

articles were included in the review. Any irrelevant articles or articles not meeting the inclusion and exclusion criteria were omitted.

### **Evaluation of search results**

The search results were evaluated initially based on reading each article. The inclusion and exclusion criteria listed above dictated whether or not the

### **Data collection**

Data collection was completed independently by authors, which included specific information about the articles (eg, eligibility for review, methods,

TABLE 3  
Extended

Grade of Recommendation	Notes
C	An en-bloc resection of 2 implants and alveolar bone was performed. <sup>25</sup>
C	Of 25 cases of BRONJ, 3 patients had received dental implants. The first 2 lost their mandibular implants during antibiotic or laser therapy. while in the third patient implant treatment was successful in maxillary region. <sup>26</sup>
C	Patients at risk must be given a full explanation of the potential risks of implant failure and BRONJ development. Because the potential role of infection is still debated, great attention should be paid to the long-term oral hygiene of implant-prosthetic restorations. <sup>14</sup>
C	As the failure rate seen was less than 1%, the placement of implants in BP patients was not considered an absolute contraindication. <sup>13</sup>
C	In this case, treatment was changed from alendronate to teriparatide and then BRONJ resolved. <sup>27</sup>
C	BRONJ associated with dental implants is a late and devastating side effect of BP, and long-term follow-up is essential for these patients. <sup>15</sup>
C	BRONJ case was successfully treated with systemic antibiotics, chlorhexidine mouth rinse, and debridement of the necrotic bone. <sup>28</sup>
C	Case was presented with a chief complaint of pain and gingival bleeding at the site of implant insertion. Biopsy was taken that was consistent with BRONJ. <sup>29</sup>
C	Conservative therapy is recommended and jaw resection might be considered if chemotherapy is planned or the necrotic bone around implants is infected. <sup>30</sup>
C	Sequestrectomy with curettage in combination with IV antimicrobial therapy (the protocol of chronic suppurative osteomyelitis management) was applied for 7 cases of BRONJ. In 6 patients, signs and symptoms resolved. Only 1 patient had a persistent dehiscence at the site of surgery and diagnosed as peri-implantitis. <sup>31</sup>
C	Nine implants osseointegrated successfully. Patient was treated by surgical debridement, antibiotics, and steroids. <sup>32</sup>
C	Patients undergoing long-term oral BP use should be treated with caution. The failures were successfully managed by systemic antibiotics, local antimicrobial mouthwash, and aggressive defect management (detoxification and mixture of bone graft and tetracycline). <sup>33</sup>
C	Implant placement is rarely contraindicated by preexisting systemic diseases, and no instances of medication-induced implant failure have been reported in the literature. Note: This report was published in 1995 but BRONJ was not reported until 2003.

participants, interventions, results, and statistics). These results were then summarized and discussed.

**Quality assessment**

Each article underwent a quality assessment and level of evidence. Strength of evidence and grade of

recommendation were determined according to previously established guidelines as outlined in Table 1. Two authors (G.K.C. and A.A.) independently analyzed and assessed the quality of each article. During situations of disagreement, all authors then discussed the results and arrived at a final agreement on the quality of the articles. Appropri-

ate unbiased conclusions were then presented. Due to the heterogeneity of the included studies in terms of study design and outcomes, a descriptive review and analysis of studies is presented.

## RESULTS

Of the initial search of 28 articles and their references that met the study criteria, 21 studies were appropriate for inclusion (Figure 1). These 21 studies were divided into 2 groups to address our "PICO" questions. The first group of studies evaluated the success rate of dental implant placement in patients with a history of BP use from the aspect of implant osseointegration and absence of BRONJ. Relevant details of this group of studies are summarized in Table 2.

The second group focused on studies that describe BRONJ cases in dental implant patients with a history of BP use. Relevant details of this group of studies are presented in Table 3. Finally, 16 studies that did not meet all of our inclusion and exclusion criteria were excluded.<sup>34-50</sup>

## DISCUSSION

It is estimated that 30 million BP prescriptions are written each year in the United States and more than 190 million worldwide.<sup>6</sup> Given the widespread use of these drugs, widespread placement of dental implants, and growing concern of BRONJ in BP patients, it is important to evaluate the topic of osseointegration of dental implants in patients taking BP medications and risk of developing BRONJ. The success rate of dental implants in patients is thought to depend not only on the use of BP, but also on their systemic health status along with the quality, quantity, and healing capability of the bone.<sup>11,28,49</sup> For example, osteoporotic bone exhibits reduced mechanical strength with decreased mineral content, crystallinity, carbonate to phosphate ratios, and altered trabecular architecture. Therefore, in patients requiring dental implant placement, there is a possibility that osseointegration can be compromised to some extent based on disease status or BP medication use. Most of the studies in our review that were of moderate strength of evidence revealed that osteoporosis and BP use have no effect on successful implant osseointegration and func-

tion,<sup>18,19,21-24</sup> while 2 retrospective studies by Zahid et al<sup>17</sup> and Kasai et al<sup>20</sup> cast doubt on this concept and reported that there were significant differences in success rates of dental implants between cases and controls.

Most reported cases of BRONJ are associated with invasive dental procedures, and dental implant therapy by its nature is an invasive dental procedure. However, the current systematic review reveals a low rate of BRONJ in dental implant patients taking BP as compared to other invasive procedures. The reason for this remains unknown, though it may be due to several factors such as underreporting of implant failures, more sterile operatory conditions in implant patients, frequent irrigation of bone during implant surgery, use of antimicrobials, or regular follow-up and wound management in patients with implants as compared to patients with routine dental extractions. Some of the aforementioned clinical factors could potentially prevent peri-implantitis or osteomyelitis/osteonecrosis at an implant site and thus avert the development of BRONJ at that site. Although some population studies with higher strength of evidence exist on the rate of BRONJ after tooth extraction,<sup>51-53</sup> there is a lack of similar studies with respect to dental implant placement. There are a few case reports and case series that reported BRONJ in dental implant patients with a history of BP use.<sup>12-15,25-33</sup> Most of the available studies indicated that the occurrence of BRONJ was negligible to minimal if oral BP was used for fewer than 5 years.<sup>15,17,21,23,30</sup> There were, on the other hand, a few studies that reported BRONJ in patients who used oral BP for fewer than 5 years.<sup>26,28,30</sup> Our findings indicate little difference in implant success rates between patients taking BP and those not taking BP, and also point out a lack of consistent protocols or guidelines in the evaluation and treatment of BRONJ, as different authors reported diverse approaches to management with varying clinical results. These findings have important clinical implications to implant dentistry and are consistent with the previous systematic review published by Madrid and Sanz.<sup>16</sup>

## LIMITATIONS

Most of the included articles in our study were retrospective studies or case series and case reports



that are of moderate to weak strength of evidence. Inherent bias in these studies makes it difficult to make firm conclusions, and hence results must be interpreted within this context. Non-English publications and grey literature were not included in this review. It is possible that certain publications may not be retrieved with the specific search criteria used in this systematic review. Also, limiting the search to only 2 electronic databases may have missed publications from countries that are not usually indexed in these 2 databases. There was not a common definition for success rate of dental implant placement in the included studies, thereby contributing to possible inaccuracy of success rates. The current definition of BRONJ does not include occult yet advanced osteonecrotic lesions in the jaws that may not have an obvious bony exposure or sequestrum but are clinically evident via a sinus tract and radiographic findings; hence, the number of BRONJ cases may have been underreported in some studies.

Importantly, most of the studies in this field to date are case reports and case series or retrospective studies comprising weak to moderate strength of evidence, and most have relatively small population sizes, varying treatment modalities, paucity of statistical analyses or rigor, and lack adequate control for confounding variables or effect modifiers. Well-controlled studies with higher strength of evidence and larger population sizes are required to more accurately address this topic in the future.

### CONCLUSIONS

The data on the failure or success rate of osseointegration of dental implants in patients undergoing oral or intravenous BP treatment are limited. Based on the current literature, most of the retrospective studies with moderate strength of evidence report that a history of oral or intravenous BP use is not an absolute contraindication for dental implant placement as compared to dental implant patients not taking BP, and dental implants can osseointegrate successfully in this patient population. However, thorough medical history and review of systems is recommended for all patients, and clinical decision-making and risk assessment should be made on a case by case

basis with consideration of all possible factors in addition to BP therapy.

Based on the current literature, most of the retrospective studies with moderate strength of evidence report that a history of oral or intravenous BP use is not an absolute contraindication for dental implant placement, and dental implants can osseointegrate successfully in patients with a history of BP use. However, some case reports and case series report BRONJ cases in dental implant patients with a history of oral and intravenous BP use. Some factors such as systemic health status of the patient, type of medication, route of administration (intravenous BP has higher risk of BRONJ than oral BP), and longer duration of BP use could be determining factors with respect to BRONJ development in patients receiving dental implants. A prudent clinician should disclose the low risk of developing BRONJ and the possibility of implant failure to the patient preoperatively in the informed consent process.<sup>14,15</sup> Again, thorough medical history and review of systems are recommended for all patients and clinical decision-making, and risk assessment should be made on a case by case basis, taking into account all possible factors.

### ABBREVIATIONS

BP: bisphosphonate

BRONJ: bisphosphonate-related osteonecrosis of the jaw

MeSH: Medical Subject Heading

### REFERENCES

1. Im GI, Qureshi SA, Kenny J, et al. Osteoblast proliferation and maturation by bisphosphonates. *Biomaterials*. 2004;25:4105–4115.
2. Fournier P, Boissier S, Filleur S, et al. Bisphosphonates inhibit angiogenesis in vitro and testosterone-stimulated vascular regrowth in the ventral prostate in castrated rats. *Cancer Res*. 2002;62:6538–6544.
3. Rogers MJ, Gordon S, Benford HL, et al. Cellular and molecular mechanisms of action of bisphosphonates. *Cancer*. 2000;88:2961–2978.
4. Lin JH. Bisphosphonates: a review of their pharmacokinetic properties. *Bone* 1996;18:75–85.
5. Green JR. Bisphosphonates: preclinical review. *Oncologist*. 2004;9:3–13.
6. Advisory Task Force on Bisphosphonate-Related Osteonecrosis of the Jaws, American Association of Oral and Maxillofacial Surgeons. American Association of Oral and Maxillofacial Surgeons position paper on bisphosphonate-related osteonecrosis of the jaws. *J Oral Maxillofac Surg*. 2007;65:369–376.

7. Durie BG, Katz M, Crowley J. Osteonecrosis of the jaw and bisphosphonates. *N Engl J Med*. 2005;353:99–102.
8. Dimopoulos MA, Kastritis E, Anagnostopoulos A, et al. Osteonecrosis of the jaw in patients with multiple myeloma treated with bisphosphonates: evidence of increased risk after treatment with zoledronic acid. *Haematologica*. 2006;91:968–971.
9. Ruggiero SL, Mehrotra B. Ten years of alendronate treatment for osteoporosis in postmenopausal women. *N Engl J Med*. 2004;351:190–192.
10. Schwartz HC. Osteonecrosis and bisphosphonates: correlation versus causation. *J Oral Maxillofac Surg*. 2004;62:763–764.
11. Javed F, Romanos GE. Impact of diabetes mellitus and glycemic control on the osseointegration of dental implants. A systematic literature review. *J Periodontol*. 2009;80:1719–1730.
12. Starck WJ, Epker BN. Failure of osseointegrated dental implants after diphosphonate therapy for osteoporosis: a case report. *Int J Oral Maxillofac Implants*. 1995;10:74–78.
13. Goss A, Bartold M, Sambrook P, et al. The nature and frequency of bisphosphonate-associated osteonecrosis of the jaws in dental implant patients: a South Australian case series. *J Oral Maxillofac Surg*. 2010;68:337–343.
14. Bedogni A, Bettini G, Totola A, et al. Oral bisphosphonate-associated osteonecrosis of the jaw after implant surgery: a case report and literature review. *J Oral Maxillofac Surg*. 2010;68:1662–1666.
15. Lazarovici TS, Yahalom R, Taicher S, et al. Bisphosphonate-related osteonecrosis of the jaw associated with dental implants. *J Oral Maxillofac Surg*. 2010;68:790–796.
16. Madrid C, Sanz M. What impact do systemically administered bisphosphonates have on oral implant therapy? A systematic review. *Clin Oral Implants Res*. 2009;20(suppl 4):87–95.
17. Zahid T, Wang BY, Cohen R. Influence of bisphosphonates on alveolar bone loss around osseointegrated implants. *J Oral Implantol*. 2011;37:335–346.
18. Koka S, Babu NM, Norell A. Survival of dental implants in post-menopausal bisphosphonate users. *J Prosthodont Res*. 2010;54:108–111.
19. Martin DC, O’Ryan FS, Indresano AT, et al. Characteristics of implant failures in patients with a history of oral bisphosphonate therapy. *J Oral Maxillofac Surg*. 2010;68:508–514.
20. Kasai T, Pogrel MA, Hossaini M. The prognosis for dental implants placed in patients taking oral bisphosphonates. *J Calif Dent Assoc*. 2009;37:39–42.
21. Grant BT, Amenedo C, Freeman K, et al. Outcomes of placing dental implants in patients taking oral bisphosphonates: a review of 115 cases. *J Oral Maxillofac Surg*. 2008;66:223–230.
22. Bell BM, Bell RE. Oral bisphosphonates and dental implants: a retrospective study. *J Oral Maxillofac Surg*. 2008;66:1022–1024.
23. Fugazzotto PA, Lightfoot WS, Jaffin R, et al. Implant placement with or without simultaneous tooth extraction in patients taking oral bisphosphonates: postoperative healing, early follow-up, and the incidence of complications in two private practices. *J Periodontol*. 2007;78:1664–1669.
24. Jeffcoat MK. Safety of oral bisphosphonates: controlled studies on alveolar bone. *Int J Oral Maxillofac Implants*. 2006;21:349–353.
25. Favia G, Piattelli A, Sportelli P, Capodiferro S, Iezzi G. Osteonecrosis of the posterior mandible after implant insertion: a clinical and histological case report. *Clin Implant Dent Relat Res*. 2011;13:58–63.
26. Manfredi M, Merigo E, Guidotti R, Meleti M, Vescovi P. Bisphosphonate-related osteonecrosis of the jaws: a case series of 25 patients affected by osteoporosis. *Int J Oral Maxillofac Surg*. 2011;40:277–284.
27. Narongroeknawin P, Danila MI, Humphreys LG Jr, Barasch A, Curtis JR. Bisphosphonate-associated osteonecrosis of the jaw, with healing after teriparatide: a review of the literature and a case report. *Spec Care Dentist*. 2010;30:77–82.
28. Shin EY, Kwon YH, Herr Y, et al. Implant failure associated with oral bisphosphonate-related osteonecrosis of the jaw. *J Periodontol Implant Sci*. 2010;40:90–95.
29. Park W, Kim NK, Kim MY, et al. Osteonecrosis of the jaw induced by oral administration of bisphosphonates in Asian population: five cases. *Osteoporos Int*. 2010;21:527–533.
30. Shirota T, Nakamura A, Matsui Y, et al. Bisphosphonate-related osteonecrosis of the jaw around dental implants in the maxilla: report of a case. *Clin Oral Implants Res*. 2009;20:1402–1408.
31. Alons K, Kuijpers SC, de Jong E, et al. Treating low- and medium-potency bisphosphonate-related osteonecrosis of the jaws with a protocol for the treatment of chronic suppurative osteomyelitis: report of 7 cases. *Oral Surg Oral Med Oral Pathol Oral Radiol Endod*. 2009;107:e1–e7.
32. Brooks JK, Gilson AJ, Sindler AJ, et al. Osteonecrosis of the jaws associated with use of risedronate: report of 2 new cases. *Oral Surg Oral Med Oral Pathol Oral Radiol Endod*. 2007;103:780–786.
33. Wang HL, Weber D, McCauley LK. Effect of long-term oral bisphosphonates on implant wound healing: literature review and a case report. *J Periodontol*. 2007;78:584–594.
34. Ferlito S, Liardo C, Puzzo S. Bisphosphonates and dental implants: a case report and a brief review of literature. *Minerva Stomatol*. 2011;60:75–81.
35. Garg A, Guez G. Study investigates novel approach to bone loss in the jaw. *Dent Implantol Update*. 2011;22:9–15.
36. Fleisher KE, Glickman RS. Risk factors for bisphosphonate-related osteonecrosis of the jaws. *J Oral Maxillofac Surg*. 2011;69:959.
37. Seymour RA, Walton G. Malignant disease and the delivery of dental care. *Dent Update*. 2010;37:20–22, 25–26.
38. Koka S, Salinas TJ, Kennel KA. Osteoporosis, fracture risk, and prosthodontic implications. *Int J Prosthodont*. 2009;22:505–506.
39. Montoya-Carralero JM, Parra-Mino P, Ramírez-Fernández P, et al. Dental implants in patients treated with oral bisphosphonates: a bibliographic review. *Med Oral Patol Oral Cir Bucal*. 2010;15:e65–e69.
40. Bourgeois SL Jr. Bisphosphonate medications—the good, the bad, and the ugly. *Tex Dent J*. 2009;126:596–604.
41. Flichy-Fernández AJ, Balaguer-Martínez J, Peñarrocha-Diago M, Bagán JV. Bisphosphonates and dental implants: current problems. *Med Oral Patol Oral Cir Bucal*. 2009;14:E355–E360. Review.
42. McLeod NM. Oral bisphosphonates and dental implants. *J Oral Maxillofac Surg*. 2009;67:1355.
43. Pigrau C, Almirante B, Rodriguez D, et al. Osteomyelitis of the jaw: resistance to clindamycin in patients with prior antibiotics exposure. *Eur J Clin Microbiol Infect Dis*. 2009;28:317–323.
44. Dai M, Li Y, Head TW, et al. Point of care. *J Can Dent Assoc*. 2008;74:617–626.
45. Wynn RL. Do Fosamax-type drugs increase the risk of osteonecrosis of the jaw for patients receiving dental implants? *Gen Dent*. 2008;56:410–411.
46. Phillips G. Bisphosphonate therapy and dental treatment. *J Indiana Dent Assoc*. 2007–2008;86(4):4–8.
47. Otomo-Corgel J. Implants and oral bisphosphonates: risky business? *J Periodontol*. 2007;78:373–376.
48. Garg A, Guez G. Study investigates novel approach to bone loss in the jaw. *Dent Implantol Update*. 2011;22:9–15.
49. Garg AK. Bisphosphonates and avascular necrosis of alveolar bone: a potential threat to dental implants. *Dent Implantol Update*. 2006;17:73–78.
50. Oliver R, Badr M. Interventions for the prevention of osteonecrosis of the jaws in patients receiving bisphosphonate

therapy undergoing oral surgery (Protocol). *Cochrane Database of Syst Reviews*. 2010;2:CD008355.

51. Mavrokokki T, Cheng A, Stein B, Goss A. Nature and frequency of bisphosphonate-associated osteonecrosis of the jaws in Australia. *J Oral Maxillofac Surg*. 2007;65:415–423.

52. Sedghizadeh PP, Stanley K, Caliqiuri M, et al. Oral

bisphosphonate use and the prevalence of osteonecrosis of the jaw: an institutional inquiry. *J Am Dent Assoc*. 2009;140:61–66.

53. Hoff AO, Toth BB, Altundag K, et al. Frequency and risk factors associated with osteonecrosis of the jaw in cancer patients treated with intravenous bisphosphonates. *J Bone Miner Res*. 2008; 23:826–836.