

# Immediate Restoration of NobelActive Implants Placed Into Fresh Extraction Sites in the Anterior Maxilla

Christopher Bell  
Robert E. Bell, DDS\*

The aim of this study is to compare the success rates of immediately placed and loaded NobelActive implants with the success rate of immediately placed implants that were allowed to osseointegrate prior to loading. The charts of all patients in a private oral surgery office receiving single-unit dental implants in the maxillary anterior region in fresh extraction sites from 2008–2011 were evaluated. All patients receiving NobelActive implants and immediate restorations were included in the study group, while those receiving implants with delayed restorations were included in the control group. Patient records were evaluated for variables such as age, gender, torque values at time of implant placement, smoking habits, use of bisphosphonates, and other significant diseases such as diabetes. The success rate of the study group was 92.9%, whereas the success rate of the control group was 97.6%. This was not statistically significant. Torque values of the failed implants of the study group were similar to those of successful implants in the study group. All implants placed in patients scheduled for immediate loading achieved high torque values and were able to be restored immediately. NobelActive implants were able to obtain high torque values for predictable immediate restoration in fresh extraction sites. Acceptable success rates with excellent soft tissue healing were achieved.

**Key Words:** *implant, Implants, immediate placement, immediate load, immediate loading, dental implant, dental implants, immediate restoration, NobelActive, immediately restoring, Nobel Active, Nobel*

## INTRODUCTION

Implant protocols have evolved over the past 40 years since Branemark introduced the concept of unloaded endosseous cylindrical implants. Implant design and surface technology has also changed. Roughened surfaces, altered thread patterns, and internal connectors have improved implant success and decreased healing times. Implants placed immediately into fresh extraction sites have been shown to be successful. Immediately loaded implants—whether they be splinted and in occlusion or single units immediately restored out of occlusion in healed sites—have high success rates with proper patient selection.<sup>1</sup>

Studies of immediately restored implants placed in fresh extraction sites have sometimes met with higher failure rates.<sup>2,3</sup> This is reasonable because of

the decreased buttressing of an extraction site compared to a healed site. Other studies of immediately placed restored implants have demonstrated high success rates.<sup>4–6</sup> Immediate restoration of implants placed into fresh extraction sites, if successful, has several advantages including: simultaneous soft and hard tissue healing, support of the soft tissue by the temporary restoration, and patient convenience.

Chaushu<sup>2</sup> compared immediately loaded single-tooth implants placed in fresh extraction sites to immediately loaded implants in healed sites. The implants in extraction sites had an 82% success rate compared to 100% success in healed sites. Aly<sup>3</sup> noted a similar success rate of 85% for immediately restored single-unit implants in fresh extraction sites. Mijiritsky,<sup>7</sup> however, found a 95.8% success rate for implants placed in fresh extraction sites immediately restored and out of occlusion. Studies by Cornelini<sup>8</sup> and by Crespi<sup>9</sup> found immediately placed and restored implants had a 100% integra-

Central Valley Dental Implant, Tulare, Calif.  
\* Corresponding author: e-mail: tularebell@gmail.com  
DOI: 10.1563/AAID-JOI-D-11-00254

tion rate. In a literature review, De Rouck<sup>10</sup> found predictable implant survival and good maintenance of papilla levels but also found marginal bone loss and resultant recession.

Recently, Nobel Biocare introduced the NobelActive implant. When this implant is inserted into either healed bone or fresh extraction sites, it achieves much higher torque values than traditional cylindrical endosseous implants. The higher torque value translates to higher initial stability of the implant. It seems possible, therefore, that these implants might have a higher success rate when placed in fresh extraction sites and immediately restored. Also, the thread design and resultant increased torque values of NobelActive implants might make treatment planning immediate restorations more predictable and decrease the need to make intraoperative changes in the treatment plan when sufficient torque values are not achieved.

#### MATERIALS AND METHODS

The charts of patients receiving single-unit dental implants in the maxillary anterior region in fresh extraction sites from 2008–2011 in one oral surgeon's office were evaluated. Thirty-nine patients receiving NobelActive implants and immediate restorations were included in the study group. Seventy patients receiving immediate implants with delayed restorations were included in the control group. Patients were selected for the study group based on their desire for an immediate restoration. Presence of adequate bone for an immediate implant was required of both the study and control groups. Patients with class II division II occlusion with pathway wear were discouraged from receiving immediate restorations due to difficulty in keeping the restoration out of occlusion.

Patient records were stripped of identifiers and evaluated for significant variables such as age, gender, torque values at time of implant placement, smoking habits, use of bisphosphonates, and other significant diseases such as diabetes. Due to the internal firewalls used and the study being a retrospective chart review, it was exempt from institutional board review. Variables were evaluated using Fisher exact test. Statistical significance was set at  $P < .05$ .

Extractions were performed using a forceps with digital pressure on the alveolus to preserve alveolar

bone. If it was not possible to extract the teeth with forceps, the roots were sectioned mesiodistally and luxated with elevators or periostomes. After extraction, the sockets were debrided and irrigated. Implant osteotomies were created using a surgical stent and sequential drills with underpreparation of the implant site. Implants were placed using a hand-operated torque wrench. If implants reached torque values greater than 75 Ncm, the implants were backed out slightly and then advanced again until the proper implant depth was reached. The buccal residual sockets were grafted with a mixture of autogenous bone harvested from the osteotomy with a bone filter, bio-oss, and platelet-rich plasma. Temporaries were fashioned on Nobel temporary cementable abutments using the extracted crown or a lab-fabricated acrylic temporary. These were cemented in the oral surgery office the day of surgery. Care was taken to undercontour the facial emergence profile and to assure the temporary was out of occlusion. Patients were cautioned not to bite or chew with their implants but were not asked to modify their diet.

#### RESULTS

The study group included 39 patients receiving 42 single-unit NobelActive implants placed into fresh extraction sites in the anterior maxilla and immediately restored out of occlusion. Ages ranged from 24–83 years (mean 56.3 years). The control group included 70 patients receiving 84 single-unit implants placed by the same operator over a similar period. The control implants were placed into fresh extraction sites in the anterior maxilla in a single-stage technique and left to integrate unloaded for three months. Ages ranged from 24–88 years (mean 60.9 years). The resultant data is shown in the Table.

In the study group, 3 out of 42 implants failed, for a 92.9% success rate. Two of 84 implants failed in the control group, for a 97.6% success rate. The difference was not statistically significant.

In the study group, 24 implants were placed in males (57.1%) and 18 (42.9%) were placed in females. All failed implants were placed in male patients. Eighty-four implants were placed in the control group, 48 in males (57.1%) and 36 (42.9%) in females. One implant (50%) failed in a male patient and one in a female patient. These values were not statistically significant.

TABLE 1  
Comparison of the control and study groups

	Number of Patients	Number of Implants	Male	Female	Number of Smokers	Number of Failed Implants
Control group	70	84	48	36	2	2
Study group	39	42	24	18	2	3

Torque values achieved in the study group ranged from 35–75 Ncm with a mean of 56.5 Ncm and a median of 70 Ncm. Failed implants had torque values of 60, 70, and 75 Ncm, which were not significantly lower. No patient who was treatment planned to receive an immediately placed and immediately loaded NobelActive implant had the treatment plan changed during surgery to an unloaded protocol. Control group torque values ranged from 10–50 Ncm with a mean of 28.9 Ncm and a median of 35 Ncm. Both failed implants had torque values of 35 Ncm.

There were four NobelActive implants placed in smokers. Of these, 1 (25%) failed. This was not statistically significant, however, possibly due to the small number of smokers in the study. Two implants were placed in smokers in the control group, neither of which failed.

There were no failed implants in patients taking oral bisphosphonates or with other significant illnesses such as diabetes.

## DISCUSSION

This study demonstrates that NobelActive implants can be predictably placed and immediately restored in fresh extraction sites. The failure rate of this procedure, though not statistically significant, was higher than the more conventional one-stage unloaded immediate implant. This was similar to studies by Chaushu<sup>2</sup> and Aly<sup>3</sup> that showed higher failure in immediately restored immediately placed implants. The failure to show significance could be due to the small sample size. Patients need to be aware of this increased risk when selecting this procedure. All failed implants were removed and later replaced with new implants in an unloaded fashion. All of these implants integrated. Long-term success will be reexamined in a future study.

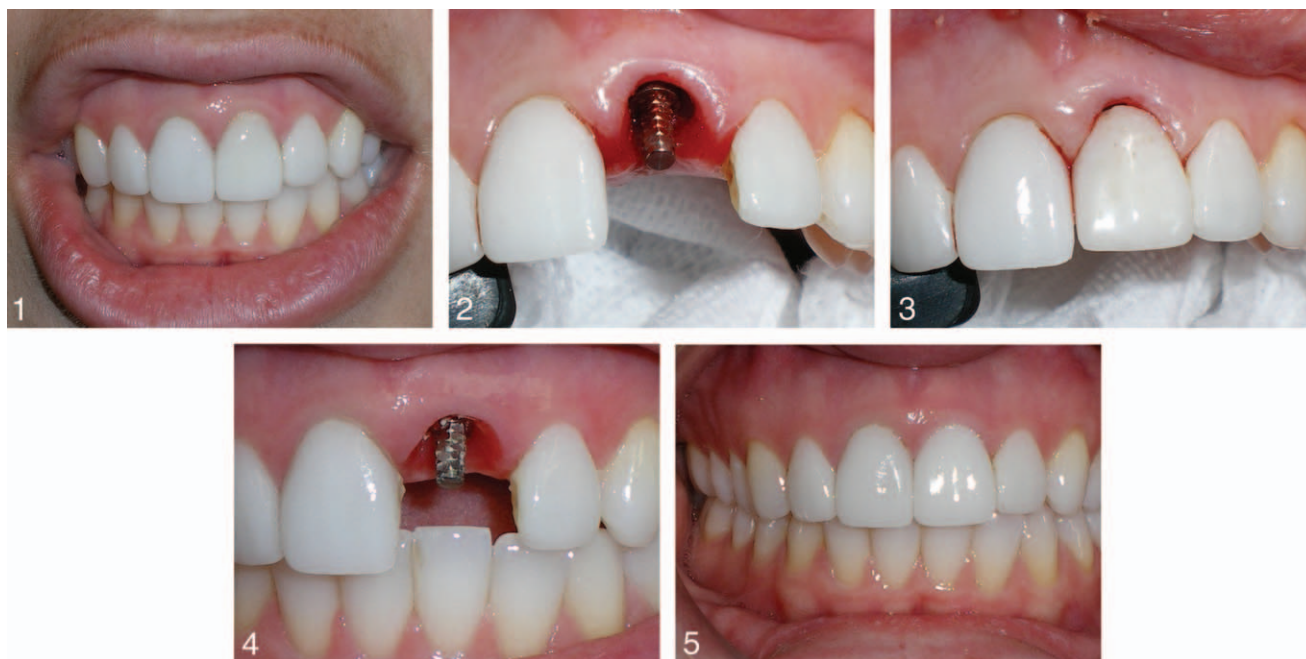
In a double-blind randomized controlled study, Canullo and Glauser showed that immediately

restored implants provided excellent short-term peri-implant tissue stability.<sup>6,11</sup> Soft tissue healing around the temporary abutments was excellent. Undercontouring the facial emergence profile to the level of the original gingival margin usually resulted in a small amount of initial apical movement of the gingiva in the immediate post-extraction phase (Figures 1–4). By the end of the 3-mo period, the gingiva had usually migrated coronally to the original gingival margin (Figure 5). After the integration phase, the implants were ready for final impressions including soft tissue indexing. Long-term tissue levels will be assessed in a future study.

Temporary restorations were easy to fashion using the patient's extracted tooth or crown. If the crown of the tooth was not available, a lab-constructed hollow acrylic crown was also easy to fashion as a temporary. Patients appreciated having a fixed temporary. Of course, those whose implants failed were disappointed and had to wear a removable or bonded temporary for a more extended period of time.

Esthetic and functional outcomes were excellent in all immediately restored fixtures. Gingival margins were maintained at or near the preoperative levels in all cases over the short follow-up period of this study. Papillary levels were maintained by adjacent teeth and supported by the temporary restorations, resulting in excellent interdental papilla.

The high torque values attained by the NobelActive implants allowed immediate restoration of all the implants that were treatment planned for this procedure. This is a real advantage, as prior patients had to be told of the possibility of not receiving an implant borne restoration if a torque value of 35 Ncm was not achieved. In this study, no implants achieved less than 35 Ncm of torque. This allowed the operator to be certain of the treatment plan preoperatively.



**FIGURES 1–5.** **FIGURE 1.** Preoperative. **FIGURE 2.** Intraoperative. **FIGURE 3.** Temporary in place. **FIGURE 4.** Tissue after healing. **FIGURE 5.** Final restoration.

### CONCLUSION

In conclusion, NobelActive implants were able to obtain high torque values and acceptable success rates with excellent soft tissue healing when immediately restored in fresh extraction sites.

### REFERENCES

1. Schwartz-Arad D. Survival of immediately provisionalized dental implants placed immediately into fresh extraction sockets. *J Periodont.* 2007;78:219–223.
2. Chaushu G. Immediate loading of single-tooth implants: immediate versus non-immediate implantation. A clinical report. *Int J Oral Maxillofac Implants.* 2001;16:267–272.
3. Aly TM. Immediate loading of implants placed into fresh extraction sockets with peri-apical lesions without augmentation. *Smile Dent J.* 2008;3:6–22.
4. Ferrara A. Immediate provisional restoration of postextraction implants for maxillary single tooth replacement. *Int J Periodont Restorative Dent.* 2006;26:37.

5. Palatella P. Two-year prospective clinical comparison of immediate replacement vs. immediate restoration of single tooth in the esthetic zone. *Clin Oral Implants Res.* 2008;19:1148–1153.
6. Canullo Luigi. Double-blind randomized controlled trial study on post-extraction immediately restored implants using the switching platform concept: soft tissue response. Preliminary report. *Clin Oral Implants Res.* 2009;20:414–420.
7. Mijiritsky E. Immediate provisionalization of single-tooth implants in fresh-extraction sites at the maxillary esthetic zone: up to 6 years of follow-up. *Implant Dent.* 2009;18:326–333.
8. Cornelini R. Immediate restoration of implants placed into fresh extraction sockets for single tooth replacement: a prospective clinical study. *Int J Periodontics Restorative Dent.* 2005;25:439–447.
9. Crespi R. Immediate versus delayed loading of dental implants placed in fresh extraction sockets in the maxillary esthetic zone: a clinical comparative study. *Int J Oral Maxillofac Implants.* 2008;23:753–758.
10. De Rouck T. Single-tooth replacement in the anterior maxilla by means of immediate implantation and provisionalization: a review. *Int J Oral Maxillofac Implants.* 2008;23:897–904.
11. Glauser R, Zembic A, Hammerle, CHF. A systematic review of marginal soft tissue at implants subjected to immediate loading or immediate restoration. *Clin Oral Implants Res.* 2006;17:82–89.