

A Two-Stage Surgical Approach to the Treatment of Severe Peri-Implant Defect: A 30-Month Clinical Follow-Up Report

Jong-Eun Kim, DDS, MSD¹
Ha-Young Kim, DDS, MSD¹
Jung-Bo Huh, DDS, MSD, PhD²
Jeong-Yol Lee, DDS, MSD, PhD¹
Sang-Wan Shin, DDS, MSD, PhD^{1*}

With the advance of dental implant technology and the consequential increase in its success rate, the implant has become a highly predictable treatment method. Despite this, related complications are on the rise, with peri-implant mucositis and peri-implantitis being the most commonly observed. As in the case of conventional periodontitis, many patients experience peri-implant mucositis and peri-implantitis. In this case presentation, extensive bone loss occurred around the implant due to peri-implantitis, and the infection was first treated by applying chlorhexidine-soaked gauze and topical antibiotics. Then the guided bone regeneration procedure was performed using a bovine bone material and a collagen membrane, which resulted in the recovery of the lesion. With follow-ups of the healing process for 30 months, a successful outcome was observed that is reported herein.

Key Words: *implant, guided bone regeneration, peri-implantitis, infrabony defects, surface treatment*

INTRODUCTION

Interest in and studies on osseointegration between an implant and the bone, which Branemark triggered in the late 1960s,¹ have been on the rise. The osseointegrated implant has become known as the clinically widely accepted and reliable treatment option for restoring the edentulous area.

With the increase in the clinical use of implants, the incidence of related complications also increased, with peri-implant mucositis and peri-implantitis being the most common. Peri-implant

mucositis is a reversible inflammation of the soft tissue around an implant. Characteristic clinical findings of peri-implantitis are bleeding on probing (BOP) suppuration, and a probing pocket depth (PPD) of 4 mm or more. The characteristic radiographical findings include bone resorption.² Inadequate treatment may result in total loss of osseointegration, and consequential loss of the implant.³ About 28%-56% of subjects treated with dental implants reportedly experience peri-implantitis. In 12%-43% of implant sites, peri-implantitis is known to occur.⁴ As with conventional periodontitis, many patients are experiencing peri-implantitis.

The most significant risk factors of peri-implantitis are known to include poor oral hygiene, a history of periodontitis, and smoking. Uncontrolled diabetes and drinking alcohol are known to be slightly related to peri-implantitis.² Other risk factors include occlusal overload,⁵ and iatrogenic factors such as excess cement, improper seating of the

¹ Postgraduate School of Clinical Dentistry, Institute for Clinical Dental Research, Korea University Medical Center, Korea University, Seoul, South Korea.

² Department of Prosthodontics, Institute of Translational Dental Sciences, School of Dentistry, Pusan National University, Yang-San, South Korea.

* Corresponding author, e-mail: swshin@korea.ac.kr
DOI: 10.1563/AAID-JOI-D-12-00030

prosthesis, and overcontouring of the prosthesis. Most of the currently available approaches for the treatment of peri-implantitis are based on the treatment methods for periodontitis because of the general knowledge that peri-implantitis and periodontitis share a common causal pathogen.⁶

Peri-implantitis, however, needs approaches that slightly differ from that for periodontitis because the implant has features such as a rough surface and a screw shape that are distinct from natural teeth. The ultimate goal of the treatment of peri-implantitis is to achieve a re-osseointegration for which various protocols, including various treatment methods for contaminated surfaces of implants and regenerative treatment, are now being attempted.⁷ To clean the contaminated surface of an implant, tetracycline,⁸ citric acid,⁹ chlorhexidine, and hydrogen peroxide have been used, and topical and systemic antibiotic therapies have been utilized.^{10,11} In addition, various types of lasers have been used to treat contaminated implant surfaces.^{12–14} Decontamination has no significant influence on re-osseointegration, though it affects the resolution of inflammation. It is unknown which decontamination method is superior to others.⁷

The treatment protocol for peri-implantitis described by Mombelli and Lang¹⁵ recommends that surgical treatment and the guided bone regeneration (GBR) procedure are to be performed if a probing pocket depth of 5 mm or deeper or extensive bone loss, as assessed via radiography. It is known that the surgical approach with the GBR procedure using bone graft materials for bone regeneration around implants and re-osseointegration could achieve a significantly good outcome.^{7,16} Generally, the GBR procedure for peri-implantitis involves removal of the granulation tissue from the surface of the implant, followed by surface treatment and insertion of the bone graft materials and barrier membranes.

For a general GBR procedure such as ridge preservation, it is recommended that if there is acute infection in the extraction site, the inflammation be treated first and a bone graft procedure be performed using the delayed approach rather than performing the bone graft procedure simultaneously with tooth extraction and treatment of the inflammation.¹⁷ Clinical studies and animal studies on surgical treatment of peri-implantitis that have been published so far reported only on the

treatment procedure where treatment of the infection. The removal of the granulation tissue, and bone regeneration using GBR were performed simultaneously. No studies have been reported on the surgical procedure using GBR for acute infection in peri-implantitis.

In this presented case, extensive loss of the alveolar bone around the implant due to peri-implantitis was recovered using a 2-stage surgical approach that consisted of treatment of the infection, the GBR procedure, and follow-up of the healing process for 30 months. This case report was conducted in accordance with the Helsinki Declaration.

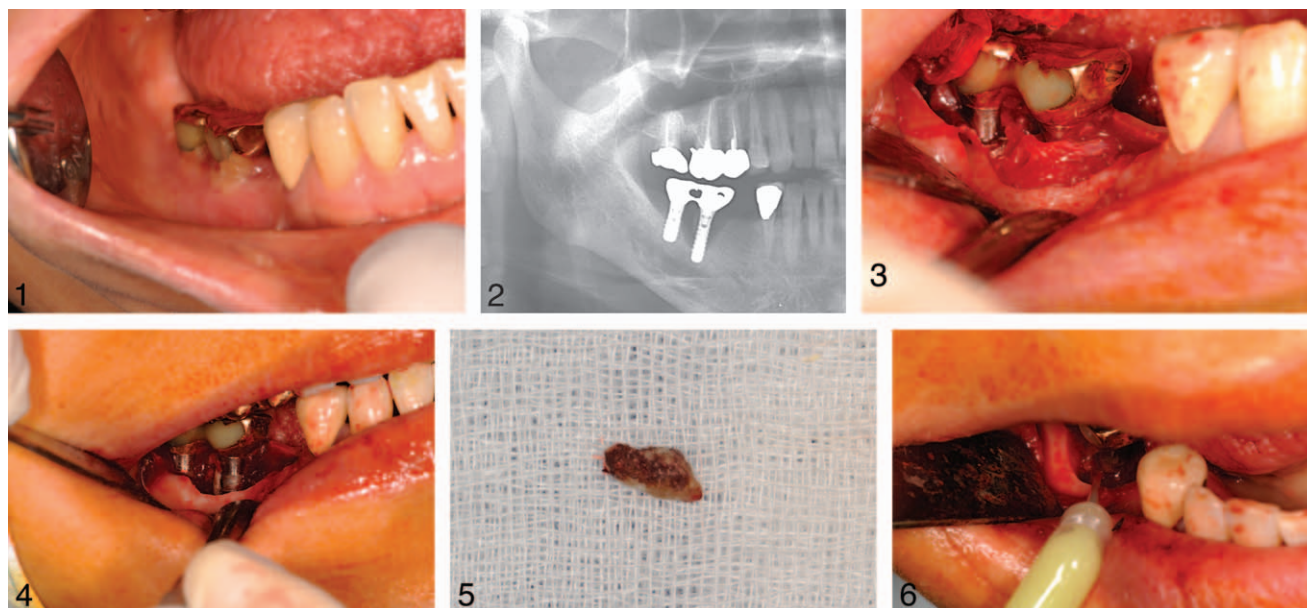
CLINICAL REPORT

Patient information

A 52-year-old female patient without a systemic disease consulted the dental clinic of Korea University Guro Hospital in February 2009. The patient had swelling, pus, and intermittent pain in the implant site. Examination of her dental history revealed 2 transgingival 1-piece implant systems (ITI implants, Straumann, Switzerland) implanted in the mandibular right first molar and second molar sites 7 years prior to consult. After 6 months, the patient had a fixed bridge prosthesis placed on the implant site. The implant site was asymptomatic during the 1-year follow-up. Due to unknown reason, the patient was not able to visit the hospital for regular check-ups. The patient only recently visited the hospital because of aggravated discomfort. The patient reported experiencing intermittent swelling and abnormal bleeding while brushing her teeth since a year ago.

Clinical oral examination and infection treatment

Clinical examinations and panoramic radiography were performed. The clinical examination revealed gingival inflammation, swelling, and discharge of pus around the implant site. During the probing examination, severe bleeding occurred, and a 10-mm probing depth was found (Figure 1). The radiography revealed a large radiolucent lesion around the implant site near the mandibular right first molar, revealing only about 4 mm of the apex of the implant maintained its osseointegration (Figure 2). The radiography also revealed that an



FIGURES 1–6. **FIGURE 1.** At the first examination, gingival inflammation, swelling, and pus are seen around the implant prosthesis. **FIGURE 2.** Panoramic radiograph at the first examination. Radiolucency in a very wide area over the implant placed at the site of the mandibular right first molar is seen. A radiopaque object that was about 3–4 mm long is seen vertically along the distal surface of the implant body. **FIGURE 3.** Findings from the first surgery that was performed to remove the granulation tissue and treat the infection. A large amount of granulation tissue is seen around the implant. The thread of the implant at the site of the mandibular right second premolar is also shown. **FIGURE 4.** After removal of the granulation tissue. The object that was suspected to have caused the radiopacity in the radiograph taken during the first examination is shown. **FIGURE 5.** Given the texture and various features of this object, it was ascertained as a dead bone that remained on the surface of the implant without being absorbed. **FIGURE 6.** Injection of topical antibiotics onto the contaminated surface of the implant.

approximately 3- to 4-mm-long vertical radiopacity along the surface of the implant body at the site of the mandibular right first molar. The radiography revealed the radiopaque portion; however, it is not sufficient to identify what the radiopacity was. Although the implant-supported prosthesis had no mobility, the implants at the sites of the mandibular right first molar and second molar were linked with the fixed bridge prosthesis, which made it difficult to accurately assess mobility of implants and loss of the osseointegration.

As a peri-implant probing depth exceeding 5 mm, swelling, discharge of abscess, and BOP were observed, surgical treatment with the GBR procedure was planned according to Mombelli and Lang's treatment protocol.¹⁵ The treatment was performed in 2 stages. In the first stage, the granulation tissue around the implant was removed and both topical and systemic antibiotics were used for the infection. After the inflammation of the soft tissue was completely relieved, in the second stage, GBR procedure was planned.

As the implant sites were acutely infected and

had discharge of abscess, removal of the granulation tissue and systemic antibiotic treatment were first performed to reduce the patient's discomfort. Under local anesthesia, sulcular incision was performed and the full-thickness flap was dissected. A large amount of granulation tissue was observed around the implants, and half of the implant at the site of the mandibular right second premolar was exposed (Figure 3). All the granulation tissues on the infrabony defect around the implants and on the flap were removed using a carbon curette. After the removal of the granulation tissue, it became possible to observe a region that was suspected to have caused the radiopacity observed in the implant body (Figure 4). Given the texture and other features, the radiopaque region was adjudged to be a part of the alveolar bone (Figure 5). The exposed surface of the implants was decontaminated by placing a gauze soaked in 0.2% chlorhexidine on the surface of the implants for 5 min. After the gauze was removed, topical antibiotics (Perio-clone, Sunstar, Inc, Osaka, Japan) were injected onto the contaminated surface of the implants (Figure 6),

and suturing was performed. Systemic antibiotic treatment (500 mg, amoxicillin, three times daily for 7 days) was also performed. The patient was advised to disinfect her mouth 4 times a day using the concomitantly prescribed 0.2% chlorhexidine.

Regenerative treatment

About 4 weeks later, the patient revisited the hospital. Her acute infection had almost completely disappeared, and her discomfort decreased. The outcome of the healing of the soft tissue was observed to have been favorable. The prosthesis of the implant at the site of the mandibular right first molar was removed to assess the feasibility of the GBR procedure in the implant at the same site. After the implant was removed, it was clinically assessed. The abutment and implant at the site had no mobility, and were found to have been stable in the percussion test. The periostest (Siemens AG, Bensheim, Germany) of the abutment linked to the implant achieved a score of -2 , which indicates that the osseointegration of the root apex of the implant was still maintained. Therefore, peri-implantitis was treated and adequate bone regeneration and osseointegration were achieved with surgical treatment of the mandibular right first molar. It was decided that an implant would be placed at the site of the mandibular right second molar edentulous area while achieving adequate bone regeneration and re-osseointegration through surgical treatment.

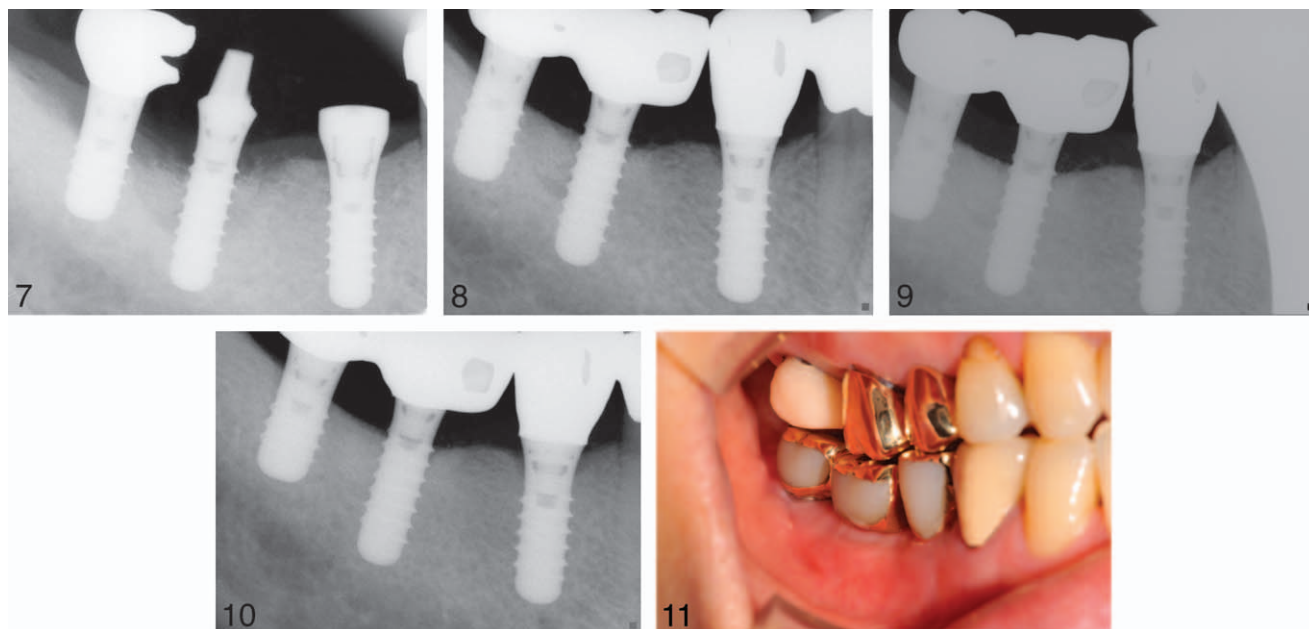
Surgical treatment was performed to achieve bone regeneration. Under local anesthesia, sulcular incision was performed and the full-thickness flap was dissected. After observing the absence of the remaining granulation tissue and inflammation, an implant was placed at the site of the mandibular right second premolar according to the standard procedure (Straumann, Switzerland). Then GBR procedure was performed on the peri-implantitis defect. Prior to the GBR procedure, for decontamination, a piece of gauze that was soaked in 0.2% chlorhexidine was again applied to the exposed surface of the implant. Then decortication of the neighboring bone was performed to allow the neighboring cells and blood to participate in the healing process. Xenograft material (Bio-Oss, Geistlich Biomaterials, Mannheim, Germany) was applied: sufficient Xenograft material was applied to cover the surface of the implant, the intrabony defect due to the peri-implantitis, and the thread of the

posterior implant. After grafting, an absorbable barrier membrane (Bio-Gide, Geistlich Biomaterials, Mannheim, Germany) was applied: a membrane that could cover the entire bone graft site was used, and the shape of the membrane was adjusted to fit a neck of nonsubmerged implant fixture. To allow good healing of the flap, tensionless suture was performed. Primary closure was performed to avoid infecting the bone graft material and the surgery site (Figure 7).

Follow-up and prognosis

Systemic antibiotics were administered (500 mg, amoxicillin, three times a day for 7 days), and chlorhexidine was prescribed for the patient to use after brushing her teeth. Disinfection was performed on the day after the surgery. The sutures were removed 10 days after the surgery. The postoperative healing process proceeded without particular problems, and about 6 months later, the probing depth was found to have decreased to about 4 mm without bleeding during the probing examination. The radiography revealed that the bone filling covered nearly the entire neighboring area of the implant, and the increased radiopacity was compared with that in the immediate postoperative period. Impression taking was performed, and fixed bridge prosthesis was fabricated. Determined that it would be better to splint with the posterior implant, the prosthesis of the posterior implant was removed, and splinting was again performed. At the same time, crown prosthesis was made for the implant that was placed 6 months ago at the site of the mandibular right second premolar during the surgery (Figure 8).

Since then, the patient regularly visited the hospital 6, 12, 18, 24, and 30 months postoperatively. Clinical examinations such as measurement of the peri-implant pocket depth, bleeding while probing the examination, and the degree of mobility of the implant, as well as a radiographic analysis, were performed. The regular radiography revealed a gradually maturing bone graft recipient site (Figures 9, 10). Based on the clinical findings during the follow-up, the periodontal pocket was found to have maintained the depth of about 3 mm, and has decreased 7 mm to about 10 mm from the first consult. The bone regenerated by approximately 8 mm at the bone resorption site. The case



FIGURES 7–11. **FIGURE 7.** Immediately after the GBR procedure. The prosthesis was removed to confirm the degree of mobility and to ensure a favorable regenerative procedure. The bone particle in the GBR site is shown. **FIGURE 8.** Six months after the GBR. The radiopacity increased from that in the immediate post-operative period. The bone filling was observed around the implant. The prosthesis was made at this time. **FIGURE 9.** Radiographic view at 12 months postoperatively. **FIGURE 10.** Radiographic view at 30 months postoperatively. **FIGURE 11.** Clinical photo at 30 months postoperatively. No inflammatory finding around the implant was observed and the implant was well-maintained.

remains asymptomatic at present, without particular abnormal findings (Figure 11).

DISCUSSION

In this patient's case, the implant that manifested peri-implantitis had a probing depth that was about 10 mm deep, presence of bleeding during the probing, and had a very large defect due to the bone resorption in the radiography. In this patient's case, after the flap was opened, the granulation tissue was completely removed for infection treatment in the first stage. After 4 weeks, the patient was recalled for the second stage of treatment. Surgical treatment, including the GBR procedure, was performed in this stage. It is determined that the treatment of peri-implantitis by the 2-staged approach promoted healing of the soft tissue by resolving the inflammation before the GBR procedure. This maintained the integrity of the bone graft material by achieving primary closure during the secondary bone graft procedure. It was also helpful in achieving a high degree of bone regeneration at the defect site with bone loss around the implant.

It is known that the procedure used in this

patient's case wherein complete removal of the granulation tissue and treatment of the contaminated surface of the implant were performed and a bone graft material and barrier membrane were applied are the optimum treatments of inflammation and induce bone regeneration in cases wherein severe loss of the neighboring bone is involved due to peri-implantitis.^{18,19} The implant that contracted peri-implantitis in the case of this patient was a nonsubmerged type. For this implant, the GBR procedure was performed, and then nonsubmerged healing process was performed. According to studies with animal tests, after GBR was performed in the peri-implantitis site, the outcome of the bone regeneration did not significantly differ between the submerged healing and the nonsubmerged healing.^{19,20}

In this patient's case, significantly good bone regeneration was achieved using the decontamination method wherein chlorhexidine-soaked gauze was applied for 5 min. In the animal test on the treatment of peri-implantitis on the SLA, TPS, and machined surface of the implant, Wetzel et al²¹ reported that after decontamination with chlorhexidine, the use of Bio-Oss as a bone graft material

resulted in a bone regeneration of about 83.4% (2.6 mm) on the surface of the SLA. In addition, Schou et al¹⁹ reported that after decontamination using chlorhexidine, a bone graft procedure using Bio-Oss yielded about 5-mm bone regeneration. In a review article, Renvert et al⁷ reported that a BIC of about 39%–46% was achieved in many studies regardless of the decontamination method. Thus, it is believed that simple decontamination using a chlorhexidine-soaked gauze will help achieve a good outcome in bone regeneration.²² The decontamination method resulted in a favorable outcome in the patient's case. It is very meaningful that a favorable outcome was achieved using the simple decontamination method instead of the complex one; and consequently, the surgeon's convenience was promoted and the surgical operation time was reduced. In this patient's case, minocycline was applied to the site of the peri-implantitis after the removal of the granulation tissue during the treatment process. This is performed to further improve the healing process, and to help improve the probing depth and the bleeding score.¹¹

In this patient's case, a xenograft material (Bio-Oss) and a collagen membrane (Bio-Gide) were used for the GBR procedure. Although many other bone graft materials demonstrated clinical success in a period as short as 6–12 months, only the combined use of Bio-Oss and Bio-Gide demonstrated clinical predictability for 2–4 years.² In addition, in the animal test, combined use of Bio-Oss and Bio-Gide reportedly resulted in significantly good re-osseointegration.²³ Though relevant data are limited, combined use of Bio-Oss and Bio-Gide is concluded to have potential in forming new bones around an implant and re-osseointegration. Excellent bone regeneration was also observed in this patient's case.

The type of bone defect caused by peri-implantitis may considerably influence the outcome. Among the types of bone defects due to peri-implantitis, a circumferential defect without buccal dehiscence is most common,²⁴ and for a circumferential defect, the prognosis after the bone regeneration procedure is known to be most favorable.²⁵ In this patient's case, the good bone regeneration of about 8 mm is attributed to the fact that only circumferential defects existed. In addition, the rough surface of the implant was more advantageous in terms of the formation and

maintenance of a blood clot, and is known to be of great help in osseointegration along the surface of the implant.²⁶

Although the exposed surface of the implant was later covered almost completely via bone regeneration, it is unknown whether re-osseointegration occurred or not. The histological and radiographic assessment of a ligature-induced peri-implantitis in animal model reported a re-osseointegration of about 1%–84%.^{24,27} Radiographic assessment of re-osseointegration has limitations, however because re-osseointegration is identifiable only with a histological specimen. If regenerative surgery of peri-implantitis is performed, it is important to closely observe bone regeneration based on a radiograph and to monitor clinical values such as PPD and BOP, because no histological findings from human studies are available.

The patient in this case was unable to visit the hospital due to personal reasons for 6 years after the follow-up check-up. Therefore no appropriate plaque removal procedures were performed for 6 years. Peri-implantitis-related bone resorption tends to accelerate over time if oral hygiene is not improved.²⁸ Patients who need to have an implant placed need to regularly visit the hospital, and are required to regularly measure their probing depth to diagnose peri-implantitis.²⁹ Failure to detect the destruction of the gingival attachment and bone loss due to lack of regular checkups, and unsteady removal of plaque on the patient, are factors that have greatly influenced the progression of the peri-implantitis. Likewise, peri-implantitis cannot be effectively cured if strict plaque control is not performed even if regenerative surgery had been performed. Strict management of postoperative oral hygiene is necessary.³⁰

CONCLUSION

In conclusion, in the case of extensive bone loss due to peri-implantitis around an implant, 2-stage treatment can be a good treatment option: the primary treatment that involves removal of the granulation tissue and treatment of the infection via surgery, and the secondary treatment that consists of guided bone regeneration using Bio-Oss and Bio-Gide. In addition, decontamination using a chlor-

hexidine-soaked gauze achieved a favorable outcome.

ABBREVIATIONS

BOP: bleeding on probing
GBR: guided bone regeneration
PPD: probing pocket depth
SLA: sand-blasted, large-grit, acid-etched

REFERENCES

1. Branemark PI, Adell R, Breine U, Hansson BO, Lindstrom J, Ohlsson A. Intra-osseous anchorage of dental prostheses. I. Experimental studies. *Scand J Plast Reconstr Surg*. 1969;3:81–100.
2. Schwarz F, Sahn N, Bieling K, Becker J. Surgical regenerative treatment of peri-implantitis lesions using a nanocrystalline hydroxyapatite or a natural bone mineral in combination with a collagen membrane: a four-year clinical follow-up report. *J Clin Periodontol*. 2009;36:807–814.
3. Quirynen M, De Soete M, van Steenberghe D. Infectious risks for oral implants: a review of the literature. *Clin Oral Implants Res*. 2002;13:1–19.
4. Zitzmann NU, Berglundh T. Definition and prevalence of peri-implant diseases. *J Clin Periodontol*. 2008;35(8 Suppl):286–291.
5. Isidor F. Influence of forces on peri-implant bone. *Clin Oral Implants Res*. 2006;17 Suppl 2:8–18.
6. Ericsson I, Berglundh T, Marinello C, Liljenberg B, Lindhe J. Long-standing plaque and gingivitis at implants and teeth in the dog. *Clin Oral Implants Res*. 1992;3:99–103.
7. Renvert S, Polyzois I, Maguire R. Re-osseointegration on previously contaminated surfaces: a systematic review. *Clin Oral Implants Res*. 2009;20 Suppl 4:216–227.
8. Schenk G, Flemmig TF, Betz T, Reuther J, Klaiber B. Controlled local delivery of tetracycline HCl in the treatment of periimplant mucosal hyperplasia and mucositis. A controlled case series. *Clin Oral Implants Res*. 1997;8:427–433.
9. Zablotsky MH, Diedrich DL, Meffert RM. Detoxification of endotoxin-contaminated titanium and hydroxyapatite-coated surfaces utilizing various chemotherapeutic and mechanical modalities. *Implant Dent*. 1992;1:154–158.
10. Mombelli A. Microbiology and antimicrobial therapy of peri-implantitis. *Periodontol 2000*. 2002;28:177–189.
11. Renvert S, Lessem J, Dahlen G, Lindahl C, Svensson M. Topical minocycline microspheres versus topical chlorhexidine gel as an adjunct to mechanical debridement of incipient peri-implant infections: a randomized clinical trial. *J Clin Periodontol*. 2006;33:362–369.
12. Park CY, Kim SG, Kim MD, Eom TG, Yoon JH, Ahn SG. Surface properties of endosseous dental implants after NdYAG and CO₂ laser treatment at various energies. *J Oral Maxillofac Surg*. 2005;63:1522–1527.
13. Kreisler M, Al Haj H, d'Hoedt B. Temperature changes at the implant-bone interface during simulated surface decontamination with an Er:YAG laser. *Int J Prosthodont*. 2002;15:582–587.
14. Huang HH, Chuang YC, Chen ZH, Lee TL, Chen CC. Improving the initial biocompatibility of a titanium surface using an Er,Cr:YSGG laser-powered hydrokinetic system. *Dent Mater*. 2007;23:410–414.
15. Mombelli A, Lang NP. The diagnosis and treatment of peri-implantitis. *Periodontol 2000*. 1998;17:63–76.
16. Persson LG, Ericsson I, Berglundh T, Lindhe J. Guided bone regeneration in the treatment of periimplantitis. *Clin Oral Implants Res*. 1996;7:366–372.
17. Darby I, Chen S, De Poi R. Ridge preservation: what is it and when should it be considered. *Aust Dent J*. 2008;53:11–21.
18. Claffey N, Clarke E, Polyzois I, Renvert S. Surgical treatment of peri-implantitis. *J Clin Periodontol*. 2008;35:316–332.
19. Schou S, Holmstrup P, Jorgensen T, et al. Anorganic porous bovine-derived bone mineral (Bio-Oss) and ePTFE membrane in the treatment of peri-implantitis in cynomolgus monkeys. *Clin Oral Implants Res*. 2003;14:535–547.
20. Schou S, Holmstrup P, Jorgensen T, Stoltze K, Hjorting-Hansen E, Wenzel A. Autogenous bone graft and ePTFE membrane in the treatment of peri-implantitis. I. Clinical and radiographic observations in cynomolgus monkeys. *Clin Oral Implants Res*. 2003;14:391–403.
21. Wetzel AC, Vlassis J, Caffesse RG, Hammerle CH, Lang NP. Attempts to obtain re-osseointegration following experimental peri-implantitis in dogs. *Clin Oral Implants Res*. 1999;10:111–119.
22. Schou S, Berglundh T, Lang NP. Surgical treatment of peri-implantitis. *Int J Oral Maxillofac Implants*. 2004;19 Suppl:140–149.
23. Nociti FH, Jr., Caffesse RG, Sallum EA, Machado MA, Stefani CM, Sallum AW. Evaluation of guided bone regeneration and/or bone grafts in the treatment of ligature-induced peri-implantitis defects: a morphometric study in dogs. *J Oral Implantol*. 2000;26:244–249.
24. Schwarz F, Jepsen S, Herten M, Sager M, Rothamel D, Becker J. Influence of different treatment approaches on non-submerged and submerged healing of ligature induced peri-implantitis lesions: an experimental study in dogs. *J Clin Periodontol*. 2006;33:584–595.
25. Schwarz F, Sahn N, Schwarz K, Becker J. Impact of defect configuration on the clinical outcome following surgical regenerative therapy of peri-implantitis. *J Clin Periodontol*. 2010;37:449–455.
26. Persson LG, Berglundh T, Lindhe J, Sennerby L. Re-osseointegration after treatment of peri-implantitis at different implant surfaces. An experimental study in the dog. *Clin Oral Implants Res*. 2001;12:595–603.
27. Persson LG, Mouhyi J, Berglundh T, Sennerby L, Lindhe J. Carbon dioxide laser and hydrogen peroxide conditioning in the treatment of periimplantitis: an experimental study in the dog. *Clin Implant Dent Relat Res*. 2004;6:230–238.
28. Fransson C, Tomasi C, Pikner SS, et al. Severity and pattern of peri-implantitis-associated bone loss. *J Clin Periodontol*. 2010;37:442–448.
29. Lindhe J, Meyle J. Peri-implant diseases: Consensus Report of the Sixth European Workshop on Periodontology. *J Clin Periodontol*. 2008;35:282–285.
30. Roos-Jansaker AM, Lindahl C, Persson GR, Renvert S. Long-term stability of surgical bone regenerative procedures of peri-implantitis lesions in a prospective case-control study over 3 years. *J Clin Periodontol*. 2011;38:590–597.