

# Safe Sinus Lift: Use of Acrylic Stone Trimmer to Avoid Sinus Lining Perforation

Prashanth Konatham Haribabu, BDS, MDS, MSD<sup>1\*</sup>  
 Krishna Kumar Raja, BDS, MDS<sup>2</sup>  
 Shankar Iyer, DDS, MDS<sup>3</sup>

Iatrogenic injury to the maxillary sinus membrane is a common complication during direct sinus lift procedures. The most common cause is perforation of the Schneiderian membrane using a tungsten-carbide round bur no.6. We propose a safe technique in which an acrylic stone trimmer is used to create a window in the maxillary antrum thereby minimizing the risk of injury to the delicate sinus membrane.

**Key Words:** *direct sinus lift, Schneiderian membrane perforation, acrylic stone trimmer, bovine bone graft, collagen membrane, dental implant*

## INTRODUCTION

The sinus lift procedure was introduced by Boyne et al<sup>1</sup> in early 1980s to overcome the anatomic limitation and gain vertical bone height in atrophic areas of the posterior maxilla to facilitate placement of dental implants.<sup>1,2</sup> This procedure has significantly contributed towards the application of the dental implants. Even though sinus membrane elevation is a relatively safe pre-prosthetic surgical procedure, there are some potential problems associated to the technique. The most prevalent intraoperative complication is iatrogenic perforation of the Schneiderian membrane (11%–56%).<sup>3</sup> The Schneiderian membrane of the maxillary antrum is a thin membrane that consists of periosteum covered with respiratory epithelium, which is delicate, friable, and easy to perforate. Disruption of sinus membrane leads to loss of graft material, early implant failure, and interruption of normal sinus physiological functions.<sup>4,5</sup> The literature shows that 30% of sinus membrane perforation occurs with the

use of rotary instruments and drills before the membrane is elevated.<sup>3</sup> It is very difficult to repair a tear or perforation in the sinus membrane by suturing because of its inaccessibility and the friable nature of the sinus lining membrane.<sup>6,7</sup>

The main purpose of this report is to demonstrate a new technique in which an antral opening is created using an acrylic stone trimmer, which is commonly used for prosthodontic laboratory purposes. This tool helps the clinician perform an atraumatic and safe sinus lift procedure to augment the posterior maxillary sinus floor using bovine bone graft.

## CASE REPORT

A 68-year-old woman reported to the Oral & Maxillofacial Surgery Unit at SRM Dental College, SRM University, Chennai, India, for implant rehabilitation of the edentulous upper right maxillary molar region (#1–#4). Radiographic examination (panoramic view) showed insufficient bony support as a result of severe alveolar bone resorption and pneumatization of maxillary sinus. The patient had no history of medical or surgical contraindications to undergo the surgical procedure. Therefore, a lateral sinus lift procedure was planned to augment the bone in the posterior maxillary sinus with subsequent placement of root-form dental im-

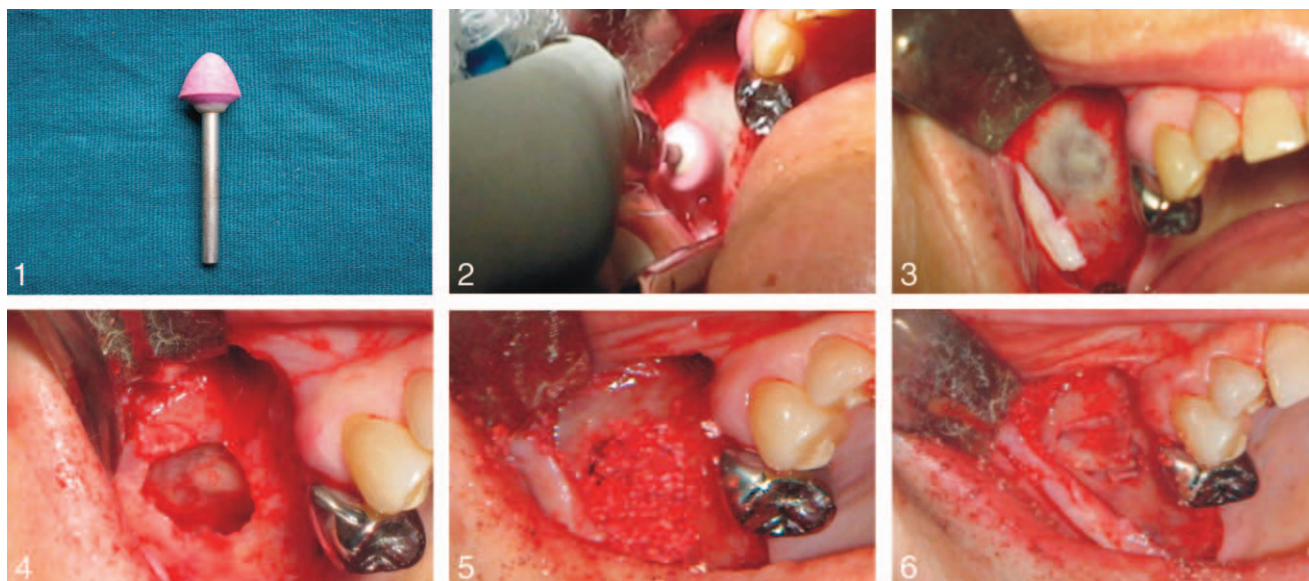
<sup>1</sup> Department of Diagnostic Science, New Jersey Dental School, University of Medicine and Dentistry of New Jersey, Newark, NJ.

<sup>2</sup> Department of Oral & Maxillofacial Surgery, SRM University, Ramapuram, Chennai, TN, India.

<sup>3</sup> Center for Reconstructive Dentistry, Smile USA, Elizabeth, NJ.

\* Corresponding author, e-mail: prasan777000@hotmail.com

DOI: 10.1563/AAID-JOI-D-12-00037



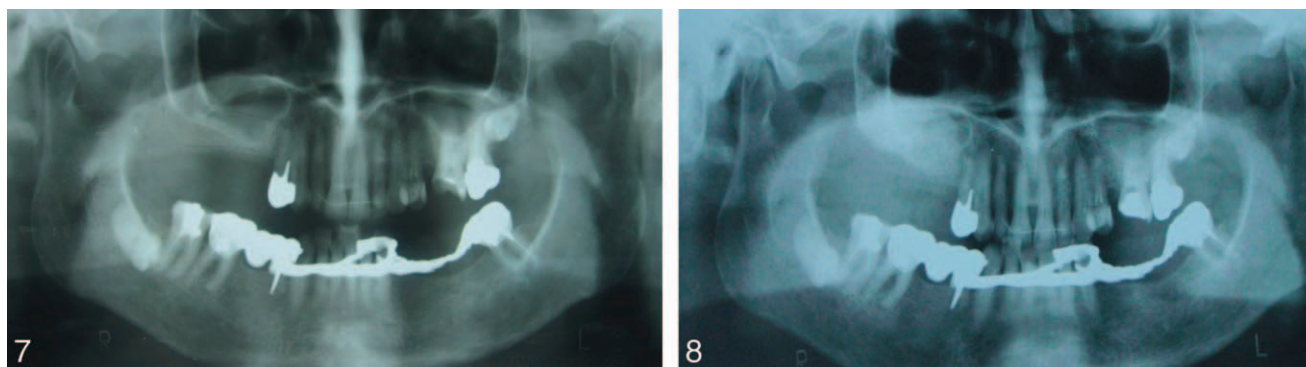
**FIGURES 1–6.** **FIGURE 1.** Acrylic stone trimmer. **FIGURE 2.** Preparation of the lateral window. **FIGURE 3.** Demonstration of the intact membrane. **FIGURE 4.** Sinus membrane lifted. **FIGURE 5.** Packing the antral cavity with bovine bone graft. **FIGURE 6.** Placement of collagen membrane.

plants. An informed written consent was obtained from the patient. Before surgery, she was provided with full details about the procedure and possible postoperative complications.

A sterile surgical area was prepared. Local anesthesia (lidocaine 2% with epinephrine 1:80,000, AstraZeneca Pharma, Bangalore, India) was administered to the buccal and palatal areas undergoing the procedure. A crestal incision was made on the edentulous zone with a buccal-releasing incision on the distal surface of the last tooth extending up to the tuberosity area. A full-thickness mucoperiosteal flap was raised to expose the maxillary alveolar process up to the lateral wall of the maxillary sinus. We had ingeniously used an acrylic stone trimmer (shape 1, size: 3/32" [2.35-mm shanks], Dedeco International Inc, Long Eddy, NY) attached to a straight surgical rotary handpiece (EX 6D, 1:1 Direct Drive, Nakanishi Inc, Tochigi-Ken, Japan) connected to a micromotor (NSK Z500, Nakanishi Inc, Tochigi-Ken, Japan) (Figure 1). The osteotomy milling was performed at 2500 rpm perpendicular to the lateral sinus wall with adequate external irrigation. The lateral window was successfully created without injuring the sinus membrane and root apices of the maxillary posterior teeth (Figure 2). The integrity of the schneiderian membrane was rechecked. The remaining thinned out bone around the orifice of the

lateral wall was carefully removed using a bone clipper, a procedure mimicking the removal of a cracked eggshell (Figure 3).

We were able to achieve 1.5-cm window orifice on the lateral maxillary sinus wall using the acrylic stone trimmer. The remaining adherent bone on the window was carefully infrafractured using a periosteal pusher. A blunt dissection was carried out using a set of sinus lift instruments. We were able to carefully detach and elevate the sinus membrane from the antral floor (Figure 4). A meticulous manipulation was necessary so that the integrity of the membrane would not rupture. The graft material used for the guided bone regeneration was bovine dried bone graft (Bio-Oss, Geistlich Pharma AG, Wolhusen, Switzerland) impregnated with fresh venous blood from the patient and collagen membrane (Bio-Guide, Geistlich Pharma AG) was used to cover the lateral window in the maxillary sinus wall. About 2.5 g of bovine dried bone graft was packed into the right maxillary antrum by elevating the sinus membrane. The bone was compacted meticulously using several blunt curettes of different shapes and sizes, while endeavoring to maintain the sinus membrane integrity (Figures 5 and 6). The mucoperiosteal flap was reapproximated and closed using simple interrupted sutures. The patient received oral antibiotic treatment with 500 mg of amoxicillin and 400 mg of



**FIGURES 7 AND 8.** **FIGURE 7.** Preoperative radiograph. **FIGURE 8.** Postoperative radiograph.

metronidazole every 8 hours for the next 5 days. She was supplemented with oral analgesics to manage pain and advised to use nasal decongestants during the postoperative period (Figures 7 and 8).

#### DISCUSSION

Placement of dental implants in severely atrophic maxilla is a serious challenge within the field of oral implantology. In the past, onlay bone grafts using rib or iliac crest were applied to augment an atrophic ridge.<sup>2,8</sup> The posterior segment of maxilla is usually compromised due to sinus pneumatization, bone resorption after tooth loss, or both. A deficient vertical height makes prosthodontic rehabilitation more complicated. To solve these problems, the maxillary lateral wall sinus lift procedure with bone grafting in the maxillary sinus provides an effective solution.<sup>5</sup>

The most common complication of sinus augmentation is membrane perforation. Ideal management of sinus membrane perforation is not clearly stated in the literature. Small perforations usually do not need treatment because the membrane folds itself during the elevation. Larger perforations are usually managed by use of collagen membrane and a block graft instead of a cancellous graft.<sup>9,10</sup>

Chanavaz classified complications into several categories: soft tissue perforation, sinus infection, hemosinus, and so forth.<sup>11</sup> He suggested that there is a disturbance in performing the procedure if the sinus membrane perforation is more than 3 mm. Vlassis and Fugazzotto<sup>12</sup> classified perforations of the sinus membrane into 5 groups based on location and difficulty to repair. Pikos<sup>13</sup> groups

sinus perforations by size: small (5–10 mm) and large (>10 mm). The success of sinus grafting depends primarily on the neovascularization of the graft mass, which is derived from the sinus floor.<sup>4</sup> Any sinus membrane perforation leads to inferior regenerative results of bone grafting procedure.<sup>10,14</sup>

Using a simple and cost-effective acrylic stone trimmer to create the lateral window in the maxillary sinus (similar to the Caldwell-Luc operation) helped us to maintain the integrity of the Schneiderian membrane. This tool also helped us to achieve full control of the rotary instrument while creating the window. These trimmers can be used as disposable instrument to ensure maximum milling efficiency (it prevents clogging of bone particles) and avoid contamination of the Schneiderian membrane. Conventional burs tend to damage and perforate the sinus membrane, which leads to failure of the sinus augmentation procedure and various complications. Even though a piezosurgery device is tuned to cut the bone only at specific frequency (25–30 kHz), the possibility of injury to the membrane still persists because of the transmission of mechanical heat energy to the soft tissues, which can perforate the sinus membrane.<sup>5</sup>

#### CONCLUSION

In conclusion, we would like to stress the importance of maintaining the integrity of the Schneiderian membrane during a direct sinus lift procedure for implant rehabilitation. We were able to achieve high implant success rate and avoid damaging the maxillary sinus membrane by using a simple, cost-effective, and disposable acrylic stone trimmer as the bur of choice.

## REFERENCES

1. Boyne PJ, Cole MD, Stinger D. A technique for osseous restoration of deficient edentulous maxillary ridges. *J Oral Maxillofac Surg.* 1985;43:87–91.
2. Boyne PJ, James RA. Grafting of the maxillary sinus floor with autogenous marrow and bone. *J Oral Surg.* 1980;38:613–616.
3. Wallace SS, Mazor Z, Froum SJ, Cho SC, Tarnow DP. Schneiderian membrane perforation rate during sinus elevation using piezosurgery: clinical results of 100 consecutive cases. *Int J Periodontics Restorative Dent.* 2007;27:413–419.
4. Kim KY, Hwang JW, Yun PY. Closure of large perforation of sinus membrane using pedicled buccal fat pad graft: a case report. *Int J Oral Maxillofac Implants.* 2008; 23:1139–1142.
5. Schlee M, Steigmann M, Garg AK. Piezosurgery: basics and possibilities. *Implant Dent.* 2006;15:334–340.
6. Choi BH, Zhu SJ, Jung JH, Lee SH, Huh JY. The use of autologous fibrin glue for closing sinus membrane perforations during sinus lifts. *Oral Surg Oral Med Oral Pathol Oral Radiol Endod.* 2006; 101:150–154.
7. Kaufman E. Maxillary sinus elevation surgery: an overview. *J Esthet Restor Dent.* 2003;15:272–282.
8. Terry BC, Albright JE, Baker RD. Alveolar ridge augmentation in the edentulous maxilla with use of autogenous ribs. *J Oral Surg.* 1974; 32:429–434.
9. Wheeler SL, Holmes RE, Calhoun CJ. Six year clinical and histologic study of sinus-lift grafts. *Int J Oral Maxillofac Implants.* 1996;11:26–34.
10. Zorzano LA, Tojo M. Maxillary sinus lift with intraoral autologous bone and B-tricalcium phosphate: histological and histomorphometric clinical study. *Med Oral Pathol Oral Cir Bucal.* 2007; 12:E532–E536.
11. Chanavaz M. Maxillary sinus: anatomy, physiology, surgery, and bone grafting related to implantology—eleven years of surgical experience (1979–1990). *J Oral Implantol.* 1990;16:199–209.
12. Vlassis JM, Fugazzotto PA. A classification system for sinus membrane perforations during augmentation procedures with options for repair. *J Periodontol.* 1999; 70:692–699.
13. Pikos MA. Maxillary sinus membrane repair: report of a technique for large perforations. *Implant Dent.* 1999; 8:29–34.
14. Proussaefs P, Lozada J, Kim J. Effects of sealing the perforated sinus membrane with a resorbable collagen membrane: a pilot study in humans. *J Oral Implantol.* 2003; 29:235–241.