

Utilization of Ethyl Cyanoacrylate and 2-Octyl Cyanoacrylate Adhesives for Autogenous Bone Graft Fixation: Histomorphometric Study in Rats

Jônatas Caldeira Esteves, DDS, MSc^{1*}
 Jônatas Mattos Monteiro, DDS²
 Alessandra Marcondes Aranega, DDS, MSc, PhD³
 Walter Betoni Junior, DDS, MSc, PhD⁴
 Celso Koogi Sonoda, DDS, MSc, PhD³

The present study analyzes the repair process of autogenous bone graft in a block fixed with ethyl cyanoacrylate and 2-octyl cyanoacrylate adhesives in rat calvaria. Forty-eight rats, divided into 3 groups, received round osteotomies at the right parietal bone for the attainment of autogenous bone graft fragment, which was fixed at the opposite side to the donor site with ethyl cyanoacrylate (ethyl group) and 2-octyl cyanoacrylate (octyl group) adhesives. In the control group, bone fragment was only juxtaposed at the parietal bone surface without any fixation material. The animals were euthanized after 10 and 60 postoperative days. The calvariae were processed in a laboratory for the attainment of slides stained through the hematoxylin and eosin technique for histological and histometric analysis. The qualitative analysis showed a discrete inflammatory infiltrate in the control group and moderate inflammatory infiltrate in the ethyl and octyl groups at the 10-day period, which remained at the 60-day period, mainly in the octyl group. The bone fragment remained bonded to the recipient site through the adhesive, but graft incorporation was not observed in any of the specimens. Resorption was higher in the octyl group followed by the ethyl and control groups, both at the 10- and 60-day periods, but with no statistical significance ($P < .05$). Although promoting graft fixation and its maintenance at the recipient site, both studied adhesives did not allow the graft incorporation, producing a localized and discrete inflammatory reaction, which persisted at 60 days, being more intense in the octyl cyanoacrylate group.

Key Words: *tissue adhesives, tissue repair, autogenous graft*

INTRODUCTION

From the viewpoint of biocompatibility and predictable results, the autogenous bone graft is the main resource for the reconstruction of maxillary defects, because it is the only option that associates

osteogenic, osteoinductive, and osteoconductive properties.¹ The successful autogenous bone graft is related to 3 factors that are essential during healing for its incorporation into the recipient site: suitable blood flow, absence of contamination, and fixation.²

In the last decade, plates, screws, and other metallic and biodegradable materials have been used for graft stability, as well as for the fixation of fractures of all craniofacial bones. This is due to the fact that these materials provide a rigid fixation with three-dimensional control of bone positioning.^{3,4} However, disadvantages such as inflammatory reactions, infection, cortical bone resorption, bone dislocation, and technique difficulty have led

¹ Department of Diagnosis and Surgery, Division of Periodontology, Universidade Estadual Paulista, School of Dentistry, Araraquara, Brazil.

² Private practice, Araçatuba, Brazil.

³ Department of Surgery and Integrated Clinic, Universidade Estadual Paulista, School of Dentistry, Araçatuba, Brazil.

⁴ Oral and Maxillofacial Surgery, Cuiabá University-UNIC, Cuiabá, Brazil

* Corresponding author, e-mail: jonatasce@hotmail.com
 DOI: 10.1563/AAID-JOI-D-12-00063

medical and dental researchers to search for alternative methods of bone fixation.^{4,5} Tissue adhesives are a potential option for this purpose.

Cyanoacrylates are polymeric plastic adhesives condensed in a formaldehyde base, characterized by their polymerization in the presence of water.^{5,6} The most interesting properties of adhesives are their quick polymerization, strong adherence to the surfaces where they are applied, biocompatibility,⁷⁻⁹ and bacteriostatic^{10,11} and hemostatic¹² effects. The first cyanoacrylate-based adhesive utilized on living tissues was methyl-2 cyanoacrylate, which was toxic and caused edema and tissue necrosis.¹³ In attempts to decrease adhesive toxicity, new compounds were developed, replacing methyl by ethyl, butyl, or octyl, to obtain more favorable biological behavior.¹⁴ The adhesive degradation rate is inversely proportional to its molecular chain length, and is directly related to the level of local inflammation and toxicity.¹³

Cyanoacrylates have hemostatic, embolic, and adhesive properties. Currently, the medical literature describes their successful use for cutaneous wound closure¹⁵ or surgical incision closure,¹⁶ closure or prevention of fistulae,¹⁷ aneurism embolization,¹⁸ and treatment of hemorrhages in esophageal varicosities.¹⁹

The use of cyanoacrylates for osteosynthesis is rare. Some experimental studies have reported their utilization in the fixation of the nasal septum of rabbits,⁸ osteosynthesis of experimentally created defects,^{5,15} and experimental treatment of zygomatic fractures,⁹ in addition to studies in humans with osteochondral fracture reduction,²⁰ and reconstruction of orbital wall fractures¹¹ and mandibular fractures.²¹ All studies showed promising results concerning the fragment's joint stability and satisfactory histological behavior with the adjacent tissues.

Bone graft fixation, intra- or extra-orally, with tissue adhesives based on cyanoacrylate could significantly improve this surgical technique, ensuring more comfort for the patient, eliminating the need for bone perforation for screw installation, and eliminating the need for posterior screw removal. Moreover, our understanding of cyanoacrylate's biological behavior related to bone tissue structure would allow for the establishment of new perspectives for adhesive clinical use. Therefore, the purpose of this study was to analyze, histomorpho-

metrically, the repair process of an autogenous bone graft fixed *en bloc* with ethyl cyanoacrylate and 2-octyl cyanoacrylate adhesives in rat calvaria, as well as to test the capacity of these adhesives to maintain the grafted bone bulk.

MATERIALS AND METHODS

For this experiment (Research Ethics Committee Protocol #2008-005587), 48 male adult rats were used (*Rattus norvegicus albinus*, Wistar), with a mean weight of 250 g. During all experiments, the animals were kept in cages at the Vivarium of the Surgery and Integrated Clinics Department and fed with solid animal food (Ração Guabi Nutrilabor, Campinas-SP, Brazil) and water *ad libitum*, except in the fasting periods (8–10 h) that preceded the surgical procedure, in which they received only water.

Animals were randomly divided into 3 experimental groups: Group I, Control; Group II, ethyl cyanoacrylate; and Group III, 2-octyl cyanoacrylate. The animals were studied for 10 and 60 days, with 8 animals in each group *per period*.

After anesthesia with intramuscular xylazine hydrochloride (10 mg/kg) (Coopers Brasil Ltda, Cotia-SP, Brazil) and ketamine hydrochloride (80 mg/kg; Fort Dodge Saúde Animal Ltda, Campinas-SP, Brazil), trichotomy and antisepsis were accomplished with 10% polyvinylpyrrolidone iodine (PVP-I) in the frontoparietal region. The animals received a medium longitudinal incision of approximately 20 mm in the scalp over the calvarial sagittal suture, followed by soft tissue dissection, exposing the parietal bones. In each animal of the control group, with a 3-mm-diameter trephine bur at low speed, a rounded osteotomy was performed in the right parietal bone under constant irrigation of 0.9% physiological saline solution, yielding a rounded bone fragment, while maintaining the integrity of the dura mater and brain. With the aid of a #8 spherical bur at low speed, the left parietal bone was decorticalized, and on its surface the bone fragment was fixed with ethyl- and 2-octyl cyanoacrylate in groups II and III, respectively. In the control group, after decorticalization, the graft was positioned only at the recipient site, without any type of fixation material. The flap was repositioned and sutured with a continuous spiral suture with Mono Nylon 5-0 (Ethicon, Johnson & Johnson, São Paulo-SP, Brazil).

The animals were euthanized at 10 and 60 days

postoperatively. The calvariae of each animal were removed, and the left parietal bones containing the grafts were separated, with the suprapariosteal soft tissues preserved. The pieces were fixed in 10% formaldehyde and subsequently subjected to routine laboratory processing. The blocks were cross-sectionally cut in serial 6- μ m-thick pieces in such a way that the most central region of the graft was cut and then stained by hematoxylin and eosin.

A single trained examiner analyzed the obtained slides qualitatively using an optical microscope (Aristoplan-Leitz, Leica Microsystems, Wetzlar, Hesse, Germany). For histological analysis at the graft/recipient site interface, the following were considered: the presence of adhesive fragments, inflammatory infiltrate, fibroblastic proliferation, and the presence of new bone and capillary formation, graft vitality, and resorption level, in both superficial and deep tissues, at both periods studied.

To determine the absence or presence and intensity of the inflammatory process, we quantified the number of inflammatory cells in 5 different fields of the same specimen examined at $\times 400$ magnification by optical microscopy. The inflammatory process was considered discrete when the number of inflammatory cells was lower than 100, moderate between 100 and 500, and intense when higher than 500.

For quantitative analysis, the slides obtained from the histological cuts were analyzed by optical microscopy (Aristoplan-Leitz) at $\times 2.5$ magnification, through a camera (Axio Cam Mrc5-Zeiss, Carl Zeiss, Obercocher, Baden-Württemberg, German) connected to a computer which, by means of AxioVision 4.5 software (Carl Zeiss), converted the images into digital "TIF" archives. The bone graft size was quantified at 10 and 60 days through digital images opened by Imagelab 2000 software (Diracon Bio Informática Ltda, Vargem Grande do Sul, São Paulo, Brazil). With the "Areas Selection" tool, the entire image area corresponding to the bone graft was delimited. Subsequently, with the "Areas Calculation" and "Calculation Table" tools, a value in pixels corresponding to the selected area was provided. This value was used for statistical analysis.

Statistical analysis was accomplished with GMC 9 software (created by Geraldo Maia, FORP-USP). Initially, data were subjected to a normal curve adherence test, which showed nonparametric behavior. Thus, we used the Kruskal-Wallis test to compare

the sample data at 10 and 60 days. Later, the Mann-Whitney test was used for individual comparisons.

RESULTS

After the animals' death, all graft fragments were fixed to the recipient site, in both the control and the adhesive groups. There was no presence or sign of infection or active suppuration, at both the 10- and 60-day periods.

Qualitative results at 10 days

Group I

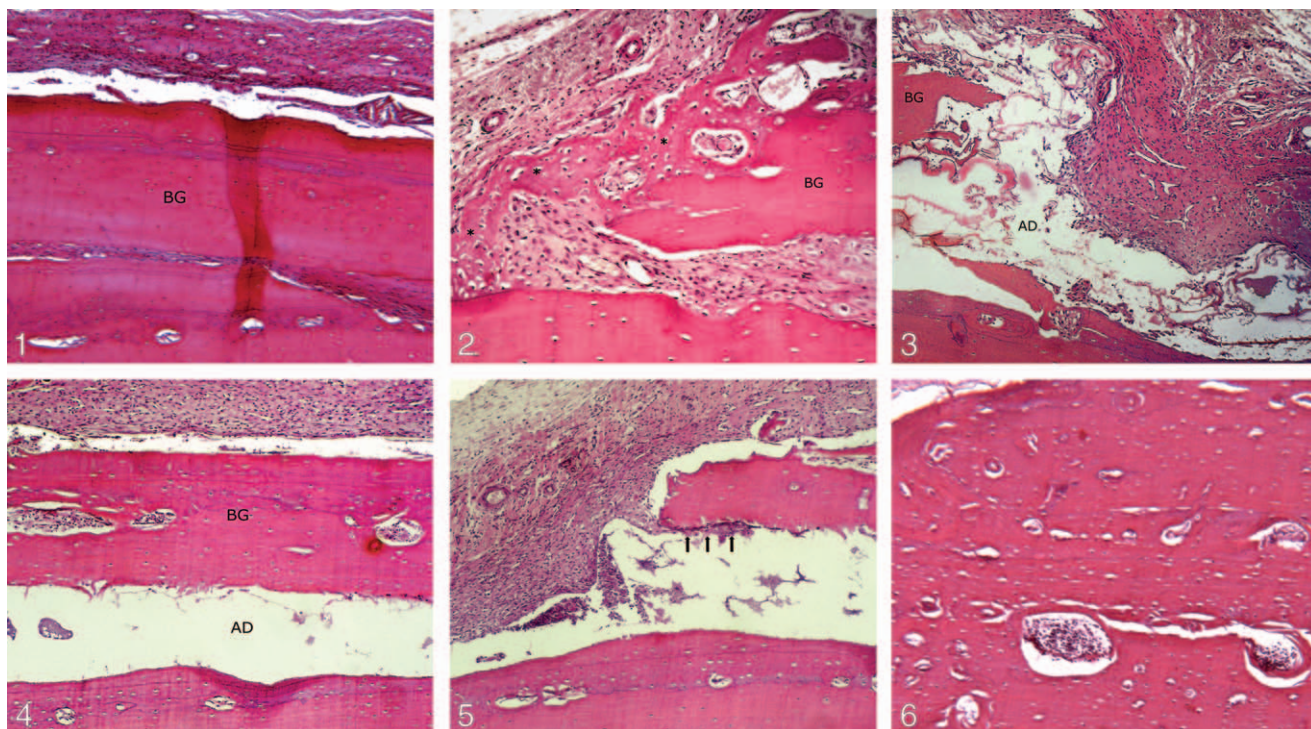
Superficially, the periosteum presented hyperplasia with a discrete inflammatory infiltrate. Underneath, the graft was observed, with most of its lacunae filled by osteocytes. At the interface between the graft and the recipient site, it was possible to observe a thin layer of compact fibrous connective tissue and points of bone remodeling at both the graft and the parietal bone (Figure 1). At the peripheral regions, we observed areas with initial new bone formation from the graft fragment, recipient site, and periosteum (Figure 2).

Group II

Similarly to the control group, the periosteum on the graft presented hyperplasia and a moderate inflammatory cell infiltrate. Most of the osteocyte lacunae were empty. The entire bone interface region presented residual cyanoacrylate, which established proximity with the bone surface, with apparent inflammation. In some specimens, it was possible to notice discrete areas of new bone formation and resorption at the interface with the cells derived from the medullar spaces of the recipient site. At the graft margins, where adhesive was in direct contact with the connective tissue, a moderate inflammatory infiltrate was observed. Also at this region, there was connective tissue proliferation with a high quantity of collagen fibers and blood vessels, from the parietal bone surface superior to the periosteum (Figure 3). At the region closer to the periosteum, this tissue assumed a less cellular aspect, filled by osteoid matrix.

Group III

Moderate to severe inflammation was observed at the periosteum. The bone graft was cellularized in



FIGURES 1–6. **FIGURE 1.** Group I: 10 days: Superficially, corrugated periosteal tissue with fibers parallel to graft surface. Bone graft fragment (BG) with osteocyte lacunae. Interface area filled by fibrous connective tissue (hematoxylin and eosin, original $\times 125$). **FIGURE 2.** Group I: 10 days: Graft peripheral area, where it is possible to observe areas of bone new formation (asterisks) from the graft fragment (BG) and from the parietal bone (OP) (hematoxylin and eosin, original $\times 160$). **FIGURE 3.** Group II: 10 days: Bone graft (BG) peripheral area. Direct contact of the adhesive (AD) with fibrous connective tissue which is presented with moderate inflammatory infiltrate (hematoxylin and eosin, original $\times 160$). **FIGURE 4.** Group III: 10 days: Thick periosteal tissue with moderate inflammatory infiltrate. Underneath, bone graft (BG) with osteocyte lacunae and intratrabeular spaces filled by connective tissue. 2-octyl cyanoacrylate adhesive (AD) filling the entire interface area of graft-recipient site (hematoxylin and eosin, original $\times 125$). **FIGURE 5.** Group III: 10 days: Graft margins: contact between adhesive and fibrous connective tissue with moderate inflammatory infiltrate. Migration of connective tissue with inflammatory cells through the interface area (arrows) (hematoxylin and eosin, original $\times 160$). **FIGURE 6.** Group I: 60 days: Union between bone graft and recipient site through mature bone (hematoxylin and eosin, original $\times 125$).

almost all specimens. Adhesive filled all interface areas, as in the ethyl group (Figure 4). At the graft margins, it was possible to observe inflammatory cells and collagen fibers toward the interface center, from the interior surface of the graft (Figure 5). The connective tissue at the margins of the graft and under the periosteum presented moderate to intense inflammation, mainly at the areas near the adhesive, without apparent new bone formation.

Qualitative results at 60 days

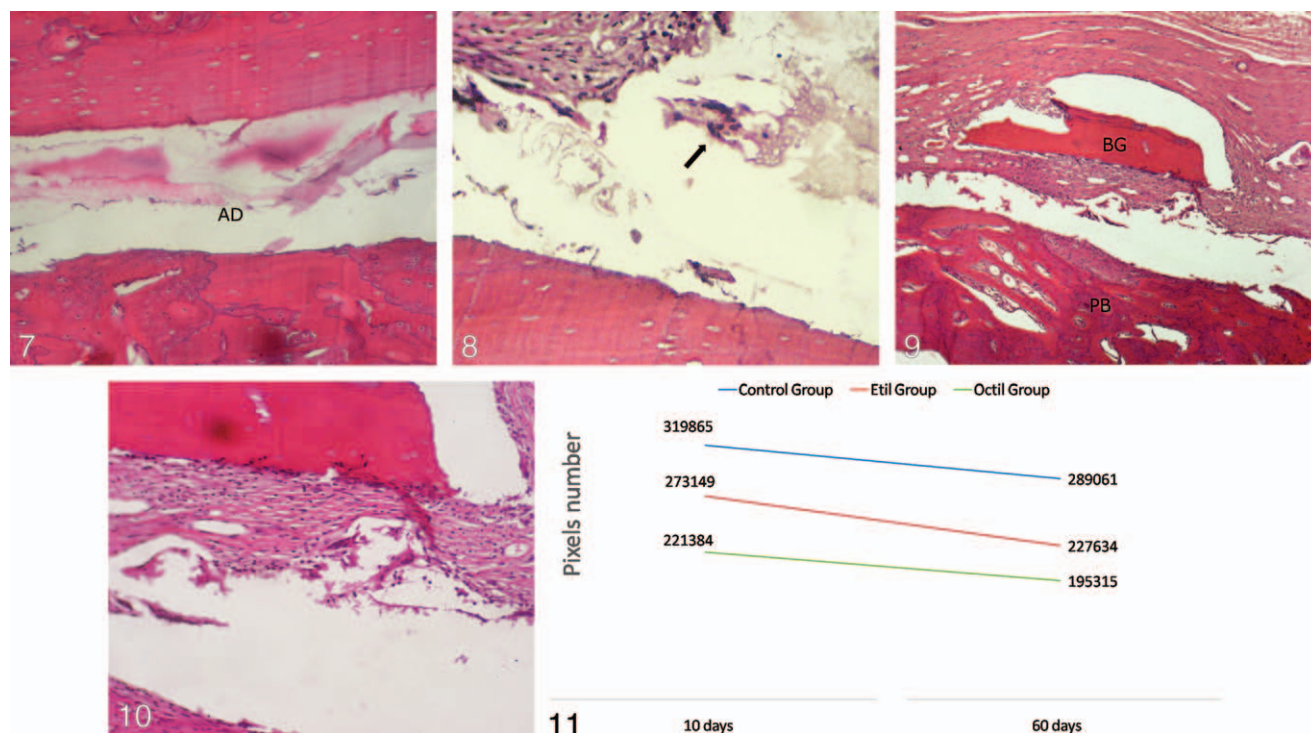
Group I

At 60 days, the periosteal layer over the graft showed no signs of hyperplasia and presented a discrete inflammatory infiltrate. Bone graft was incorporated into the recipient site through newly formed bone tissue at the interface region. In

several specimens, this new bone formation occurred only at the central third of the graft, with margins connected to the donor site by a dense connective tissue. The graft had an aspect of mature bone, well-vascularized and with lacunae filled by osteocytes in the Haversian systems (Figure 6).

Group II

A thin periosteum with discrete inflammatory infiltrate covered the bone graft fragment, which showed signs of resorption and the presence of osteoclastic cells from the periosteum, at both upper and peripheral areas. Some osteocyte lacunae of the areas in contact with the periosteum were filled by basophilic nuclei. However, most remained empty. The interface area was filled by the adhesive with no signs of bone apposition or resorption (Figure 7). At graft margins and interface



FIGURES 7–11. **FIGURE 7.** Group II: 60 days: Adhesive (AD) permanence at the interface between graft and recipient site. Graft has few signs of bone remodeling, mainly at the area near to the adhesive (hematoxylin and eosin, original $\times 160$). **FIGURE 8.** Group II: 60 days: Interface peripheral area. Presence of fibrous connective tissue with moderate inflammatory infiltrate and multinucleated giant cells (arrow) in contact with the adhesive (hematoxylin and eosin, original $\times 250$). **FIGURE 9.** Group III: 60 days: Bone graft fragment (BG) extensively resorbed surrounded by connective tissue presenting moderate inflammatory infiltrate, also at the parietal bone (PB). Adhesive persistence filling the entire area of graft-recipient site interface (hematoxylin and eosin, original $\times 125$). **FIGURE 10.** Group III: 60 days: Fibrous connective tissue surrounding the graft, separating it from the adhesive, infiltrated by inflammatory (hematoxylin and eosin, original $\times 250$). **FIGURE 11.** Mean (in pixels) of the bone grafts area at 10 and 60 days in control, ethyl and octyl groups.

peripheral areas, adhesive fragments were observed surrounded by multinucleated cells and moderate inflammatory infiltrate, composed mainly of lymphocytes and macrophages. In this same area, new bone formation was observed at the bone graft and recipient site (Figure 8).

Group III

The periosteal layer, in some specimens, presented persistent and discrete inflammation. In almost half of the animals, the graft fragment was intensely resorbed and lacked vitality (Figure 9). Adhesive still filled all interface areas, mainly at the graft central area, which remained without vitality. In some specimens, there was a migration of the fibrous connective tissue over the adhesive and under the graft fragment, encapsulating and isolating it from the recipient site. Similarly to the ethyl group, no specimen showed a complete union between the bone graft and the recipient site. Near the graft

margins, a dense connective tissue was in contact with the adhesive, where multinucleated cells and intense inflammatory infiltrate, mainly lymphocytes and macrophages, were observed (Figure 10).

Quantitative results

Quantitative results are shown in Figure 11. At 60 days, the grafts in all the groups demonstrated volumetric loss; however, there was no statistically significant difference among them.

DISCUSSION

It is known that titanium screws clinically represent the gold standard for bone graft fixation.²² In the present study, it was not possible to use this procedure, due to the lack of titanium screws produced especially for the region studied, since the thinness of the rats' parietal bone did not allow for the utilization of commercial screws. Therefore,

to obtain a control group, we compared bone fragments fixed with adhesives with a group where the graft remained juxtaposed only to the recipient site. The results of this group showed that the choice of the surgical technique of graft obtainment and recipient site was correct, since the repair occurred satisfactorily over the periods studied.

Partial graft resorption is a natural process during the remodeling stage. However, the presence of inflammatory reaction or micromovements accelerates this process. It is important to establish that the bone graft at the calvaria, as proposed in the present study, is subject to poor micromovements, which certainly contributed to its incorporation into the recipient site in the control group. The same certainly would not be observed in environments more susceptible to stresses and tensions, such as the oral cavity.

In an experimental study with rabbit calvaria, Saska et al²³ fixed autogenous bone blocks with ethyl cyanoacrylate or titanium screws. Despite the adhesive biocompatibility and maintenance of bone block stability in both groups, the authors did not observe graft incorporation into the recipient site.

The biological behavior of cyanoacrylates for internal use is still controversial. Toriumi et al⁶ found acute inflammation with seroma formation when fixing autogenous bone fragments to the auricular cartilage of rabbits with ethyl and butyl cyanoacrylate, while experimental studies found favorable histological responses with the utilization of butyl cyanoacrylate for bone fixation.^{5,24} These authors observed a foreign body reaction with a discrete, but persistent, inflammatory infiltrate at tissues adjacent to the adhesive, but with no toxic effects or necrosis.

In the present study, both adhesives showed a moderate to intense inflammatory infiltrate at 10 days, mainly at areas where adhesive had direct contact with the connective tissue, which persisted at the 60-day period, mainly in group III. The contact of adhesives with bone did not produce direct bone lesions or necrosis at the recipient site, which is in accordance with other studies' findings of good tolerance of bone tissue to cyanoacrylates.^{5,11,23,24} Histotoxicity of cyanoacrylates, according to the literature, is a result of cellular reactions to formaldehyde and oxygenated compounds produced during product polymerization, as well as to

the acid medium in which the polymer is maintained to remain liquid.¹³

Generally speaking, group III showed a more intense inflammatory process and higher bone graft resorption. There is a vast quantity of literature concerning the clinical and histological descriptions of 2-octyl cyanoacrylate adhesive for external use on skin;^{15,25-27} however, no reports were found concerning the adhesive behavior in bone tissue. Previous studies comparing the toxicity of cyanoacrylates reported that adhesives with a higher molecular chain, such as butyl and octyl cyanoacrylate, had more biological acceptance and, therefore, a lower inflammatory reaction when compared with adhesives with a shorter molecular chain, such as methyl and ethyl cyanoacrylate.^{6,28} This pattern of histological behavior has not necessarily been confirmed in studies utilizing these adhesives in bone or cartilage tissues, since both ethyl and butyl cyanoacrylate have been shown to be adequate for osteosynthesis.^{5,8,9,11,20,21,24} The histological and histometric analysis of the octyl group showed the worst results concerning the inflammatory process and graft resorption, which, theoretically, does not classify it as a more biocompatible adhesive, even with the higher molecular chain.

Despite the noticeable capacity for bone graft retention at the recipient site in both groups II and III, graft incorporation was not observed in both groups at 60 days. The histological results showed that the adhesive permanence at the interface did not allow for graft revascularization, which, in normal conditions, would occur from the recipient site. This process is evident in group I, where, at 60 days, it was possible to observe graft incorporation and remodeling. In groups II and III, bone remodeling was observed only at the areas in direct contact with the periosteum and, on a lower level, at the graft margins.

The higher graft fragment resorption evidenced by the histometric analysis of groups II and III in comparison with group I may be attributed to the absence of graft incorporation into the recipient site, and also to the persistent inflammatory reaction in both groups. This fact is more evident in group III, which qualitatively presented the higher inflammatory reaction and quantitatively the higher graft resorption in comparison with the other two groups. Despite the evidence found in this study concerning the inflammatory reaction to

adhesives and graft resorption, other studies should be conducted with a longer experimental period, to determine the permanence of this material, or lack thereof, on bone tissue.

According to the results obtained, and within the limitations of this study, it was possible to conclude that, although the adhesives promoted bone graft fixation and maintenance, none of them allowed the direct graft incorporation into the recipient site, determining a local and discrete inflammatory reaction that persisted at 60 days, and this reaction was more intense in the octyl cyanoacrylate group.

REFERENCES

- Burchardt H. The biology of bone graft repair. *Clin Orthop Relat Res.* 1983;174:28–42.
- Chiapasco M, Zaniboni M. Failures in jaw reconstructive surgery with autogenous onlay bone grafts for pre-implant purposes: incidence, prevention and management of complications. *Oral Maxillofac Surg Clin North Am.* 2011;23:1–15.
- Suuronen R. Biodegradable fracture-fixation devices in maxillofacial surgery. *Int J Oral Maxillofac Surg.* 1993;22:50–57.
- Ahn DK, Sims CD, Randolph MA, et al. Craniofacial skeletal fixation using biodegradable plates and cyanoacrylate glue. *Plast Reconstr Surg.* 1997;99:1508–1515.
- Shermak MA, Wong L, Inoue N, et al. Fixation of the craniofacial skeleton with butyl-2-cyanoacrylate and its effects on histotoxicity and healing. *Plast Reconstr Surg.* 1998;102:309–318.
- Toriumi DM, Raslan WF, Friedman M, Tardy ME. Histotoxicity of cyanoacrylate tissue adhesives. A comparative study. *Arch Otolaryngol Head Neck Surg.* 1990;116:546–550.
- Gonzalez E, Orta J, Quero C, et al. Ethyl-2-cyanoacrylate fixation of the cranial bone flap after craniotomy. *Surg Neurol.* 2000;53:288–289.
- Alkan S, Dadaş B, Celik D, Coskun BU, Yilmaz F, Başak T. The efficacy of N-2-butyl cyanoacrylate in the fixation of nasal septum to the anterior nasal spine in rabbits: experimental study. *Eur Arch Otorhinolaryngol.* 2007;264:1425–1430.
- Dadaş B, Alkan S, Cifci M, Başak T. Treatment of tripod fracture of zygomatic bone by N-2-butyl cyanoacrylate glue fixation, and its effects on the tissues. *Eur Arch Otorhinolaryngol.* 2007;264:539–544.
- Howell JM, Bresnahan KA, Stair TO, Dhindsa HS, Edwards BA. Comparison of effects of suture and cyanoacrylate tissue adhesive on bacterial counts in contaminated lacerations. *Antimicrob Agents Chemother.* 1995;39:559–560.
- Kim YO. Use of cyanoacrylate in facial bone fractures. *J Craniofac Surg.* 1997;8:229–234.
- Lumsden AB, Heyman ER. Closure Medical Surgical Sealant Study Group. Prospective randomized study evaluating an absorbable cyanoacrylate for use in vascular reconstructions. *J Vasc Surg.* 2006;44:1002–1009.
- Tseng YC, Tabata Y, Hyon SH, Ikada Y. In vitro toxicity test of 2-cyanoacrylate polymers by cell culture method. *J Biomed Mater Res.* 1990;24:1355–1367.
- Eaglstein WH, Sullivan T. Cyanoacrylates for skin closure. *Dermatol Clin.* 2005;23:193–198.
- Bruns TB, Worthington JM. Using tissue adhesive for wound repair: a practical guide to Dermabond. *Am Fam Physician.* 2000;61:1383–1388.
- Durai R, Ng PC. Easy way of gluing the skin of surgical wounds. *Int J Clin Pract.* 2009;63:1115–1117.
- Yuen HK, Cheng AC, Auyeung KC. Late-onset occult cerebrospinal fluid leakage after orbital exenteration. *Ophthal Plast Reconstr Surg.* 2008;24:238–240.
- Tokuda T, Tanigawa N, Shomura Y, et al. Transcatheter embolization for peripheral pseudoaneurysms with n-butyl cyanoacrylate. *Minim Invasive Ther Allied Technol.* 2009;18:361–365.
- Cipolletta L, Zambelli A, Bianco MA, et al. Acrylate glue injection for acutely bleeding oesophageal varices: a prospective cohort study. *Dig Liver Dis.* 2009;41:729–734.
- Yilmaz C, Kuyurtar F. Fixation of a talar osteochondral fracture with cyanoacrylate glue. *Arthroscopy.* 2005;21:1009.
- Mehta MJ, Shah KH, Bhatt RG. Osteosynthesis of mandibular fractures with N-butyl cyanoacrylate: a pilot study. *J Oral Maxillofac Surg.* 1987;45:393.
- Noda K, Tanikawa R, Sugimura T, et al. Use of bioabsorbable plates for cranial fixation. *Neurol Med Chir.* 2009;49:559–562.
- Saska S, Hochuli-Vieira E, Minarelli-Gaspar AM, Gabrielli MF, Capela MV, Gabrielli MA. Fixation of autogenous bone grafts with ethyl-cyanoacrylate glue or titanium screws in the calvaria of rabbits. *Int J Oral Maxillofac Surg.* 2009;38:180–186.
- Amarante MT, Constantinescu MA, O'Connor D, Yaremchuk MJ. Cyanoacrylate fixation of the craniofacial skeleton: an experimental study. *Plast Reconstr Surg.* 1995;95:639–646.
- Souza EC, Fitaroni RB, Januzelli DM, Macruz HM, Camacho JC, Souza MR. Use of 2-octyl cyanoacrylate for skin closure of sternal incisions in cardiac surgery: observations of microbial barrier effects. *Curr Med Res Opin.* 2008;24:151–155.
- Mangano A, Albertin A, LaColla L. Use of 2-octyl-cyanoacrylate skin adhesive (Dermabond) for wound closure following reduction mammoplasty: a prospective, randomized intervention study. "Tips and tricks" to improve statistical analysis and significance of results. *Plast Reconstr Surg.* 2009;124:669.
- Perin LF, Helene A Jr, Fraga MF. Sutureless closure of the upper eyelids in blepharoplasty: use of octyl-2-cyanoacrylate. *Aesthet Surg J.* 2009;29:87–92.
- Lerner R, Binur NS. Current status of surgical adhesives. *J Surg Res.* 1990;48:165–181.