

Histologic Evaluation of Osseous Regeneration Following Combination Therapy With Platelet-Rich Plasma and Bio-Oss in a Rat Calvarial Critical-Size Defect Model

Philip J. DeNicolò, DMD¹
 M. Kelly Guyton, PhD²
 Michael F. Cuenin, DMD³
 Steven D. Hokett, DDS⁴
 Mohamed Sharawy, PhD⁵
 James Borke, PhD⁶
 James C. McPherson III, PhD^{2*}

Platelet-rich plasma (PRP) is an autogenous source of growth factors shown to facilitate human bone growth. Bio-Oss, an osteoconductive xenograft, is used clinically to regenerate periodontal defects, restore dental alveolar ridges, and facilitate sinus-lift procedures. The purpose of this study was to analyze whether a combination of PRP and Bio-Oss would enhance bone regeneration better than either material alone. PRP and/or Bio-Oss were administered in an 8-mm critical-size defect (CSD) rat calvarial model of bone defect between 2 polytetrafluoroethylene membranes to prevent soft tissue incursion. Eight weeks after the induction of the CSD, histologic sections were stained with hematoxylin and eosin stain and analyzed via light microscopy. Qualitative analyses revealed new bone regeneration in all 4 groups. The Bio-Oss and PRP plus Bio-Oss groups demonstrated greater areas of closure in the defects than the control or PRP-only groups because of the space-maintaining ability of Bio-Oss. The groups grafted with Bio-Oss showed close contact with new bone growth throughout the defects, suggesting a stronger graft. The use of PRP alone or in combination with Bio-Oss, however, did not appear to enhance osseous regeneration at 8 weeks. Areas grafted with Bio-Oss demonstrated greater space-maintaining capacity than controls, and PRP was an effective vehicle for placement of the Bio-Oss. However, at 8 weeks this study was unable to demonstrate a significant advantage of using PRP plus Bio-Oss over using Bio-Oss alone.

Key Words: bone regeneration, platelet-rich plasma, Bio-Oss

INTRODUCTION

Inflammation and alveolar bone loss are hallmarks of periodontal disease, and historically, regenerative attempts have involved a myriad of techniques and materials usually consisting of bone grafts and/or barrier membranes to repair bony defects.¹ While great strides have been made in periodontal research, novel therapies that improve bone regeneration are still needed, and combining treatments that have already demonstrated partial bone restoration may offer greater efficacy than single therapies.

Platelet-rich plasma (PRP), which provides an enhanced

concentration of platelets compared with blood, has gained wide interest as a therapy for soft and hard tissue injuries. Blood platelets are an invaluable source of growth factors that modulate critical cellular events involved in wound-healing responses.² In addition, many of the growth factors released from activated platelets are osteoinductive.³ Examples of growth factors found in PRP that may aid in bone regeneration are platelet-derived growth factor (PDGF), transforming growth factor beta (TGF- β), and insulin-like growth factors (IGF; IGF-I and IGF-II).⁴ An added benefit of using PRP as a potential therapy for bone loss is that PRP is autologous, nontoxic, and nonimmunoreactive.

Bone substitutes such as Bio-Oss (Ed Geistlich Sons, Wolhusen, Switzerland), a bovine bone derivative, have demonstrated efficacy in bone regeneration. Bio-Oss is a natural material made of anorganic bovine bone containing carbonate apatite with macro- and microconfigurations closely parallel to that of the structure of human bone.⁵ One advantage of using Bio-Oss is that Bio-Oss has been completely deorganified by a proprietary extraction process that makes it free of antigenicity.⁶ Bio-Oss also possesses osteoconductive properties that may aid in bone formation in periodontal bone

¹ US Army Dental Activity, Dental and Trauma Research Detachment, Fort Sam Houston, San Antonio, Tex.

² Department of Clinical Investigation, D. D. Eisenhower Army Medical Center, Fort Gordon, Ga.

³ Private Practice, Mount Pleasant, SC.

⁴ Private Practice, Vancouver, Wash.

⁵ Department of Oral Biology, Medical College of Georgia, Augusta, Ga.

⁶ College of Dental Medicine, Western University of Health Sciences, Pomona, Calif.

* Corresponding author, e-mail: james.c.mcpherson4.civ@mail.mil

DOI: 10.1563/AAID-JOI-D-12-00075

defects.⁷ A recent study in a canine model of dental implants indicated that bone regeneration in groups that received Bio-Oss in the defect was similar to that in autologous bone.⁸ However, previous studies have indicated that Bio-Oss is not completely resorbable, and the amount of bone regeneration has been variable.⁹ A Cochrane review of the clinical trial literature for Bio-Oss and other bone augmentations therapies, alone or in combination, for dental implants suggests that many studies were not powered sufficiently to detect true benefits.¹⁰ Thus, further studies are necessary to dissect the potential benefits of Bio-Oss, particularly in combination with other materials.

Previous research has addressed the use of growth factors, alone or in combination with Bio-Oss or other grafting materials, to enhance bone regeneration. Bio-Oss may provide an appropriate carrier vehicle for growth factors to allow for rapid repair of bony defects. In an *in vitro* study, Tsay et al¹¹ observed that PRP, combined with different bone substitutes (including Bio-Oss) and activated with thrombin receptor activator peptide-6, retained significant growth factor levels, allowing for a longer growth factor release for up to 14 days. The effects of bone substitutes on the repair of critical-size defects (CSDs) in rat calvarial, a model for craniomandibulofacial nonunions, has been used routinely to identify potential therapies to enhance bone growth.¹² The combination of osteoinduction by PRP and osteoconduction with Bio-Oss could potentially enhance bone regeneration and serve as a model for future studies.

The current study combined PRP with Bio-Oss to engineer a grafting combination that may promote bone regeneration to a greater extent than each material used separately in the CSD model. The major objectives of the current study were to analyze whether a combination of PRP and Bio-Oss would enhance bone regeneration and/or close the CSD more efficiently than either material alone.

MATERIALS AND METHODS

Animal care

Animal care was delivered in accordance with the guidelines established by, and oversight provided by, the Institutional Animal Care and Use Committee, Dwight David Eisenhower Army Medical Center, Fort Gordon, Ga. Food (Teklad Rodent Blocks, Harlan, Indianapolis, Ind) and water were available *ad libitum*.

Animals used

Forty-eight adult male Sprague-Dawley rats (Harlan), of the same genetic strain and weighing 325–375 g, were quarantined for 7 days then randomly divided into 4 groups of 12 rats each.

PRP and Bio-Oss preparations

The PRP was prepared in the following manner: citrated blood (0.105 M sodium citrate) was obtained from donor rats of the same experimental population. Animals were anesthetized intraperitoneally with 65 mg/kg ketamine and 7 mg/kg xylazine. Anesthetic depth was monitored to ensure that the

procedure was painless. Isoflurane anesthesia via a face mask was applied when necessary. Blood was obtained via cardiac puncture or via the caudal vena cava after a ventral midline incision was made. Exsanguinated animals were then euthanized, if necessary, by placement in a CO₂ chamber. We obtained 10 to 12 mL of blood in this manner.

The protocol for PRP preparation was patterned after the protocol used by the Hematology Department at Eisenhower Army Medical Center. The blood was decanted into centrifuge tubes and centrifuged in a Beckman Model J-6M centrifuge (Beckman Coulter, Inc, Fullerton, Calif) at 150g for 10 minutes at 20°C. The PRP or buffy coat was decanted into a small sterile beaker. Approximately 1 mL of PRP was obtained. Approximately 100 µL of whole blood and PRP were collected to determine platelet counts using an Abbot Cell-Dyn 3500 hematology analyzer (Abbott Diagnostics, Santa Clara, Calif) with the parameters set for rats. The coagulation process was initiated by adding a mixture of 1000 units of topical bovine thrombin (both from Sigma Chemical Co, St Louis, Mo) in 10% calcium chloride per milliliter of PRP. This mixture was added drop-wise until the PRP formed a gel, and then it was added to the surgical defect (as described later).

Bio-Oss, particle size 0.25–1.0 mm, was reconstituted in 1 mL of saline for use in this study. To create the PRP plus Bio-Oss implant material, the Bio-Oss was hydrated with excess PRP. The calcium chloride and bovine thrombin mixture was then added to form a gel with internalized Bio-Oss particles, and added to the defect.

CSD and graft-site preparation

Cranial CSD was created as previously described.^{13–14} Briefly, animals were anesthetized intraperitoneally with a cocktail of ketamine HCl, 100 mg/mL (65 mg/kg), and xylazine HCl, 20 mg/mL (7 mg/kg), via a 25-gauge needle. Sterile eye lubricant ointment was placed in the eyes. Under sterile conditions, the skin overlying the calvarium was shaved with a #40 blade and the surgical site cleaned with Novalsan scrub (Zoetis Inc, Kalamazoo, Mich) and sterile water. An autoclaved 3-inch stockinette was rolled over the prepared rat using aseptic technique, and the head was exteriorized by cutting a hole in the stockinette and pulling the head through. The anesthetized rat was placed in a Stoelting rodent stereotaxic device (Stoelting Co, Wood Dale, Ill) to secure the head during the surgical procedure. The stereotaxic device was fitted with a specialized anesthesia nose cone, through which 0.25%–0.50% isoflurane in 1 L/min oxygen was administered and adjusted to maintain an appropriate anesthetic plane. A midline incision was made from the middle of the nasal bones to the posterior nuchal line. Full-thickness flaps with periosteum were reflected laterally. An 8-mm craniotomy was made utilizing a dental handpiece at slow speed with a sterilized 8-mm diamond grit trephine bur (Continental Diamond Tool Corp, New Haven, Ind) and copious saline irrigation. Care was taken to avoid the underlying dura. The edges of the bony defect were smoothed using a #2 round bur with saline irrigation as needed. A 9-mm diameter polytetrafluoroethylene (PTFE) membrane (Fluoropore Membrane Filters, pore size 0.5 µm, Millipore Corp, Bedford, Mass) was placed deep to the cranium and superficial to the dura with the reinforced

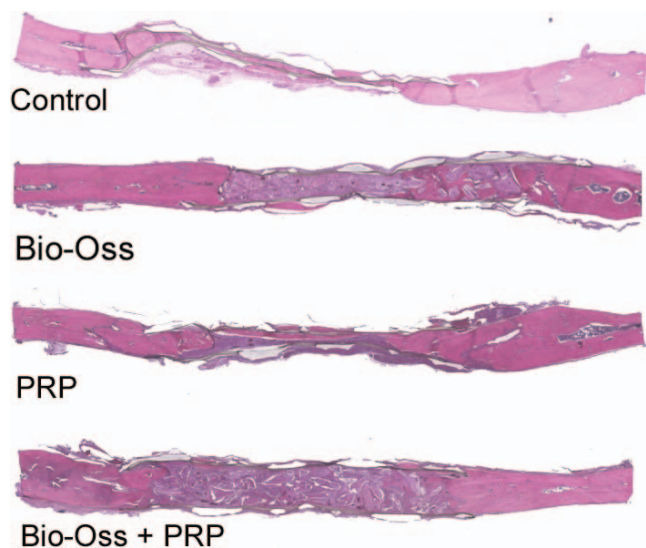


FIGURE 1. The greater space-maintaining capability of the groups containing Bio-Oss is evident in these representative comparisons, and a thin layer of new bone transverses the defect in the platelet-rich protein only group. Original magnification $\times 40$, then digitally enhanced using SimplePCI imaging software.

side adjacent to the dura. The membrane was adjusted to achieve an overlap covering the defect.

After the CSD surgeries, groups were treated as follows: 1) no material was placed in the defect (surgical control group); 2) PRP (500 μL) was placed into the defect (PRP group); 3) Bio-Oss (40 mg) was placed into the defect; 4) PRP plus Bio-Oss gel (40 mg Bio-Oss, saturated with PRP, then coagulated) was placed into the defect. The saline-moistened treatment material, if any, appropriate to each study group was carefully placed into the defect. A second 10-mm diameter PTFE membrane was placed superficial to the outer cranium and deep to the periosteum so the membrane edges overlapped the defect by 1 mm. The periosteum and temporalis muscle were repositioned to cover the outer surface of the membrane and sutured with continuous 4-0 Vicryl sutures on a cutting needle. The skin was closed with interrupted sutures using 4-0 Vicryl on a cutting needle. After the surgical procedures, the animals were observed for any signs of pain or distress. If analgesics were indicated, buprenorphine (0.1–0.5 mg/kg intraperitoneally via a 25-gauge needle) was administered subcutaneously every 12 hours until signs of pain subsided.

Histologic evaluation

At 8 weeks after surgery, the animals were euthanized by CO_2 asphyxiation. The cranium was removed, and placed in 10% formalin (Fischer Chemicals, Fair Lawn, NJ). The calvaria were radiographed using a Faxitron Series 43807N X-Ray System (Hewlett Packard, Wheeling, Ill) soft x-ray analysis technique (time, 15 seconds; kilovolt peak, 35; milliamps, 2.5) for radiomorphologic comparisons.

The specimens were then sectioned sagittally to yield 2 samples per specimen, and 1 of these samples was demineralized for 10 days using Cal-EX Decalcifying Solution (Fischer Chemicals). Each specimen was placed in a cassette, imbedded

in paraffin wax, sectioned at 3- μm thickness on a 2030 Biocut microtome (Leica, Reichert-Jung, Nussloch, Germany), and stained with hematoxylin and eosin stain. Histologic slides were scanned using a Photometrics Coolsnap Fx camera (Roper Scientific Inc, Tucson, Ariz) attached to a Nikon Diaphot 300 inverted microscope (Southern Micro Instruments, Atlanta, Ga) and SimplePCI Imaging (Compix Inc, Imaging Systems, Cranberry Township, Pa), at a $\times 40$ power. Histology sections were then analyzed qualitatively by light microscopy at a magnification of $\times 40$. New bone growth, as evidenced by the presence of osteoblasts, and amount of closure of the CSD were observed and documented for each histology section.

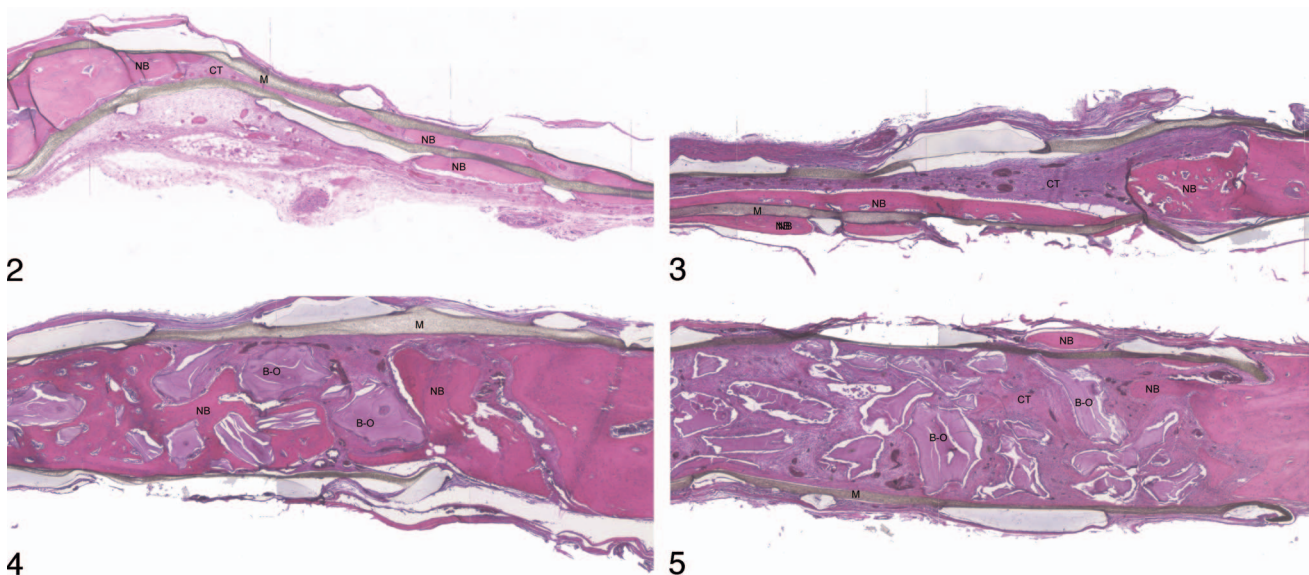
RESULTS

The mean whole-blood platelet count of $500\,625 \pm 3609$ platelets/ μL (mean \pm SD) was increased 151% \pm 7% to $754\,125 \pm 3397$ platelets/ μL in the PRP preparation. Figure 1 represents a cranial CSD with each therapy. Histologic staining of cross-section slices of the cranium revealed that control defects healed with a combination of new bone growth and dense fibrous connective tissue (Figure 1). Magnified images of the control groups (Figure 2) demonstrated that new bone growth was mainly limited to the periphery of the defect. A collapse of the defect occurred between the PTFE membranes, creating a thin residual defect. The animals that received only PRP after CSD surgery appeared similar to control groups with bone growth mainly at the periphery and connective tissue throughout a collapsed defect (Figures 1 and 3).

Unlike the PRP group, CSDs containing only Bio-Oss particles demonstrated a greater amount of bone growth near the center of the defect (Figures 1 and 4). The groups grafted with Bio-Oss showed intimate contact between new bone and Bio-Oss particles, with new bone surrounding Bio-Oss particles and new bone internal to Bio-Oss particles. The borders of new bone areas showed osteoblastic rimming and evidence of osteoclastic activity. New bone growth was also found external to the membranes used to isolate the defects on both the side facing the dura (Figure 3) and the side facing the calvarial periosteum (Figure 4). Bio-Oss particles appeared largely intact, with little evidence of resorption, presenting space-maintaining characteristics.

The PRP plus Bio-Oss treatment did not appear to further enhance new bone formation as compared with Bio-Oss alone (Figures 1 and 5). The original space between the defect was maintained in both the Bio-Oss and PRP plus Bio-Oss groups. Also of note, there was no inflammatory cell response in any of the 4 groups that was indicative of graft rejection. However, it is important to note that the rats were all of the same genetic strain, which may account for the lack of an inflammatory response, even though the PRP preparations were pooled from multiple rats.

Radiographs of the calvarial defects yielded little information about regeneration of the defects via new bone growth because of the radiodense properties of the Bio-Oss particles and because the particles were not resorbed during the 8-week time of this study (Figure 6). Therefore, the groups grafted with Bio-Oss appeared densely filled, with Bio-Oss particles completely filling in the defect. The control group and PRP groups



FIGURES 2–5. **FIGURE 2.** New bone is forming within and outside the polytetrafluoroethylene membranes in this control specimen. Note the collapsed nature of the defect. NB indicates new bone; CT, connective tissue; M, membrane. Original magnification $\times 40$, then digitally enhanced using simple PCI. **FIGURE 3.** Note the thin layer of new bone below the membrane that nearly transverses the defect in the platelet-rich protein only group and the collapsed nature of the defect. New bone is forming within and outside the membrane, and in contact with the membrane. NB indicates new bone; CT, connective tissue; M, membrane. Original magnification $\times 40$, then digitally enhanced using simple PCI. **FIGURE 4.** Note the space maintained by the Bio-Oss particles and the new bone formed in contact with the Bio-Oss particles in the Bio-Oss only group. NB indicates new bone; B-O, Bio-Oss; M, membrane. Original magnification $\times 40$, then digitally enhanced using simple PCI. **FIGURE 5.** Note the space being maintained by the nonresorbed Bio-Oss particles in the platelet-rich protein plus Bio-Oss group, surrounded by new bone. NB indicates new bone; CT, connective tissue; B-O Bio-Oss; M, membrane. Original magnification $\times 40$, then digitally enhanced using SimplePCI.

appeared radiolucent, with the defects still visible. However, some new bone regeneration was apparent in both groups at the periphery of the defect.

DISCUSSION

The purpose of this study was to assess the regenerative capacities of combination therapy with an anorganic bovine bone Bio-Oss and PRP, alone or in combination, nonspontaneously healing CSD to evaluate osseous wound healing. Qualitative comparisons were made among different groups via histologic and radiographic techniques. The CSDs from control and PRP groups healed in a very thin dimension, and the tissue consisted of new bone originating from the periphery of the defects. The centers of the defects were filled mainly with dense fibrous connective tissue. Space maintenance was absent in the control and PRP groups, indicating that the defect was not stable. In contrast to the control and PRP animals, treatment with Bio-Oss and PRP plus Bio-Oss after CSD resulted in greater stability within the membranes because of the space-maintaining characteristics of Bio-Oss. The pattern of new bone growth was also different in that Bio-Oss particles were well integrated into the new bone throughout the defect and in central locations; however, new bone formation was limited because of incomplete resorption of Bio-Oss in the central locations. Radiomorphometric findings confirmed histologic data that the control and PRP groups had a radiolucent appearance, with evidence of radiodensity representing new

bone growth forming at the periphery of all defects. The Bio-Oss and the PRP plus Bio-Oss groups demonstrated uniformly radiodense granular appearances, owing to the presence of nonresorbed Bio-Oss particles. The characteristic radiodensity of Bio-Oss particles prevented a densitometric evaluation of these radiographs to assess new bone growth.

Placing PTFE membranes on either side of the calvarial defect is a technique that has been commonly used in this laboratory to isolate the defects.^{13,14} Bio-Oss was used to provide a source of hydroxyapatite bone mineral, as well as a trabecular microstructure similar to human bone, creating an osteoconductive effect. Additionally, the incorporation of a solid particulate graft material ensures complete anatomic space maintenance. Linde et al¹⁵ refer to this technique as “osteopromotion,” referring to the use of physical means to seal off an anatomic site in order to prevent other tissues, notably connective tissue, from interfering with osteogenesis. In-growth of connective tissue and other rapidly regenerating tissues is prevented, allowing slower migrating cells with osteogenic potential to migrate into the area from the adjacent bone margins and to form new bone relatively undisturbed.

Resorption and replacement of the Bio-Oss particles may occur with time; however, the extent of resorption and length of time required is controversial.¹⁶ Still, these grafted sites have the potential to heal at a much greater thickness and strength than the control or PRP-only groups and have increased utility as bone graft materials in periodontics, where increased thickness and strength of new bone is necessary in sinus-lift procedures, alveolar ridge augmentation, or guided bone regeneration.

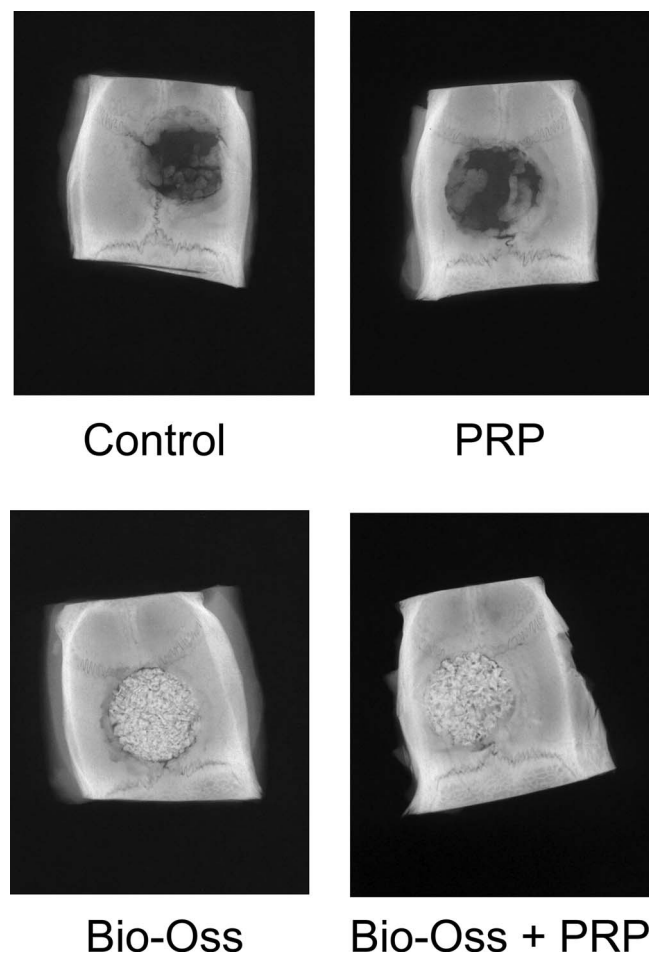


FIGURE 6. New bone formation can be seen around the periphery of the defects in the control and platelet-rich protein group x-rays. The lack of Bio-Oss resorption at 8 weeks is evidenced in the Bio-Oss and the platelet-rich protein plus Bio-Oss group x-rays.

The PRP was tested as an autogenous source of growth factors recognized as promoting early bone regeneration (PDGF, IGF-I, and TGF- β), providing an osteoinductive effect. In the present study, CSDs from the control and PRP groups healed in a very thin dimension, and the tissue consisted of new bone originating from the periphery of the defects. Space maintenance was absent in the control and PRP groups, indicating that the defect was not stable. An important consideration for these findings is that even though animals were allowed to recover, the CSDs would most likely never heal completely. Previous studies have demonstrated that if allowed to mature for a longer period, these defects would not totally regenerate.¹²

The 8-week course of the experiment was chosen to maximize assessment of the early effects of PRP addition, and this time frame may have greatly influenced the degree of maturity of the defects grafted with Bio-Oss. Several studies have shown excellent bone regeneration with Bio-Oss with more extended time periods for maturation of the grafted sites. Studies in dogs, primates, and humans have demonstrated remarkable bone regeneration at 6–7 months after implant surgery.^{17–19} With an extended period of time to allow for graft

maturation in this rat model (12 to 16 weeks), increased bone growth might occur in the defects grafted with Bio-Oss.

Artzi et al²⁰ evaluated Bio-Oss in its cancellous form when grafted in 15 fresh human extraction sockets in 15 patients. The study found the average clinical bone fill of the augmented sockets was 82.3%. New osseous tissue adhered to the Bio-Oss particles. Also, the resorbability of the porous bovine bone mineral could not be recognized in the 9-month period of the study. In a following study, histochemical analysis of the samples previously obtained from extraction sockets grafted with Bio-Oss demonstrated grafted particles that were not significantly resorbed at 9 months.²¹ The researchers concluded that cancellous anorganic bovine bone is a biocompatible filler agent in extraction socket sites and an acceptable graft for edentulous ridge preservation at sites prepared to receive endosseous implants. The Bio-Oss was determined to be osteoconductive based on the promotion of osseous ingrowth and close integration with newly generated bone. In other studies that examined the ability of Bio-Oss to induce new bone formation, investigators deproteinized cancellous bovine bone and applied chaotropic solvents used in the protocol for purification of bone morphogenic proteins.²² The results showed that small amounts of protein were present in the Bio-Oss in close association with the mineral phase. Some of the extracted material possessed osteoinductive potential, and the presence of growth factors (TGF- β and bone morphogenic protein-2) were detected; which may explain the osteopromotive ability of Bio-Oss.

The current study was designed to evaluate potential additive or synergistic effects by combining Bio-Oss and PRP. The PRP may adsorb onto the surface of the Bio-Oss particles, rendering them osteoconductive. This concept is supported by Jiang et al,²³ in a study in which PDGF-BB and IGF-I were radiolabeled and incubated with anorganic bovine bone matrix. Results showed that PDGF-BB and IGF-I adsorbed to the bone mineral matrix in a concentration-dependent fashion. This suggests that these growth factors can be absorbed onto the anorganic bovine bone mineral matrix and may subsequently enhance the osteogenic properties of this bone graft material. In the present study, increased bone formation due to PRP therapy after CSD was not detected. Platelet counts in PRP resulted in approximately 754 000 platelets/ μ L, which was similar to the PRP platelet counts achieved by Marx et al.² However, the mean percent increase in platelet concentration, 151%, was lower than that achieved in other reported studies. The coagulation of the PRP produced a gel that had excellent handling characteristics and could easily be placed within the calvarial defect. The fact that the PRP group did not regenerate bone in an amount greater than the control group contradicts earlier findings of greater bone density in bone grafts in which PRP was added.² The control group may have performed similarly to PRP, as it contained a coagulum of whole blood, which formed a fibrin clot and would contain platelets that released growth factors (although at a lower concentration).

Kim et al²⁴ reported results similar to those in this study using demineralized bone powder plus PRP in a dog model. Histologic analysis showed that all of the bone defects surrounding implants and treated with demineralized bone powder, with or without PRP, were filled with new bone at 6 weeks, with enhanced bone maturity. Studies that evaluated

NOTE

The opinions expressed in this article are exclusively those of the authors and not necessarily those of the US Army Dental Corps or the Department of the Army. The use of commercial products in this project does not imply endorsement by the US government.

REFERENCES

- Chen FM, Zhang J, Zhang M, An Y, Chen F, Wu ZF. A review on endogenous regenerative technology in periodontal regenerative medicine. *Biomaterials*. 2010;31:7892–7927.
- Marx RE, Carlson ER, Eichstaedt RM, Schimmele SR, Strauss JE, Georgeff KR. Platelet-rich plasma: growth factor enhancement for bone grafts. *Oral Surg Oral Med Oral Pathol Oral Radiol Endod*. 1998;85:638–646.
- Nauth A, Giannoudis PV, Einhorn TA, et al. Growth factors: beyond bone morphogenetic proteins. *J Orthop Trauma*. 2010;24:543–546.
- Tozum TF, Demiralp B. Platelet-rich plasma: a promising innovation in dentistry. *J Can Dent Assoc*. 2003;69:664.
- Gross JS. Bone grafting materials for dental applications: a practical guide. *Compend Contin Educ Dent*. 1997;18:1013–1018,1020–1022,1024.
- Thaller SR, Hoyt J, Borjeson K, Dart A, Tesluk H. Reconstruction of calvarial defects with anorganic bovine bone mineral (Bio-Oss) in a rabbit model. *J Craniofac Surg*. 1993;4:79–84.
- Baldini N, De Sanctis M, Ferrari M. Deproteinized bovine bone in periodontal and implant surgery. *Dent Mater*. 2011;27:61–70.
- De Santis E, Botticelli D, Pantani F, Pereira FP, Beolchini M, Lang NP. Bone regeneration at implants placed into extraction sockets of maxillary incisors in dogs. *Clin Oral Implants Res*. 2011;22:430–437.
- Skoglund A, Hising P, Young C. A clinical and histologic examination in humans of the osseous response to implanted natural bone mineral. *Int J Oral Maxillofac Implants*. 1997;12:194–199.
- Esposito M, Grusovin MG, Coulthard P, Worthington HV. The efficacy of various bone augmentation procedures for dental implants: a Cochrane systematic review of randomized controlled clinical trials. *Int J Oral Maxillofac Implants*. 2006;21:696–710.
- Tsay RC, Vo J, Burke A, Eising SB, Lu HH, Landesberg R. Differential growth factor retention by platelet-rich plasma composites. *J Oral Maxillofac Surg*. 2005;63:521–528.
- Schmitz JP, Hollinger JO. The critical size defect as an experimental model for craniomandibulofacial nonunions. *Clin Orthop Relat Res*. 1986;206:299–308.
- Turonis JW, McPherson JC III, Cuenin MF, Hokett SD, Peacock ME, Sharawy M. The effect of residual calcium in decalcified freeze-dried bone allograft in a critical-sized defect in the *Rattus norvegicus* calvarium. *J Oral Implantol*. 2006;32:55–62.
- Yun JI, Wikesjo UM, Borke JL, et al. Effect of systemic parathyroid hormone (1-34) and a beta-tricalcium phosphate biomaterial on local bone formation in a critical-size rat calvarial defect model. *J Clin Periodontol*. 2010;37:419–426.
- Linde A, Alberius P, Dahlin C, Bjurstam K, Sundin Y. Osteopromotion: a soft-tissue exclusion principle using a membrane for bone healing and bone neogenesis. *J Periodontol*. 1993;64:1116–1128.
- Duda M, Pajak J. The issue of bioresorption of the Bio-Oss xenogeneic bone substitute in bone defects. *Ann Univ Mariae Curie Sklodowska Med*. 2004;59:269–277.
- Hurzeler MB, Kohal RJ, Naghsbandi J, et al. Evaluation of a new bioresorbable barrier to facilitate guided bone regeneration around exposed implant threads. An experimental study in the monkey. *Int J Oral Maxillofac Surg*. 1998;27:315–320.
- Berglundh T, Lindhe J. Healing around implants placed in bone defects treated with Bio-Oss. An experimental study in the dog. *Clin Oral Implants Res*. 1997;8:117–124.
- Zitzmann NU, Naef R, Scharer P. Resorbable versus nonresorbable membranes in combination with Bio-Oss for guided bone regeneration. *Int J Oral Maxillofac Implants*. 1997;12:844–852.
- Artzi Z, Tal H, Dayan D. Porous bovine bone mineral in healing of human extraction sockets. Part 1: histomorphometric evaluations at 9 months. *J Periodontol*. 2000;71:1015–1023.
- Artzi Z, Tal H, Dayan D. Porous bovine bone mineral in healing of

the effect of PRP on bone healing of autogenous bone grafts in CSDs in rabbits did detect greater bone formation at earlier 4-week points but not at 12 weeks after surgery.^{25,26} The researchers concluded that the beneficial effects of PRP were greatest at the initial healing period of 4 weeks, an observation supported by our pilot study at 6 weeks and our experiments at 8 weeks. In contrast, other studies observed a histologically significant enhancement of bone healing in PRP treated vs control rats, with an 8-mm CSD, at both 4 and 12 weeks,²⁷ while others reported that PRP soak loaded onto a absorbable collagen sponge did not enhance bone regeneration in rats at 4 or 8 weeks vs sponge or controls in a 6-mm CSD model.²⁸ Subsequent radiographic examination in the latter study suggested that the PRP preparation did not have a significant effect on osteogenesis.²⁹

Mariano et al³⁰ evaluated the ability of PRP to heal a CSD in diabetic rats at 30 days. Control rats exhibited newly formed bone close to the borders of the surgical defect, while the PRP-treated rats exhibited a greater amount of newly formed bone close to the borders of the surgical defect, with regenerating bone often bridging the defect. These conflicting observations, including our own, may be at least partially explained by the findings of Nagata et al,³¹ who observed that bone healing in rat CSDs is influenced by the proportion of graft material to PRP. The variability of results seen in clinical and animal studies may have several explanations. A standardized PRP preparation and the addition of a titanium mesh for space maintenance may help resolve these discrepancies and guide clinicians in the use of PRP in clinical settings.

CONCLUSIONS

It can be concluded from this study that all groups (control [hemotologic coagulum], PRP, Bio-Oss, and Bio-Oss plus PRP), produced osseous regeneration when grafted into a CSD within the rat calvarium and allowed to heal for 8 weeks. Areas grafted with Bio-Oss had a greater space-maintaining capacity and the potential to heal in a greater dimension. It is also apparent from these studies that any positive effects of PRP on the healing process could not be determined at 8 weeks. The possibility that early positive effects of PRP-derived growth factors occurred before being naturally degraded suggests that their effects on osseous regeneration were short lived or not significant. However, PRP has handling characteristics, that are advantageous for use with grafting materials as it is gelatinous and comes from an autologous source. This suggests that PRP can serve as an excellent vehicle for placing and handling particulate bone graft materials, which may be of significant benefit.

ABBREVIATIONS

CSD: critical-size defect
 IGF-I, IGF-II: insulin-like growth factors
 PDGF: platelet-derived growth factor
 PRP: platelet-rich plasma
 PTFE: polytetrafluoroethylene
 TGF- β : transforming growth factor beta

- human extraction sockets: 2. Histochemical observations at 9 months. *J Periodontol.* 2001;72:152–159.
22. Schwartz Z, Weesner T, van Dijk S, et al. Ability of deproteinized cancellous bovine bone to induce new bone formation. *J Periodontol.* 2000;71:1258–1269.
23. Jiang D, Dziak R, Lynch SE, Stephan EB. Modification of an osteoconductive anorganic bovine bone mineral matrix with growth factors. *J Periodontol.* 1999;70:834–839.
24. Kim SG, Kim WK, Park JC, Kim HJ. A comparative study of osseointegration of Avana implants in a demineralized freeze-dried bone alone or with platelet-rich plasma. *J Oral Maxillofac Surg.* 2002;60:1018–1025.
25. Nagata MJ, Melo LG, Messori MR, et al. Effect of platelet-rich plasma on bone healing of autogenous bone grafts in critical-size defects. *J Clin Periodontol.* 2009;36:775–783.
26. Nagata MJ, Messori M, Pola N, et al. Influence of the ratio of particulate autogenous bone graft/platelet-rich plasma on bone healing in critical-size defects: a histologic and histometric study in rat calvaria. *J Orthop Res.* 2010;28:468–473.
27. Messori MR, Nagata MJ, Mariano RC, et al. Bone healing in critical-size defects treated with platelet-rich plasma: a histologic and histometric study in rat calvaria. *J Periodontol Res.* 2008;43:217–223.
28. Pryor ME, Polimeni G, Koo KT, et al. Analysis of rat calvaria defects implanted with a platelet-rich plasma preparation: histologic and histometric observations. *J Clin Periodontol.* 2005;32:966–972.
29. Pryor ME, Yang J, Polimeni G, et al. Analysis of rat calvaria defects implanted with a platelet-rich plasma preparation: radiographic observations. *J Periodontol.* 2005;76:1287–1292.
30. Mariano R, Messori M, de Moraes A, et al. Bone healing in critical-size defects treated with platelet-rich plasma: a histologic and histometric study in the calvaria of diabetic rat. *Oral Surg Oral Med Oral Pathol Oral Radiol Endod.* 2010;109:72–78.
31. Nagata M, Messori M, Okamoto R, et al. Influence of the proportion of particulate autogenous bone graft/platelet-rich plasma on bone healing in critical-size defects: an immunohistochemical analysis in rat calvaria. *Bone.* 2009;45:339–345.