

Repair Technique for Fractured Implant-Supported Metal-Ceramic Restorations: A Clinical Report

Amanda Fucci Wady, DDS, MSc¹
 André Gustavo Paleari, DDS, MSc, PhD¹
 Thallita Pereira Queiroz, DDS, MSc, PhD²
 Rogerio Margonar, DDS, MSc, PhD^{2*}

The fracture of porcelain structures have been related in either natural dentition or implant-supported restorations. Techniques using a composite resin or indirect methods can be used. This article presents a porcelain fracture on implant-supported metal-ceramic restoration. IPS Empress e.max laminate veneer restoration was used to repair the fracture. With this technique, it was possible to restore aesthetics and function, combined with low cost and patient satisfaction.

Key words: fracture, ceramics, repair, laminate veneer, implantology

INTRODUCTION

Because of their esthetic benefits and satisfactory mechanical properties,¹ metal-ceramic (MC) restorations have been used for several years.^{1–3} During this time, porcelain fracture occurred at rates of 2.3–8%.^{4–6} In addition, clinical studies showed the prevalence of ceramic fractures ranged from 5–10% over 10 years of use.⁷

Although the success of metal-ceramic crowns and fixed partial dentures in natural dentition is well established, scarce data are available on the porcelain fracture of implant-supported MC restorations.^{8,9} Some researchers have shown that porcelain^{9–12} fractures occur at a higher rate in implant-supported restorations than do fractures involving metal ceramics in natural dentition.^{9–12}

Another factor associated to porcelain fractures that should be considered is whether the crown is screw-retained or cemented-retained. Some researchers^{8,13–15} have suggested that the presence

of a screw-access hole in an MC crown can weaken the porcelain around the opening, resulting in porcelain fracture, while cement-retained restorations can overcome this problem. In general, the reasons for the porcelain failures may be related to repeated stresses, strains during chewing, trauma^{7,16,17} or laboratory mistakes.¹⁸

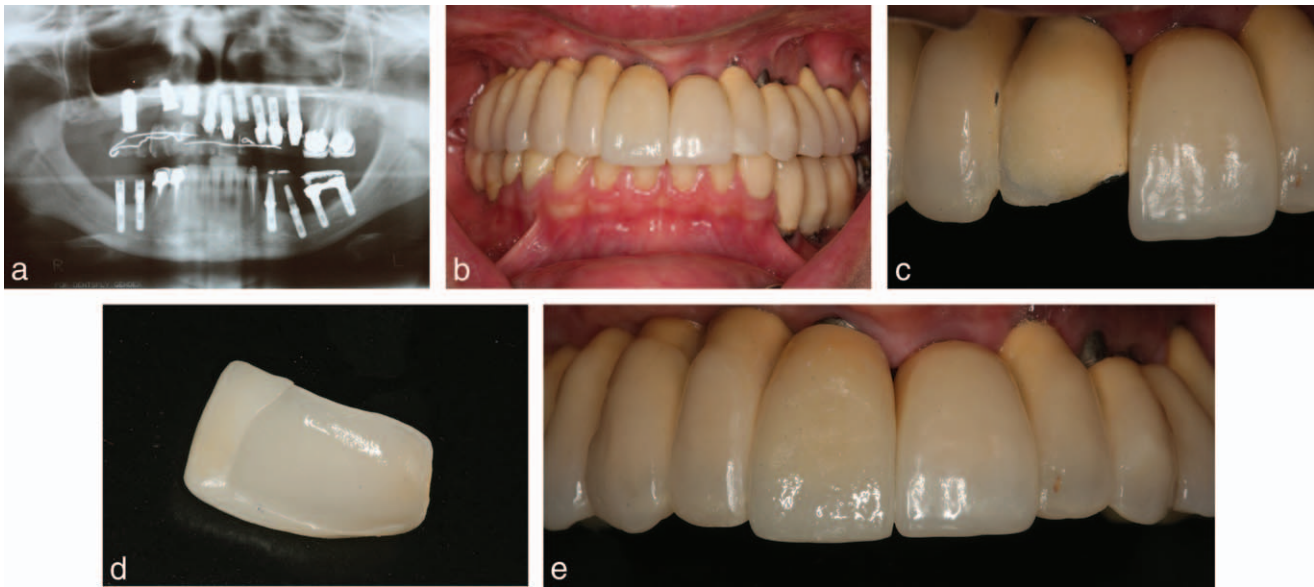
Various techniques for porcelain repair have been suggested. There are direct methods using a composite resin to restore the fractured porcelain.^{4,19,20} In addition, indirect methods can be achieved. These techniques use porcelain in a laboratory procedure.^{21,22} The advantages of direct methods are less time, lower cost, and easy application. The disadvantages may be low strength, poor wear qualities, and poor esthetics.^{23–26} The indirect methods involves clinical and laboratory procedures but may be more esthetic.²⁷

Furthermore, the clinical success of porcelain repair depends on the bond between the ceramic and the composite resin.^{18,28} The research has studied different treatments using bonding agents and acid application.^{18,29,30} According to the reports described herein, it is still not clear what the technique of choice for dentists should be, especially when the fractured restoration involves implant-supported MC prosthesis. Thus, this article

¹ UNESP, Univ Estadual Paulista, Araraquara Dental School, Department of Dental Materials and Prosthodontics, Araraquara, São Paulo, Brazil.

² Araraquara University Center – UNIARA, Araraquara, São Paulo, Brazil.

* Corresponding author, e-mail: rogeriomargonar@terra.com.br
 DOI: 10.1563/AAID-JOI-D-12-00085



FIGURES 1–5. FIGURE 1. Initial radiograph. **FIGURE 2.** Conventional metal-ceramic restorations cemented on abutments. **FIGURE 3.** Upper right central incisor with fractured porcelain. **FIGURE 4.** Porcelain veneers (IPS Empress e.max). **FIGURE 5.** Upper right central incisor after porcelain veneers cemented.

describes an indirect technique to repair a fractured MC fixed partial dentures supported by implants.

CLINICAL REPORT

A 48-year-old woman was evaluated for treatment, and an oral rehabilitation was accomplished with fixed prosthesis on implants. Different professionals performed the surgical procedure of implant placement. Clinical and radiographic examination (Figure 1) revealed that the implants were of different brands. At that point, the treatment chosen was abutment for cemented restorations,³¹ and MC restorations were used (Figure 2). Two years after the end of treatment, a fractured porcelain labial surface of the maxillary right central incisor was observed (Figure 3).

For the repair, the tooth was prepared for a porcelain laminate veneer. A diamond rotary cutting instrument (3145 KG Sorensen, Barueri, Sao Paulo, Brazil) was used to prepare the labial surface of the maxillary right central incisor. The impression material used was addition silicone (Elite, Zhermack, Badia Polesine, Italy) using a one-stage impression technique. The porcelain veneers were fabricated using a leucite-reinforced glass-ceramic (IPS Empress e.max) (Ivoclar Vivadent, Schaan, Liechtenstein) (Figure 4).

The surfaces of the veneer and the maxillary

right central incisor were treated with fluoride acid 10%, and then a silane agent (Angelus, Londrina, Brazil). The cement used for the cementation process was Rely X resin cement (3M, St Paul, Minn). All steps were performed according manufacturer instructions. Figure 5 shows the porcelain veneers cemented in the mouth.

DISCUSSION

This paper reports an indirect approach to repair fracture on implant-supported fixed denture. There are evidences that porcelain fractures occur at a higher rate in implant-supported restorations than in natural dentition.^{9–12} The possible reasons for this difference are related to lack of neurologic feedback and the periodontal reflex mechanism that is not present on implants as a protective device in masticatory force generation.^{9,32,33}

Although it has been suggested that screw-retained restorations are predisposed to a higher rate of fracture,^{8,13–15} this report stated a case of a cemented-retained restoration. It was not possible to determine the exact cause of the fracture since the patient does not have a parafunctional habit and the restoration was not interfering with the patient’s occlusion. Several factors—such as the shape and thickness of the veneer, microstructural inhomogeneities, residual stresses induced by

processing, elastic modulus of the supporting substrate material, and environmental effects—are likely associated with crack initiation and propagation within dental ceramics.^{13,34,35}

One of the advantages of replacing only the failed crown with a porcelain laminate veneer is related to the low cost of this chosen treatment; the costs associated with replacement of the whole implant-supported fixed restorations is greater than other treatment alternatives.⁹ In addition, the patient presented implants with different trademarks placed in unfavorable positions, which make difficult the choice and the subsequent purchase of new components to replace the full MC restoration.

In addition, some studies have shown techniques for improved resin-to-ceramic bond strengths. The silane coupling agents have been the most indicated material for porcelain repair. Hydrofluoric acid has been recommended to use on fractured ceramic part of a crown before the application of the silane agent.^{18,28} In the present report case, hydrofluoric acid followed by the application of a silane were used to conditioning the porcelain surfaces. This technique has achieved considerable success to date.

Another benefit of the chosen treatment is the excellent esthetic achieved. In this specific case, the fracture problem was of more concern in the patient due to the high degree of esthetics required since it involved a central upper incisor. The long-term predictability of the esthetic appearance of the direct repairs techniques, using composites applied directly to fractured restoration, could be lacking because the composites are not as color stable as porcelain, and the bond strength decreases over time.^{25–27} The disadvantages of this technique are the need for provisional restoration after the preparation of the tooth and, consequently, more chair time spent for implementing the steps when compared to direct methods of repair.

Thus, this indirect method reported is suggested as a clinical alternative to repair an MC restoration of an implant-supported fixed denture since it allows reestablishing of esthetics, masticatory function, and patient satisfaction with a low cost and a great long-term prognosis.

ABBREVIATION

MC: metal-ceramic

ACKNOWLEDGMENT

We thank the patient who participated in the study.

REFERENCES

1. Furuchi M, Oshima A, Ishikawa Y, Koizumi H, Tanoue N, Matsumura H. Effect of metal priming agents on bond strength of resin-modified glass ionomers joined to gold alloy. *Dent Mater J*. 2007;26:728–732.
2. Yilmaz H, Dinçer C. Comparison of the bond compatibility of titanium and an NiCr alloy to dental porcelain. *J Dent*. 1999;27:215–222.
3. Anusavice KJ, Kakar K, Ferree N. Which mechanical and physical testing methods are relevant for predicting the clinical performance of ceramic-based dental prostheses? *Clin Oral Implants Res*. 2007;18:218–231.
4. Dupont R. Large ceramo-metallic restorations. *Int Dent J*. 1968;18:288–308.
5. Rosenstiel SF, Land MF, Fujimoto J. *Contemporary Fixed Prosthodontics*. St. Louis, Mo: Mosby Year Book; 2000.
6. Shillingburg HT, Hobo S, Whitsett LD. *Fundamental of Fixed Prosthodontics*. Chicago, Ill: Mosby Year Book; 1997.
7. Coornaert J, Adriaens P, De Boever J. Long-term clinical study of porcelain-fused-to-gold restorations. *J Prosthet Dent*. 1984;51:338–342.
8. Torrado E, Ercoli C, Al Mardini M, Graser GN, Tallents RH, Cordaro L. A comparison of the porcelain fracture resistance of screw-retained and cement-retained implant-supported metal-ceramic crowns. *J Prosthet Dent*. 2004;91:532–537.
9. Kinsel RP, Lin D. Retrospective analysis of porcelain failures of metal ceramic crowns and fixed partial dentures supported by 729 implants in 152 patients: patient-specific and implant-specific predictors of ceramic failure. *J Prosthet Dent*. 2009;101:388–394.
10. Brägger U, Aeschlimann S, Bürgin W, Hämmerle CH, Lang NP. Biological and technical complications and failures with fixed partial dentures (FPD) on implants and teeth after four to five years of function. *Clin Oral Implants Res*. 2001;12:26–34.
11. Brägger U, Karoussis I, Persson R, Pjetursson B, Salvi G, Lang N. Technical and biological complications/failures with single crowns and fixed partial dentures on implants: a 10-year prospective cohort study. *Clin Oral Implants Res*. 2005;16:326–334.
12. Pjetursson BE, Tan K, Lang NP, Brägger U, Egger M, Zwahlen M. A systematic review of the survival and complication rates of fixed partial dentures (FPDs) after an observation period of at least 5 years. *Clin Oral Implants Res*. 2004;15:625–642.
13. Al-Omari WM, Shadid R, Abu-Naba'a L, El Masoud B. Porcelain fracture resistance of screw-retained, cement-retained, and screw-cement-retained implant-supported metal ceramic posterior crowns. *J Prosthodont*. 2010;19:263–273.
14. Guichet DL, Caputo AA, Choi H, Sorensen JA. Passivity of fit and marginal opening in screw- or cement-retained implant fixed partial denture designs. *Int J Oral Maxillofac Implants*. 2000;15:239–246.
15. Karl M, Graef F, Taylor TD, Heckmann SM. In vitro effect of load cycling on metal-ceramic cement- and screw-retained implant restorations. *J Prosthet Dent*. 2007;97:137–140.
16. Thurmond JW, Barkmeier WW, Wilwerding TM. Effect of porcelain surface treatments on bond strengths of composite resin bonded to porcelain. *J Prosthet Dent*. 1994;72:355–359.
17. Chadwick RG, Mason AG, Sharp W. Attempted evaluation of three porcelain repair systems – what are we really testing? *J Oral Rehabil*. 1998;25:610–615.
18. Ozcan M. Evaluation of alternative intra-oral repair

techniques for fractured ceramic-fused-to-metal restorations. *J Oral Rehabil.* 2003;30:194–203.

19. Bertolotti RL, Lacy AM, Watanabe LG. Adhesive monomers for porcelain repair. *Int J Prosthodont.* 1989;2:483–489.

20. Kupiec KA, Wuertz KM, Barkmeier WW, Wilwerding TM. Evaluation of porcelain surface treatments and agents for composite-to-porcelain repair. *J Prosthet Dent.* 1996;76:119–124.

21. Welsh SL, Schwab JT. Repair technique for porcelain-fused-to-metal restorations. *J Prosthet Dent.* 1977;38:61–65.

22. Bakland LK. Replacing porcelain veneers in the mouth. *Quintessence Int (Berl).* 1972;3:45–49.

23. Barreto MT, Bottaro BF. A practical approach to porcelain repair. *J Prosthet Dent.* 1982;48:349–351.

24. Helpin ML, Fleming JE. Laboratory technique for the laminate veneer restoration. *Pediatr Dent.* 1982;4:48–50.

25. Cardoso AC, Spinelli Filho P. Clinical and laboratory techniques for repair of fractured porcelain in fixed prostheses: a case report. *Quintessence Int.* 1994;25:835–838.

26. Hirschfeld Z, Rehany A. Esthetic repair of porcelain in a complete-mouth reconstruction: a case report. *Quintessence Int.* 1991;22:945–947.

27. Galiatsatos AA. An indirect repair technique for fractured

metal-ceramic restorations: a clinical report. *J Prosthet Dent.* 2005; 93:321–323.

28. Ozcan M, van der Sleen JM, Kurunmäki H, Vallittu PK. Comparison of repair methods for ceramic-fused-to-metal crowns. *J Prosthodont.* 2006;15:283–288.

29. Rada RE. Intraoral repair of metal ceramic restorations. *J Prosthet Dent.* 1991;65:348–350.

30. Berksun S, Saglam S. Shear strength of composite bonded porcelain-to-porcelain in a new repair system. *J Prosthet Dent.* 1994; 71:423–428.

31. Drago C, Lazzara RJ. Guidelines for implant abutment selection for partially edentulous patients. *Compend Contin Educ Dent.* 2010;31:14– 20, 23–24, 26–27; quiz 28, 44.

32. Jacobs R, van Steenberghe D. Role of periodontal ligament receptors in the tactile function of teeth: a review. *J Periodontol Res.* 1994;29:153–167.

33. Schulte W. Implants and the periodontium. *Int Dent J.* 1995; 45:16–26.

34. Kelly JR: Perspectives on strength. *Dent Mater.* 1995;11: 103–110.

35. Ritter JE: Predicting lifetimes of materials and material structures. *Dent Mater.* 1995;11:142–114