

Maxillary Ridge Augmentation with Custom-Made CAD/CAM Scaffolds. A 1-Year Prospective Study on 10 Patients

Francesco Mangano, DDS^{1*}
Aldo Macchi, MD, DDS¹
Jamil Awad Shibli, DDS, PhD²
Giuseppe Luongo, MD, DDS³
Giovanna Iezzi, DDS⁴
Adriano Piattelli, MD, DDS⁴
Alberto Caprioglio, MD, DDS¹
Carlo Mangano, MD, DDS¹

Several procedures have been proposed to achieve maxillary ridge augmentation. These require bone replacement materials to be manually cut, shaped, and formed at the time of implantation, resulting in an expensive and time-consuming process. In the present study, we describe a technique for the design and fabrication of custom-made scaffolds for maxillary ridge augmentation, using three-dimensional computerized tomography (3D CT) and computer-aided design/computer-aided manufacturing (CAD/CAM). CT images of the atrophic maxillary ridge of 10 patients were acquired and modified into 3D reconstruction models. These models were transferred as stereolithographic files to a CAD program, where a virtual 3D reconstruction of the alveolar ridge was generated, producing anatomically shaped, custom-made scaffolds. CAM software generated a set of tool-paths for manufacture by a computer-numerical-control milling machine into the exact shape of the reconstruction, starting from porous hydroxyapatite blocks. The custom-made scaffolds were of satisfactory size, shape, and appearance; they matched the defect area, suited the surgeon's requirements, and were easily implanted during surgery. This helped reduce the time for surgery and contributed to the good healing of the defects.

Key Words: Alveolar ridge augmentation, CT, computer-aided design/computer-aided manufacturing (CAD/CAM), custom-made scaffolds

INTRODUCTION

The rehabilitation of partially and totally edentulous maxilla with implant-supported prostheses has become common practice in the last few decades, with reliable long-term results.¹ However, alveolar bone defects of varying sizes occur as a result of advanced periodontitis, jawbone cysts, tooth extractions, and dental trauma.² In such

situations, due to the major changes in both vertical and horizontal bone dimensions, the placement of dental implants in the correct position may be extremely complicated or impossible.² In the posterior maxilla, sinus grafting is a well-established technique to achieve bone regeneration, with successful long-term follow-up results.¹ As an alternative, short implants are being increasingly used in extremely resorbed posterior regions.^{3,4} Recent studies show that short implants can reach satisfactory clinical levels of reliability and survival.^{3,4} In the anterior maxilla, however, the ideal approach would be to augment bone vertically and horizontally in a predictably successful way. The first therapeutic option to provide better functional and

¹ Dental School, University of Varese, Italy.

² Dental School, University of Guarulhos, Sao Paulo, Brazil.

³ Dental School, University of Naples, Italy.

⁴ Dental School, University of Chieti, Italy.

* Corresponding author, e-mail: francescomangano1@mclink.net
DOI: 10.1563/AAID-JOI-D-12-00122

esthetic results is alveolar ridge augmentation, which simultaneously provides better implant support and decreased interarch length.^{2,5} Several techniques have been proposed to achieve alveolar ridge augmentation, with different success rates, including (1) onlay block bone grafting,^{5,6} (2) interpositional grafts,⁷ (3) guided bone regeneration,^{8,9} (4) ridge split technique/ridge expansion,¹⁰ and (5) distraction osteogenesis.⁹ Although it has been shown that it is possible to augment bone vertically and horizontally with all these different techniques,^{2,5-11} the number of complications and failures of these augmentation procedures is still too high to recommend their widespread use.¹¹ Over the years, autogenous bone has remained the gold standard for alveolar ridge augmentation.^{2,5,7,11,12} However, surgical invasion of the donor site and quantitative limitations of the extracted bone may cause clinical problems.¹²⁻¹⁴ In addition, the resorption of autogenous bone after augmentation is an undesirable factor which may compromise long-term stability.¹²⁻¹⁴

In implant dentistry, priority should be given to those interventions that are less invasive, involve less risk of complications, and reach their goal within the shortest timeframe.¹² Currently, a variety of bone substitutes are available for alveolar ridge augmentation.¹⁵ The characteristics of ideal bone substitutes are as follows: They should show biocompatibility, have excellent osteoconductive properties and appropriate strength, and they should be able to be formed into a suitable shape easily and ultimately replace the bone completely within a short period.¹⁵ Prepared allogeneic or xenogenic materials have been successfully used for ridge augmentation^{7,16,17} and, more recently, biologically inert alloplastic scaffolds have been shown to offer a reasonable alternative.¹⁸ Porous hydroxyapatite (HA) ceramics have been used extensively as substitutes in bone grafts because the crystalline phase of natural bone is HA.¹⁸ For optimal bone regeneration, scaffolds need to fit anatomically into the requisite bone defects and, ideally, promote cell growth and differentiation.¹⁶⁻¹⁸ For this reason, there is a clinical need for anatomically shaped biomaterials to repair voids of bone loss in bone defects.¹⁹⁻²¹ Current implant procedures typically require bone replacement materials to be manually cut, shaped, and formed at the time of implantation, resulting in an expensive and time-consuming

process. Moreover, it is difficult to shape the graft into an appropriate configuration.¹⁹⁻²¹ This limitation can compromise the mechanical stability and the biological properties of the scaffold. Computer-aided design/computer-aided manufacturing (CAD/CAM) technologies have recently opened new frontiers in biomedical applications.²¹

The aim of this study was to demonstrate how new CAD/CAM technologies allow the fabrication of anatomically shaped, custom-made porous HA scaffolds that can be predictably used for alveolar ridge augmentation.

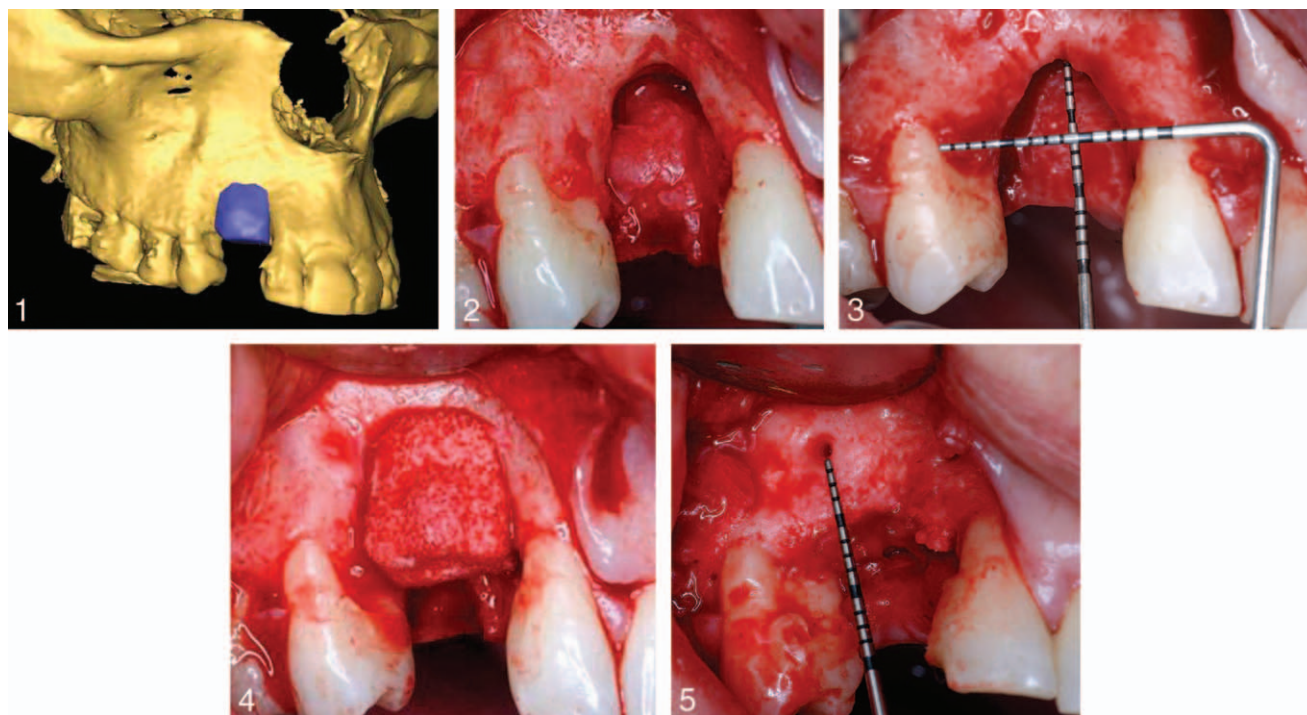
MATERIALS AND METHODS

Patient selection

Patients were recruited and treated in two different clinical centers: the Department of Oral Surgery of the University of Varese, Italy, and the Department of Oral and Maxillofacial Surgery of the University of Guarulhos, Sao Paulo, Brazil. Between January 2007 to January 2010, any patient with the following criteria was eligible for inclusion in this trial: (1) partial edentulism in the anterior/posterior maxilla, (2) a residual bone height between 5 and 7 mm and a thickness of at least 5 mm measured on CT scans, and (3) requiring vertical and horizontal bone augmentation to allow placement of dental implants. Exclusion criteria consisted of: (1) irradiation, chemotherapy, or immunosuppressive therapy over the past 5 years, (2) HIV or hepatitis B or C, (3) treatment with intravenous amino-bisphosphonates, (4) uncontrolled diabetes, (5) poor oral hygiene and motivation, (6) active periodontal infections, (7) heavy smoking habit (more than 15 cigarettes/day). The study protocol was explained to each subject, and signed informed consent was obtained. The protocol was approved by the Ethical Committees of the University of Varese (Italy) and University of Guarulhos, Sao Paulo (Brazil), and the study was performed according to the principles outlined in the World's Medical Association's Declaration of Helsinki on experimentation involving human subjects, as revised in 2008.

Preoperative work-ups

A complete examination of the oral hard and soft tissues was carried out on each patient. Preoperative work-ups included an assessment of the



FIGURES 1–5. **FIGURE 1.** 3D reconstruction of the maxilla. The alveolar ridge defect has been virtually reconstructed, drawing an anatomically shaped custom-made scaffold. **FIGURE 2.** Clinical view of the U-shaped defect. **FIGURE 3.** Clinical measurement of the U-shaped defect with a periodontal probe. **FIGURE 4.** Hydroxyapatite scaffold placed in position and fitted securely to the maxilla. **FIGURE 5.** Eight-month clinical control. Newly formed and well-integrated bone was observed filling the entire defect.

edentulous ridge using casts and diagnostic wax-up. Panoramic radiographs formed the basis for the primary investigation. Then, CT scans were acquired using a modern cone-beam scanner.

CAD/CAM procedures

CAD/CAM alveolar ridge reconstruction involved three steps: (1) the virtual planning and design of the custom-made scaffold, (2) manufacture of the custom-made scaffold, and (3) reconstructive surgery.

Virtual planning and design of the custom-made scaffold

CT datasets of the maxillary ridges were loaded in the Digital Imaging and Communications in Medicine (DICOM) format into specific three-dimensional (3D) reconstruction software (Mimics, Materialise, Leuven, Belgium). The hard tissue threshold was selected so that only bone was reconstructed from the slices. With this software, it was possible to perform an accurate and complete 3D reconstruction of the maxilla. This reconstruction was then transferred as a stereolithographic file (STL) to a 3D

CAD program (Rhinoceros, Robert McNeel & Associates, Seattle, Wash). The software permitted the operator to virtually reconstruct the alveolar ridge defect, drawing an anatomically shaped, custom-made scaffold (Figure 1).

Manufacture of the custom-made scaffold

The 3D geometry of the anatomically shaped, custom-made scaffold was imported into proprietary CAM software and used to generate a set of tool-paths for fabrication by a proprietary computer-numerical-control (CNC) milling machine. A porous HA block (Biocoral, Biocoral Inc, Le Garenne Colombes, France) was placed in the milling machine and milled into the exact shape of the 3D template. In this way, an anatomically shaped, custom-made synthetic HA scaffold was manufactured. The scaffolds were sterilized before surgery.

Reconstructive surgery

Local anesthesia was obtained by infiltrating articaine (4% containing 1:100 000 adrenaline). Wide exposure of the atrophic edentulous ridge was achieved with a crestal incision and lateral

releases. A widely mobilized mucoperiosteal flap was elevated, depicting the bone defect (Figures 2 and 3). The recipient site was weakened with multiple micro-holes to enhance bleeding from the trabecular bone. The clinically sized, anatomically shaped custom-made porous HA scaffold was placed in position strictly overlapping the underlying alveolar crest and fitted securely to the residual bone (Figure 4). Rigid fixation of the scaffold was obtained by means of a titanium mini-screw (Ningbo Cibe Medical Treatment Appliance Co Ltd, Ningbo, China) in a transversal axis (buccal to apical). The greatest surgical care was taken to obtain a tension-free suture (Supramid, Leader, Milan, Italy) above the scaffold to avoid ischemic damage to the mucosa and suture dehiscence. All patients received oral antibiotics, 2 g each day for 6 days (Augmentin, GlaxoSmithKline Beecham, Brentford, UK). Postoperative pain was controlled by administering 100 mg nimesulide (Aulin, Roche Pharmaceutical, Basel, Switzerland) every 12 hours for 2 days, and detailed instructions about oral hygiene were given, with mouthrinses with 0.12% chlorhexidine (Chlorexidine, OralB, Boston, Mass) administered twice a day for 14 days without mechanical cleaning of the surgical areas. Sutures were removed 14 days after surgery. No removable prosthesis was allowed for 6 months. Patients were enrolled in an oral hygiene programme with recall visits every 4 months for the entire duration of the study.

Implant placement and biopsies retrieval

Eight months after augmentation, under local anesthesia, mini-screws were removed, and the implants were inserted.²² The choice of the implant type, diameter, and length was left to the surgeon according to the anatomical limitations and the treatment plan. Implants were placed at the bone crest level and were submerged for a healing period of 4 months.²² Bone core biopsies were retrieved using a 2.0 × 10 mm trephine bur under sterile saline solution irrigation, in all patients. Bone cores (approximately 2 × 6 mm) were retrieved with a trephine bur via a transcrestal path at a minimum distance of 5 mm from the nearest teeth. The bone core biopsies were immediately stored in 10% buffered formalin and were subsequently processed (Precise 1 Automated System, Assing, Rome, Italy) to obtain thin ground sections. The specimens were

dehydrated in an ascending series of alcohol rinses and embedded in glycol methacrylate resin (Technovit 7200 VLC, Heraeus Kulzer GmbH & Co, Wehrheim, Germany). After polymerization, the specimens were sectioned lengthwise along the longer axis, using a high-precision diamond disk saw, to about 150 microns and ground down to about 30 microns. Two slides were obtained from each specimen. The slides were stained with basic fuchsin and toluidine blue.

Histological and histomorphometric evaluation

Histomorphometry of newly formed bone, marrow spaces, and residual graft material were carried out on each specimen using a light microscope at low magnification (×25) (Laborlux S, Ernst Leitz GmbH, Wetzlar, Germany) connected to a high-resolution video camera (3CCD, JVC KY-F55B, JVC, Yokohama, Japan) and interfaced to a monitor and personal computer (Intel Pentium III 1200 MMX, Intel Corporation, Santa Clara, Calif). This optical system was linked to a digitizing pad (MatrixVision GmbH, Oppenweiler, Germany) and a histometry software package with image-capturing capabilities (Image-Pro Plus Version 4.5, Media Cybernetics Inc, Silver Spring, Md). The values for marrow spaces/soft tissues, residual graft material, and newly formed bone were recorded exactly 1 mm from the pre-existing bone, and the mean percentage values were calculated.

Prosthetic procedure

Four months later, the implants were exposed, abutments were placed, and implant-supported acrylic resin temporary fixed restorations were cemented with temporary cement (Temp-Bond, Kerr, Orange, Calif). The placement of the definitive prosthetic restorations was performed on an individual basis, after soft tissue maturation, at least 3 months after implant placement. These restorations were carefully evaluated for proper occlusion protrusion and laterotrusion were assessed on the articulator and intraorally.

Clinical, radiographic and prosthetic evaluation

After the bone reconstruction, patients were enrolled in a program with recall visits every 4 months for the entire duration of the study. Any complications before implant placement (failure of

TABLE

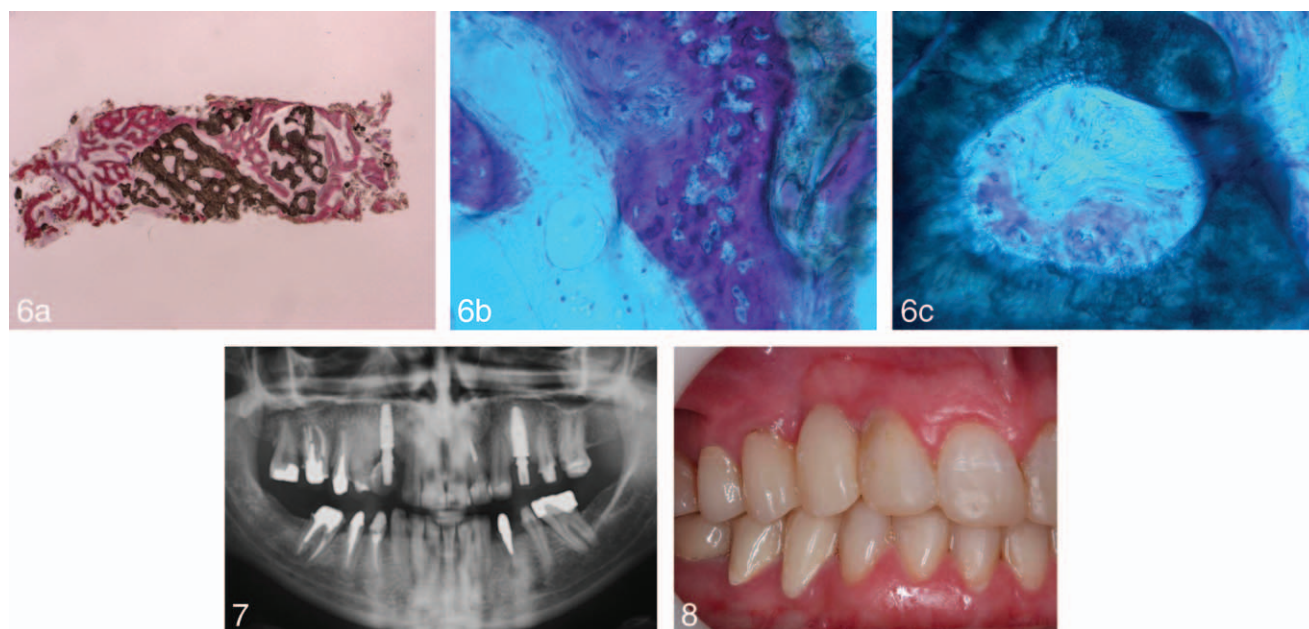
Measurements of the bone defects registered with a periodontal probe before and 8 months after augmentation (in mm).

Patient	Height		Width	
	Pre-	Post-	Pre-	Post-
1	5	2	4	1
2	7	2	2	0
3	9	4	3	1
4	6	2	3	1
5	5	2	4	1
6	4	1	2	0
7	6	2	2	0
8	5	2	3	1
9	4	1	3	2
10	6	2	4	2

the augmentation procedure due to dehiscence or infection) were registered. One year after implant placement, the following clinical parameters were investigated for each implant: (1) presence/absence of pain, suppuration or exudation and (2) presence/absence of implant mobility, tested manually using the handles of two dental mirrors. In addition, panoramic and intraoral periapical radiographs were taken using an alignment system with a rigid film-object X-ray source coupled to a beam-aiming device to achieve reproducible exposure geometry.²³ Finally, prosthesis function was tested. Static and dynamic occlusion was evaluated using standard occluding papers. The evaluation of implant survival and success was performed according to the following clinical and radiographic parameters. Implants were divided into survived and failed categories. A survived implant was still functional at the end of the study, after 1 year of functional loading.²⁴ Implant failures included implants presenting pain on function, suppuration, or clinical mobility; failures were removed. The conditions for which implant removal could be indicated included failure of osseointegration or infection, recurrent peri-implantitis, or implant loss caused by mechanical overload. To achieve implant success, the following clinical and radiographic success criteria had to be fulfilled: (1) absence of pain on function, (2) absence of suppuration or exudation, (3) absence of clinically detectable implant mobility, (4) absence of continuous peri-implant radiolucency, and (5) absence of prosthetic complications.²⁴

RESULTS

A total of 10 patients (5 males and 5 females, ages 52–66, mean age 56.5 years) were considered eligible and were enrolled in this study. Patients were recruited and subjected to bone augmentation from January 2007 to January 2010. In all patients, the anatomically shaped, custom-made scaffolds matched the shape of the bone defects well and were easily implanted during surgery. This matching of the shape helped to reduce the operation time. In two patients, the custom-made scaffolds broke at the placement of titanium mini-screws for rigid fixation. This intra-operative event was considered a minor complication. In fact, the broken scaffolds were placed in position again, secured with the help of mini-screws; a good fit was obtained, sutures were inserted, and no other complication or failure of the augmentation procedure was registered in these patients. The 8-month postoperative healing period was uneventful for 9 patients; 1 patient experienced dehiscence of the custom-made scaffold 2 months after the reconstructive surgery. This dehiscence forced the surgeon to raise a mucoperiosteal flap and expose the most coronal part of the graft. This was removed with a piezoelectric device, the graft surface was carefully cleaned, and sutures were inserted. No other complications were registered for this patient. After the healing period, newly formed, well-integrated bone was observed in all patients, filling the defects (Figure 5; Table). Representative examples of the histological sections are illustrated in Figure 6a through c. The specimens consisted of newly formed trabecular bone and biomaterial, mainly in the central portion (Figure 6a). The new bone was in strict contact with the residual material. Wide osteocyte lacunae in the vicinity of and at close contact with the graft material, and osteoid matrix undergoing mineralization were observed. New bone formation was also seen inside the residual particles of HA (Figure 6b) with newly formed osteoid matrix undergoing mineralization (Figure 6c). From the histomorphometric measurements of bone cores retrieved 8 months after augmentation, the mean percentages of new bone, biomaterial and marrow spaces were 34.9% (\pm 4.2), 26.3% (\pm 2.8), and 38.8% (\pm 4.7), respectively. The new bone was clinically available to allow a correct implant placement. In total, 10 implants were positioned. Four implants were inserted in the



FIGURES 6–8. **FIGURE 6.** Representative examples of the histological sections: (a) Newly formed trabecular bone and biomaterial, in the central portion of the specimen ($\times 12$, acid fuchsin and toluidine blue). (b) The biomaterial is surrounded by newly formed bone, with wide osteocyte lacunae in the vicinity of and at close contact with the graft material, and osteoid matrix undergoing mineralization. New bone formation is observed inside the biomaterial too ($\times 200$, acid fuchsin and toluidine blue). (c) Osteoid matrix undergoing mineralization inside the biomaterial ($\times 200$, acid fuchsin and toluidine blue). **FIGURE 7.** Radiographic control. **FIGURE 8.** Clinical control.

posterior maxilla and 6 implants in the anterior maxilla. All patients were treated according to the allocated interventions, no drop-out, exclusion, or deviation from the protocol occurred up to 1 year after loading. The prosthetic restorations comprised 10 single crowns (SCs). The last final prosthesis was delivered in March 2011. At the end of the study, no implants were lost and all implants were still in function, giving an overall survival rate of 100% (Figures 7 and 8). None of the implants caused pain, suppuration, or exudation or were clinically mobile. No implants showed continuous peri-implant radiolucency, and no prosthetic complications were reported.

DISCUSSION

To perform esthetic and prosthetic rehabilitation with dental implants, alveolar ridge augmentation is often needed for patients with extensive horizontal and vertical ridge resorption.² Strategies used to overcome alveolar ridge atrophy include various techniques and materials developed to increase bone volume, including onlay/inlay bone grafting,^{5–7} guided bone regeneration,^{8,9} ridge split tech-

nique/ridge expansion,¹⁰ and distraction osteogenesis.⁹ Over the years, autogenous bone has remained the gold standard for maxillofacial reconstruction.^{2,5,7,11,12} However, autogenous bone transplants have limitations,^{12–14} including the requirement for additional surgery for harvesting, the availability of grafts of sufficient size and shape, and the risk of donor site morbidity (which may include fracture, long-standing pain, nerve damage and infection).^{12–14} In addition, one of the most unfavorable consequences with autogenous bone is a tendency toward graft resorption, which seems more prevalent with endochondral bone onlay grafts, such as those from the iliac crest, when not in function with implant prostheses.^{12–14} A variety of bone substitutes—such as allogeneic, xenogenic, and synthetic materials—as well as combinations of these are currently available for ridge augmentation.^{7,15–18} An ideal bone substitute should be able to regenerate complex 3D anatomical defects while possessing mechanical properties similar to the native structures, allowing for function and load bearing. It should be biocompatible and, ideally, bioresorbable. It should contain continuous internal porosity for proper tissue formation and permit nutrient and waste exchange. Lastly, it should

encourage appropriate cell differentiation through either soluble or insoluble factor signaling and allow for delivery of pluripotent cell types, such as mesenchymal stem cells.¹⁵⁻¹⁸ Surgeons are always searching for improved techniques for reconstruction. Until now, surgeons have estimated the size and shape of a bone graft through preoperative planning, using plain radiographs, and deciding the final shape and manually cutting a bone graft into shape during the operation.¹⁹⁻²¹ With this complex and time-consuming approach, the size and shape of conventional bone grafts could be rather inaccurate, depending heavily upon each surgeon's level of skill, and could result in unstable clinical outcomes.¹⁹⁻²¹ Now, digital CT images combined with CAD/CAM techniques can be used as tools to directly produce customized devices in a biocompatible scaffold, providing a valuable alternative to bone replacement based on autograft procedures.¹⁹⁻²¹

CAD/CAM technologies have started a new age in dentistry.¹⁹⁻²⁸ The development of CAD/CAM software, implemented in radiology procedures, and the easy acquisition and transfer of DICOM data allow the surgeon to analyze the patient by performing 3D measurements and to manipulate deformed or missing anatomy by segmentation and insertion of unaltered or ideal skeletal constructs.¹⁹⁻²⁸ CAD/CAM technologies can be indirectly or directly applied in the field of maxillofacial bone reconstruction to improve the precision of reconstruction. The indirect method consists of printing CT scan data to produce a 3D stereolithographic model of the maxilla/mandible, on which the graft material can be manually shaped preoperatively.^{24,26} Although this method is currently used and reduces operative time at surgery, the shaping precision is limited because bone deformities are printed together with healthy bone, so it is difficult to recompose the original anatomy. The manually bent material can cause positioning bias because only low precision may be gained if no system exists to transfer the virtual planning into the surgical environment, and the procedure is time-consuming.²⁴⁻²⁶ Owing to recent improvements in computer technology combined with advanced 3D cutting machinery, however, it is now possible to directly cut a block of bone substitute into the most appropriate shape that has been preoperatively designed using 3D com-

puted simulation.²¹ This technique, along with the use of recently developed bone substitutes—such as porous hydroxyapatite, which has excellent osteoconductivity and mechanical properties suitable for machine-cutting—make it possible to preoperatively cut the bone graft into a highly accurate anatomically shaped, custom-made scaffold.²¹ In the present study, a new protocol for computer-assisted surgery is introduced. This protocol can be divided into four phases: (1) the data acquisition phase, which includes CT scan of the patient; (2) the planning phase, which includes the importing of CT data into a software program for virtual planning and design of the anatomically shaped, custom-made scaffold; (3) manufacture of the custom-made scaffold using CAD/CAM technology and proprietary CNC milling machine; and (4) the surgical phase, which includes utilizing CAD/CAM-derived scaffold for alveolar ridge augmentation of the maxilla. In this 1-year prospective study, the custom-made scaffolds were of satisfactory size, shape, and appearance, matched the defect area, suited the surgeon's requirements, and were easily implanted during surgery. This helped reduce the time for surgery and contributed to the good healing of the defects. In two patients, the custom-made scaffolds broke at the placement of titanium mini-screws for rigid fixation; however, these were considered minor complications as the broken scaffolds were easily placed and again secured in position. A good fit was obtained, and no other complications were registered. After 8 months, well-formed bone was clinically available to allow a correct implant placement. The protocol presented in this paper offers several benefits: The virtual environment permits ideal preoperative planning. Intraoperative time is not consumed by approximately and repeatedly modeling the scaffold to the native maxilla (as in conventional procedures). In fact, the utilized CNC milling process was highly accurate in 10 patients without the need for intraoperative correction. The approach offered precise, anatomically fitting scaffolds, with the benefit of increased stability and reduced operative time. Another benefit of this technique is the accurate reproduction of the patient's maxillary contour, reducing the quantity of graft material required for conventional bone augmentation techniques. Conventional augmentation procedures

often require more graft material, if an accurate preoperative planning is absent.^{24,26}

The protocol introduced in this study has some limitations. The first limitation is dimensional, and is related to the maximum size of the customized scaffold (12 mm height × 10 mm width). In fact, to obtain favorable reconstructive results, the bone grafting procedure needs three fundamental requisites: a suitable vascular support, a valid interface between graft and the osteogenic cell lines, and the mechanical stability of the graft.^{5-18,27-29} Because the osteoblasts require high oxygen tension for bone matrix production, the higher the permeability of the graft to the vascular network, the more effective the new bone formation.^{5-18,27-29} A complete vascular invasion of the scaffold has to be considered an important prerequisite for successful bone regeneration.^{5-18,27-29} If the scaffold is too big, vascular invasion can be poor, and this could finally jeopardize the healing process.²⁷⁻²⁹ The second limitation is related to the presence of metallic restorations next to the edentulous area; in fact, the presence of artifacts may complicate the CAD process and the custom-made scaffold design. Third, the scaffold is designed for placement in the defect area and not to be in contact with the residual roots. In particular, the scaffold is designed to have a distance of at least 2 mm from the adjacent teeth (residual roots). This distance is decided during the CAD process; however, the presence of narrow spaces and partial root exposure may represent a limitation of this technique. In these cases, clinicians may have difficulty avoiding contact between the scaffold and the residual roots. Calcium phosphate prostheses made from porous HA have been widely used for hard tissue repair and augmentation in different clinical settings because of their good biocompatibility and osteoconductivity.^{21,28,29} They have appropriate porosity for the diffusion of nutrients and the invasion of vascularity from a surrounding tissue, and appropriate surface chemistry to allow cells to adhere and express the osteogenic phenotype. In addition, porous HA possess appropriate mechanical strength; they are able to form a suitable shape easily and ultimately replace the bone completely within a short period.^{21,28,29} Fabrication of bone replacement materials and scaffolds for tissue engineering applications benefits significantly from manufactur-

ing techniques that precisely control the scaffold architecture, both internally and externally.²¹

In the present study, a limited number of patients were treated, with a short follow-up time; further studies will be necessary to verify these results. However, this study represents the first step in the development of a wider experimental protocol for alveolar ridge augmentation using CAD/CAM technology and porous hydroxyapatite scaffolds. We have presented a new method for the manufacture of anatomically shaped, custom-made scaffolds for ridge augmentation, which improves the precision and efficiency of maxillary reconstruction. Digital technology is advancing rapidly in dentistry.³⁰ Computers are making previously manual tasks easier, faster, cheaper and more predictable.³⁰ This new protocol for alveolar ridge augmentation using CAD/CAM to construct anatomically shaped, custom-made scaffolds may represent a viable way to reproduce the patient's anatomical contour, give the surgeon better procedural control, and reduce operating time.

ABBREVIATIONS

3D: three-dimensional
 CAD/CAM: computer-aided design/computer-aided manufacturing
 CNC: computer-numerical-control
 HA: hydroxyapatite
 STL: stereolithographic

ACKNOWLEDGMENTS

The authors are grateful to senior lecturer Rachel Sammons, University of Birmingham, UK, for help in writing this manuscript.

REFERENCES

1. Chiapasco M, Casentini P, Zaniboni M. Bone augmentation procedures in implant dentistry. *Int J Oral Maxillofac Implants*. 2009; 24(suppl):237-259.
2. Rocchietta I, Fontana F, Simion M. Clinical outcomes of vertical bone augmentation to enable dental implant placement: a systematic review. *J Clin Periodontol*. 2008;35:203-215.
3. Lai HC, Si MS, Zhuang LF, Shen H, Liu YL, Wismeijer D. Long-term outcomes of short dental implants supporting single crowns in posterior region: a clinical retrospective study of 5-10 years. *Clin Oral Implants Res*. 2013;24:230-237.
4. Elangovan S, Mawardi HH, Karimbux NY. Quality assessment of systematic reviews on short dental implants. *J Periodontol*. 2013;84:758-767.

5. Cordaro L, Torsello F, Accorsi Ribeiro C, Liberatore M, Mirisola di Torresanto V. Inlay-onlay grafting for three-dimensional reconstruction of the posterior atrophic maxilla with mandibular bone. *Int J Oral Maxillofac Surg.* 2010;39:350–357.
6. Jensen OT, Kuhlke L, Bedard JF, White D. Alveolar segmental sandwich osteotomy for anterior maxillary vertical augmentation prior to implant placement. *J Oral Maxillofac Surg.* 2006;64:290–296.
7. Felice P, Marchetti C, Iezzi G, et al. Vertical ridge augmentation of the atrophic posterior mandible with interpositional bloc grafts: bone from the iliac crest vs bovine anorganic bone. Clinical and histological results up to one year after loading from a randomized controlled clinical trial. *Clin Oral Implants Res.* 2009;20:1386–1393.
8. Urban IA, Jovanovic SA, Lozada JL. Vertical ridge augmentation using guided bone regeneration (GBR) in three clinical scenarios prior to implant placement: a retrospective study of 35 patients 12 to 72 months after loading. *Int J Oral Maxillofac Implants.* 2009;24:502–510.
9. Chiapasco M, Romeo E, Casentini P. Alveolar distraction osteogenesis vs vertical guided bone regeneration for the correction of vertically deficient edentulous ridges: A 1–3 year prospective study on humans. *Clin Oral Implants Res.* 2004;15:82–95.
10. Gonzalez-Garcia R, Monje F, Moreno C. Alveolar split osteotomy for the treatment of the severe narrow ridge maxillary atrophy: a modified technique. *Int J Oral Maxillofac Surg.* 2011;40:57–64.
11. Carinci F, Farina A, Zanetti U, et al. Alveolar ridge augmentation: a comparative longitudinal study between calvaria and iliac crest bone grafts. *J Oral Implantol.* 2005;31:39–45.
12. Esposito M, Grusovin MG, Felice P, Karatzopoulos G, Worthington HV, Coulthard P. The efficacy of horizontal and vertical bone augmentation procedures for dental implants. A Cochrane systematic review. *Eur J Oral Implantol.* 2009;2:167–184.
13. Chiapasco M, Zaniboni M. Failures in jaw reconstruction surgery with autogenous onlay bone grafts for pre-implant purposes: incidence, prevention and management of complications. *Oral Maxillofac Surg Clin North Am.* 2011;23:1–15.
14. Sbordone L, Toti P, Menghim-Fabris GB, Sbordone C, Piombino P, Guidetti F. Volume changes of autogenous bone grafts after alveolar ridge augmentation of atrophic maxillae and mandibles. *Int J Oral Maxillofac Surg.* 2009;38:1059–1065.
15. Blokhuis TJ, Arts JJ. Bioactive and osteoinductive bone graft substitutes: definitions, facts and myths. *Injury.* 2011;2(suppl 2):S26–S29.
16. Contar CM, Sarot JR, da Costa MB, et al. Fresh-frozen bone allografts in maxillary ridge augmentation: histologic analysis. *J Oral Implantol.* 2011;37:223–231.
17. Walloway P, Dorow A. Lateral augmentation of the alveolar ridge using framework technique with allogeneic bone grafts. *J Oral Implantol.* 2012;38:661–667.
18. Guda T, Oh S, Appleford MR, Ong JL. Bilayer hydroxyapatite scaffolds for maxillofacial bone tissue engineering. *Int J Oral Maxillofac Implants.* 2012;27:288–294.
19. Markiewicz MR, Bella RB. Modern concepts in computer-assisted craniomaxillofacial reconstruction. *Curr Opin Otolaryngol Head Neck Surg.* 2011;19:295–301.
20. Smith MH, Flanagan CL, Kempainen JM, et al. Computed tomography based tissue-engineered scaffolds in craniomaxillofacial surgery. *Int J Med Robotics Comput Assist Surg.* 2007;3:207–216.
21. Oka K, Murase T, Moritomo H, Goto A, Yoshikawa H. Corrective osteotomy using customized hydroxyapatite implants prepared by preoperative computer simulation. *Int J Med Robotics Comput Assist Surg.* 2010;6:186–193.
22. González-García R, Naval-Gías L, Muñoz-Guerra MF, Sastre-Pérez J, Rodríguez-Campo FJ, Gil-Díez-Usandizaga JL. Pre-prosthetic and implantological surgery in patients with severe maxillary atrophy. *Med Oral Patol Oral Cir Bucal.* 2005;10:343–354.
23. Weber HP, Crohin CC, Fiorellini JP. A 5-year prospective clinical and radiographic study of non-submerged dental implants. *Clin Oral Implants Res.* 2000;11:144–153.
24. Albrektsson T, Zarb G. Determinants of correct clinical reporting. *Int J Prosthodont.* 1998;11:517–521.
25. Benazzi S, Fiorenza L, Kozakowski S, Kullmer O. Comparing 3D virtual methods for hemimandibular body reconstruction. *Anat Rec (Hoboken).* 2011;294:1116–1125.
26. Cohen A, Laviv A, Berman P, Nashef R, Abu-Thair J. Mandibular reconstruction using stereolithographic 3-dimensional printing modeling technology. *Oral Surg Oral Med Oral Pathol Oral Radiol Endod.* 2009;18:661–666.
27. Grayson WL, Frolich M, Yeager K, et al. Engineering anatomically shaped human bone grafts. *Proc Natl Acad Sci USA.* 2010;107:3299–3304.
28. Figliuzzi M, Mangano F, Fortunato L, et al. Vertical ridge augmentation of the atrophic posterior mandible with custom-made CAD/CAM porous hydroxyapatite scaffolds: a case report. *J Craniofac Surg.* 2013; 24: 856–859.
29. Mangano F, Zecca P, Pozzi-Taubert S, et al. Maxillary sinus augmentation using computer-aided-design/ computer-aided-manufacturing (CAD/CAM) technology. *Int J Med Rob.* 2013;9:331–338.
30. van Noort R. The future of dental devices is digital. *Dent Mater.* 2012;28:3–12.