

# Modification of Maxillary Sinus Floor With Orthodontic Treatment and Implant Therapy: A Case Letter

Mehmet Sağlam, PhD<sup>1\*</sup>  
 Serhan Akman, PhD<sup>2</sup>  
 Sıddık Malkoç, ProfDr<sup>3</sup>  
 Sema S. Hakki, ProfDr<sup>4</sup>

## INTRODUCTION

Inadequate alveolar bone height in the maxillary posterior region is a common challenge for dental implant therapy. Grafting the maxillary sinus with autogenous bone or bone substitute materials is the most common modality for restoring the insufficient bone height in this region.<sup>1,2</sup> The techniques contemporarily used for sinus augmentation are (1) osteotome sinus floor elevation (OSFE), (2) bone-added OSFE<sup>2,3</sup>, (3) minimally-invasive antral membrane balloon elevation<sup>4</sup>, (4) crestal core elevation<sup>2,5</sup>, and (5) the lateral window technique.<sup>2</sup> Complications involved with these techniques are nerve and vascular injury, membrane perforation, acute or chronic sinus infection, exposure of barrier membrane, and graft loss.<sup>4,6,7</sup>

It is clinically possible to displace a tooth and its periodontium by the generation of orthodontic forces consistent with physiological displacement.<sup>8</sup> According to the pressure tension theory, the application of adequate force to a tooth allows bone resorption at the pressure side while newly formed bone is deposited on the tension side.<sup>9</sup> Therefore, it is possible to reshape the anatomy of the maxillary sinus with tooth movement.<sup>9,10</sup> Orthodontic-induced reshaping of the maxillary sinus floor may provide adequate space for implant placement.

The purpose of this case letter was to present a

clinical case with a sinus floor anatomical modification by orthodontic tooth movement followed by implant placement that includes a 2-year follow-up.

## CASE DESCRIPTION AND RESULTS

A 54-years-old male patient with chronic periodontitis and controlled type 2 diabetes presented with an edentulous posterior maxilla. The patient has used a removable prosthesis for many years (Figure 1). The posterior maxilla had insufficient bone height for implant placement (Figure 2). Bone augmentation was a consideration, but the patient refused this surgical option. Therefore, it was decided that second premolars could be moved distally through the maxillary sinus and the resulting edentulous spaces could be restored with 2 titanium implants. This would result in the patient having 3 premolars in each maxillary quadrant. The interarch relationships were compatible with an implant prosthesis and there was no absolute contraindication to implant surgery. During the initial visit, periodontal scaling was performed by hand (HU Fredy, Chicago, IL) and ultrasonic (Satelec, Merignac, France) instruments plus oral hygiene instruction were provided. At the second visit, root planning was performed to eliminate deep periodontal pockets. One month after post-root planning, there were no pocket depths greater than 3 mm. Subsequently, an orthodontic treatment plan allowing for dental implant placement was presented and accepted by the patient.

## ORTHODONTIC TREATMENT

The spaces needed for the dental implants were initially opened with a multibracket appliance and coil springs (Figure 3). Adequate space (7 mm

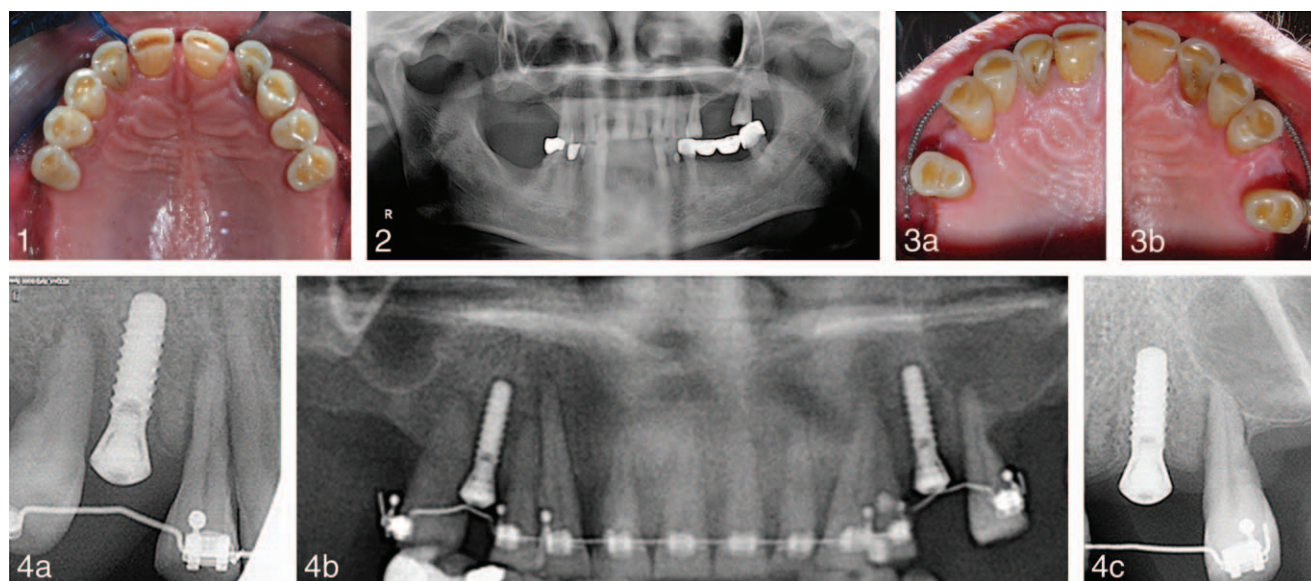
<sup>1</sup> Department of Periodontology, Izmir Katip Celebi University, Izmir, Turkey.

<sup>2</sup> Department of Prosthodontics, Selcuk University, Konya, Turkey.

<sup>3</sup> Department of Orthodontics, Inonu University, Malatya, Turkey.

<sup>4</sup> Department of Periodontology, Selcuk University, Konya, Turkey.

\* Corresponding author, e-mail: dtmehmetsaglam@hotmail.com  
 DOI: 10.1563/AAID-JOI-D-12-00136



**FIGURES 1–4.** **FIGURE 1.** Preoperative clinical intra-oral occlusal view. **FIGURE 2.** Preoperative panoramic radiograph. **FIGURE 3.** Intra-oral view showing the initial distal movement of the second premolars through the sinus with coil springs. (a) Occlusal view of right side. (b) Occlusal view of left side. **FIGURE 4.** (a) Periapical radiograph of upper right implant. (b) Panoramic radiograph of inserted dental implants. (c) Periapical radiograph of upper left implant.

mesiodistally and 6 mm buccopalatally) was provided to place dental implants 6 months after completion of the orthodontic treatment. Corresponding to accepted dental implant healing protocols, the orthodontic appliances were used to retain the distalized teeth at their new positions for an additional 4 months.

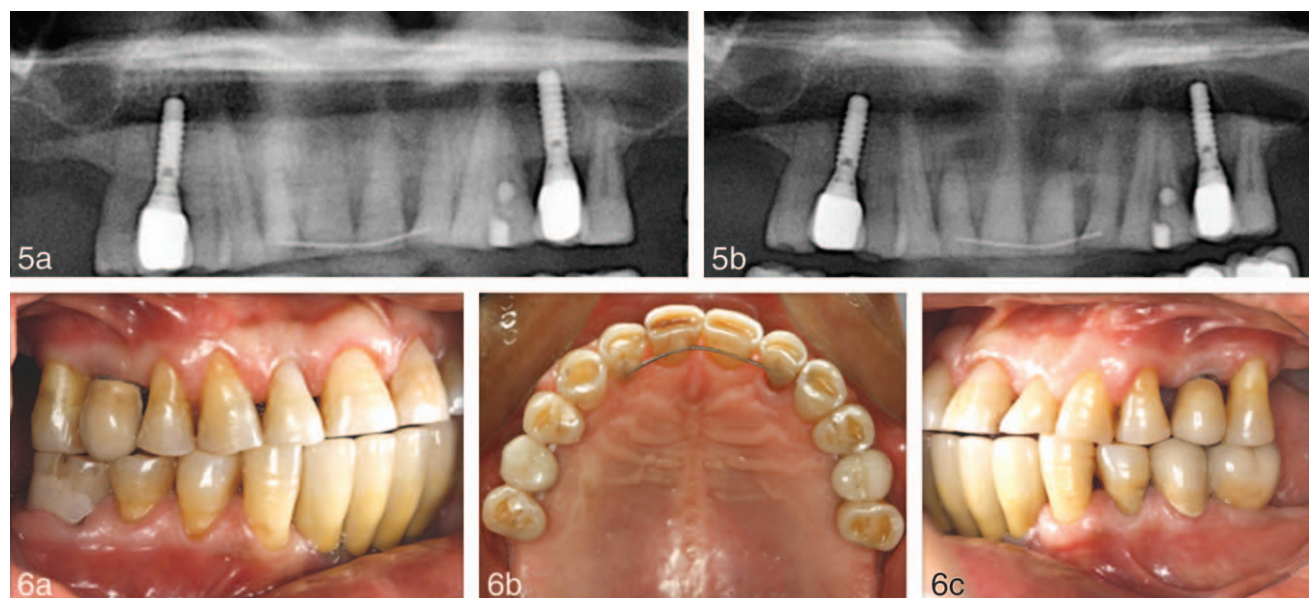
#### IMPLANT THERAPY

Dental implants were placed using a 1-stage protocol. After administering local anesthesia (Ultra-cain DS, Aventis Pharmaceuticals, Istanbul, Turkey), an incision was made on the alveolar ridge. The flap was fully elevated, and 2 dental implants (Straumann AG, Basel, Switzerland), 4.1 mm wide and 14 mm long, were placed between the newly positioned first and second premolars. Good primary stability was obtained for each implant. The mucoperiosteal flaps were adapted around the implant necks to allow nonsubmerged healing and sutured with silk sutures (Sterisilk, SSM Sterile Health Products Inc, Istanbul, Turkey). Postoperative medication included amoxicillin, 500 mg, 3 times a day for 10 days; flurbiprofen, 100 mg, 2 times a day for 5 days; and 0.2% chlorhexidine mouth rinse (Corsodyl, GlaxoSmithKline Consumer Healthcare, Middlesex, UK), 2 times a day for a week. The silk

sutures were removed 10 days post surgery. A 0.2% chlorhexidine mouth-rinse was used 2 times a day for a week. There were no complications 2 weeks after suture removal. Gingival tissue around the dental implants demonstrated no signs of inflammation. The patient was examined clinically and radiographically at 4 months post-implant surgery, and it was found that implant stability was good. Neither pain to percussion nor signs of inflammation were found. Both implants appeared radiographically osseointegrated (Figure 4) with no signs of bone resorption around either implant. Class I mobility was observed in distalized second premolar teeth but this mobility has decreased over time. Prosthetic restorations with a shortened posterior occlusion were provided for the patient. There were no remarkable radiographic changes 1 and 2 years after prosthetic loading (Figure 5). The intraoral tissue health was acceptable 2 years after prosthetic loading (Figure 6).

#### DISCUSSION

Many techniques are currently available to treat atrophy of the edentulous posterior maxilla. Regarding posterior atrophy of the maxilla, the sinus-lift technique showed a major improvement among treatment techniques for rehabilitation of edentu-



**FIGURES 5 and 6.** **FIGURE 5.** (a) Postoperative panoramic radiograph (1 year after prosthetic loading). (b) Postoperative panoramic radiograph (2 years after prosthetic loading). **FIGURE 6.** Postoperative clinical intra-oral view (2 years after prosthetic loading). (a) Right side. (b) Occlusal view. (c) Left side.

lous maxillary-posterior areas. A variety of grafting materials and surgical approaches have been utilized to effect sinus augmentation.<sup>11</sup> For the sinus lifting procedure, Schneiderian membrane perforations are the main complication during surgery with an occurrence of 7%–35% of the procedures.<sup>6</sup> Postsurgical complications consist of acute or chronic sinus infection, bleeding, wound dehiscence, exposure of barrier membrane, and graft loss.<sup>6</sup> The contamination of bone, harvested intraorally, with the periodontopathogens (*Porphyromonas gingivalis*, *Aggregatibacter actinomycetemcomitans*, *Tannerella forsythia*, or *Prevotella intermedia*), salivary Epstein-Barr virus type 1, or the combination of both, can impair osteogenesis and cause increased bone volume loss in sinus augmentation procedures.<sup>12</sup>

There are some conservative treatment options available to avoid entering the sinus cavity. One of them is placing short implants. But there is still a need for at least 6 mm of residual bone height for placement of short implants.<sup>13–15</sup> Another way of avoiding grafting the maxillary sinus would be to place tilted implants in a position mesial or distal to the sinus cavity if these areas have adequate bone.<sup>16</sup>

An additional alternative is the modification of the maxillary sinus floor by orthodontic tooth movement to provide adequate space for implant

therapy. However, the pneumatization of maxillary sinus may impede orthodontic tooth movement. Nevertheless, if proper force and mechanic are applied, tooth movement through maxillary sinus can be achieved.<sup>10,17</sup> Cacciafesta and Melsen<sup>17</sup> suggested segmented archwire mechanics to provide constant force in situations where tooth movement through the maxillary sinus was planned. They demonstrated that a force of 50 gr exerted from Ni-Ti sentalloy spring could achieve tooth movement through the maxillary sinus. Re et al<sup>10</sup> reported a case, which exhibited pneumatization of the maxillary sinus that resulted from earlier extractions. The patient was treated using an endosseous implant inserted in the retromolar region to serve as orthodontic anchorage and a T-loop appliance fabricated from TMA wire to bodily move an upper second premolar through the sinus. After 6 months of active orthodontic treatment, a titanium implant with subsequent crown restoration was inserted in the alveolus of the moved tooth. They also reported that the endosseous implant inserted in the retromolar area and used as anchor has maintained its osseointegration at the end of the treatment. In our case letter, anchorage was not achieved by the use of an endosseous implant. Instead a multi-bracket appliance and coil spring were used for distalization. Distalized second premolars maintained pulp vitality and bone

support without the loss of the connective tissue attachment.

Graft materials with poor osteogenic potential, overpacking of graft materials that restrain the blood supply, and microbial contamination of bone may cause incomplete bone formation after a sinus grafting procedure.<sup>18</sup> This can adversely affect the implant therapy. Additionally, the presence of septa or severe sinus floor convolutions in maxillary sinus and narrow sinus are difficult conditions to manage in the sinus membrane lifting procedure.<sup>19</sup> In these situations orthodontic treatment could be a predictable method to reshape the maxillary sinus.

This case letter reports on a noninvasive procedure for modifying the maxillary sinus floor for implant placement. This procedure, for this patient, yielded satisfactory bone space for implantation and eliminated the complications and discomfort associated with traditional sinus lifting techniques.

Modification of sinus floor by orthodontic treatment seems to be a safe and effective method to provide adequate space for implant insertion and can be considered as an alternative treatment option in patients a needing sinus augmentation procedure because of inadequate bone height in the posterior maxilla.

## REFERENCES

1. Peleg M, Mazor Z, Chaushu G, Garg AK. Sinus floor augmentation with simultaneous implant placement in the severely atrophic maxilla. *J Periodontol.* 1998;69:1397–1403.
2. Wallace SS, Froum SJ. Effect of maxillary sinus augmentation on the survival of endosseous dental implants. A systematic review. *Ann Periodontol.* 2003;8:328–343.
3. Summers RB. The osteotome technique: Part 3—Less invasive methods of elevating the sinus floor. *Compendium.* 1994; 15:698–708, 700, 702–704 passim; quiz 710.
4. Kfir E, Kfir V, Eliav E, Kaluski E. Minimally invasive antral membrane balloon elevation: report of 36 procedures. *J Periodontol.* 2007;78:2032–2035.
5. Summers RB. The osteotome technique: Part 4—Future site development. *Compend Contin Educ Dent.* 1995;16:1090–1099, 1092 passim; 1094–1096, 1098, quiz 1099.
6. Schwartz-Arad D, Herzberg R, Dolev E. The prevalence of surgical complications of the sinus graft procedure and their impact on implant survival. *J Periodontol.* 2004;75:511–516.
7. Barone A, Santini S, Sbordone L, Crespi R, Covani U. A clinical study of the outcomes and complications associated with maxillary sinus augmentation. *Int J Oral Maxillofacial Implants.* 2006; 21:81–85.
8. Berglundh T, Marinello CP, Lindhe J, Thilander B, Liljenberg B. Periodontal tissue reactions to orthodontic extrusion. An experimental study in the dog. *J Clin Periodontol.* 1991;18:330–336.
9. Ong MA, Wang HL, Smith FN. Interrelationship between periodontics and adult orthodontics. *J Clin Periodontol.* 1998;25: 271–277.
10. Re S, Cardaropoli D, Corrente G, Abundo R. Bodily tooth movement through the maxillary sinus with implant anchorage for single tooth replacement. *Clin Orthod Res.* 2001;4:177–181.
11. Jensen OT, Shulman LB, Block MS, Iacono VJ. Report of the Sinus Consensus Conference of 1996. *Int J Oral Maxillofacial Implants.* 1998;13 Suppl:1–41.
12. Verdugo F, Castillo A, Simonian K, et al. Periodontopathogen and Epstein-Barr virus contamination affects transplanted bone volume in sinus augmentation. *J Periodontol.* 2012;83:162–173.
13. Anitua E, Orive G. Short implants in maxillae and mandibles: a retrospective study with 1 to 8 years of follow-up. *J Periodontol.* 2010;81:819–826.
14. Misch CE, Steingra J, Barboza E, Misch-Dietsh F, Cianciola LJ, Kazor C. Short dental implants in posterior partial edentulism: a multicenter retrospective 6-year case series study. *J Periodontol.* 2006;77:1340–1347.
15. Esposito M, Pellegrino G, Pistilli R, Felice P. Rehabilitation of posterior atrophic edentulous jaws: prostheses supported by 5 mm short implants or by longer implants in augmented bone? One-year results from a pilot randomised clinical trial. *Eur J Oral Implantol.* 2011;4:21–30.
16. Barone A, Orlando B, Tonelli P, Covani U. Survival rate for implants placed in the posterior maxilla with and without sinus augmentation: a comparative cohort study. *J Periodontol.* 2011;82: 219–226.
17. Cacciafesta V, Melsen B. Mesial bodily movement of maxillary and mandibular molars with segmented mechanics. *Clin Orthod Res.* 2001;4:182–188.
18. Lee KS, Kwon YH, Herr Y, Shin SI, Lee JY, Chung JH. Incomplete bone formation after sinus augmentation: A case report on radiological findings by computerized tomography at follow-up. *J Periodontal Implant Sci.* 2010;40:283–288.
19. ten Bruggenkate CM, van den Bergh JP. Maxillary sinus floor elevation: a valuable pre-prosthetic procedure. *Periodontol* 2000. 1998;17:176–182.