

# A Comparison of Computed Tomography Scans and Digital Periapical Radiographs Ridge Height Measurements

Ravichandra Juluri, BDS, MS<sup>1</sup>

Maria Moran, DMD, MS<sup>2</sup>

Jon B. Suzuki, DDS, PhD<sup>3</sup>

Ahmed Khocht, DDS, MSD<sup>3\*</sup>

To investigate the agreement between computerized tomography scans (CT) and intraoral periapical digital radiographs (PA) alveolar ridge height measurements in maxillary and mandibular posterior regions. We reviewed 100 implant patient radiographic records and identified 27 mandibular sites in 19 patients and 23 maxillary sites in 13 patients with available CT scans and matching PA radiographs. The distance from the crest of the ridge to the floor of the maxillary sinus or to the superior border of the inferior alveolar canal was measured. PAs were measured with Dexis software v. 8.0 and CTs were measured with Simplant software v. 11.02. Two examiners (RJ and MM) recorded the measurements separately; each examiner recorded two readings. The average of the 4 readings was used for data analysis. Absolute agreement: Paired *t* test comparing ridge-height measurements between the two imaging methods showed no differences for maxillary sites ( $P > 0.2$ ) and significant differences for the mandibular sites (CT  $>$  PA,  $P = 0.0009$ ). Relative agreement: Kendall rank correlation analysis of ridge-height measurements between the 2 imaging methods showed a high positive correlation for maxillary sites (Kendall's tau = 0.76,  $P = 0.0001$ ) and moderate correlation for the mandibular sites (Kendall's tau = 0.46,  $P = 0.001$ ). Maxillary PAs tend to approximate CT ridge-height measurements. By contrast mandibular PAs tend to underestimate the distance from the crest of the ridge to the inferior alveolar canal.

**Key Words:** alveolar process, radiography, dental implantation, endosseous, humans, patient care planning, preoperative care, tomography, X-ray computed

## INTRODUCTION

The advent of computerized tomography (CT) greatly facilitated the treatment planning and surgical placement of dental implants.<sup>1-3</sup> CT scans are widely used today and they offer many views that intraoral radiographs cannot match in practicality and usefulness.<sup>1,2,4</sup> Of particular interest is the cross-sectional view that allows assessment of the width and height of the jawbone available for implant placement.<sup>1,2</sup> CT scans can reveal with ease and accuracy important anatomical structures such as the floor of the maxillary sinus and superior boarder of the mandibular nerve canal.<sup>1,2</sup> With software enhancements they allow mandibular nerve mapping and virtual placement of dental implant fixtures for optimal surgical planning.<sup>1,2</sup> Some of the disadvantages of CT scans are cost<sup>5</sup> and increased X-ray dose.<sup>1,2,6-9</sup>

Not every patient in need of dental implants requires CT scan imaging.<sup>10</sup> If the implant site is away from sensitive anatomical structures and the alveolar ridge is apparently of adequate buccolingual width, conventional intraoral radiographs might be sufficient to assess the site for implant placement.<sup>11</sup> Periapical (PA) intraoral radiographs are widely

available and routinely used in the clinical practice of dentistry.<sup>1,2</sup> Conceivably, PA radiographs should be able to provide information regarding ridge height and help with assessment of bone pattern and density. Using PA radiographs to assess alveolar ridge height for implant placement would minimize cost and reduce radiation exposure associated with CT scans.

Previous studies investigating the relation between ridge height measurements on CT scans and PA radiographs mainly focused on the mandibular arch in cadaver specimens.<sup>12-14</sup> The relation between ridge height measurements on CT scans and PA radiographs taken under normal clinical use has not been previously investigated. Since clinicians often use both image types together in the treatment planning and surgical placement of implants, lack of knowledge of the relation of measures between the 2 imaging systems is a relevant gap in knowledge that needs to be addressed.

We hypothesized that due to the different technologies of the 2 imaging systems and the different views they offer the measurements of alveolar ridge height on CT scans and PA radiographs would be different. The objective of this study was to investigate the agreement between measurements of ridge height in the maxillary and mandibular posterior regions from CT scan images and intraoral periapical digital radiographs taken under normal clinical use.

Null hypothesis:  $H_0: \mu d = 0$  (where  $d$  = difference between CT and PA ridge height measurements).

<sup>1</sup> Meharry Medical College School of Dentistry, Nashville, Tenn.

<sup>2</sup> Private practice, Torrance, Calif.

<sup>3</sup> Temple University School of Dentistry, Philadelphia, Pa.

\* Corresponding author, e-mail: akhocht@llu.edu

DOI: 10.1563/AAID-JOI-D-12-00169

## MATERIALS AND METHODS

The study was approved by Temple University Institutional Review Board.

Sample size calculation: A priori power analysis indicated that a sample size for 80% power to detect a difference of 2 mm between the 2 radiographic methods at  $\alpha = 0.05$  would require an N of 50 sites per radiographic method.

For the purposes of this study previously-taken sets of CT scans and digital PA radiographs were used for measurements. The patients' records were obtained from the record pool available at the graduate periodontology and oral implantology clinic at Temple University School of Dentistry. A total of 100 patient records were reviewed. The main search criteria were partially edentulous individuals with availability of both CT scan and matching PA digital images. A total of 32 individuals with radiographic sets satisfying the search criteria were identified for use in the study. We randomly selected 27 edentulous mandibular sites (Figure 1) in 19 individuals and 23 edentulous maxillary sites (Figure 2) in 13 individuals. Selected sites were adjacent to a tooth in proper alignment without evidence of tilting.

The CT scans were taken at Able Imaging, Cherry Hill, NJ, using a GE Lightspeed CT scan machine. The films and the CD-ROM data files were sent to the graduate periodontology clinic at Temple University and were used for site evaluation prior to surgical placement of dental implants. The digital PAs were taken under regular clinical setting at the periodontology clinic at Temple University School of Dentistry. The images were taken by graduate periodontology residents with an XCP (extension cone paralleling) film holder and a DEXIS digital radiographic sensor (DEXIS LLC, Des Plaines, Ill). A Gendex radiograph machine (model G-770, Gendex Dental Systems, Lake Zurich, Ill) was used for taking all digital PAs. The digital PA radiographs were used to supplement the CT images in the treatment planning of the surgical placement of dental implants.

### Measurements

The distance from the crest of the ridge to the floor of the maxillary sinus or to the superior border of the inferior alveolar canal was measured at a distance of 4 mm from the mesial or distal of the natural tooth adjacent to the edentulous ridge area selected. The 4 mm distance from an adjacent tooth helped with precise site orientation on both imaging systems. CTs were measured with Simplant software v. 11.02 (Materialise Dental Inc, Glen Burnie, Md) and PAs were measured with Dexis software v.8.0 (DEXIS LLC). The Dexis measuring ruler was calibrated to the mm measurement of the Simplant measuring ruler.

CT scan measurements were recorded on a cross-sectional view. A straight line perpendicular to a tangent at the crest of the ridge was extended to either the floor of the maxillary sinus or the superior border of the inferior alveolar canal (Figure 3a). The length of the line was measured in mm and used as CT ridge height. PA measurements were recorded by extending a straight line parallel to the vertical axis of the adjacent natural tooth from the alveolar crest to either the floor of the maxillary sinus or the superior border of the inferior alveolar canal (Figure

3b). The length of the line was measured in mm and used as PA ridge height.

Two examiners (RJ and MM) recorded the measurements. The examiners performed their measurements independently from each other. Each examiner measured the CT scan images and digital PA images twice and took 2 sets of measurements for each image type per site. The examiners took the second set of measurements without having access to the initial set. To control for intra-examiner and interexaminer variability, we averaged both sets of measurements on both radiographic systems. The average of the 4 measurements was used as the unit of analysis.

To minimize intra-examiner and interexaminer variability, the examiners were calibrated in both radiographic imaging systems to recognize and agree on what they would consider the floor of the maxillary sinus, the superior boarder of the inferior alveolar nerve canal and the alveolar ridge crest. Measurement system analysis was used to assess the precision, consistency and bias of the measurement system utilized in the study.<sup>15</sup> The analysis showed that the 2 examiners were measuring the same way and had similar variation. Intraclass Correlation (ICC) for PA image measurements was 0.96 and for CT scan measurements was 0.99. The high ICC values (close to 1) indicate that most of the variation is coming from variation in ridge height instead of examiner error.

### Statistical analysis

We assessed the agreement between CT scans and PA radiographs in multiple ways:

- Relative agreement: we computed Kendall rank correlation coefficient (Kendall's tau ( $\tau$ )) to examine the relative agreement between the paired observations.
- Absolute agreement: was assessed by comparing the mean difference between ridge height measurements recorded on PA and CT images with a paired *t* test.
- Limit of agreement: was assessed as per Bland and Altman<sup>16</sup> to graphically investigate the agreement between the measurements obtained from the PA and CT images.
- Categorical agreement: to evaluate how each radiographic method presented ridge height clinically, we assigned ridge height measurements for each site to one of the following categories: short, medium, and tall. We then computed the kappa statistic to determine the categorical agreement between the 2 radiographic methods.

All statistical analysis was done with JMP statistical package (v. 10.0, SAS Institute, Inc, Cary, NC).

## RESULTS

There are a total of 50 sites of ridge-height measurements coming from two groups: 27 mandibular sites and 23 maxillary sites. CT measurements ranged from 1.41–20.71 mm and PA measurements ranged from 0.57–16.75 mm. Plotting the difference in measurement between the 2 radiographic methods against mean for all ridge-height data (Figure 4) shows that the majority of observations for maxillary sites (black points) are located to the left of 10mm, with smaller

difference between the 2 methods, usually within  $\pm 2$  mm. The majority of observations for mandibular sites (white points) are on the right side of 10 mm with much larger differences. Therefore, we need to analyze these 2 groups of data separately.

### Maxillary sites

First, we check the relative agreement between CT and PA methods for maxillary sites with the Kendall rank correlation coefficient. The Kendall's tau value is 0.763 ( $P < 0.0001$ ), which indicates that for maxillary sites, CT and PA results are statistically dependent.

Next, we check whether there is absolute agreement between CT and PA methods for the maxillary sites with the paired  $t$  test. The average (SD) for CT measurements was 7.24 (3.39) mm and for PA measurements was 7.1 (3.82) mm. The paired  $t$  test shows no significant difference between the CT and PA imaging methods for maxillary sites ( $P$  value is 0.63). This indicates that CT scan measures are comparable to PA measures.

We also check the limit of agreement and precision of estimated limits of agreement between the 2 radiographic methods for maxillary sites.<sup>16</sup> The mean and the standard deviation of the differences was 0.1465 (1.4396) mm. From Figure 5, we can see most of the points indeed fall between ( $-2$  mm, 2 mm) which is the maximum tolerated difference range we specified between the 2 imaging methods. This shows relatively good agreement between CT and PA imaging methods for maxillary sites.

### Mandibular sites

For mandibular sites, the tau value is 0.46 ( $P < 0.001$ ). This statistical dependence shows relative agreement between CT and PA methods for mandibular sites as well. The average (SD) for CT measurements was 14.29 (3.41) mm and for PA measurements was 12.46 (2.73) mm. The paired  $t$  test shows there is a significant difference between the CT and PA imaging methods ( $P < 0.001$ ). Based on the means for both methods, we can conclude that CT scan measures are statistically larger than PA measures.

For mandibular sites the mean and the standard deviation of the differences was 1.83 (2.55) mm. The limits of agreement for mandibular sites are ( $-3.26$ , 6.92). This lack of agreement is also obvious in Figure 6. Most of mandibular points fall outside the range of ( $-2$ , 2). The standard error of the limit  $d-2s$  and  $d+2s$  is 0.849. The 95% CI for the lower limits of agreement is ( $-5.01$ ,  $-1.52$ ), and the 95% CI for the upper limits of agreement is (5.17, 8.67). Even the most conservative 95% CI for the limits of agreement ( $-1.52$ , 5.17) is wider than maximum tolerate difference range, therefore we would conclude CT and PA methods are significantly different for mandibular sites.

To evaluate how each radiographic method presented ridge height from a clinical perspective we assigned actual measurements from each site to one of the following three ridge height categories: short ( $< 6$  mm), medium (6–10 mm) and tall ( $> 10$  mm). We created a contingency table by cross-tabulating categorical measures from CT scans with categorical measures from PA radiographs by number of sites we assigned

to each category on the bases of the radiographic method (Table 1). The percentage agreement between categorical measures from CT scans and PA radiographs is shown in parentheses.

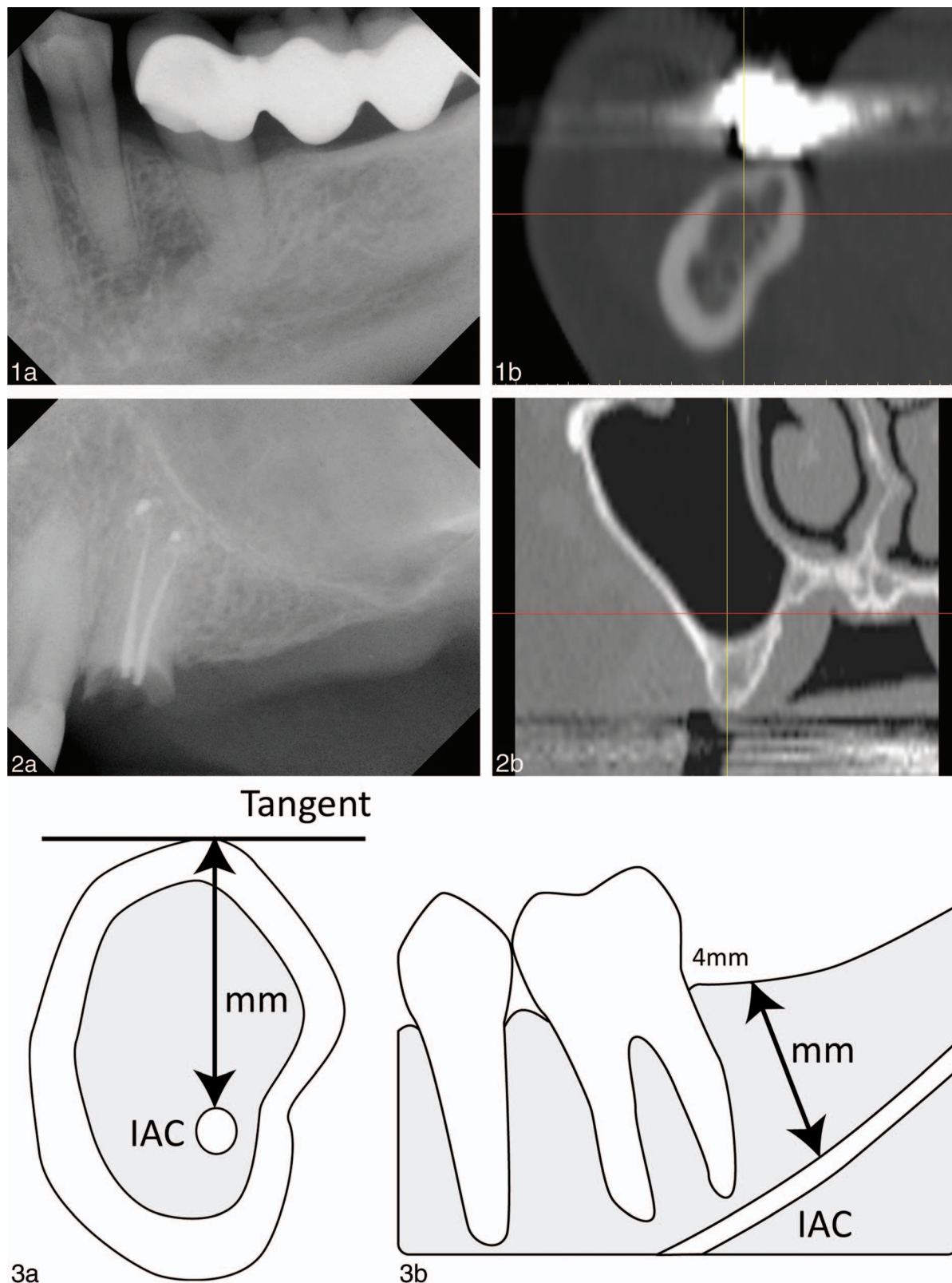
Agreement between CT scans and PA radiographs to present ridge height as short, medium or tall was moderate ( $\kappa = 0.54$ ). The overall percentage agreement was 74%. The percentage agreement tended to increase with increasing ridge height. Chi-square analysis showed significant differences between both imaging systems in categorizing ridge height ( $P = 0.001$ ). The number of sites categorized as short by both imaging systems was small. Out of 5 sites categorized as having short ridge height based on CT scan measures only 3 sites agreed with PA radiographs (60% agreement). Out of 16 sites categorized as having medium ridge height based on CT scan measures only 10 sites agreed with PA radiographs (62.5% agreement). However, out of 29 sites categorized as having tall ridge height based on CT scan measures 24 sites agreed with PA radiographs (82.76% agreement). This indicates better agreement between the 2 imaging systems with ridge height greater than 10 mm.

### DISCUSSION

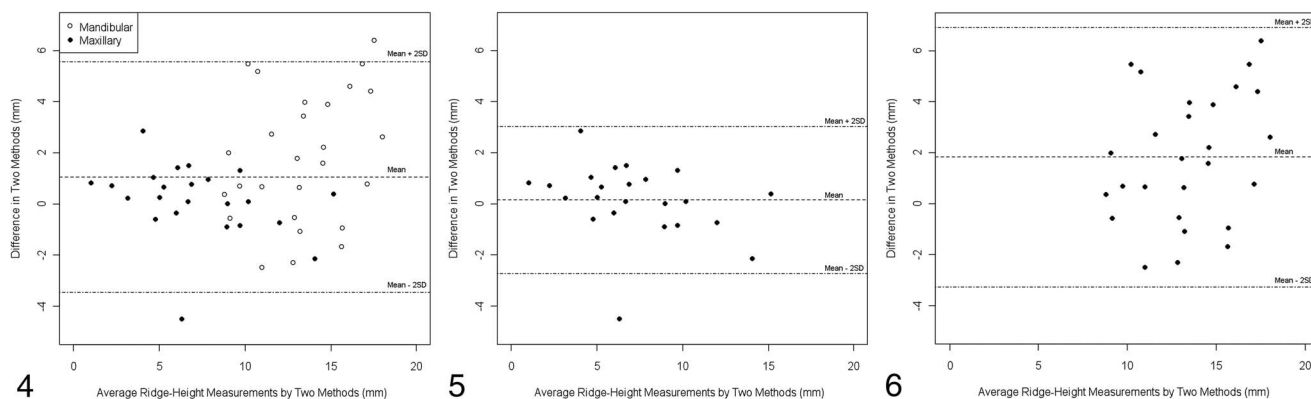
The present study findings demonstrated that edentulous ridge height measurements on PA radiographs and CT scan images were positively related in both maxillary and mandibular arches. However, in the maxilla the absolute measures were comparable but in the mandible the measures significantly differed. Measurements taken on mandibular PA radiographs tended to be lower than the measurements taken on mandibular CT scan images. The 2 imaging systems tended to show better agreement with increasing ridge height. It is interesting to note that despite the differences in the method of determining ridge height using the 2 imaging modalities, the maxillary measurements showed reliably good relative and absolute agreement.

We used several statistical analyses to investigate the agreement between ridge height measurements recorded on the 2 imaging systems. We investigated relative agreement (Kendall rank correlation), absolute agreement (paired  $t$  test), limits of agreement (Bland and Altman) and categorical agreement (Kappa test). The Kappa statistical test is frequently used to determine the degree of agreement between 2 variables.<sup>17,18</sup> The Kappa test requires the variables to be measured on a nominal or ordinal scale, which would not be suitable for the continuous measurements of ridge height recoded in this study. Thus the continuous measurements were converted to an ordinal scale to calculate the Kappa statistic. In addition we used the Bland and Altman method for demonstrating agreement among continuous variables.<sup>16</sup> The Bland and Altman method looks at between-method differences rather than correlation. Although the mandibular measurements showed moderate correlation (Kendall's tau = 0.46), the Bland and Altman analysis showed poor agreement (Figure 6).

For the purposes of this study we selected 2 mm as the critical target difference between the 2 radiographic methods. Our selection of 2-mm target difference is based on the 2-mm safety zone between the apical end of the implant and the



**FIGURES 1–3. FIGURE 1.** Example images of mandibular radiographic matched sets. (a) Represents a periapical (PA) radiograph showing an edentulous area distal to a mandibular premolar. (b) Represents a computerized tomography (CT) cross-sectional view 4 mm distal to the mandibular premolar. **FIGURE 2.** Example images of maxillary radiographic matched sets. (a) Represents a PA radiograph showing an edentulous area distal to a maxillary broken premolar. (b) Represents a CT cross-sectional view 4 mm distal to the maxillary broken premolar. **FIGURE 3.** Ridge height measurement diagrams. (a) Illustrates a mandibular CT cross-sectional view of an edentulous area 4 mm distal to an adjacent natural tooth. A straight line perpendicular to a tangent at the crest of the ridge was extended to the superior border



**FIGURES 4–6.** **FIGURE 4.** Difference against average measurement for all ridge-height data. Maxillary sites represented by black points and mandibular sites by white points. “Mean” line: is the mean difference (d) between computerized tomography (CT) and periapical digital radiograph (PA) measurements. “Mean + 2SD” lines: represent the “limits of agreement” as per Bland and Altman. **FIGURE 5.** Difference against average measurement for maxillary ridge-height data. “Mean” line: is the mean difference (d) between CT and PA measurements. “Mean + 2SD” lines: represent the “limits of agreement” as per Bland and Altman. **FIGURE 6.** Difference against average measurement for mandibular ridge-height data. “Mean” line: is the mean difference (d) between CT and PA measurements. “Mean + 2SD” lines: represent the “limits of agreement” as per Bland and Altman.

adjacent vital structures recommended by most implant manufacturers and practitioners.<sup>19,20</sup> If the difference in measurements between the 2 radiographic methods were less than 2 mm it would be within the recommended safety zone. Even though the mean differences between the 2 methods were <2 mm, the standard deviation of the differences tended to be high indicating a wide range of variance in both upper and lower jaw measurement differences. Most of the differences in the upper jaw fell between the  $-2, +2$  mm limit (Figure 5); by contrast most of the differences in the lower jaw fell outside the  $-2, +2$  mm limit (Figure 6).

It is well documented that alveolar bone density and thickness varies in different regions in the mouth.<sup>21,22</sup> In the posterior maxilla the bone on the buccal and lingual aspects of the alveolar ridge tends to be thin.<sup>21,22</sup> By contrast, in the posterior mandible the bone on the buccal and lingual aspects of the alveolar ridge tends to be thick and dense.<sup>21,22</sup> Furthermore, the buccal aspect of the mandibular bone in the posterior region projects a shelf-like bone process that adds to the thickness of bone.<sup>21,22</sup> The increased bone thickness in the posterior mandible (Figure 1b) most likely obscured visibility of the superior border of the inferior alveolar canal on PA radiographs and resulted in the underestimation of the distance from the crest of the ridge to the inferior alveolar canal. Underestimation of the ridge height in the posterior mandible would lead to using shorter implants or rejecting the site for implant placement.

Both PA radiographs and CT scans are valuable diagnostic aids and implant treatment-planning tools.<sup>3,10,11</sup> Often clinicians would use CT scan images preoperatively for ridge assessment and implant size selection prior to surgical implant placement and use PA radiographs during implant surgery to

assess proper implant orientation and proximity to sensitive anatomical structures.<sup>10,11</sup> In addition, PA radiographs are usually used to assess osseous tissue healing around implants following surgical placement and also to monitor osseous stability around dental implants when put to function.<sup>1,2</sup>

Another commonly-used radiographic imaging technique in dental implant preoperative planning is panoramic radiography.<sup>23</sup> Panoramic radiography gives a general overview of maxillary and mandibular arches, ridge height, maxillary sinus and the mandibular nerve canal in 1 image.<sup>1,2</sup> Panoramic images are widely available and tend to be inexpensive.<sup>23</sup> Their disadvantages include poor resolution, ghost images, magnification, and image distortion.<sup>10,24</sup> Due to image magnification and distortion, precise measurements are not possible.<sup>25</sup> Even though many of the patient records used in this study contained panoramic images, because of their known limitations with precise measurements they were not investigated.

Unlike the 2-dimensional images of conventional radiography, computerized tomography scans offer a 3-dimensional image of the area of interest.<sup>2</sup> A fanbeam of X rays rotates around the patient to generate an axial slice of the area of interest per a single rotation.<sup>1,2,26</sup> Multiple overlapping rotations generate sequential axial slices of the whole area of interest.<sup>1,2,26</sup> With the help of a computer and mathematical algorithms the axial slices are combined to generate a 3-dimensional image of the area of interest.<sup>1,2,26</sup> In the early 1980s, CT scans were introduced to dentistry.<sup>27</sup> The 3-dimensional images of the jawbones were used to determine the absolute bone quantity, bone quality, and the location of vital structures with precision greater than other imaging modalities previously used.<sup>27</sup>

In the posterior maxillary region, upon loss of molar teeth a

of the inferior alveolar canal, with the length of the line measured in mm. (b) Illustrates a mandibular PA image of the same site presented in image (a). Ridge height was recorded at a distance of 4 mm distal to the natural tooth immediately anterior to the edentulous area. A straight line parallel to the vertical axis of the natural tooth was extended from the alveolar crest to the superior border of the inferior alveolar canal, with the length of the line measured in mm. IAC indicates inferior alveolar canal.

TABLE 1

Percentage agreement between categorical ridge height assignments from computerized tomography (CT) scan and periapical (PA) images\*

PA images	CT scan images				Total
	Short	Medium	Tall		
Short	3 (60)	4 (25)	0		7
Medium	2 (40)	10 (62.50)	5 (17.24)		17
Tall	0	2 (12.50)	24 (82.76)		26
Total	5	16	29		50

\*Data presented as number of sites followed by the percentage agreement in parentheses.

combination of alveolar ridge resorption and pneumatization of the maxillary sinus may severely impact on ridge height.<sup>21</sup> Locating the floor of the maxillary sinus and examining its relation to the alveolar crest is essential in the preoperative planning of implant placement in the posterior maxilla.<sup>3</sup> CT scan images can accurately locate the floor of the maxillary sinus, and allow excellent visualization of the sinus anatomy and sinus pathology if present.<sup>25,28</sup> In this study PA radiographs in the posterior maxilla showed ridge height measurements comparable to those obtained from CT scan images. These findings suggest that bone thickness in the posterior maxilla does not hinder the visualization of the maxillary sinus floor on PA radiographs.

In the mandible, most CT scan studies have focused on the localization of the mandibular nerve canal within the body of cadaver mandibles. Klinge et al<sup>12</sup> measured the distance from the superior border of the mandibular nerve canal to the crest of the ridge on periapical and panoramic radiographs, hypocycloidal tomography, and computerized tomography taken on mandibular specimens. The mandibular specimens were then sectioned and the actual distance was measured. They reported that the CT images gave the most accurate position of the mandibular canal.

Sonick et al<sup>14</sup> fabricated a customized acrylic-resin template with gutta percha markers for a human cadaver mandible. They measured the distance between the markers and known mandibular anatomic locations. They also took periapical, panoramic, and CT scans radiographs of the mandible with stent and recorded similar readings from the radiographs. They reported that the measurements taken on the CT scans were the most accurate. Lindh et al<sup>13</sup> examined the visibility of the mandibular canal in cadaver mandibles with CT scan images, PA and panoramic radiographs. The mandibular specimens were subsequently sectioned for contact radiography that served as the "gold standard". They also reported that computerized tomography gave better visualization of the mandibular canal than periapical and panoramic radiography.

Collectively the cited studies demonstrated that CT scan images are superior to intraoral and panoramic radiography to visualize the mandibular canal. Our data agree with the cited studies and further extend their findings into the realm of clinical utilization and management of actual implant patients. CT scan images, because of the multiple views they offer, were able to overcome the bone thickness hindrances of the posterior mandible and allow an accurate visualization of the

mandibular canal not only in relation to the alveolar crest but also in a buccolingual direction.

Furthermore, in the pre-assessment phase of the study, when we were reviewing available records to select the images to be used for the study, many of the PAs reviewed did not show the mandibular canal region in the image. Quite often the image area of the radiographic sensor was not wide enough to include the mandibular canal region apical to the root apices. Because of these inadequacies many of these records were rejected. These limitations provide another reason to exercise caution when using PA radiographs for visualization of the mandibular nerve.

In this study for consistency we only used CT scans. The current trend is shifting towards the use of cone beam CT scans. Since cone beam CT scans offer the same views provided by CT scans and the software used to measure ridge height on CT scans is also used to measure ridge height on cone beam CT scans, the findings from this study would also be applicable to cone beam CT scan images.

In conclusion, our findings showed that under normal clinical use, maxillary PAs tend to approximate CT ridge-height measurements. By contrast mandibular PAs tend to underestimate the distance from the crest of the ridge to the inferior alveolar canal. These findings are consistent with the notion that PA radiographs are unreliable diagnostic/treatment-planning aids for placement of dental implants in the posterior mandible. Based on these findings, it is recommended that CT scans be used in the pre-surgical planning of implant placement in the mandibular posterior region.

#### ABBREVIATIONS

CT: computerized tomography

PA: periapical

#### ACKNOWLEDGMENT

This study was supported in part by NIMHD/NCRR NIH R25RR017577 for Meharry CRECD program, and served as part of a Masters in Science in Clinical Investigation award to RJ.

#### REFERENCES

1. Grondahl HG, Grondahl K. Radiographic examination of the implant patient. In: Lang NP, Lindhe J, eds. *Clinical Periodontology and Implant Dentistry*. 5th ed. Ames, Iowa: Blackwell Publishing; 2008:600–622.

2. Tetradis S, Klokkevold PR. Diagnostic imaging for the implant patient. In: Newman M, Takei H, Klokkevold PR, eds. *Carranza's Clinical Periodontology*. 11th ed. St Louis, Missouri: Elsevier; 2011:649–662.
3. Andersson JE, Svartz K. CT-scanning in the preoperative planning of osseointegrated implants in the maxilla. *Int J Oral Maxillofac Surg*. 1988;17:33–35.
4. Quirynen M, Lamoral Y, Dekeyser C, et al. CT scan standard reconstruction technique for reliable jaw bone volume determination. *Int J Oral Maxillofac Implants*. 1990;5:384–389.
5. Scaf G, Lurie AG, Mosier KM, Kantor ML, Ramsby GR, Freedman ML. Dosimetry and cost of imaging osseointegrated implants with film-based and computed tomography. *Oral Surg Oral Med Oral Pathol Oral Radiol Endod*. 1997;83:41–48.
6. Clark DE. Absorbed dose determination for tomographic implant site assessment techniques. *Oral Surg Oral Med Oral Pathol*. 1993;75:3–4.
7. Dula K, Mini R, Lambrecht JT, et al. Hypothetical mortality risk associated with spiral tomography of the maxilla and mandible prior to endosseous implant treatment. *Eur J Oral Sci*. 1997;105:123–129.
8. Dula K, Mini R, van der Stelt PF, Lambrecht JT, Schneeberger P, Buser D. Hypothetical mortality risk associated with spiral computed tomography of the maxilla and mandible. *Eur J Oral Sci*. 1996;104:503–510.
9. Ekestubbe A, Thilander A, Grondahl K, Grondahl HG. Absorbed doses from computed tomography for dental implant surgery: comparison with conventional tomography. *Dentomaxillofac Radiol*. 1993;22:13–17.
10. BouSerhal C, Jacobs R, Quirynen M, van Steenberghe D. Imaging technique selection for the preoperative planning of oral implants: a review of the literature. *Clin Implant Dent Relat Research*. 2002;4:156–172.
11. Dula K, Mini R, van der Stelt PF, Buser D. The radiographic assessment of implant patients: decision-making criteria. *Int J Oral Maxillofac Implants*. 2001;16:80–89.
12. Klinge B, Petersson A, Maly P. Location of the mandibular canal: comparison of macroscopic findings, conventional radiography, and computed tomography. *Int J Oral Maxillofac Implants*. 1989;4:327–332.
13. Lindh C, Petersson A, Klinge B. Visualisation of the mandibular canal by different radiographic techniques. *Clin Oral Implants Res*. 1992;3:90–97.
14. Sonick M, Abrahams J, Faiella R. A comparison of the accuracy of periapical, panoramic, and computerized tomographic radiographs in locating the mandibular canal. *Int J Oral Maxillofac Implants*. 1994;9:455–460.
15. Wheeler DJ. *EMP (Evaluating the Measurement Process) III Using Imperfect Data*. Knoxville, Tenn: SPC Press; 2006.
16. Bland JM, Altman DG. Statistical methods for assessing agreement between two methods of clinical measurement. *Lancet*. 1986;1:307–310.
17. Borzabadi-Farahani A, Borzabadi-Farahani A. Agreement between the index of complexity, outcome, and need and the dental and aesthetic components of the index of orthodontic treatment need. *Am J Orthod Dentofac*. 2011;140:233–238.
18. Borzabadi-Farahani A, Eslamipour F, Asgari I. A comparison of two orthodontic aesthetic indices. *Aust Orthod J*. 2012;28:30–36.
19. Bartling R, Freeman K, Kraut RA. The incidence of altered sensation of the mental nerve after mandibular implant placement. *J Oral Maxillofac Surg*. 1999;57:1408–1412.
20. Kraut RA, Chahal O. Management of patients with trigeminal nerve injuries after mandibular implant placement. *J Am Dent Assoc*. 2002;133:1351–1354.
21. Araujo M, Lindhe J. The edentulous alveolar ridge. In: Lindhe J, Lang NP, eds. *Clinical Periodontology and Implant Dentistry*. 5th ed. Ames, Iowa: Blackwell Publishing; 2008:50–68.
22. Lindhe J, Karring T, Araujo M. The anatomy of the periodontal tissues. In: Lindhe J, Lang NP, eds. *Clinical Periodontology and Implant Dentistry*. 5th ed. Ames, Iowa: Blackwell Publishing; 2008:3–49.
23. Sakakura CE, Morais JA, Loffredo LC, Scaf G. A survey of radiographic prescription in dental implant assessment. *Dentomaxillofac Radiol*. 2003;32:397–400.
24. Tal H, Moses O. A comparison of panoramic radiography with computed tomography in the planning of implant surgery. *Dentomaxillofac Radiol*. 1991;20:40–42.
25. Yim JH, Ryu DM, Lee BS, Kwon YD. Analysis of digitalized panorama and cone beam computed tomographic image distortion for the diagnosis of dental implant surgery. *J Craniofac Surg*. 2011;22:669–673.
26. Curry TS, Dowdey JE, Murry RC. *Christensen's Physics of Diagnostic Radiology*. 4th ed. Philadelphia: Lippincott Williams & Wilkins; 1990.
27. McGivney GP, Haughton V, Strandt JA, Eichholz JE, Lubar DM. A comparison of computer-assisted tomography and data-gathering modalities in prosthodontics. *Int J Oral Maxillofac Implants*. 1986;1:55–68.
28. Park YB, Jeon HS, Shim JS, Lee KW, Moon HS. Analysis of the anatomy of the maxillary sinus septum using 3-dimensional computed tomography. *J Oral Maxillofac Surg*. 1070;69:1070–1078.