

# Dental Gypsum Verification Jig to Verify Implant Positions: A Clinical Report

Abdulmohsin Alhashim, BDS, MSD<sup>1\*</sup>  
Robert J. Flinton, DDS, MS<sup>2</sup>

## INTRODUCTION

**R**ehabilitation of a completely edentulous arch with an implant-supported prosthesis is a predictable treatment modality.<sup>1-3</sup> In large measure, the occlusal scheme and restorative materials for implant-supported prostheses are determined by the opposing arch. When the opposing arch is restored with a complete denture, a metal-reinforced two- to four-implant-retained/supported prosthesis with a bilateral balanced occlusion is recommended.<sup>4-7</sup> For example, if the maxillary arch is restored with an all-implant-supported hybrid prosthesis, the choice of mandibular prosthesis may be a similar all-implant-supported prosthesis or four fixture/dual bar-implant supported and retained prosthesis. Metal is the material of choice to reinforce such prostheses. Distortion of the metal framework from expansion/shrinkage of the materials, used in the lost wax technique, often requires the framework to be sectioned and soldered to obtain a passive fit. Nobel alloys usually provide a more accurate fit and, if necessary, can be relatively easy to solder—but the cost of high noble alloys is prohibitive.

Today, with the introduction of computer-aided design/computer-assisted machining (CAD/CAM), milled frameworks have a significantly better fit than the conventional casting technique. The milled framework is generally milled out of titanium and is considerably less expensive to construct than are cast frameworks.

Since titanium cannot be laser welded conven-

tionally,<sup>8</sup> one must use a jig to verify the accuracy of the implant analog master cast. This verification jig is usually fabricated from acrylic resin, which has 6% dimensional shrinkage.<sup>9</sup> The use of more accurate materials for the verification jig fabrication—such as dental gypsum, which has a total distortion of 0.08–0.2%<sup>9</sup>—will provide greater accuracy relative to implant position than will acrylic resin. Acrylic resin attaches to cast metal via mechanical retention, produced by the addition of beads and strips to the wax pattern to obtain undercuts. Such undercuts are not easily milled into titanium frameworks; therefore, cutting undercuts into the framework after milling is a good alternative. This case report demonstrates fabrication of a verification jig using gypsum and a fixed dental prosthesis using a milled titanium framework and acrylic resin.

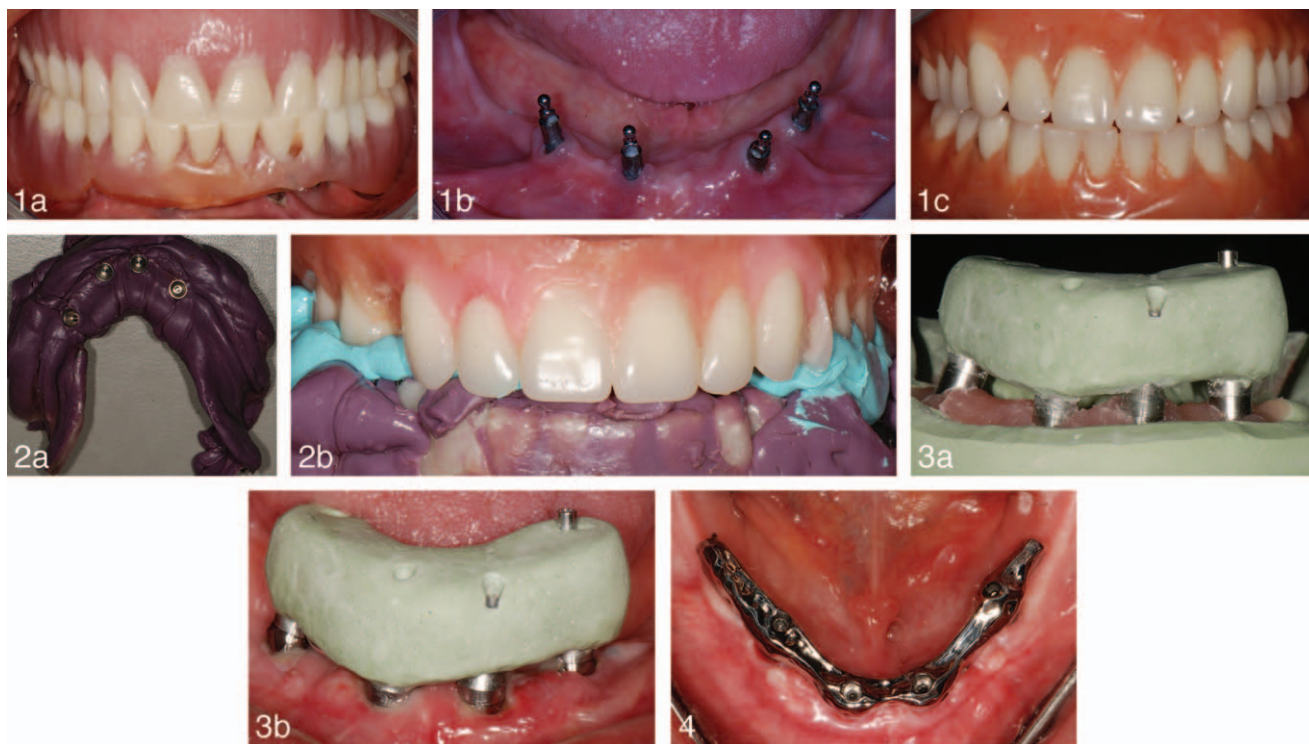
## CASE REPORT

An 83-year-old African-American female presented for treatment with chief complaint: “My lower denture is uncomfortable, and I believe it was done right.” A review of the patient’s medical history revealed no significant findings. The patient had four temporary implants in the mandible that were angled labially and showed through the mandibular denture base (Figure 1a and b). The soft tissues around the temporary implants were inflamed and suppurative. The patient had an atrophic mandible with high muscle attachments and a lack of keratinized tissue. Maxillary and mandibular preliminary impressions were made in stock metal trays with irreversible hydrocolloid impression material (Jeltrate, DENTSPLY, York, Pa). The impressions were poured with Type III dental stone (Microstone, Whip Mix, Louisville, Ky). Record bases were fabricated with acrylic resin (Triad Tru Tray, York, Pa), and occlusion rims were added using baseplate wax. The existing temporary implants were recontoured

<sup>1</sup> Department of Oral Rehabilitation, College of Dental Medicine, Georgia Health Sciences University, Augusta, Ga.

<sup>2</sup> Department of Restorative Dentistry, University of Medicine and Dentistry of New Jersey – New Jersey Dental School, Newark, NJ.

\* Corresponding author, e-mail: aalhashim@georgiahealth.edu  
DOI: 10.1563/AAID-JOI-D-12-00196



**FIGURES 1–4. FIGURE 1.** (a and b) Wear of anterior teeth on existing dentures was present due to edge to edge occlusion. High frenal attachment, lack of keratinized tissue and ill-fitting mandibular denture contributed to gingival inflammation around labially angled implants. (c) Diagnostic dentures with adequate anterior tooth overlap were fabricated to meet patient's esthetic expectations and use for surgical guide fabrication. **FIGURE 2.** (a and b) Final impression and centric relation record utilizing mandibular surgical guide against Maxillary wax trial denture. **FIGURE 3.** (a and b) Verification jig was fabricated from dental stone on the master cast. One screw in one end of the jig was tightened to stabilize the jig while radiographs were taken to verify implant positions. Tissue around implant was healing after partial thickness flap procedure to gain keratinized tissue. **FIGURE 4.** Framework was tried-in intraorally to verify the fit. The milled framework had smooth surface and lacked mechanical undercuts which were necessary for acrylic attachment. Gingival tissue around implants healed uneventfully.

with a diamond bur at high speed under copious water to permit an ideal anterior tooth placement. A tentative vertical dimension of occlusion (VDO) was established; a centric relation record was made using Aluwax (BencoDental, Pittston, Pa); a face bow transfer was made using the Hanau Spring-Bow (Hanau/Denar, Anaheim, Calif); and the maxillary diagnostic cast was mounted on a Hanau Wide-View articulator with Type III mounting stone (Mounting Stone, Whip Mix). The mandibular diagnostic cast was mounted using the centric relation record at VDO. Esthetics and phonetics were used to set the maxillary anterior teeth with the patient present. The centric relation was verified and protrusive record was taken to program the articulator settings for the horizontal and lateral condylar indications. Ivoclar Ortholingual teeth (Amherst, NY) were used to develop a balanced, lingualized occlusal scheme since it was opposing a

maxillary complete denture. At the wax trial denture appointment, VDO, CR, esthetics, and phonetics were confirmed. A duplicate of the maxillary wax trial denture was made to be used for fabrication of the final prosthesis. The maxillary and the mandibular wax trial dentures were flaked and processed conventionally with Luciton 199 and were termed called diagnostic dentures (Figure 1c). The diagnostic dentures were inserted and pressure indicating paste was used to verify complete seating. The borders were checked with disclosing wax and adjusted accordingly. A patient remount procedure was accomplished, and the occlusion was refined. The mandibular diagnostic denture was duplicated in orthodontic acrylic resin (Caulk Orthodontic Resin, DENTSPLY) to fabricate a surgical guide for implant placement. The existing temporary implants were surgically removed and four implants ( $4.3 \times 13$  mm Replace Select, Nobel Biocare, Yorba

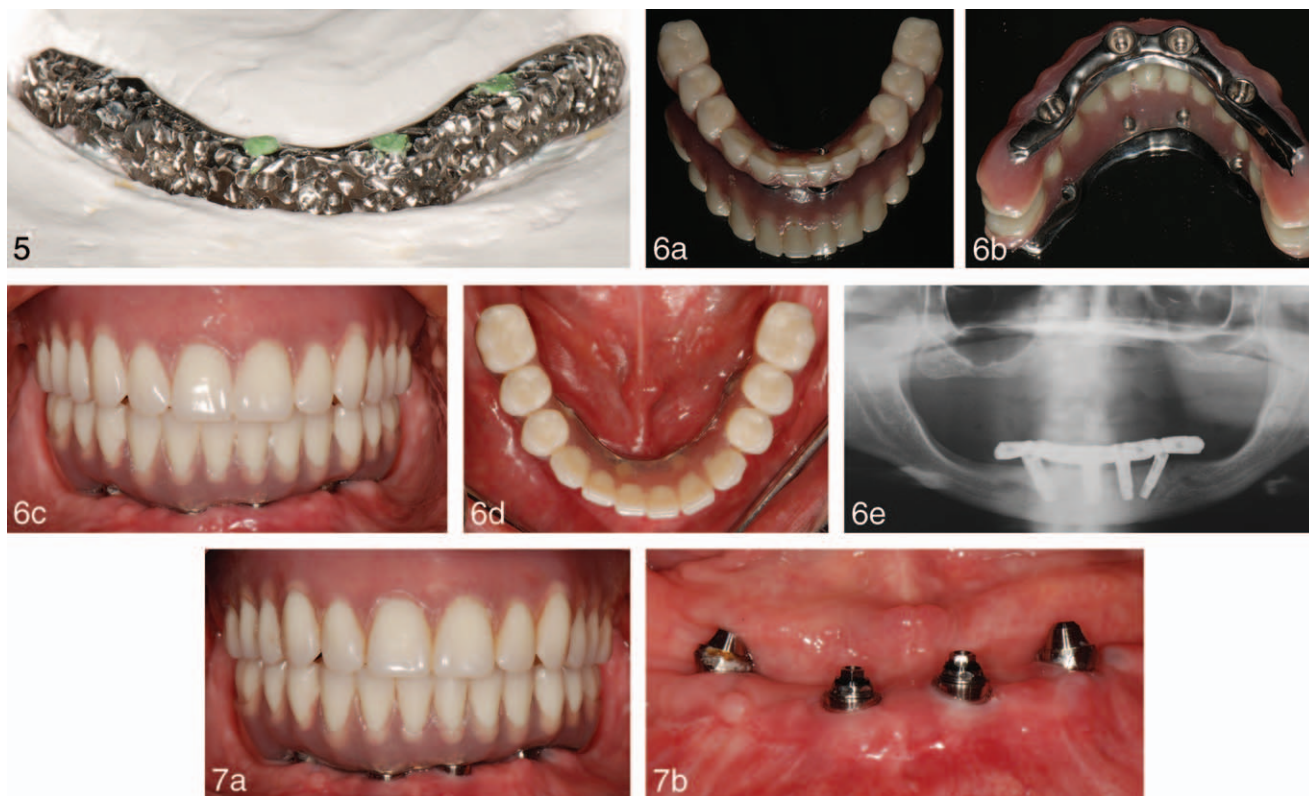
Linda, Calif) were placed in the mandible, using the all-on-four technique and allowed to heal for four months.<sup>10–13</sup>

Uncovery of the implants was performed. Four multi-unit abutments (Nobel Biocare) were torqued down to 32N/cm; the two distal abutments were angled at 30°, and the two forward abutment were placed vertically. The surgical guide was hollowed out to create room for the impression copings, and an open tray, fixture-level impression was made in medium body polyether impression material (Impregum, 3M, ESPE, Seefeld, Germany) using the surgical guide (Figure 2a). The patient was guided into centric relation to confirm complete seating and articulation. A centric relation record was made with vinyl polysiloxane (Blu-Mousse, Parkell Inc, Edgewood, NY) against the duplicated maxillary wax trial denture (Figure 2b). The surgical guide with the impression copings was unscrewed and removed from the patient's mouth in one piece. Implant analogs were connected to impression copings and gingival moulage (Gi-Mask, Coltene, Whaledent Inc, NY) was injected around the junction of the impression copings and the analogs. The impression was poured with Type IV dental stone (Microstone). A verification jig made of Type V dental stone (Die Keen) and four non-engaging temporary abutments were tried in the mouth to verify the accuracy of the mandibular master cast (Figure 3a and b). The mandibular master cast was mounted to the duplicated maxillary wax trial denture using the centric relation record, and a labial index made of putty (Coltene, Pearson Dental, Sylmar, Calif), was fabricated before the surgical guide was recovered. The surgical guide was removed from the mandibular master cast. Four plastic temporary abutments were screwed onto the mandibular master cast, and the mandibular framework was formed using a pattern resin. Ideal design of the framework was aided by the use of the labial index made from the surgical guide, which was a duplicate of the original diagnostic denture. The resin pattern framework was scanned using a CAD/CAM touch probe scanner (Forte, Nobelbiocare, Mahwah, NJ) to fabricate a screw retained titanium framework. The fit of the framework was confirmed with a one-screw test and radiographs (Figure 4). The mandibular teeth were attached to the titanium framework using the labial index. The duplicated wax trial prostheses were

tried in the mouth and evaluated for esthetics, phonetics, the vertical dimension of occlusion and centric relation. A face bow preservation index was fabricated. Four implant analogs were attached to the mandibular wax trial prosthesis before flasking. The mandibular wax trial prosthesis was flasked. Mechanical undercuts were created in the titanium framework at high speed with a coarse inverted cone diamond bur under water coolant. Screw access holes were blocked with putty before acrylic packing and processed with Luciton 199 (Figure 5). The maxillary wax trial denture was flasked and processed conventionally with Luciton 199. Both processed dentures were deflasked and replaced on the plaster mounts on the articulator. A laboratory remount was performed to eliminate processing errors. The prostheses were removed from the casts, finished and polished (Figure 6a and b). The maxillary denture was inserted, and pressure indicating paste was used to verify complete seating. The borders were checked with disclosing wax and adjusted accordingly. The relationship of the intaglio surface of the mandibular prosthesis to the soft tissue was evaluated with the pressure indicating paste and adjusted accordingly. Disclosing material, explorer, and radiographs were used to confirm complete seating of the mandibular prosthesis (Figure 6c). The prosthesis was torqued down to 15 N/cm. A centric relation record was made with modeling plastic impression compound on the mandibular prosthesis, and the mandibular prosthesis was mounted against the maxillary denture. A new centric relation record was made to verify the remounted prostheses. Selective grinding was performed to refine the balanced lingualized occlusal scheme. The occlusion again was verified intraorally (Figure 6d and e).

The patient was given instructions on how to use and maintain the prostheses. The use of super floss and waterpik to clean underneath the mandibular prosthesis was demonstrated to the patient. The patient was seen after 24 hours, and minor adjustments were made. It was explained to the patient that the maxillary complete denture will need a relin or remake in the future, and it should be done when required to maintain healthy, physiologic tissue and prevent bone resorption. Recall was scheduled biannually (Figure 7a and b). The positive attitude of the patient, as well as her satisfaction with the treatment that addressed her





**FIGURES 5–7. FIGURE 5.** Mechanical undercuts were created with high-speed and a diamond bur before teeth were attached to the milled framework. Screw-access holes were blocked with putty before acrylic packing. **FIGURE 6.** (a through e) Occlusal and intaglio surfaces of the completed mandibular prosthesis. Treatment result with proper teeth set up. Screw access holes were closed with composite. The panoramic radiograph confirms complete seating of the prosthesis and shows some of the mechanical undercuts within the milled framework. **FIGURE 7.** (a and b) Treatment result at 6-month follow-up. Retrievability is one of the advantages of screw-retained prostheses. Tissue around implant looks healthy. There was some calculus on one of the distal abutments which was shown to the patient and explained the importance of oral hygiene reinforcement in that particular area.

chief complaints and desires contributed to a good prognosis.

#### DISCUSSION

CAD/CAM technology produces a better fitting and less expensive framework when compared with the lost wax technique.<sup>14–17</sup> Mechanical undercuts are necessary for acrylic resin attachment to the framework. The mechanical undercuts cannot be milled easily with the present CAD/CAM technology. In this case report, the mechanical undercuts were created after the titanium framework was milled. There was no negative effect on the fit of the titanium framework after creation of mechanical undercuts when checked on the definitive cast and in the patient's mouth. Verification jigs are recommended before milling frameworks and usually made out of acrylic resin, which has a 6%

dimensional shrinkage<sup>9</sup>; this is significant relative to attaining passive fit frameworks. The use of more accurate materials for verification jigs fabrication—such as dental gypsum, which has a total distortion of 0.08–0.2%<sup>9</sup>—will provide greater accuracy in reproducing the exact positions of the implants than will those made of acrylic resin. If a framework fits the definitive cast that has implant positions verified by use of a verification jig made out of type IV dental stone, the fit of the framework in the patient's mouth will be predictable. If the dental stone verification jig, made on the definitive cast, does not fit in the patient's mouth, it must be cut until it seats. Lute the units together with impression plaster and make an open tray final impression in Impregum (3M, ESPE). Verification of implant positions in the new definitive cast is recommended with a new verification jig to rule out any errors encountered in handling and pouring up the final

impression. Restorative materials that contact the underlying tissue surface have a major role in keeping the underlying tissue healthy. Titanium is more biocompatible than acrylic resin because it is smoother and less porous.<sup>18,19</sup> Commercial laboratories charge a higher fee when processing a hybrid prosthesis as compared to a complete denture. This case report demonstrates an economical technique to process the hybrid prosthesis conventionally.

#### ABBREVIATIONS

CAD/CAM: computer-aided design/computer-assisted machining

VDO: virtual dimension of occlusion

#### ACKNOWLEDGMENTS

The authors thank Ms. Eva Bober (CDT/MDT, Department of Restorative Dentistry, University of Medicine and Dentistry of New Jersey – New Jersey Dental School, Newark, NJ) for her contributions and guidance in the technical aspects throughout the treatment. Also, special thanks to Dr. Norachai Phisuthikul (Department of Periodontics, University of Medicine and Dentistry of New Jersey – New Jersey Dental School, Newark, NJ) for the successful implant placements.

#### REFERENCES

1. Branemark PI, Hansson BO, Adell R, et al. Osseointegrated implants in the treatment of the edentulous jaw. Experience from a 10-year period. *Scand J Plast Reconstr Surg Suppl.* 1977;16:1–132.
2. Adell R, Lekholm U, Rockler B, Branemark PI. A 15-year study of osseointegrated implants in the treatment of the edentulous jaw. *Int J Oral Surg.* 1981;10:387–416.
3. Adell R, Eriksson B, Lekholm U, Branemark PI, Jemt T. Long-term follow-up study of osseointegrated implants in the treatment of totally edentulous jaws. *Int J Oral Maxillofac Implants.* 1990;5:347–359.

4. Lang BR, Razzoog ME. Lingualized integration: tooth molds and an occlusal scheme for edentulous implant patients. *Implant Dent.* 1992;1:204–211.
5. Reitz JV. Lingualized occlusion in implant dentistry. *Quintessence Int.* 1994;25:177–180.
6. Sadowsky SJ. The implant-supported prosthesis for the edentulous arch: design considerations. *J Prosthet Dent.* 1997;78:28–33.
7. Nikolopoulou F, Ktena-Agapitou P. Rationale for choices of occlusal schemes for complete dentures supported by implants. *J Oral Implantol.* 2006;32:200–203.
8. Liu J, Watanabe I, Yoshida K, Atsuta M. Joint strength of laser-welded titanium. *Dent Mater.* 2002;18:143–148.
9. Craig RG. *Restorative Dental Materials.* 10th ed. Philadelphia, PA: Mosby; 1997.
10. Malo P, Rangert B, Nobre M. “All-on-four” immediate-function concept with Branemark system implants for completely edentulous mandibles: a retrospective clinical study. *Clin Implant Dent Relat Res.* 2003;5(suppl 1):2–9.
11. Khatami AH, Smith CR. “All-on-four” immediate function concept and clinical report of treatment of an edentulous mandible with a fixed complete denture and milled titanium framework. *J Prosthodont.* 2008;17:47–51.
12. Ferreira EJ, Kuabara MR, Gulinelli JL. “All-on-four” concept and immediate loading for simultaneous rehabilitation of the atrophic maxilla and mandible with conventional and zygomatic implants. *Br J Oral Maxillofac Surg.* 2010;48:218–220.
13. Pomares C. A retrospective study of edentulous patients rehabilitated according to the “all-on-four” or the “all-on-six” immediate function concept using flapless computer-guided implant surgery. *Eur J Oral Implantol.* 2010;3:155–163.
14. Drago C, Saldarriaga RL, Domagala D, Almasri R. Volumetric determination of the amount of misfit in CAD/CAM and cast implant frameworks: a multicenter laboratory study. *Int J Oral Maxillofac Implants.* 2010;25:920–929.
15. Abduo J, Lyons K, Bennani V, Waddell N, Swain M. Fit of screw-retained fixed implant frameworks fabricated by different methods: a systematic review. *Int J Prosthodont.* 2011;24:207–220.
16. Almasri R, Drago CJ, Siegel SC, Hardigan PC. Volumetric misfit in CAD/CAM and cast implant frameworks: a university laboratory study. *J Prosthodont.* 2011;20:267–274.
17. Karl M, Holst S. Strain development of screw-retained implant-supported fixed restorations: procera implant bridge versus conventionally cast restorations. *Int J Prosthodont.* 2012;25:166–169.
18. Akagawa Y, Hashimoto M, Kondo N, Yamasaki A, Tsuru H. Tissue reaction to implanted biomaterials. *J Prosthet Dent.* 1985;53:681–686.
19. Fujioka-Hirai Y, Akagawa Y, Minagi S, Tsuru H, Miyake Y, Suginaka H. Adherence of *Streptococcus mutans* to implant materials. *J Biomed Mater Res.* 1987;21:913–920.